Please visit us at www.Groupinsiders.com

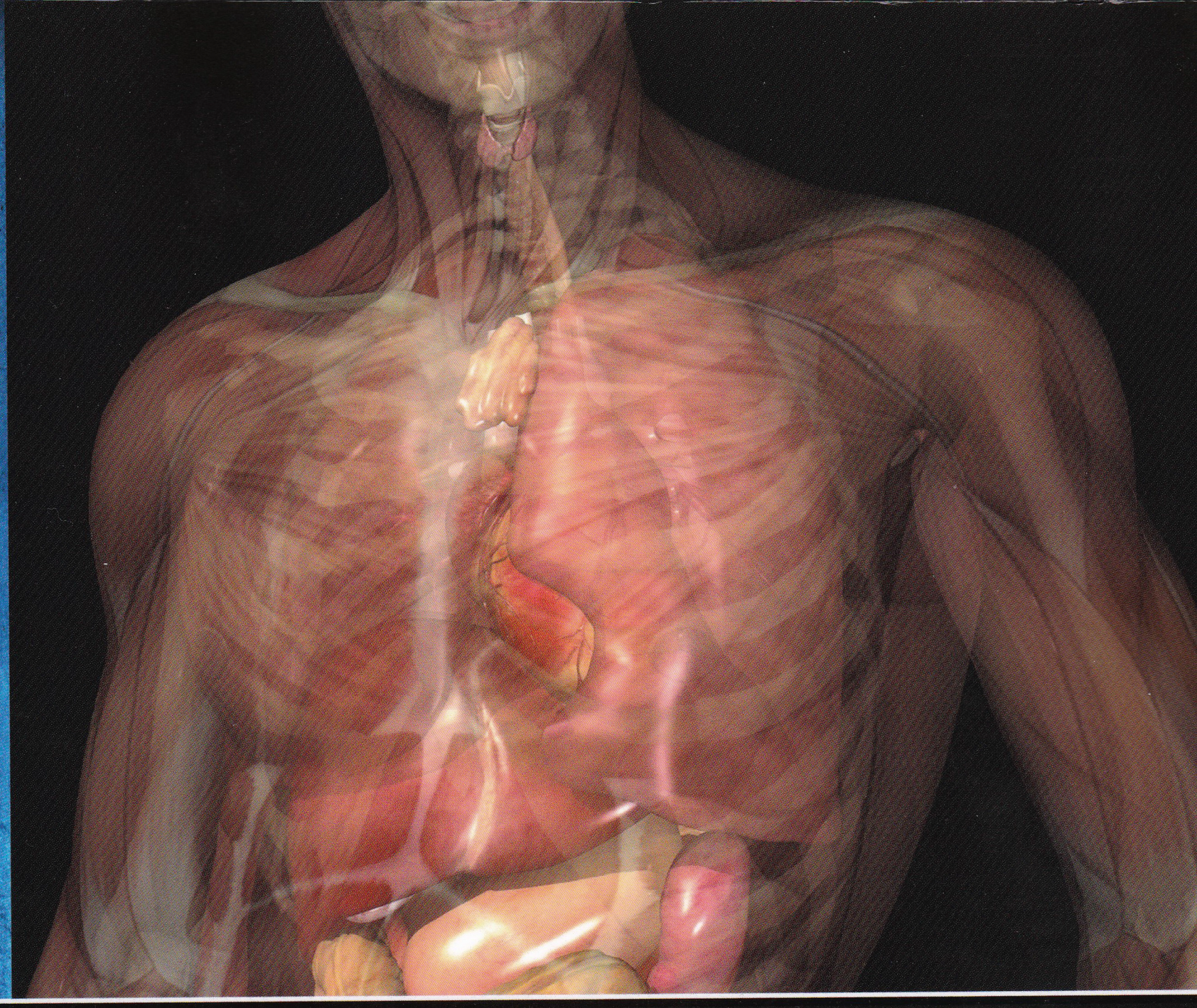

Anatomy

USMLE STEP 1

BECKER
PROFESSIONAL EDUCATION®

Please visit us at www.Groupinsiders.com

USMLE Step 1

Anatomy

Dr. Jack Wilson, PhD

National Instructor

V 1.2

Please visit us at www.Groupinsiders.com

Please visit us at www.Groupinsiders.com

Dr. Jack Wilson, PhD
Professor of Anatomy and Neurobiology
University of Tennessee Health Science Center
Memphis, TN

Steven R. Daugherty, PhD
Director, Faculty and Curriculum at Becker Professional Education
Chicago, IL

The United States Medical Licensing Examination® (USMLE®) is a joint program of the Federation of State Medical Boards (FSMB) and National Board of Medical Examiners® (NBME®). United States Medical Licensing Examination, USMLE, National Board of Medical Examiners, and NBME are registered trademarks of the National Board of Medical Examiners. The National Board of Medical Examiners does not sponsor, endorse, or support Becker Professional Education in any manner.

© 2013 by DeVry/Becker Educational Development Corp. All rights reserved.

No part of this work may be reproduced, translated, distributed, published or transmitted without the prior written permission of the copyright owner. Request for permission or further information should be addressed to the Permissions Department, DeVry/Becker Educational Development Corp.

3 4 5 6 7 8 9 18 17 16 15 14 13

Table of Contents

Anatomy

Unit 1 Early Human Development

Chapter 1 Early Human Development 1-1
1 Gametogenesis 1-1
2 Genital System Development 1-7

Chapter 2 Week 1: Fertilization to Early Implantation 2-1
1 Fertilization 2-1

Chapter 3 Week 2: Bilaminar Disk and Implantation 3-1
1 Bilaminar Disk and Implantation 3-1

Chapter 4 Week 3: Gastrulation 4-1
1 Gastrulation 4-1

Review Questions: Chapters 1–4 4-5

Unit 2 Gross Anatomy and Organogenesis

Chapter 5 The Back 5-1
1 Skeletal System of the Back and Spinal Cord 5-1
2 Spinal Nerves 5-11

Chapter 6 Autonomic Nervous System 6-1
1 Introduction 6-1
2 Divisions of the ANS: Sympathetic and Parasympathetic Nervous System 6-4

Review Questions: Chapters 5-6 6-10

Please visit us at www.Groupinsiders.com

© DeVry/Becker Educational Development Corp. All rights reserved.

Table of Contents

Anatomy

Chapter 7 Thorax 7-1

1 Thoracic Wall 7-1
2 Lungs and Pleurae 7-5
3 Serous Membranes and Pleura 7-7
4 Lungs 7-10
5 Mediastinum and Development of the Heart 7-12
6 Septation of the Heart Tube 7-18
7 Adult Heart 7-27
8 Overview of Mediastinum 7-39
9 Radiology Images 7-44

Review Questions: Chapter 7 7-49

Chapter 8 Abdomen 8-1

1 Planes and Regions of the Anterior Wall of the Abdomen 8-1
2 Layers of the Anterior Body Wall and Their Contributions to the Inguinal Region and Canal 8-3
3 Inguinal Canal 8-5
4 Inguinal Hernia 8-8
5 Descent of the Testis 8-11
6 Development of the Gut Tube 8-13
7 Three Important Foregut Derivatives 8-20
8 Midgut Development 8-22
9 Major Congenital Defects of the Gut Tube 8-23
10 Adult Viscera of the Abdomen 8-26
11 Blood Supply to Abdomen 8-32
12 Veins of the Abdomen 8-37
13 Development of the Urinary System 8-40
14 Posterior Abdominal Wall 8-45
15 Radiology Images 8-47

Please visit us at www.Groupinsiders.com

© DeVry/Becker Educational Development Corp. All rights reserved.

Table of Contents

Anatomy

Chapter 9 Pelvis and Perineum 9-1
1 Muscular Diaphragms of the Pelvis and Perineum 9-1
2 Perineum 9-6

Review Questions: Chapters 8-9 9-11

Chapter 10 Upper Limb 10-1
1 Overview 10-1
2 Development of Limbs 10-1
3 Brachial Plexus 10-2
4 Cutaneous Nerves of the Forearm and Hand 10-4
5 Lesions of the Upper Limb and Brachial Plexus 10-5
6 Blood Supply to the Upper Limb 10-11
7 Rotator Cuff Muscles of the Shoulder Joint 10-13
8 Carpal Tunnel 10-14
9 Radiology Images 10-15

Chapter 11 Lower Limb 11-1
1 Overview 11-1
2 Lumbosacral Plexus 11-1
3 Segmentation of Nerve Fibers in Lumbosacral Plexus 11-3
4 Cutaneous Innervation of the Foot and Lower Leg 11-3
5 Nerve Lesions of the Lower Limb 11-4
6 Blood Supply to the Lower Limb 11-6
7 Knee Joint 11-10

Review Questions: Chapters 10-11 11-14

Chapter 12 Head and Neck 12-1
1 Head and Neck Development 12-1
2 Blood Vessels of the Head and Neck 12-9
3 Foramina in the Skull 12-10
4 Meninges of the Brain 12-12
5 Dural Venous Sinuses 12-14

Review Questions: Chapter 12 12-17

Please visit us at www.Groupinsiders.com

© DeVry/Becker Educational Development Corp. All rights reserved.

Table of Contents

Anatomy

Unit 3 Neuroscience

Chapter 13 Introduction and Embryology of the Nervous System 13-1

1 Overview of the Nervous System 13-1
2 Embryology of the Nervous System 13-3
3 Review of the Autonomic Nervous System 13-8

Chapter 14 Neurohistology 14-1

1 Cellular Elements of the Nervous System 14-1
2 Axon Transport 14-5
3 Regeneration of Axons 14-7

Chapter 15 Meninges and Circulation of Cerebrospinal Fluid 15-1

1 Dural Venous Sinuses 15-1
2 Cerebrospinal Fluid 15-3
3 Ventricular System of the Brain 15-4

Review Questions: Chapter 13-15 15-7

Chapter 16 Spinal Cord 16-1

1 General Structure of the Spinal Cord 16-1
2 Typical Spinal Nerve 16-2
3 Internal Structure of the Spinal Cord 16-4
4 Overview of Long Tract Systems of the Spinal Cord 16-7
5 Descending Long Tract Systems 16-8
6 Reflex Innervation of Skeletal Muscles 16-12
7 Ascending Sensory Long Tract Systems 16-17
8 Spinal Cord Lesions 16-27

Review Questions: Chapter 16 16-33

Please visit us at www.Groupinsiders.com

© DeVry/Becker Educational Development Corp. All rights reserved.

Table of Contents

Anatomy

Chapter 17 Brainstem 17-1

1 Overview 17-1
2 Surface Features of the Brainstem 17-1
3 Cranial Nerve Organization and Function 17-5
4 Position of Long Tracts in Brainstem 17-19
5 Internal Organization of the Brainstem and Medulla Oblongata 17-20
6 Pons 17-23
7 Midbrain 17-25
8 Corticobulbar Tract: Upper Motor Neurons for Cranial Nerve and Lower Motor Neurons 17-27
9 Auditory and Vestibular Systems: CN VIII 17-30
10 Voluntary Horizontal Gaze 17-40
11 Blood Supply to the Brainstem 17-42
12 Brainstem Syndromes 17-44

Review Questions: Chapter 17 2-28

Chapter 18 Cerebellum 18-1

1 Overview 18-1
2 Organization of the Cerebellum 18-2
3 Cerebellar Afferents (Inputs) 18-4
4 Microscopic Structure 18-5
5 Cerebellar Efferents (Outputs) 18-8
6 Lesions of the Cerebellum 18-10

Chapter 19 Basal Ganglia 19-1

1 Components of the Basal Ganglia 19-1
2 Basal Ganglia Afferents 19-4
3 Interconnections of Basal Ganglia: Direct and Indirect Pathways 19-4
4 Cognitive Function 19-7
5 Functional Review 19-7
6 Basal Ganglia Disorders 19-8

Review Questions: Chapters 18-19 19-10

Please visit us at www.Groupinsiders.com

© DeVry/Becker Educational Development Corp. All rights reserved.

Table of Contents

Anatomy

Chapter 20 The Visual System 20-1

1 Overview 20-1
2 Components of the Eyeball 20-1
3 Pupillary Light Reflex 20-3
4 Accommodation Reflex 20-4
5 Histology of the Retina 20-5
6 Visual Pathway 20-7
7 Visual Field Defects 20-8

Review Questions: Chapter 20 20-9

Chapter 21 Diencephalon 21-1

1 Divisions of the Diencephalon 21-1

Chapter 22 Cerebral Cortex 22-1

1 Overview 22-1
2 Surface Features of the Cortex 22-1
3 Somatotopic Regions of the Cortex: Homunculus 22-3
4 Cell Layers of the Cortex 22-4
5 Blood Supply of the Cortex 22-5
6 Functional Areas of the Cortex 22-8
7 Language Disorders (Aphasias) 22-11
8 Additional Cortical Disorders 22-13
9 Internal Capsule 22-16

Chapter 23 Limbic System 23-1

1 Overview of the Limbic System 23-1
2 Papez Circuit 23-2
3 Amygdala 23-3
4 Cortex Review 23-4

Review Questions: Chapters 21-23 23-5

Please visit us at www.Groupinsiders.com

© DeVry/Becker Educational Development Corp. All rights reserved.

Table of Contents

Anatomy Figures

Unit 1 Early Human Development

Chapter 1 Early Human Development

Figure 1-1.2A . . Spermatogenesis 1-3
Figure 1-1.2B . . Oogenesis 1-5
Figure 1-2.2A . . Urogenital Ridge and Indifferent Gonads 1-7
Figure 1-2.2B . . Migration of Primordial Germ Cells 1-8
Figure 1-2.3A . . Indifferent Gonad 1-9
Figure 1-2.3B . . Male Genital Development 1-10
Figure 1-2.3C . . Female Genital Development 1-11
Figure 1-2.4 . . . Development of External Genitalia 1-12
Figure 1-2.5 . . . Developmental Anomalies of External Genitalia 1-13

Chapter 2 Week 1: Fertilization to Early Implantation

Figure 2-1.0 . . . Week One 2-1

Chapter 3 Week 2: Bilaminar Disk and Implantation

Figure 3-1.0 . . . Week Two 3-1

Chapter 4 Week 3: Gastrulation

Figure 4-1.0 . . . Gastrulation 4-1

Unit 2 Gross Anatomy and Organogenesis

Chapter 5 The Back

Figure 5-1.1 . . . Vertebral Column 5-1
Figure 5-1.2 . . . Typical Vertebra 5-2
Figure 5-1.3 . . . Anterior and Posterior Longitudinal Ligaments 5-3
Figure 5-1.4A . . Intervertebral Disks 5-4
Figure 5-1.4B . . Herniated Intervertebral Disk 5-5
Figure 5-1.4C . . Herniated Intervertebral Disk (Detail) 5-5
Figure 5-1.5 . . . Spinal Cord in the Vertebral Canal 5-6
Figure 5-1.6 . . . Meninges 5-7
Figure 5-1.7 . . . Meningeal Spaces 5-9
Figure 5-1.8 . . . Interlaminar Spaces 5-10
Figure 5-2.0 . . . Spinal Nerve 5-11
Figure 5-2.1 . . . Exit of Spinal Nerves From Vertebral Column 5-12

Please visit us at www.Groupinsiders.com

© DeVry/Becker Educational Development Corp. All rights reserved.

Table of Contents

Anatomy Figures

Chapter 6 Autonomic Nervous System

Figure 6-1.3 . . . Neurons of the Autonomic Nervous System. 6-2
Figure 6-1.5 . . . Comparison of Somatic and Visceral Neurons 6-3
Figure 6-2.0 . . . Overview of Autonomic Nervous System. 6-4
Figure 6-2.1A . . Sympathetic Nervous System 6-4
Figure 6-2.1B . . Sympathetic Pathways 6-6
Figure 6-2.1C . . Sympathetic Outflow From Spinal Cord. 6-7
Figure 6-2.2A . . Parasympathetic Nervous System Overview 6-8
Figure 6-2.2B . . Parasympathetic Nervous System 6-9

Chapter 7 Thorax

Figure 7-1.1 . . . Thoracic Wall. 7-1
Figure 7-1.2 . . . Thoracic Cavity 7-2
Figure 7-1.3 . . . Mammary Gland 7-3
Figure 7-1.4 . . . Lymphatics of Mammary Gland 7-4
Figure 7-2.1A . . Development of Trachea and Lungs 7-5
Figure 7-2.1B . . Tracheoesophageal Fistula 7-6
Figure 7-3.1A . . Pleurae. 7-7
Figure 7-3.1B . . Pleural Spaces. 7-8
Figure 7-4.0 . . . Lobes of Lungs 7-10
Figure 7-4.1A . . Lymphatics of Lungs. 7-11
Figure 7-4.1B . . Drainage of Thoracic Duct. 7-11
Figure 7-5.0 . . . Mediastinal Compartments 7-12
Figure 7-5.1A . . Heart Tube and Early Heart Development 7-13
Figure 7-5.1B . . Prenatal Circulation 7-15
Figure 7-5.1C . . Postnatal Circulation 7-17
Figure 7-6.1A . . Atrial Septation 7-18
Figure 7-6.1B . . Adult Right Atrium 7-19
Figure 7-6.2 . . . Atrial Septal Defects. 7-20
Figure 7-6.3 . . . Ventricular Septation 7-21
Figure 7-6.4 . . . Ductus Arteriosus 7-22
Figure 7-6.5A . . Truncus Arteriosus Septation. 7-23
Figure 7-6.5B . . Tetralogy of Fallot 7-24

Please visit us at www.Groupinsiders.com

© DeVry/Becker Educational Development Corp. All rights reserved.

Table of Contents

Anatomy Figures

Figure 7-6.5C . . Transposition of Great Vessels 7-25
Figure 7-6.5D . . Persistent Truncus Arteriosus 7-26
Figure 7-7.1 . . . Pericardium. 7-27
Figure 7-7.3A . . Anterior Surface of the Heart 7-28
Figure 7-7.3B . . External Heart: Anterior and Sulci 7-29
Figure 7-7.3C . . External Heart: Posterior and Sulci 7-30
Figure 7-7.4 . . . Surface Anatomy of the Heart 7-31
Figure 7-7.5A . . Interior Heart 7-32
Figure 7-7.5B . . Structures of Left and Right Ventricles 7-33
Figure 7-7.6 . . . Heart Sounds 7-34
Figure 7-7.7A . . Coronary Arteries 7-35
Figure 7-7.7B . . Cardiac Veins 7-37
Figure 7-7.8 . . . Conducting System 7-38
Figure 7-8.1 . . . Mediastinum 7-39
Figure 7-8.2 . . . Superior Mediastinum. 7-39
Figure 7-8.3 . . . Posterior Mediastinum 7-41
Figure 7-8.4 . . . Diaphragm 7-42
Figure 7-9.0A . . Anterior Chest 7-44
Figure 7-9.0B . . Lateral Chest. 7-44
Figure 7-9.0C . . Orientation of Cross Sectional Imaging. 7-45
Figure 7-9.0D . . Thorax CT. 7-45
Figure 7-9.0E . . Thorax CT. 7-46
Figure 7-9.0F . . Thorax CT. 7-46
Figure 7-9.0G . . Thorax CT. 7-47
Figure 7-9.0H . . Thorax CT. 7-47
Figure 7-9.0I. . . Thorax CT. 7-48

Chapter 8 Abdomen

Figure 8-1.0A . . Regions of the Abdomen. 8-1
Figure 8-1.0B . . Pelvic Bone 8-2
Figure 8-2.0 . . . Inguinal Canal. 8-3
Figure 8-3.0 . . . Inguinal Canal. 8-5
Figure 8-4.1 . . . Indirect Inguinal Hernia 8-8

Please visit us at www.Groupinsiders.com

© DeVry/Becker Educational Development Corp. All rights reserved.

Table of Contents

Anatomy Figures

Figure 8-4.2 . . . Direct Inguinal Hernia 8-9
Figure 8-4.3 . . . Femoral Hernia 8-10
Figure 8-5.0A . . Descent of Testis 8-11
Figure 8-5.0B . . Hydrocele 8-12
Figure 8-6.0 . . . Body Foldings 8-14
Figure 8-6.1 . . . Peritoneum 8-15
Figure 8-6.2A . . Foregut Development 8-16
Figure 8-6.2B . . Foregut Development (Detail) 8-17
Figure 8-6.2C . . Greater and Lesser Omenta 8-18
Figure 8-6.2D . . Cross Section of the Abdomen 8-19
Figure 8-7.2A . . Development of the Pancreas 8-20
Figure 8-7.2B . . Annular Pancreas 8-21
Figure 8-10.1 . . Stomach (Detail) 8-26
Figure 8-10.2 . . Liver—Visceral Surface 8-27
Figure 8-10.3 . . Bile Drainage 8-28
Figure 8-10.4 . . Pancreas 8-29
Figure 8-10.10 . . Anal Canal 8-31
Figure 8-11.1 . . Aorta 8-32
Figure 8-11.2A . . Celiac Trunk 8-33
Figure 8-11.2B . . Superior and Inferior Mesenteric Arteries 8-35
Figure 8-12.1 . . Inferior Vena Cava 8-37
Figure 8-12.2 . . Portal Venous System 8-38
Figure 8-12.3 . . Portal-Caval Anastomoses 8-39
Figure 8-13.1A . . Renal Development 8-40
Figure 8-13.1B . . Metanephric Kidney 8-41
Figure 8-13.2A . . Development of Hindgut and Urinary Bladder 8-42
Figure 8-13.2B . . Urachal Cyst 8-43
Figure 8-13.2C . . Imperforate Anus 8-44
Figure 8-14.1 . . Kidneys and Ureter 8-45
Figure 8-15.0A . . Upper and Lower GI 8-47
Figure 8-15.0B . . Abdomen CT 8-48
Figure 8-15.0C . . Abdomen CT 8-48
Figure 8-15.0D . . Abdomen CT 8-49

Please visit us at www.Groupinsiders.com

© DeVry/Becker Educational Development Corp. All rights reserved.

Table of Contents

Anatomy Figures

Figure 8-15.0E . . Abdomen CT 8-49
Figure 8-15.0F . . Abdomen CT 8-50

Chapter 9 Pelvis and Perineum

Figure 9-1.1A . . Pelvic and Urogenital Diaphragms 9-1
Figure 9-1.1B . . Puborectalis Muscle 9-2
Figure 9-1.2 . . . Urogenital Diaphragm 9-3
Figure 9-1.3A . . Male Pelvis 9-4
Figure 9-1.3B . . Female Pelvis 9-5
Figure 9-2.0A . . Boundaries of the Perineum 9-6
Figure 9-2.0B . . Course of Pudendal Nerve and Vessels 9-7
Figure 9-2.2A . . Spaces and Structures of the Perineum 9-8
Figure 9-2.2B . . Extravasation of Urine 9-9

Chapter 10 Upper Limb

Figure 10-3.0 . . Brachial Plexus 10-2
Figure 10-4.0 . . Sensory Innervation of the Hand 10-4
Figure 10-6.0 . . Blood Supply of Upper Limb 10-11
Figure 10-7.0 . . Shoulder and Rotator Cuff. 10-13
Figure 10-8.0A. . Carpal Tunnel and Ventral Side of Wrist 10-14
Figure 10-8.0B. . Carpal Tunnel: Detailed View. 10-14
Figure 10-9.0A. . Shoulder and Elbow 10-15
Figure 10-9.0B. . Wrist and Hand 10-16

Chapter 11 Lower Limb

Figure 11-2.0 . . Lumbosacral Plexus 11-1
Figure 11-4.0 . . Sensory Innervation of Foot 11-3
Figure 11-6.0 . . Blood Supply to Lower Limb 11-6
Figure 11-6.1 . . Blood Supply to Hip 11-7
Figure 11-6.2 . . Blood Supply to Lower Limb 11-8
Figure 11-7.0 . . Knee Joint. 11-10
Figure 11-7.1A. . Collateral Ligaments. 11-11
Figure 11-7.1B. . Cruciate Ligaments 11-12

Please visit us at www.Groupinsiders.com

© DeVry/Becker Educational Development Corp. All rights reserved.

Table of Contents

Anatomy Figures

Chapter 12 Head and Neck

Figure 12-1.1A. . Pharyngeal Apparatus: Frontal Section of Pharynx 12-1
Figure 12-1.1B. . Pharyngeal Apparatus 12-1
Figure 12-1.1C. . Frontal Section of Pharynx 12-3
Figure 12-1.2 . . Pharyngeal Apparatus 12-4
Figure 12-1.3 . . Tongue Development 12-6
Figure 12-1.4A. . Development of Face 12-7
Figure 12-1.4B. . Development of Hard Palate 12-8
Figure 12-2.1 . . Blood Supply to Head and Neck 12-9
Figure 12-3.0A. . Cranial Cavity 12-10
Figure 12-3.0B. . Base of Skull 12-11
Figure 12-4.0 . . Frontal Section of Cranial Cavity 12-12
Figure 12-5.0 . . Dural Venous Sinuses 12-14
Figure 12-5.1 . . Cavernous Sinus 12-15

Unit 3 Neuroscience

Chapter 13 Introduction and Embryology of the Nervous System

Figure 13–2.1A . Nervous System Development 13-4
Figure 13–2.1B . Brain Vesicles and Adult Derivatives 13-5
Figure 13–2.2 . . Spina Bifida 13-7
Figure 13–3.1 . . Sympathetic Pathways 13-8

Chapter 14 Neurohistology

Figure 14–1.2 . . Classification of Neurons 14-2
Figure 14–1.3 . . Multipolar Neuron 14-3
Figure 14–2.0 . . Axon Transport 14-5
Figure 14–3.1 . . Neuron Regeneration 14-7

Chapter 15 Meninges and Circulation of Cerebrospinal Fluid

Figure 15-1.0 . . Dural Venous Sinuses 15-1
Figure 15-1.1 . . Cranial Meninges 15-2
Figure 15–3.0A . Ventricles of CNS 15-4
Figure 15–3.0B . Circulation of Cerebrospinal Fluid 15-5

Please visit us at www.Groupinsiders.com

© DeVry/Becker Educational Development Corp. All rights reserved.

Table of Contents

Anatomy Figures

Chapter 16 Spinal Cord

Figure 16–2.0 . . Spinal Nerve Distribution 16-2
Figure 16–3.0A . Organization of the Spinal Cord 16-4
Figure 16–3.0B . Spinal Cord Cross Section 16-4
Figure 16–3.2A . Organization of Gray Matter 16-5
Figure 16–3.2B . Topographic Organization of Ventral Horn 16-6
Figure 16–5.0 . . Organization of Descending Long Tract 16-8
Figure 16–5.1A . Corticospinal Tract 16-9
Figure 16–5.1B . Corticospinal Tract with Cross Sections 16-10
Figure 16–5.1C . Motor Systems of Spinal Cord 16-11
Figure 16–6.1A . Deep Muscle Stretch (Monosynaptic) Reflex 16-12
Figure 16–6.1B . Upper and Lower Motor Neuron Lesions 16-13
Figure 16–6.1C . Muscle Stretch Reflex 16-14
Figure 16–6.3A . Inverse Myostatic Reflex 16-15
Figure 16–6.3B . Contralateral vs. Ipsilateral Lesions 16-16
Figure 16–7.0 . . Typical Sensory Pathway 16-17
Figure 16–7.1A . Dorsal Column/Medial Lemniscus Pathway 16-18
Figure 16–7.1B . Dorsal Column/Medial Lemniscus Pathway With Cross Sections 16-19
Figure 16–7.1C . Dorsal Columns in Spinal Cord Cross Section 16-19
Figure 16–7.2A . Spinothalamic Tract (Anterolateral System) 16-22
Figure 16–7.2B . Spinothalamic (Anterolateral) Tract With Cross Sections 16-23
Figure 16–7.2C . Spinothalamic Tract in Spinal Cord Cross Section 16-23
Figure 16–7.2D . Comparison of Epicritic and Protopathic Pathways 16-25
Figure 16–7.3 . . Spinocerebellar Tracts 16-26
Figure 16–8.0A . Regional Sections of the Spinal Cord 16-27
Figure 16–8.0B . Lesions of the Spinal Cord 16-28
Figure 16–8.1 . . Poliomyelitis 16-28
Figure 16–8.2 . . Amyotrophic Lateral Sclerosis (ALS) 16-29
Figure 16–8.3 . . Tabes Dorsalis 16-29
Figure 16–8.4 . . Anterior Spinal Artery (ASA) Occlusion 16-30
Figure 16–8.5 . . Subacute Combined Degeneration 16-30
Figure 16–8.6A . Syringomyelia 16-31

Please visit us at www.Groupinsiders.com

© DeVry/Becker Educational Development Corp. All rights reserved.

Table of Contents

Anatomy Figures

Figure 16–8.6B . Syringomyelia: Areas of Effect. 16-31
Figure 16–8.7A . Brown-Séquard Syndrome 16-32
Figure 16–8.7B . Brown-Séquard Syndrome: Areas of Effect 16-32

Chapter 17 Brainstem

Figure 17–2.0A . Ventral Surface of Brainstem. 17-2
Figure 17–2.0B . Dorsal Surface of Brainstem 17-3
Figure 17–2.0C . Cranial Nerves. 17-3
Figure 17–2.0D . Attachment of Cranial Nerves to Brainstem. 17-4
Figure 17–3.0A . Ocular Muscles 17-6
Figure 17–3.0B . Movement of Eye Muscles. 17-6
Figure 17–3.0C . External and Internal Strabismus. 17-6
Figure 17–3.1A . Upper Medulla 17-9
Figure 17–3.1B . Lower Pons 17-10
Figure 17–3.1C . Mid Pons. 17-11
Figure 17–3.1D . Midbrain 17-12
Figure 17–3.1E . Trigeminal Nucleus. 17-13
Figure 17–3.1F . Lower Medulla 17-14
Figure 17–3.1G . Upper Medulla 17-15
Figure 17–3.1H . Lower Pons 17-16
Figure 17–3.1I . Mid-Upper Pons 17-17
Figure 17–3.1J . Midbrain 17-18
Figure 17–4.0 . . Long Tracts in Brainstem 17-19
Figure 17–8.0 . . Corticobulbar Tract. 17-27
Figure 17–8.1A . Corticobulbar Innervation of CN VII 17-28
Figure 17–8.1B . Supranuclear Lesion. 17-29
Figure 17–8.1C . Nuclear Lesion. 17-29
Figure 17–8.1D . Peripheral Lesion 17-29
Figure 17–9.1A . Organization of the Ear. 17-30
Figure 17–9.1B . Inner Ear 17-31
Figure 17–9.1C . Organization of Cochlea 17-32
Figure 17–9.1D . Auditory Pathways 17-34
Figure 17–9.2 . . Vestibular Pathway. 17-37

Please visit us at www.Groupinsiders.com

© DeVry/Becker Educational Development Corp. All rights reserved.

Table of Contents

Anatomy Figures

Figure 17–10.0A Voluntary Horizontal Gaze Circuit 17-40
Figure 17–10.0B Abnormal Horizontal Gaze 17-41
Figure 17–11.0 . Blood Supply to Brainstem 17-42
Figure 17–11.3 . Model of Brainstem Lesions 17-43
Figure 17–12.1A Medial Medullary Syndrome (ASA) 17-44
Figure 17–12.1B Lateral Medullary Syndrome (PICA) 17-45
Figure 17–12.2A Medial Pontine Syndrome (Paramedian) 17-46
Figure 17–12.2B Lateral Pontine Syndrome (Lower) (AICA) 17-47
Figure 17–12.2C Lateral Pontine Syndrome (Mid Pons) (Superior Cerebellar) . . 17-48
Figure 17–12.3 . Medial Midbrain Syndrome (Weber) (PCA) 17-49

Chapter 18 Cerebellum
Figure 18–2.0 . . Cerebellar Organization 18-2
Figure 18–4.1 . . Cerebellar Cytology 18-6
Figure 18–4.2 . . Projection of Purkinje Axons 18-7
Figure 18–5.1 . . Cerebellar Efferents 18-9
Figure 18–6.2 . . Topographic Organization of Cerebellum 18-10

Chapter 19 Basal Ganglia
Figure 19–1.0A . Basal Ganglia and Internal Capsule 19-2
Figure 19–1.0B . Axial Section 19-2
Figure 19–1.0C . Coronal Section at Level of Mammillary Bodies 19-3
Figure 19–1.3 . . Basal Ganglia—Frontal Section 19-3
Figure 19–3.1 . . Direct and Indirect Pathways 19-5
Figure 19–3.2 . . Basal Ganglia Pathways 19-6

Chapter 20 The Visual System
Figure 20–2.0 . . Structure of Eyeball 20-1
Figure 20–3.0 . . Pupillary Light Reflex 20-3
Figure 20–5.0 . . Histology of the Retina 20-5
Figure 20–6.0 . . Visual Pathways 20-6

Please visit us at www.Groupinsiders.com

© DeVry/Becker Educational Development Corp. All rights reserved.

Table of Contents

Anatomy Figures

Chapter 21 Diencephalon

Figure 21–1.0 . . Diencephalon 21-1
Figure 21–1.1 . . Thalamus 21-1
Figure 21–1.3A . Hypothalamus 21-3
Figure 21–1.3B . Development of Pituitary Gland 21-3

Chapter 22 Cerebral Cortex

Figure 22–2.1 . . Lateral View of Cortex 22-1
Figure 22–2.2 . . Medial View of Cortex. 22-2
Figure 22–3.0 . . Motor Homunculus. 22-3
Figure 22–4.0 . . Cortical Axons 22-4
Figure 22–5.0A . Blood Supply to Brain. 22-5
Figure 22–5.0B . Distribution of MCA 22-5
Figure 22–5.0C . Distribution of ACA and PCA 22-6
Figure 22–5.0D . Distribution of Cerebral Vessels 22-7
Figure 22–5.0E . Arteriogram of Internal Carotid Artery 22-7
Figure 22–6.0 . . Functional Areas of the Cortex. 22-8
Figure 22–7.3 . . Conduction Aphasia 22-12
Figure 22–8.3A . Disconnect Syndromes 22-13
Figure 22–8.3B . Disconnect Syndromes 22-14
Figure 22–9.0 . . Internal Capsule 22-16

Chapter 23 Limbic System

Figure 23–2.0 . . Limbic System. 23-2
Figure 23–4.0 . . CNS Structures of the Cortex 23-4

Please visit us at www.Groupinsiders.com

© DeVry/Becker Educational Development Corp. All rights reserved.

Table of Contents

Anatomy Tables

Unit 1 Early Human Development

Chapter 1 Early Human Development

Table 1-2.4 . . . . Development of External Genitalia 1-12

Chapter 4 Week 3: Gastrulation

Table 4-1.0 . . . . Germ Layer Derivatives 4-3

Unit 2 Gross Anatomy and Organogenesis

Chapter 6 Autonomic Nervous System

Table 6-2.1 . . . . Distribution of Sympathetic (Thoracolumbar) Nervous System . . 6-5

Table 6-2.2 . . . . Distribution of the Parasympathetic (Craniosacral) Nervous System 6-8

Chapter 7 Thorax

Table 7-3.1 . . . . Pleural Cavity Boundaries and Reference Points 7-8

Table 7-5.1A . . . Fate of Five Dilatations of the Primitive Heart Tube 7-14

Table 7-5.1B . . . Postnatal Remnant of Prenatal Vessels 7-16

Chapter 8 Abdomen

Table 8-6.0 . . . . Adult Structures Derived from Each of the Three Divisions of the Primitive Gut Tube 8-13

Table 8-6.1 . . . . Intraperitoneal and Retroperitoneal Viscera. 8-15

Table 8-9.7 . . . . Summary of Important Congenital Malformations of the Gastrointestinal System 8-25

Table 8-12.3 . . . Clinical Signs of Portal Hypertension 8-39

Chapter 9 Pelvis and Perineum

Table 9-2.2 . . . . Congenital Malformations of Pelvis and Perineum. 9-10

Chapter 10 Upper Limb

Table 10-3.0A . . Major Motor Innervations by the Five Terminal Nerves 10-3

Table 10-3.0B . . Additional Major Nerves of the Brachial Plexus 10-4

Table 10-5.9 . . . Lesions of the Brachial Plexus and Its Branches. 10-10

Please visit us at www.Groupinsiders.com

© DeVry/Becker Educational Development Corp. All rights reserved.

Table of Contents

Anatomy Tables

Chapter 11 Lower Limb

Table 11-2.0A . . Terminal Nerves of Lumbosacral Plexus 11-2
Table 11-2.0B . . Additional Major Nerves of Lumbosacral Plexus 11-2
Table 11-3.1 . . . Segmental Innervation to Lower Limb 11-3

Chapter 12 Head and Neck

Table 12-1.1A . . Structures Derived From Pharyngeal Components 12-2
Table 12-1.1B . . Adult Structures Derived From the Fetal Pharyngeal Pouches . . 12-3
Table 12-1.4 . . . Structures Contributing to Formation of the Face. 12-7

Unit 3 Neuroscience

Chapter 13 Introduction and Embryology of the Nervous System

Table 13-2.1A . . Secondary Brain Vesicle Derivatives 13-6
Table 13-2.1B . . Derivatives of Ectoderm Germ Layer 13-6
Table 13-2.2 . . . Congenital Defects of the Nervous System 13-7

Chapter 14 Neurohistology

Table 14-1.1 . . . Major Demyelinating Diseases of the Nervous System 14-2
Table 14-2.0 . . . Nervous System Tumors in Adults and Children. 14-6

Chapter 15 Meninges and Circulation of Cerebrospinal Fluid

Table 15-3.0 . . . Major Types of Hydrocephalus 15-6

Chapter 16 Spinal Cord

Table 16-6.1 . . . Common Tested Reflexes 16-12
Table 16-6.3 . . . Comparison of Upper and Lower Motor Neuron Lesions 16-16

Chapter 17 Brainstem

Table 17-3.0 . . . Cranial Nerves. 17-25
Table 17-10.0 . . Clinical Correlate 17-41

Chapter 18 Cerebellum

Table 18-2.0 . . . Cerebellar Organization 18-3
Table 18-3.0 . . . Cerebellar Afferents 18-4
Table 18-3.1 . . . Cerebellar Cortex Neurons 18-5

Please visit us at www.Groupinsiders.com

© DeVry/Becker Educational Development Corp. All rights reserved.

Table of Contents

Anatomy Tables

Chapter 19 Basal Ganglia

Table 19-6.0 . . . Major Movement Disorders Stemming From Basal Ganglia Lesions 19-8

Chapter 20 The Visual System

Table 20-4.0 . . . Vision Abnormalities 20-4

Chapter 21 Diencephalon 21-1

Table 21-1.1 . . . The Various Thalamic Nuclei, Their Nervous Connections, and Their Functions 21-2

Table 21-1.3 . . . Functions of the Main Hypothalamic Nuclei 21-4

Chapter 22 Cerebral Cortex

Table 22-8.3 . . . Cortical Functions and Lesion Abnormalities 22-15

Table 22-9.0 . . . Internal Capsule: Arterial Supply 22-16

Please visit us at www.Groupinsiders.com

© DeVry/Becker Educational Development Corp. All rights reserved.

Please visit us at www.Groupinsiders.com

Unit 1

Early Human Development

Please visit us at www.Groupinsiders.com

Please visit us at www.Groupinsiders.com

1 Gametogenesis

Gametogenesis is the process whereby male and female gametes (sperm and ovum, respectively) are formed from *primordial germ cells*. In the fourth week of development, *primordial germ cells* develop in the cells lining the wall of the *yolk sac* and subsequently migrate from the yolk sac through the dorsal body wall to populate the indifferent gonad (discussed later). The primordial germ cells go through a specialized type of cell division called *meiosis*.

1.1 Meiosis

Meiosis is the special type of cell division of primordial germ cells that occurs within the testis (*spermatogenesis*) and ovary (*oogenesis*) to produce the male and female gametes. Meiosis is divided into two sequential divisions, *meiosis I and meiosis II*, that result in the development of *haploid gametes* containing half the number of chromosomes and half the DNA (23,1n) of what is found in typical somatic diploid cells (46,2n). The diploid number is restored in the zygote by the fusion of two male and female gametes at fertilization.

1.2 General Overview of Gametogenesis and Meiosis

- *Primordial germ cells* originate in the wall of the yolk sac during the fourth week. During the fourth week, the germ cells migrate along the dorsal mesentery of the gut tube and populate the indifferent gonads during the fifth and sixth weeks (discussed later).
- After arriving in the gonad and at different times for male and female, the primordial germ cells differentiate into *spermatogonia* or *oogonia* which enter meiosis I to become *primary spermatocytes* or *primary oocytes*.
- At the beginning of meiosis I, the primary spermatocytes and oocytes replicate their DNA.
- Meiosis I—Major events include:
  - Synapsis (pairing of maternal and paternal homologous chromosomes)
  - Chromosomal crossover (segmental exchange of DNA)
  - Alignment (of 46 homologous duplicated chromosomes)
  - Disjunction (separation of the chromosomes *without* splitting of the centromeres)
  - Cell division (23,2n)

USMLE® Key Concepts

For Step 1, you must be able to:

- Explain gametogenesis and meiosis and the formation of male and female gametes.
- Identify the sequence of events involved in the development of male and female genital systems.
- Describe the development of external genitalia.

Please visit us at www.Groupinsiders.com

© DeVry/Becker Educational Development Corp. All rights reserved.

- Meiosis II—Follows meiosis I without an intervening interphase. Major events include:
  - No synapsis or crossover events
  - Alignment
  - Disjunction (separation of the chromosomes *with* centromere splitting (23,1n)
  - Cell division

1.2.1 Male Gametogenesis: Spermatogenesis

The sequence of major events in spermatogenesis includes:

1. In the male, primordial germ cells (46,2n) migrate during the fourth to fifth weeks from the yolk sac and populate the sex cords of the indifferent gonad. Upon arrival in the indifferent gonad, the primordial cells go *dormant and will remain dormant* at birth and until puberty.
2. Spermatogenesis and meiosis I *begin at puberty* when the primordial cells differentiate into type A and B spermatogonia within the seminiferous tubules of the testis. Type A cells undergo mitosis to continuously produce type B cells for the life of the male.
3. The B spermatogonia undergo DNA replication and enter meiosis I to form primary spermatocytes (46,4n).
4. The primary spermatocytes will complete meiosis I, form secondary spermatocytes (23,2n) and enter meiosis II.
5. After finishing meiosis II the secondary spermatocytes form haploid spermatids (23,1n).
6. Spermatids undergo morphological changes to develop into mature spermatozoa (the process is called spermiogenesis).
7. Spermatogenesis begins at puberty and is continuous for life.

Please visit us at www.Groupinsiders.com

© DeVry/Becker Educational Development Corp. All rights reserved.

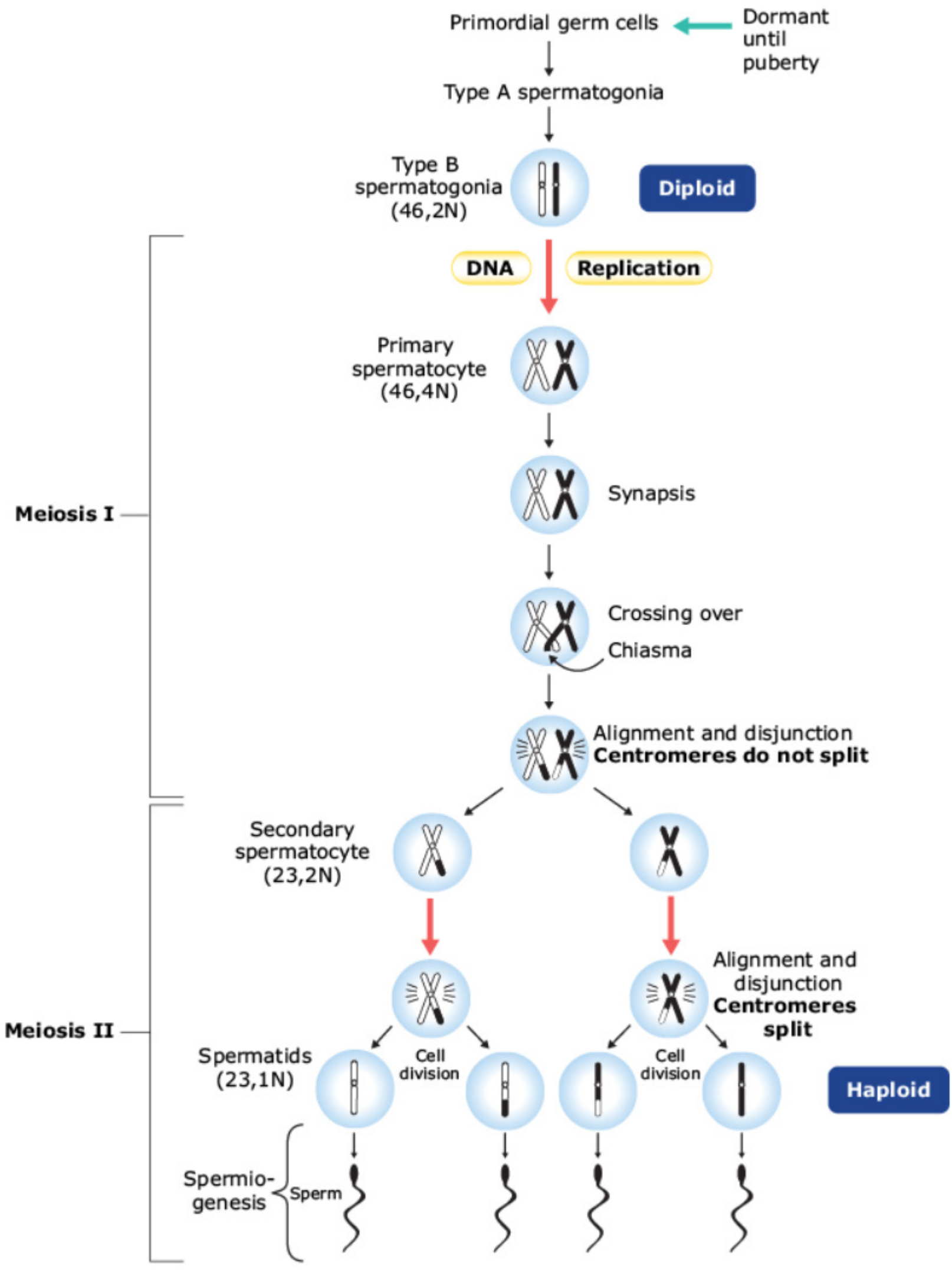

▲ **Figure 1–1.2A** Spermatogenesis

Please visit us at www.Groupinsiders.com

© DeVry/Becker Educational Development Corp. All rights reserved.

1.2.2 Female Gametogenesis: Oogenesis

The sequence of major events in oogenesis includes:

1. After the primordial cells migrate from the yolk sac into the fetal ovary during the fourth and fifth weeks of development, they differentiate into oogonia (46,2n). The oogonia go through rapid mitotic cell divisions within the ovary.
2. In the female, gametogenesis and meiosis I begin much earlier than in the male. Gametogenesis begins in the fetal ovary during the *fourth and fifth months of development*, although complete oocyte maturation will not be completed until puberty.
3. By the *fifth month*, all of the oogonia undergo DNA replication, enter meiosis I and form primary oocytes (46,4n) in the primordial follicles of the fetal ovary. The number of primary oocytes and follicles is estimated to be about 7 million by the fifth month.
4. During the *fifth month* of fetal life, all of the primary oocytes will *arrest the first time in prophase of meiosis I*.
5. The primary oocytes remain arrested in meiosis I at birth and until puberty.
6. At puberty when the female begins her monthly cycle, one of the primary oocytes will unarrest and complete meiosis I to form a secondary oocyte (23,2n) and the first polar body, which degenerates. The secondary oocyte develops within the *graafian follicle* in each monthly cycle.
7. About three hours before ovulation, the secondary oocyte will *arrest the second time in metaphase of meiosis II*. This is the cell of ovulation.
8. Only if the oocyte is fertilized will the secondary oocyte become unarrested and complete meiosis II to form an ovum (23,1n) and another polar body. If there is no fertilization, the secondary oocyte degenerates.

Please visit us at www.Groupinsiders.com

© DeVry/Becker Educational Development Corp. All rights reserved.

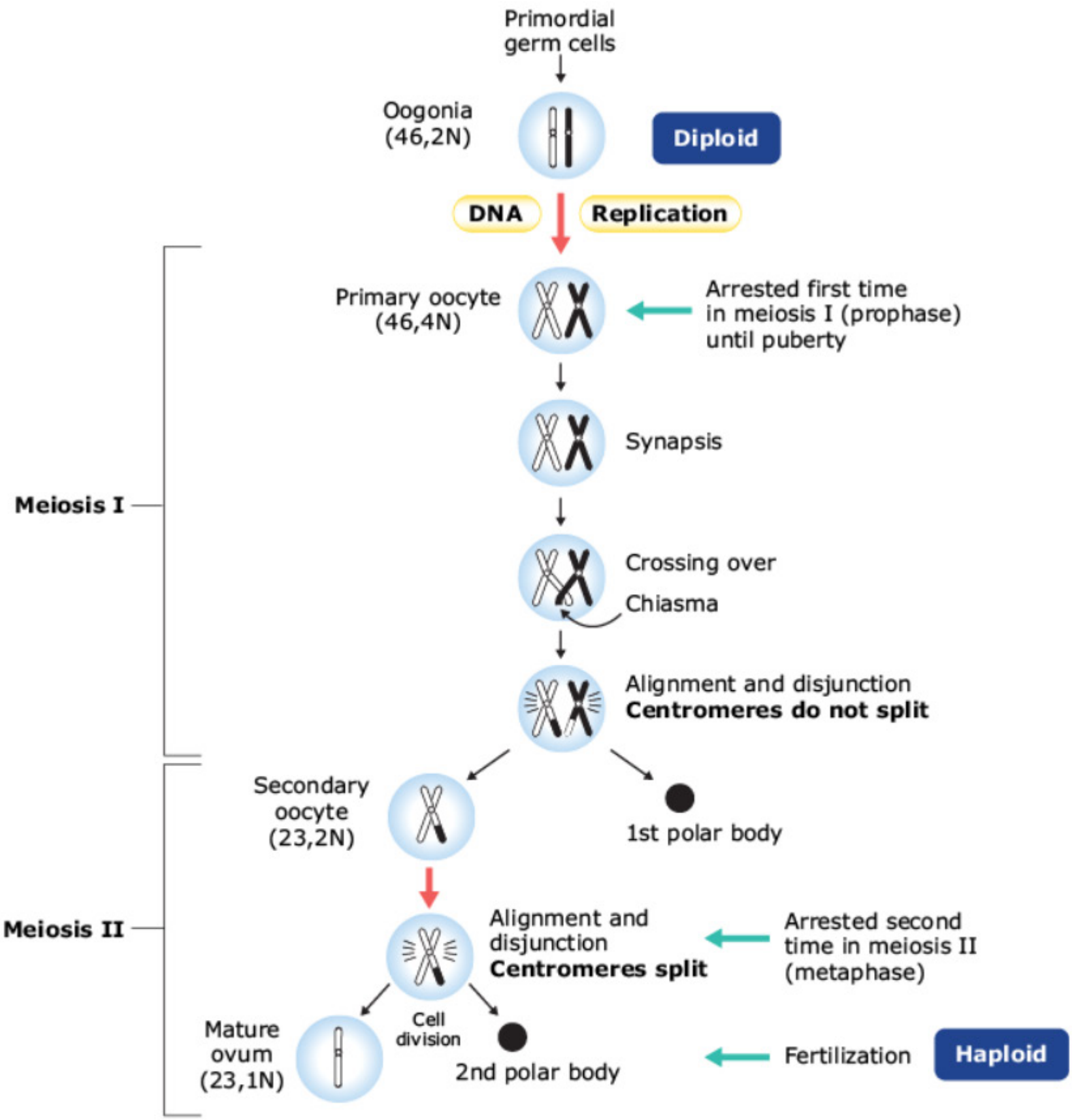

▲ **Figure 1–1.2B** Oogenesis

Please visit us at www.Groupinsiders.com

© DeVry/Becker Educational Development Corp. All rights reserved.

Clinical Application

Because all of the primary oocytes are formed by the fifth month of fetal life, a number of the primary oocytes will remain dormant until later in the reproductive life of the female. These oocytes can be in the first arrested stage for up to 40 years. This delayed maturation of the primary oocyte can account for the increase incidence of birth defects in older women (trisomy 21, Down syndrome).

1.2.3 Comparisons of Male and Female Gametogenesis

Male:

- Produces four gametes.
- Meiosis I begins at puberty.
- Continuous for life after puberty.

Female:

- Produces one gamete with polar bodies.
- Meiosis I begins in the fifth month of development.
- Has two arrested phases, then menopause.

Please visit us at www.Groupinsiders.com

© DeVry/Becker Educational Development Corp. All rights reserved.

2 Genital System Development

2.1 Timeline for Genital System Development

- **Week 3:** *Intermediate mesoderm* forms during gastrulation.
- **Week 4:** The intermediate mesoderm begins to form bilateral, longitudinal elevations on the posterior wall of the abdominal cavity called the *urogenital ridge*.
- **Week 4:** The *indifferent gonad* appears on the medial aspects of the urogenital ridge.
- **Week 5:** Surface mesothelium of the indifferent gonad penetrates into the gonad to form *primary sex cords*.
- **Weeks 4–6:** *Primordial germ cells* migrate from the yolk sac through the connecting stalk to the posterior abdominal wall and populate in the primary sex cords of the indifferent gonad.
- **Weeks 7–8:** The indifferent gonads begin to differentiate into either testis or ovary.
- **Weeks 9–12:** External genitalia of male and female become distinct.

2.2 Indifferent Gonads

Genital system development begins with the formation of paired longitudinal ridges of *intermediate mesoderm* on the dorsal wall of the embryo called the *urogenital ridge*. Between the fourth and the seventh weeks, the gonads are sexually indifferent (indifferent gonad) and one cannot distinguish between the male and female gonads, although the sex of the male (XY) and female (XX) is determined at conception. The indifferent gonads begin to develop on the medial aspect the urogenital ridge during the fourth week.

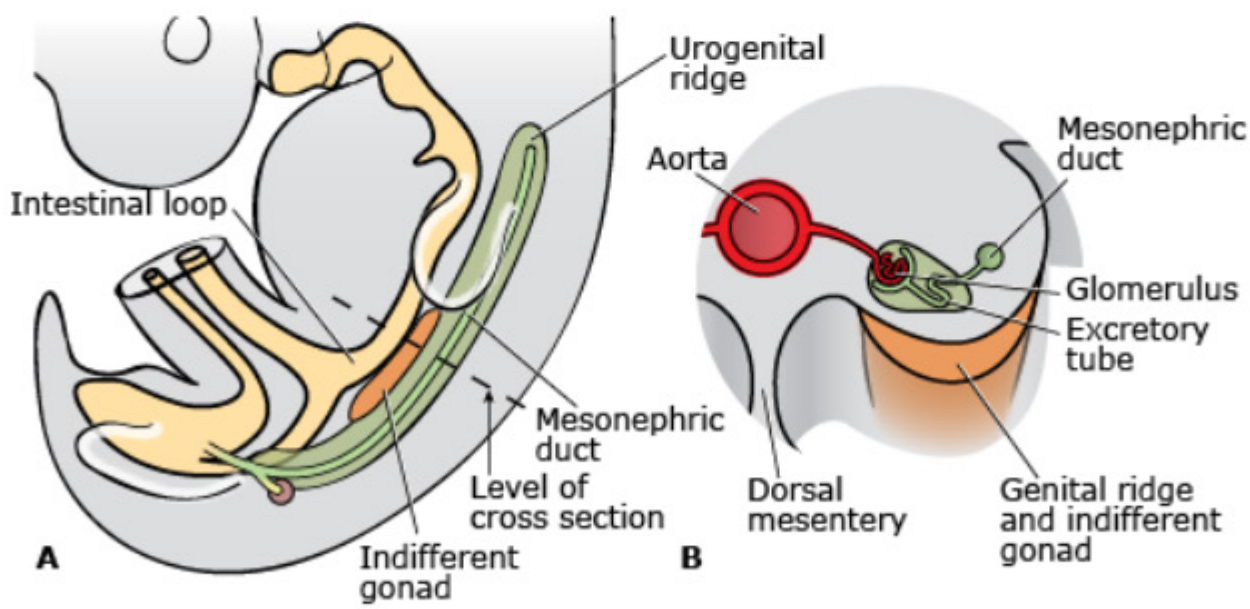

▲ **Figure 1–2.2A** Urogenital Ridge and Indifferent Gonads

Please visit us at www.Groupinsiders.com

© DeVry/Becker Educational Development Corp. All rights reserved.

Components of the indifferent gonad include:

- *Primordial germ cells* originate from the lining cells of the yolk sac and develop into the male sperm and the female ovum. During the fourth week of development, these germ cells migrate from the yolk sac through the dorsal mesentery of the gut tube, populate, and are incorporated into the primary sex cords of the indifferent gonad during the fifth and sixth weeks.

  Note: The primordial germ cells have critical inductive influences on the gonads and, without the presence of these cells, the gonads do not develop.
- *Primary sex cords* originate from the epithelium covering the surface of the gonads and grow into underlying gonad to form finger-like extensions. The primordial germ cells populate and invade the sex cords by the fifth and sixth weeks.

Important Concept

Major components of indifferent gonad:

- Primordial germ cells
- Sex cords
- Two ducts: paramesonephric and mesonephric

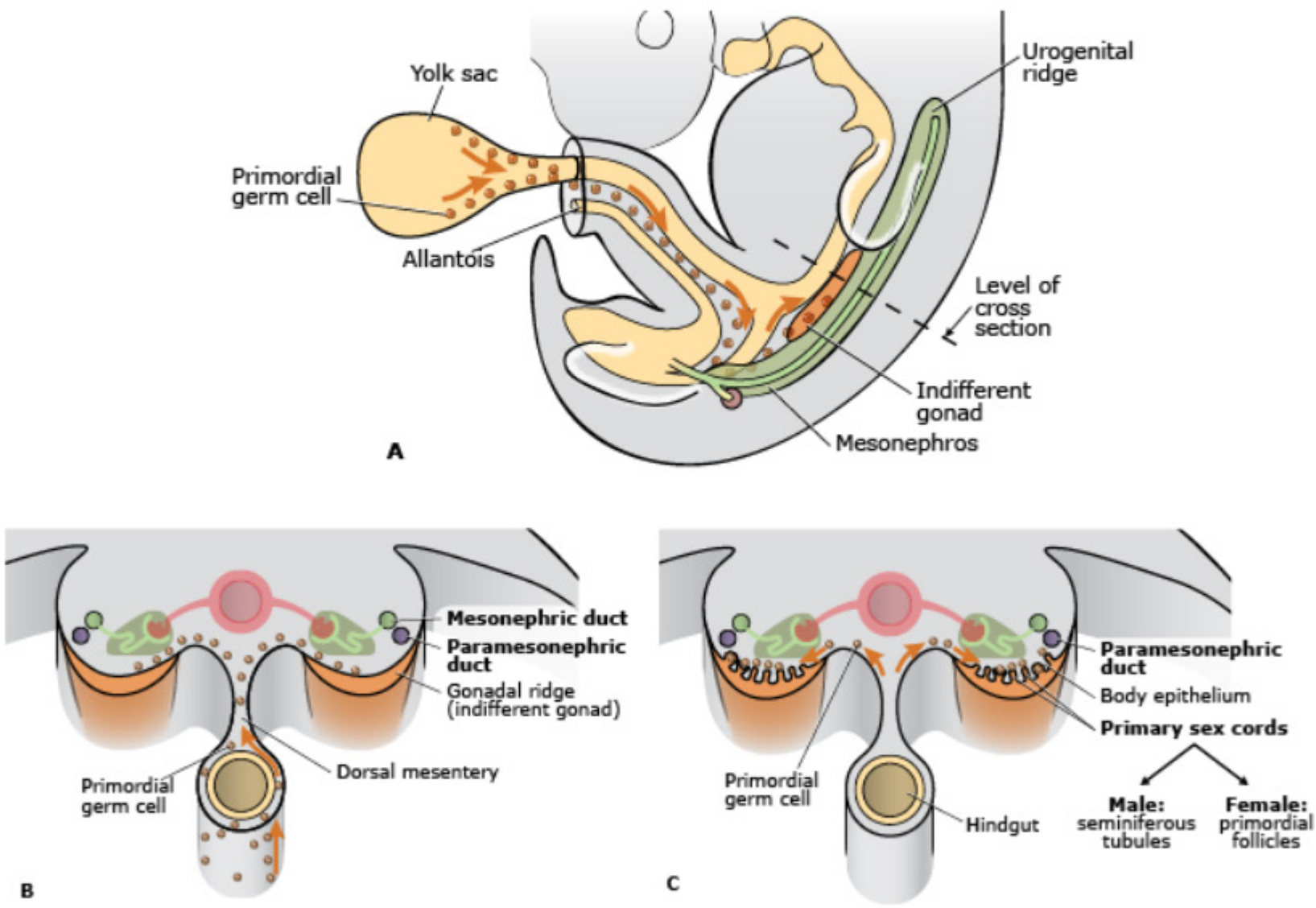

▲ **Figure 1–2.2B** Migration of Primordial Germ Cells

Please visit us at www.Groupinsiders.com

© DeVry/Becker Educational Development Corp. All rights reserved.

- Genital ducts develop within the indifferent gonad of the male and female. There is one pair of genital ducts.
  1. The *mesonephric ducts (wolffian)* play an important role in the development of the male genital tract. Testosterone influences the mesonephric duct to develop into the male genital tract: epididymis, ductus deferens, seminal vesicles, and ejaculatory duct.
  2. The *paramesonephric ducts (müllerian)* play a critical role in the development of the female genital tract. Under the influence of estrogen, the müllerian ducts form the female genital tract: oviduct, uterus, and upper vagina.

2.3 Development of Testis and Ovary

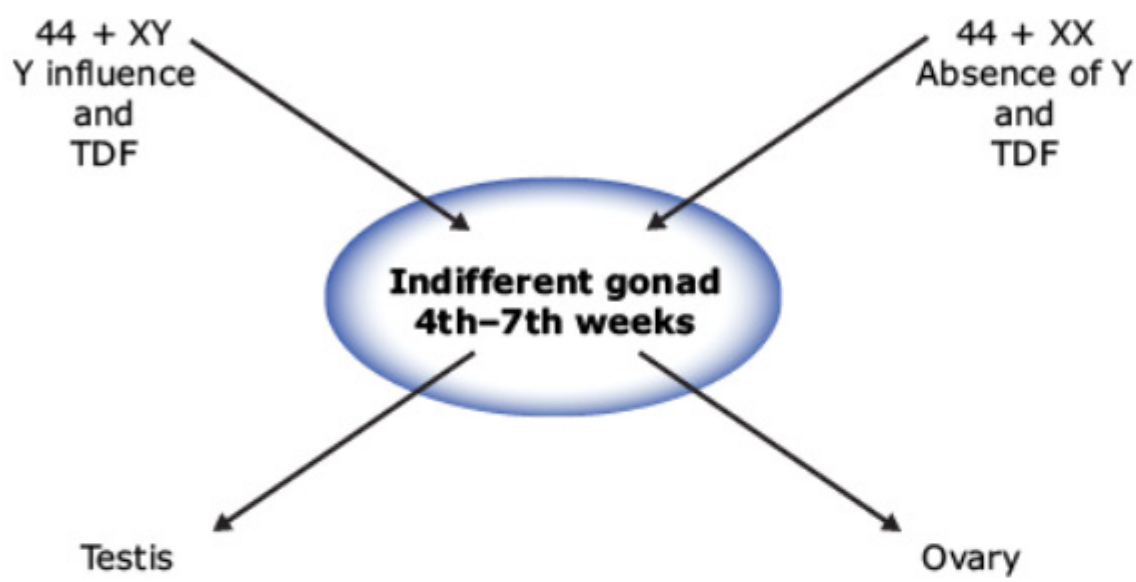

▲ **Figure 1–2.3A** Indifferent Gonad

In the seventh week of development, the indifferent gonad begins to differentiate into either a testis or ovary. The presence of a Y chromosome directs male gonadal development into a testis. In the absence of the Y chromosome, the indifferent gonad develops into an ovary.

Please visit us at www.Groupinsiders.com

© DeVry/Becker Educational Development Corp. All rights reserved.

2.3.1 Testis

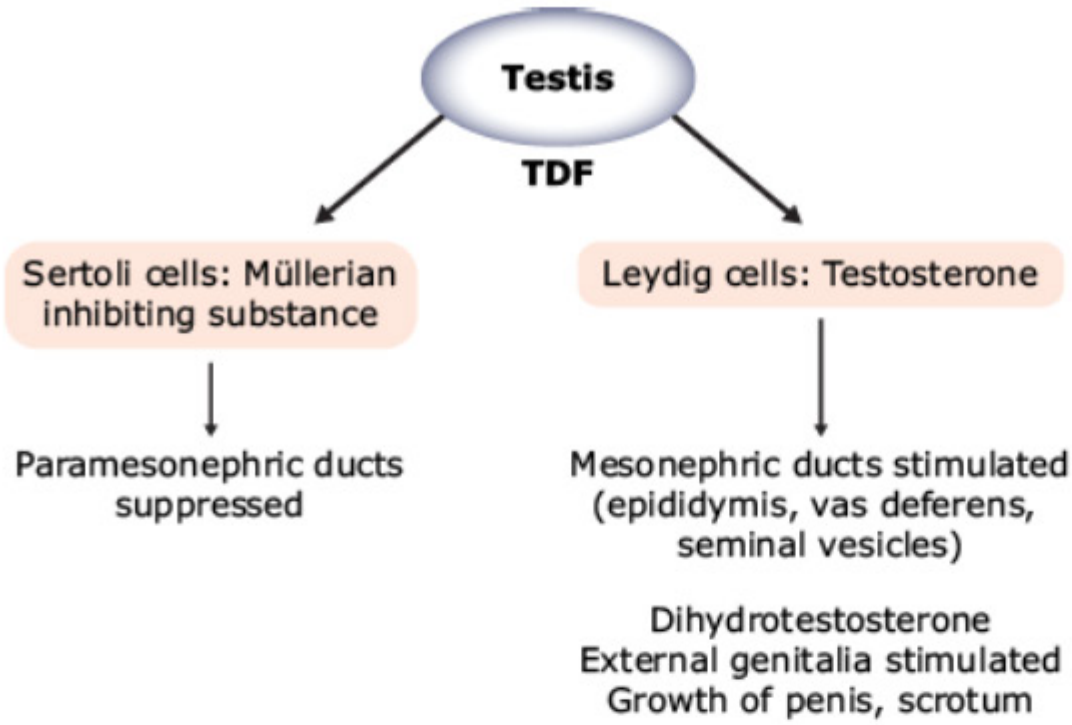

▲ **Figure 1–2.3B** Male Genital Development

In embryos with a Y chromosome, the indifferent gonad develops into a testis. There is a critical, coordinated sequence of events required to develop a testis:

1. On the short arm of the Y chromosome, the *Sry gene* encodes for *testis-determining factor (TDF)*. TDF is the trigger that initiates and directs the development of a testis from the indifferent gonad.
2. *Leydig cells* are formed early and produce *testosterone* by the eighth week. The androgens secreted by the Leydig cells induce the development of the male genital tract from the wolffian duct system (mesonephric duct).
3. In the presence of testosterone, the sex cords eventually elongate, become tubular, and develop into *seminiferous tubules* at puberty. The sex cords are populated by the primordial germ cells. Note that the primordial cells in the sex cords do not begin meiosis I until puberty.
4. *Sertoli cells* produce *müllerian-inhibiting factor (MIF)*, which results in the degeneration of the müllerian duct system (paramesonephric duct). MIF prevents the development of parts of the female genital tract in the male.
5. Some of the testosterone is converted to *dihydrotestosterone (DHT)* by the enzyme 5α-reductase, which is responsible for development of external genitalia in the male.

Please visit us at www.Groupinsiders.com

© DeVry/Becker Educational Development Corp. All rights reserved.

2.3.2 Ovary

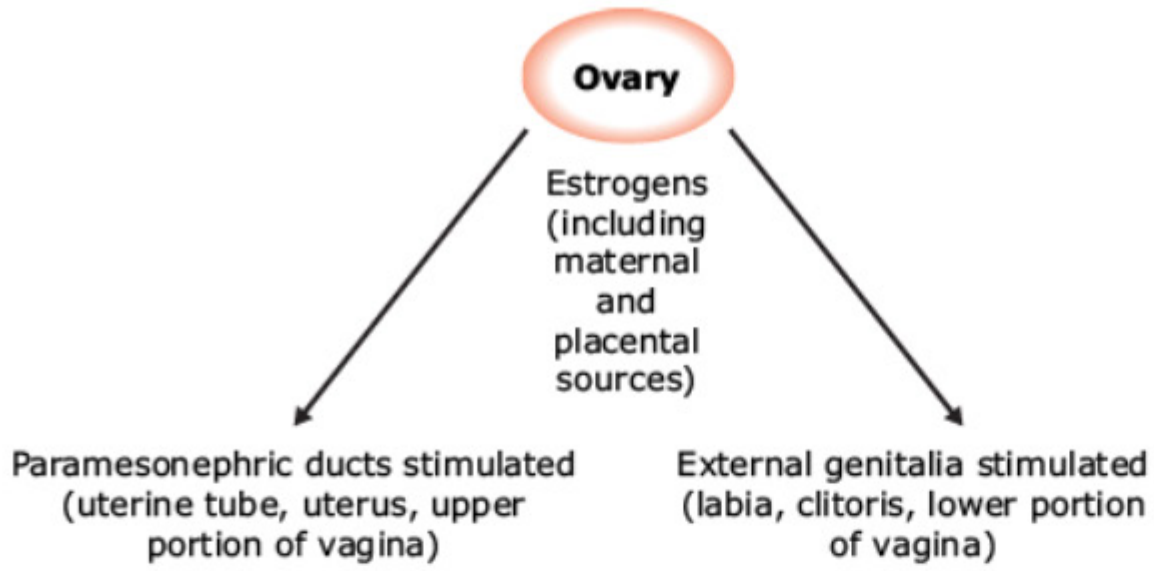

▲ **Figure 1–2.3C** Female Genital Development

In female embryos (XX) with no Y chromosome and in the absence of TDF, MIF and testosterone, the ovary develops from the indifferent gonad with no major factors involved.

- The primary sex cords are replaced by a second generation of cords that will break up and form *primordial follicles* that house the primary oocytes.
- In the female, all the oocytes will enter meiosis I and arrest the first time by the fifth month of development.
- Paramesonephric (müllerian) ducts under the influence of estrogen form the uterine tubes, uterus, and upper third of the vagina.
- The mesonephric ducts degenerate in the female after their role in the development of the final kidney.

Please visit us at www.Groupinsiders.com

© DeVry/Becker Educational Development Corp. All rights reserved.

2.4 External Genitalia

The formation of external genitalia also undergoes an *indifferent stage* of development. From the fourth to the seventh weeks, the external genitalia are undifferentiated between the two sexes. The male and female genitalia are not fully distinguishable until the twelfth week.

During the fourth week, *mesoderm* condenses to form three major components of the indifferent genitalia: *genital tubercle*, *genital (labioscrotal) swellings*, and *urethral folds*. The development of the external genitalia is outlined in Table 1–2.4.

▼ **Table 1–2.4 Development of Exernal Genitalia**

Male	Indifferent Stage	Female
Body and glans of penis	Genital tubercle	Clitoris
Ventral aspect of penis	Urogenital (urethral) folds	Labia minora
Scrotum	Labioscrotal swellings	Labia majora

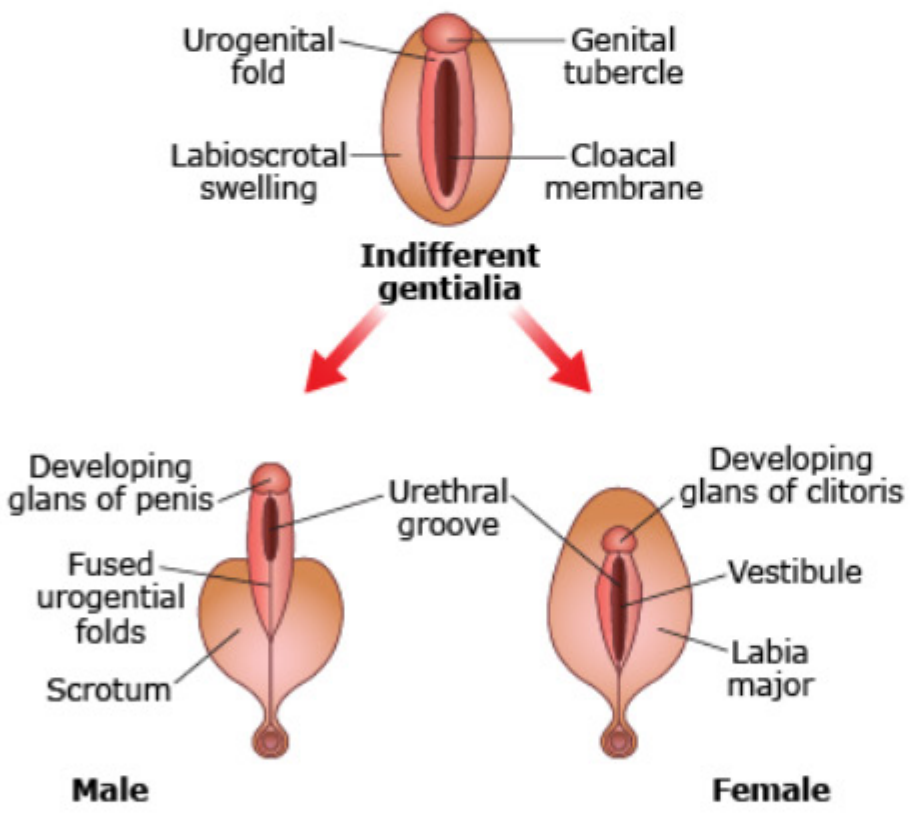

▲ **Figure 1–2.4** Development of External Genitalia

Please visit us at www.Groupinsiders.com

© DeVry/Becker Educational Development Corp. All rights reserved.

2.5 Anomalies of Male External Genitalia and Sex Differentiation

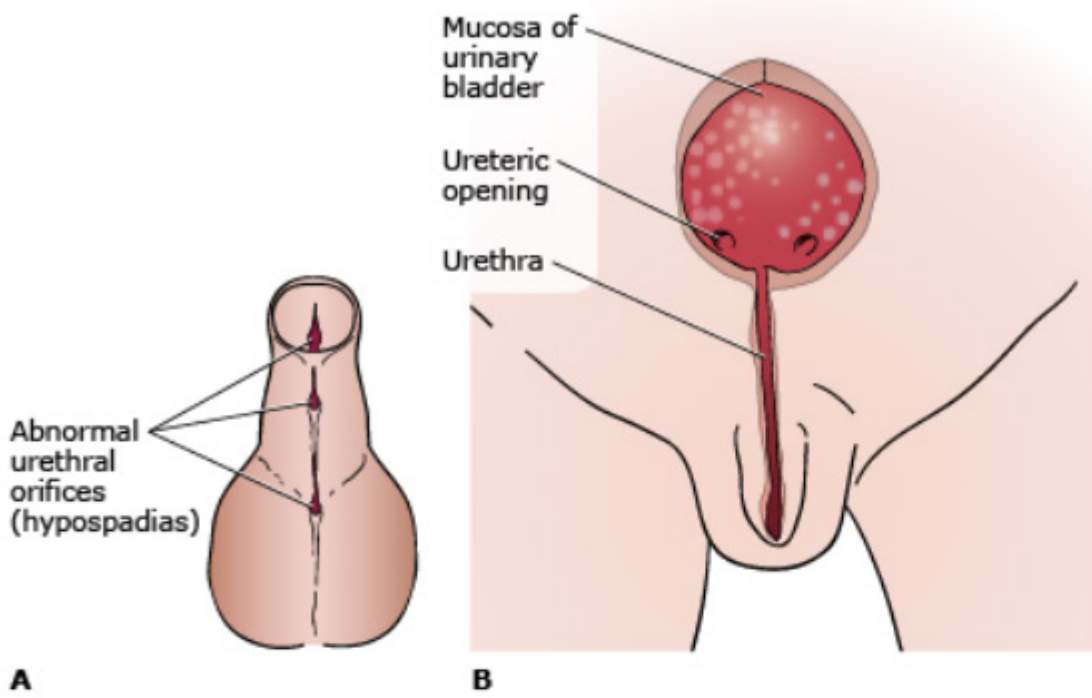

▲ **Figure 1–2.5** Developmental Anomalies of External Genitalia

2.5.1 Hypospadias

- Most common anomaly involving the penis.
- Abnormal openings of the urethra are found along the ventral surface of the penis.
- Results when the urogenital folds fail to fuse or fusion is incomplete on ventral surface.
- Can occur at the glans, along the shaft, or at the base of the penis at the scrotum.
- Often associated with a ventrally curved penis (chordee).

2.5.2 Epispadias

- A rare anomaly in which the urethra opens on the dorsal surface of the penis.
- Body wall defect.
- It is often associated with exstrophy of the bladder.

Please visit us at www.Groupinsiders.com

© DeVry/Becker Educational Development Corp. All rights reserved.

2.6 Anomalies of Sexual Differentiation

2.6.1 Female Pseudointersexuality

- Has a female genotype 46,XX.
- Has normal internal female reproductive organs.
- Excess androgen production *masculinizes the external genitalia (clitoral enlargement).*
- Results from *congenital fetal adrenal* hyperplasia that produces excess androgens.

2.6.2 Male Pseudointersexuality

- Has a male genotype 46,XY.
- Stunted development of male genitalia with female-like genitalia.
- Results from *reduced production of testosterone and MIF* and 5α-reductase deficiency.

2.6.3 Androgen Insensitivity Syndrome (Testicular Feminization Syndrome)

- Has a male genotype 46,XY with testis.
- Testis can be located in labia majora or inguinal canal and are removed to prevent tumor formation.
- Has female external genitalia with an underdeveloped vagina. The uterus and uterine tubes are absent or rudimentary.
- The social orientation of the individual is female.
- Caused by *lack of androgen receptors.*

Please visit us at www.Groupinsiders.com

© DeVry/Becker Educational Development Corp. All rights reserved.

Week 1: Fertilization to Early Implantation

1 Fertilization

Fertilization is the sequence of events whereby male and female gametes fuse to form a single cell called the *zygote* (46,2n). Fertilization involves spermatozoa penetration of the corona radiata and zona pellucida, and fusion of the male and female pronuclei. Fertilization results in the restoration of the diploid number of chromosomes and determination of sex of the embryo.

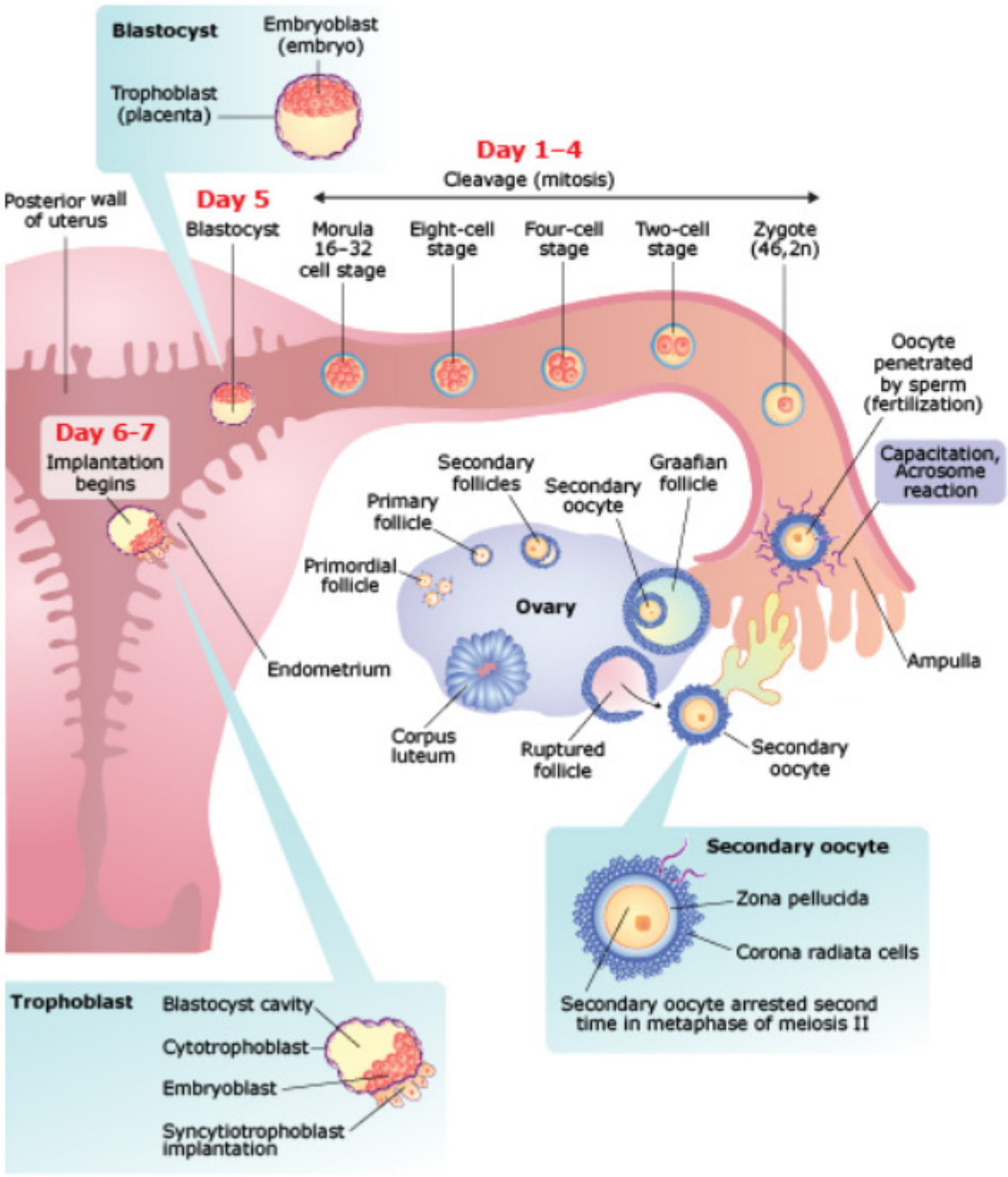

▲ **Figure 2–1.0** Week One

USMLE® Key Concepts

For Step 1, you must be able to:

- Identify the basic events of fertilization.
- Explain the important events of the first week of development.
- Describe the importance of the blastocyst and its cellular components.

Please visit us at www.Groupinsiders.com

© DeVry/Becker Educational Development Corp. All rights reserved.

- The normal site of fertilization is the *ampulla of the oviduct*.
- The ejaculate (3–4 mL) normally contains from 200 million to 600 million spermatozoa, but only 200 to 300 reach the oocyte. The spermatozoa can remain viable in the female genital tract for 48 hours.
- Freshly ejaculated spermatozoa are not able to fertilize the oocyte. When deposited in the female genital tract, spermatozoa undergo two events, *capacitation* and *acrosome reaction*.

1.1 Capacitation

Capacitation involves the removal of glycoproteins from the surface of the acrosome region of the spermatozoa that allows the sperm to penetrate the corona cells. Capacitation lasts about seven hours, with most of the process occurring in the oviduct.

1.2 Acrosome Reaction

Acrosome reaction occurs quickly when the sperm reach the zona pellucida. Apertures occur on the acrosome surface, and hydrolytic enzymes are released that are used to penetrate the zona pellucida. A *cortical reaction* occurs on the zona pellucida that usually prevents penetration of more than one spermatozoon into the oocyte (polyspermy).

1.3 Summary of First-Week Events

- *Cleavage is a series of rapid mitotic divisions of the zygote for the first four days.* During cleavage, the cells become smaller and compacted, and are called *blastomeres*.
- By the fourth day, the embryo is now a ball of 32 compacted cells called the *morula* (mulberry). The embryo is still contained in the zona pellucida at the morula stage.
- At day five, fluid begins to seep in and forms a *blastocyst cavity*. The embryo, now called a *blastocyst*, enters the uterine cavity and floats freely for about a day. The zona pellucida breaks down and disappears at this stage. The blastocyst consists of two important types of cells.
  1. The *inner cell mass (embryoblast)* forms at the embryonic pole and gives rise to the embryo proper.
  2. A peripheral single layer of cells called the *trophoblast* forms around the blastocyst cavity and contributes to the formation of the placenta.
- The blastocyst enters the uterine cavity about day five and floats freely for about a day.
- At day seven, the blastocyst begins to attach itself to the upper posterior wall of the uterus to begin *early implantation*. The blastocyst must implant for nutritional survival.
- Before implantation begins, trophoblast cells differentiate and form *cytotrophoblasts* (active in mitosis) and *syncytiotrophoblast* (lose cell membranes and no mitosis). The syncytiotrophoblasts cells form finger-like processes that invade the endometrium and release enzymes that are responsible for implantation.

Ectopic Pregnancies

- Extrauterine implantation of the blastocyst can occur in several locations.
- It occurs most commonly in the ampulla of the uterine tube, usually due to delayed transport.
- Clinical symptoms are a missed menstrual period, abdominal pain, and uterine bleeding.
- Commonly seen in women with endometriosis or pelvic inflammatory disease.
- Most common site for ectopic abdominal pregnancy is the rectouterine pouch (pouch of Douglas).

Please visit us at www.Groupinsiders.com

© DeVry/Becker Educational Development Corp. All rights reserved.

1 Bilaminar Disk and Implantation

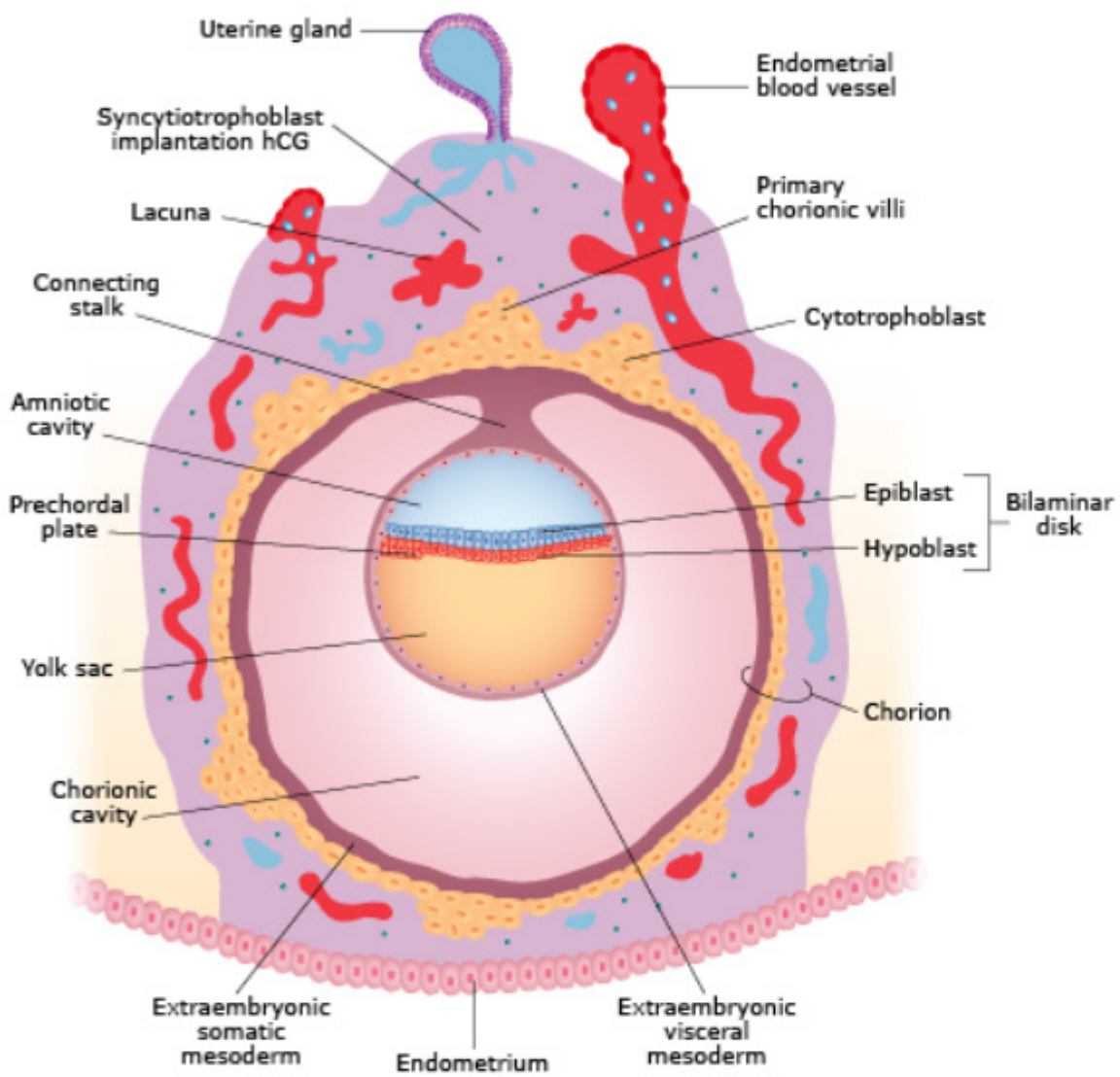

▲ **Figure 3–1.0** **Week Two**

In week two, the embryo develops the bilaminar disk and the amnion, and implantation is completed.

- The inner cell mass (embryoblast) of week one reorganizes itself into a bilaminar disk that consists of two layers of cells:
  1. *Epiblast cells* form the dorsal layer of tall columnar cells adjacent to the amniotic cavity. These cells develop into the embryo.
  2. *Hypoblast cells* consist of a ventral layer of cuboidal cells that are adjacent to the yolk sac. These cells are replaced in the third week. There are no adult structures that derive from hypoblast cells.

USMLE® Key Concepts

For Step 1, you must be able to:

- Describe the formation of the bilaminar disk and the role of epiblast cells in the second week of development.
- Explain the formation of the amnion.
- Describe the role of the syncytiotrophoblast in implantation and hormone production.

Please visit us at www.Groupinsiders.com

© DeVry/Becker Educational Development Corp. All rights reserved.

- The *amnion* develops from the epiblast layer of cells and begins secretion of amniotic fluid.
- The *primary yolk* sac is formed from the blastocyst cavity.
- Extraembryonic mesoderm is formed from cells lining the yolk sac. The extraembryonic mesoderm eventually divides into two layers, extraembryonic somatic mesoderm and extraembryonic visceral mesoderm. The chorionic cavity forms between these two layers. The wall of the chorionic cavity is called the chorion, which consists of extraembryonic somatic mesoderm, cytotrophoblast, and syncytiotrophoblast.
- *Implantation* is completed by the end of the second week as the *syncytiotrophoblast cells* actively invade into the wall of the uterus. This results in erosion of *maternal vessels (lacunar networks)* and *uterine glands*, thus establishing early nutrition for the embryo (by diffusion).
- Cytotrophoblast cells proliferate and penetrate into the syncytiotrophoblast to form columns called *primary villi*.
- At one end of the bilaminar disk, the epiblast and hypoblast cells fuse to form a thickened area called the *prechordal plate*. This area indicates the future site where the mouth will develop.
- Early *hematopoiesis* begins in the extraembryonic mesoderm surrounding the yolk sac and continues up to the sixth week. From week six to the third trimester, hematopoiesis is taken over by the liver, spleen, and thymus and finally moves to the bone marrow in the last trimester.

1.1 Amniotic Fluid

Amniotic fluid is a clear secretion produced from the lining cells of the amnion during pregnancy. The fetus swallows the fluid and is absorbed into the fetal blood through the gastrointestinal tract. Most of the amniotic fluid is excreted by the fetal kidneys into the amniotic sac. Excess fluid is removed by the placenta and passed into maternal blood. The amniotic fluid changes once every three hours. Its composition can be studied by amniocentesis.

Clinical Application

Polyhydramnios

Polyhydramnios occurs with high amounts of amniotic fluid (2L+) and is associated with multiple pregnancies, diabetes mellitus, anomalies of the CNS (anencephaly), anomalies of the GI system (inability to swallow or gut stenosis), and tracheoesophageal fistula.

Oligohydramnios

Oligohydramnios occurs when there is a low amount of amniotic fluid (less than 0.4L) and is associated with inability to excrete urine (renal agenesis). This results in other abnormalities, such as Potter syndrome and hypoplastic lungs.

Please visit us at www.Groupinsiders.com

© DeVry/Becker Educational Development Corp. All rights reserved.

1.2 Human Chorionic Gonadotropin Hormone (hCG)

- A protein secreted by syncytiotrophoblast cells.
- Maintains function of corpus luteum in the ovary during the first trimester and *production of progesterone* by the *corpus luteum*.
- Progesterone is critical for early development and maintenance of pregnancy.
- Can be assayed in maternal blood at day 8, in maternal urine at day 10, and is the basis of pregnancy testing.
- Spontaneous abortion and ectopic pregnancy are indicated by low levels of hCG.
- High levels of hCG suggest multiple pregnancies or a hydatidiform mole.

Please visit us at www.Groupinsiders.com

© DeVry/Becker Educational Development Corp. All rights reserved.

Please visit us at www.Groupinsiders.com

1 Gastrulation

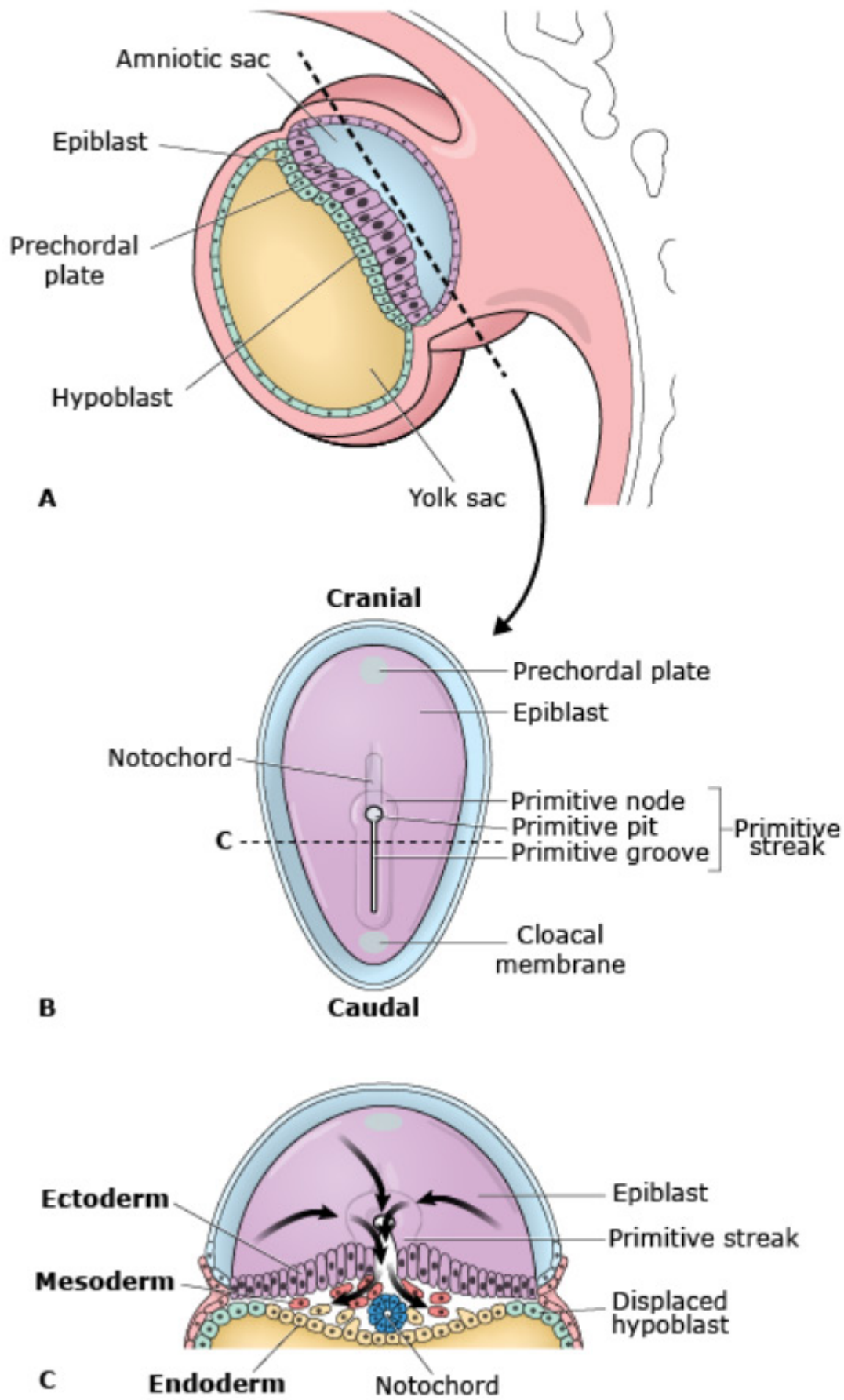

▲ **Figure 4–1.0 Gastrulation**

USMLE® Key Concepts

For Step 1, you must be able to:

- Describe the formation of the primitive streak and its role in gastrulation.
- Explain the importance of gastrulation in developing the three germ layers: ectoderm, mesoderm, and endoderm.
- Describe the role of the three germ layers in developing the basic tissues and organ systems of the body.

Important Concept

Epiblast forms all three germ layers: ectoderm, mesoderm, and endoderm.

Please visit us at www.Groupinsiders.com

© DeVry/Becker Educational Development Corp. All rights reserved.

Gastrulation is the process that transforms the bilaminar disk into a trilaminar disk that is formed by three germ layers (*ectoderm*, *mesoderm*, and *endoderm*). Note that all three germ layers are derived from epiblast.

- Gastrulation begins with the formation of the *primitive streak* (within the epiblast), consisting of a primitive node and groove.
  - Epiblast cells on the dorsal surface of the disk migrate from all directions to the midline and invaginate through the primitive streak.
  - Some of these cells displace the deeper hypoblast cells to form the definitive *endoderm layer*.
  - Other cells spread between the endoderm and the epiblast cells and form the *mesoderm layer*.
  - Epiblast cells that remain on the surface do not invaginate through the streak and form general *ectoderm*.
  - Gastrulation is completed by the middle of the third week.
- At the end of gastrulation, some of the epiblast cells at the primitive node region form a midline rod called the *notochord*. The primitive streak and the notochord establish the dorsal midline axis of the embryo.
- The *embryonic period (organogenesis)* begins at the middle of the third week and continues through the eighth week. It is in this period that many abnormal developmental events occur.
- Development of the cardiovascular and nervous systems begins in the last half of the third week.
- The major germ layer derivatives are shown in Table 4–1.0.

Connection to Neuroanatomy

Notochord will be critical in early development of the nervous system.

Please visit us at www.Groupinsiders.com

© DeVry/Becker Educational Development Corp. All rights reserved.

▼ Table 4–1.0 Germ Layer Derivatives

Ectoderm		
Surface ectoderm	• Epidermis • Hair • Nails • Inner ear, external ear • Enamel of teeth	• Lens of eye • Anterior pituitary (Rathke pouch) • Parotid gland • Anal canal below pectinate line • Mammary gland
Neuroectoderm	• Neural tube – Central nervous system – Retina and optic nerve – Pineal gland	– Neurohypophysis – Astrocytes – Oligodendrocytes (CNS myelin)
Neural crest	• Adrenal medulla • Ganglia – Sensory—pseudounipolar neurons – Autonomic—postganglionic neurons • Pigment cells • Schwann cells (PNS myelin) • Meninges – Pia and arachnoid mater • Pharyngeal arch cartilage and bone • Odontoblasts • Parafollicular (C) cells • Aorticopulmonary septum • Endocardial cushions	
Mesoderm		
	• Muscle – Smooth – Cardiac – Skeletal • Connective tissue • All serous membranes • Bone and cartilage • Blood, lymph, cardiovascular organs • Spleen • Adrenal cortex • Kidney and ureter • Gonads and genital tracts • Dura mater	
Endoderm		
Forms epithelial lining of:	• GI tract: Foregut, midgut, and hindgut • Lower respiratory system: Larynx, trachea, bronchi, and lung • Genitournary system: Urinary bladder, urethra, and lower vagina • Pharyngeal pouches: – Auditory tube and middle ear – Palatine tonsils – Parathyroid glands – Thymus	
Forms parenchyma of:	• Liver • Pancreas	• Submandibular and sublingual glands • Follicles of thyroid gland (not C cells)

Please visit us at www.Groupinsiders.com

© DeVry/Becker Educational Development Corp. All rights reserved.

Clinical Application

Sacrococcygeal Teratoma

- Failure of the primitive streak to regress after gastrulation.
- Persists as tumors that develop from remnants of the primitive streak.
- Can contain tissues derived from all three germ layers (hair, bone, and nerve).
- Usually become malignant.
- More common in females and are surgically removed.

Chordoma

- Midline tumor that develops from remnants of the notochord.
- Found at the base of the skull or in the lumbosacral region (most common site).
- One third are malignant tumors and are difficult to remove.

Please visit us at www.Groupinsiders.com

© DeVry/Becker Educational Development Corp. All rights reserved.

Chapters 1–4 Review Questions

1. A newborn male has congenital malformations of the vas deferens and other genital ducts. These congenital defects possibly could be caused by genetic defects in which of the following?

A. Sertoli cells
B. Leydig cells
C. Mesonephric duct
D. Sex cords
E. MIF production

2. A 2-week-old male is admitted to the hospital because urine is observed passing through an opening on the ventral surface of the penis. During development, which of the following was involved in this defect?

A. Ventral defect of body foldings
B. Low levels of dihydrotestosterone
C. Low levels of 5-α reductase enzyme
D. Labioscrotal swellings
E. Urogenital folds

3. During a laboratory study, a technician would expect to find which of the following cells to contain 4n DNA during spermatogenesis?

A. Secondary spermatocyte
B. Primary spermatocyte
C. Primordial germ cell
D. Haploid gamete
E. Type B spermatogonia

Please visit us at www.Groupinsiders.com

© DeVry/Becker Educational Development Corp. All rights reserved.

Review Questions Chapters 1–4

4. During the process of fertilizing harvested oocytes at a fertility clinic, a technician works under a light microscope to insert a single sperm. What would be the best indicator that fertilization was successful?

A. Capacitation occurs
B. Zona pellucida disappears
C. Arrested in metaphase of meiosis II
D. Second polar body appears
E. Two-cell zygote is visible

5. During week one of development, the blastocyst begins to implant into the uterus. Which one of the following immediate events allows implantation to begin?

A. Acrosome reaction
B. Release of enzymes from the cytotrophoblast
C. Beginning of cleavage
D. Breakdown of the zona pellucida
E. Formation of the primitive streak

Please visit us at www.Groupinsiders.com

© DeVry/Becker Educational Development Corp. All rights reserved.

Chapters 1–4 Review Questions

6. In the second week of development, a defect occurred in the production of primary villi after a woman who did not know she was pregnant received chemotherapy. The chemotherapy affected mitosis in which of the following cells that were involved in this defect?

A. Extraembryonic mesoderm
B. Syncytiotrophoblasts
C. Cytotrophoblasts
D. Epiblasts
E. Hypoblasts

7. During an experimental lab study on mice, a scientist removes the neural crest cells from the cervical region of an animal on day 30 of development. Which of the following tissues or cells will most likely be affected?

A. Smooth muscle cells
B. Peripheral nervous system myelin
C. Epithelial lining cells of the GI tract
D. Parotid gland
E. Adrenal cortex

Please visit us at www.Groupinsiders.com

© DeVry/Becker Educational Development Corp. All rights reserved.

Review Answers Chapters 1–4

1. The correct answer is C. The indifferent gonad contains a pair of genital ducts: mesonephric and paramesonephric. The mesonephric duct (wolffian) plays an important role in development of the male genital tract (vas deferens, seminal vesicles, and ejaculatory duct) under the influence of testosterone and is involved in the genetic defect of this newborn male. The paramesonephric (müllerian) duct is involved in development of the female genital tract.

2. The correct answer is E. During the development of male genitalia, the ventral aspect of the penis is closed by the fusion of the urogenital folds. Failure of the folds to fuse can result in abnormal openings of the urethra along the ventral surface of the penis.

3. The correct answer is B. During spermatogenesis, the spermatogonia (46,2n) undergo DNA replication as they enter meiosis I as a primary spermatocyte (46,4n). Each of the other cell types contains 2n DNA.

4. The correct answer is D. In oogenesis, the secondary oocyte (23,2n) is arrested the second time in metaphase of meiosis II within the graafian follicle. This is the cell that is ovulated, and only if there is fertilization will the secondary oocyte complete meiosis II and produce the second polar body and form the female pronucleus.

5. The correct answer is D. Through the end of the morula stage in the first week of development, the follicle is still encased by the zona pellucida. About day five, the zona pellucida breaks down as the morula becomes the blastocyst. This allows early implantation of the blastocyst to begin at the end of the first week with the release of enzymes from the syncytiotrophoblast cells.

6. The correct answer is C. At the end of the first week of development, trophoblast cells differentiate into two cell lines, cytotrophoblast and syncytiotrophoblast. In the second week, the cytotrophoblast cells grow out into the syncytiotrophoblast cells to form the primary villi.

7. The correct answer is B. Neural crest cells develop during neurulation from neuroectoderm cells at the neural folds by the end of the third week. These cells then migrate during embryogenesis into a number of systems. One role of the neural crest cells is the development of several components of the PNS: ganglia and Schwann cells. Schwann cells are involved in the myelination of peripheral axons.

Please visit us at www.Groupinsiders.com

© DeVry/Becker Educational Development Corp. All rights reserved.

Unit 2

Gross Anatomy and Organogenesis

Please visit us at www.Groupinsiders.com

Please visit us at www.Groupinsiders.com

1 Skeletal System of the Back and Spinal Cord

The skeletal system is divided into an *appendicular system* (pectoral and pelvic girdles and the bones of the upper and lower limbs) and an *axial system* (skull, vertebral column, ribs, and sternum).

1.1 Vertebral Column

Vertebrae develop from the *sclerotome* (mesoderm) portion of the somites (discussed later in chapter 10). The mesoderm of the sclerotome proliferates around the notochord and the neural tube to form the vertebral body and arch.

The vertebral column consists of a series of 33 vertebrae that include *7 cervical, 12 thoracic, 5 lumbar, 5 sacral (fused),* and *4 coccygeal* (single or fused) vertebrae (Figure 5–1.1). The individual vertebrae are superimposed on each other, forming a column that functions in weight-bearing, movement, muscle attachments, and protecting the spinal cord. The vertebrae are connected by intervertebral disks and ligaments. In the adult, the vertebral column has four curvatures: cervical, thoracic, lumbar, and sacral.

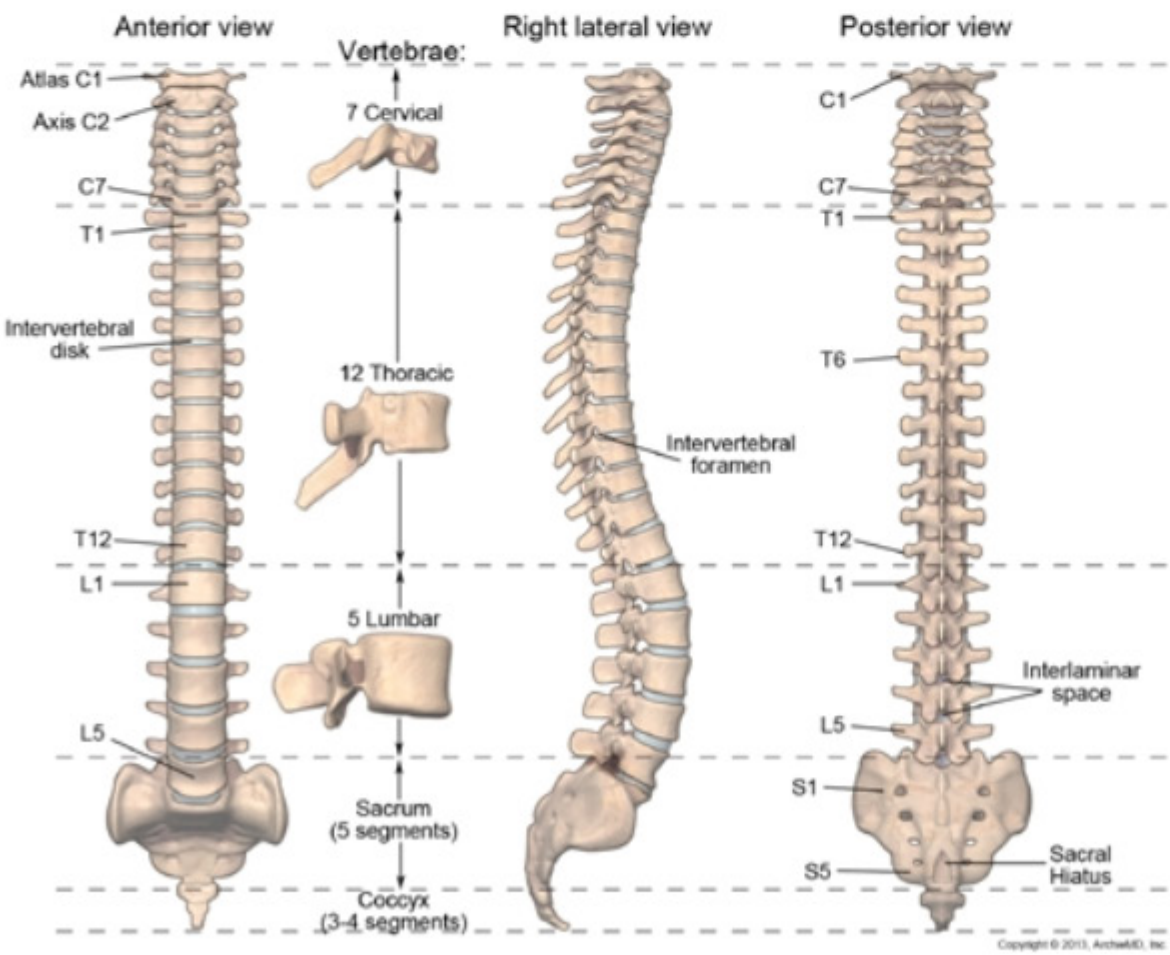

▲ **Figure 5–1.1** Vertebral Column

USMLE® Key Concepts

For Step 1, you must be able to:

- Explain the general features of the vertebral column and how they relate to the spinal cord and spinal nerves.
- Identify the intervertebral disk and the mechanism of disk herniation.
- Define the three meninges of the spinal cord and their structure and function.
- Describe the meningeal spaces and how they are used in lumbar punctures.
- Explain the basic organization and distribution of the spinal nerve system.

Please visit us at www.Groupinsiders.com

© DeVry/Becker Educational Development Corp. All rights reserved.

Please visit us at www.Groupinsiders.com

Clinical Application

Abnormal curvatures of the vertebral column include:

- *Kyphosis* (humpback) is an increased anterior forward curvature of the spine, usually resulting from osteoporosis.
- *Lordosis* (swayback) is an increased lumbar posterior curvature of the spine, usually resulting from weakness of anterior trunk muscles.
- *Scoliosis* is a lateral deviation and curvature of the spine resulting from the absence of part of a vertebra or weakness of the vertebral muscles.

1.2 Typical Vertebra

Although there are regional differences, vertebrae demonstrate a typical structural pattern.

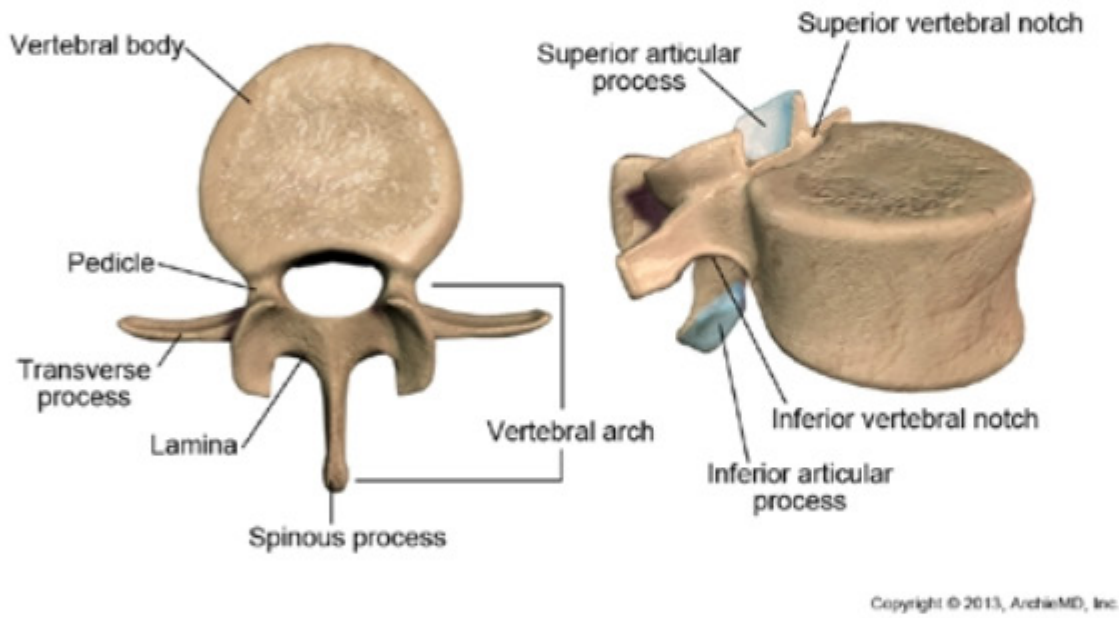

▲ **Figure 5–1.2** Typical Vertebra

- The body is the massive, anterior part of a vertebra for weight bearing. The bodies of the vertebrae are connected by the intervertebral disk and ligaments and increase in size from cervical to lumbar regions.
- Extending posteriorly from the body is the *vertebral arch*, which is composed of paired *pedicles* and *laminae*. The body and the vertebral arch form the *vertebral foramen*, which collectively form the *vertebral canal*. The vertebral canal contains and protects the spinal cord.

© DeVry/Becker Educational Development Corp. All rights reserved.

- *Intervertebral foramina* are lateral windows of the vertebral column formed by the adjacent *vertebral notches* of the successive pedicles. The spinal nerves exit through these foramina as they leave the vertebral column. The boundaries of the intervertebral foramina are:
  - **Posterior:** Articular processes and zygapophyseal joint.
  - **Anterior:** Bodies of vertebrae and intervertebral disks.
  - **Superior and Inferior:** Pedicles of the vertebrae.
- *Transverse* and *spinous processes* project from the vertebral arch to provide for attachments of muscles.
- *Superior* and *inferior articular processes* form synovial joints between adjacent vertebrae.

1.3 Anterior and Posterior Longitudinal Ligament

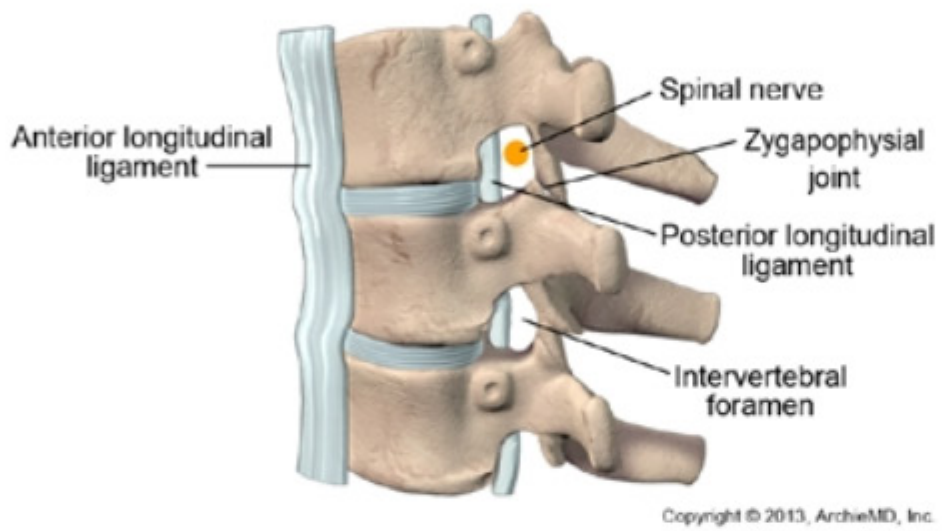

▲ **Figure 5–1.3** Anterior and Posterior Longitudinal Ligaments

The anterior and posterior longitudinal ligaments course on the anterior and posterior surfaces, respectively, of the vertebral bodies and intervertebral disks between the cervical and sacral vertebral segments. They provide support, stability, and some limitation of movement of the vertebral column.

- The *anterior longitudinal ligament* is broad and strong, and descends on the anterior surfaces of the vertebral bodies and intervertebral disks. It limits *hyperextension* of the vertebral column. The anterior longitudinal ligament can be involved in whiplash injuries when the neck is abruptly hyperextended.
- The *posterior longitudinal ligament* is narrower and runs on the posterior surfaces of the vertebral bodies and disks within the vertebral canal anterior to the spinal cord. The posterior ligament limits *hyperflexion* of the vertebral column.

Please visit us at www.Groupinsiders.com

© DeVry/Becker Educational Development Corp. All rights reserved.

1.4 Intervertebral Disks

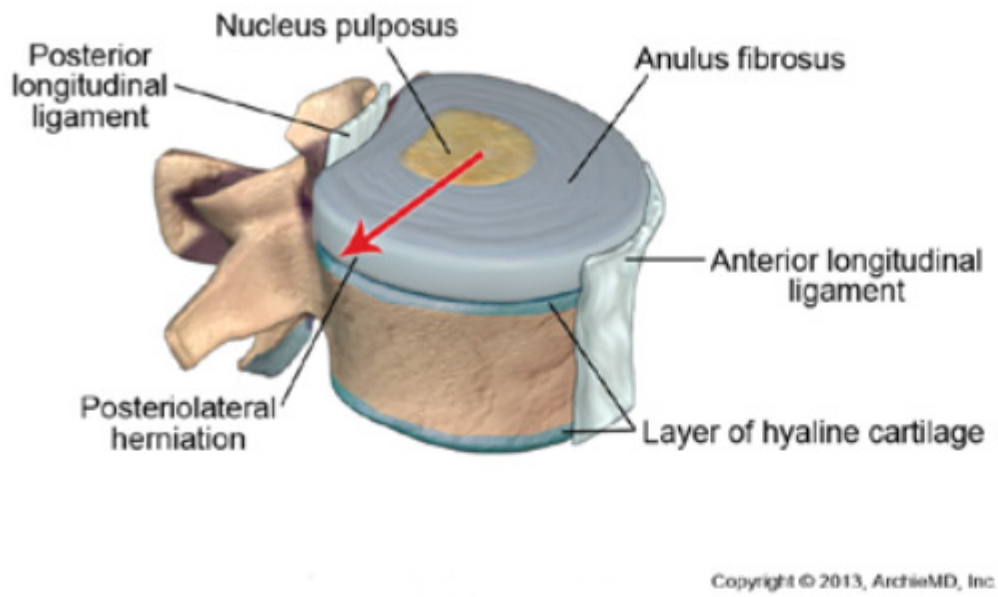

▲ **Figure 5–1.4A** Intervertebral Disks

The *intervertebral disks* are cartilaginous structures that are interposed between the bodies of adjacent vertebrae from the second cervical vertebra (axis) to the sacrum. They contribute to the movements of the vertebral column and compose about 25% of the length of the vertebral column. They are supported by anterior and posterior longitudinal ligaments.

- Note that the disks are numbered by the number of the *vertebral body above the disk* (e.g., the disk between the C6 and C7 vertebrae is the C6 disk; the disk between the L4 and L5 vertebrae is the L4 disk).
- The disks consist of two parts: *anulus fibrosus* and *nucleus pulposus*.
- The *anulus fibrosus* consists of concentric layers of connective tissue and fibrocartilage that connect adjacent vertebral bodies. They provide strength and stability for the vertebral column.
- The *nucleus pulposus* is an expandable, semi-gelatinous material located in the central area of the disk that serves as a shock absorber of compression forces applied on the vertebrae. The nucleus pulposus may herniate through the anulus fibrosus and compress the roots of the spinal nerves. The nucleus is an adult remnant of the embryonic *notochord*.

Important Concept

The posterior longitudinal ligament reinforces the disk in the dorsal midline and deviates the herniated disk laterally.

Important Concept

Herniated disk primarily compresses the spinal nerve roots one number below the numbered herniated disk in lumbar and cervical regions.

Please visit us at www.Groupinsiders.com

© DeVry/Becker Educational Development Corp. All rights reserved.

Clinical Application

Disk Herniation

Herniation of a disk occurs when the nucleus pulposus protrudes or herniates through the anulus fibrosus and compresses the roots of the spinal nerves.

Herniation is more frequent in the regions of the vertebral column with greater mobility (cervical and lumbar). In the cervical region, herniation is common at the C6 disk. In the lumbar region, the L4 and L5 disks are often involved.

Protrusion of the nucleus pulposus usually occurs *posterolaterally* through the anulus fibrosus where the disk is not reinforced by the posterior longitudinal ligament.

The herniation typically compresses roots of the spinal nerves *one number below* the herniated disk (e.g., herniation of the L4 disk will compress L5 nerve roots; herniation of the C6 disk will compress C7 nerve roots).

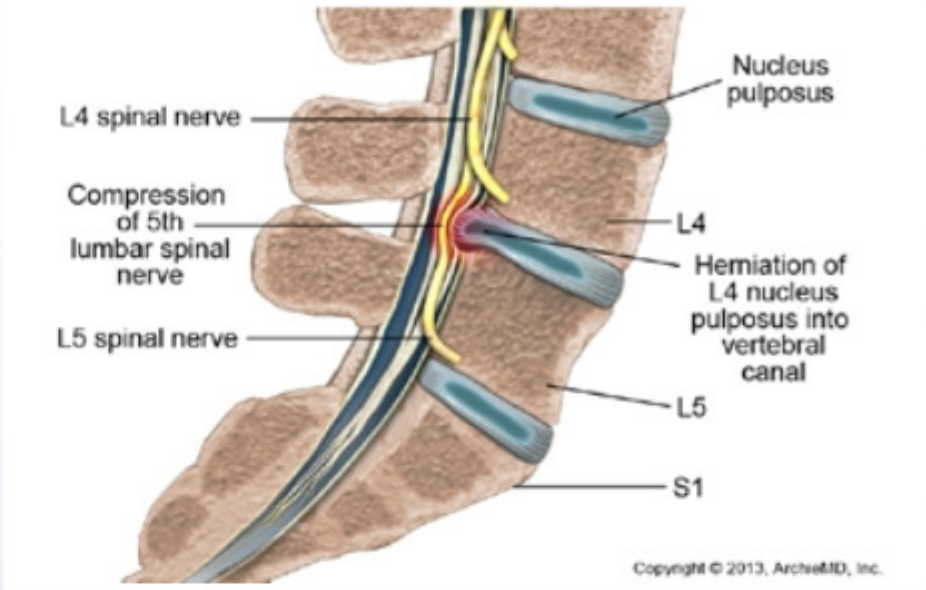

▲ **Figure 5–1.4B** Herniated Intervertebral Disk

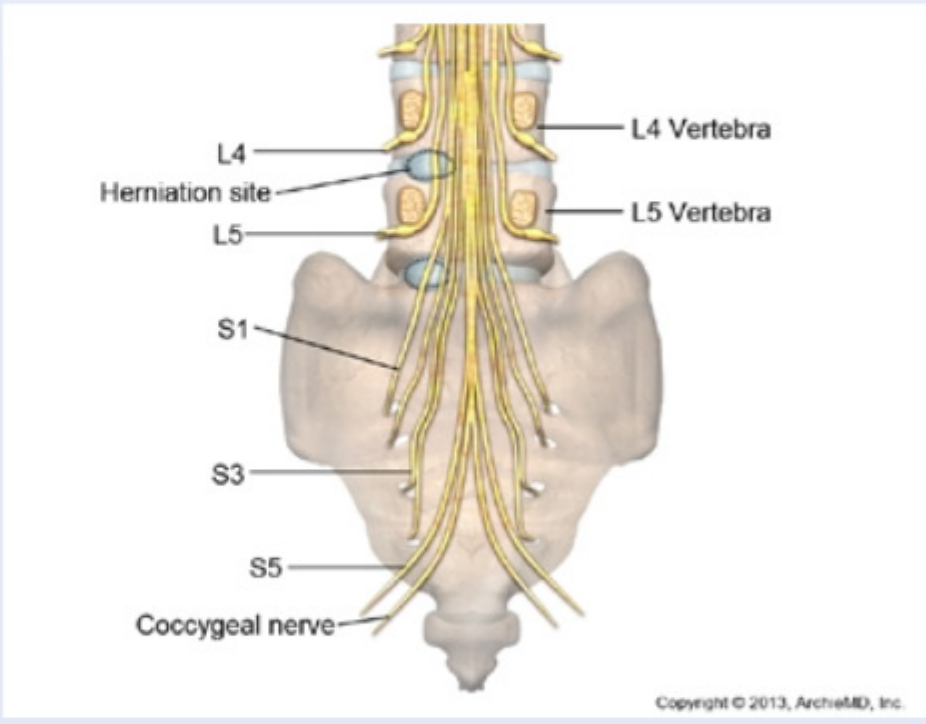

▲ **Figure 5–1.4C** Herniated Intervertebral Disk (Detail)

Please visit us at www.Groupinsiders.com

© DeVry/Becker Educational Development Corp. All rights reserved.

1.5 Spinal Cord

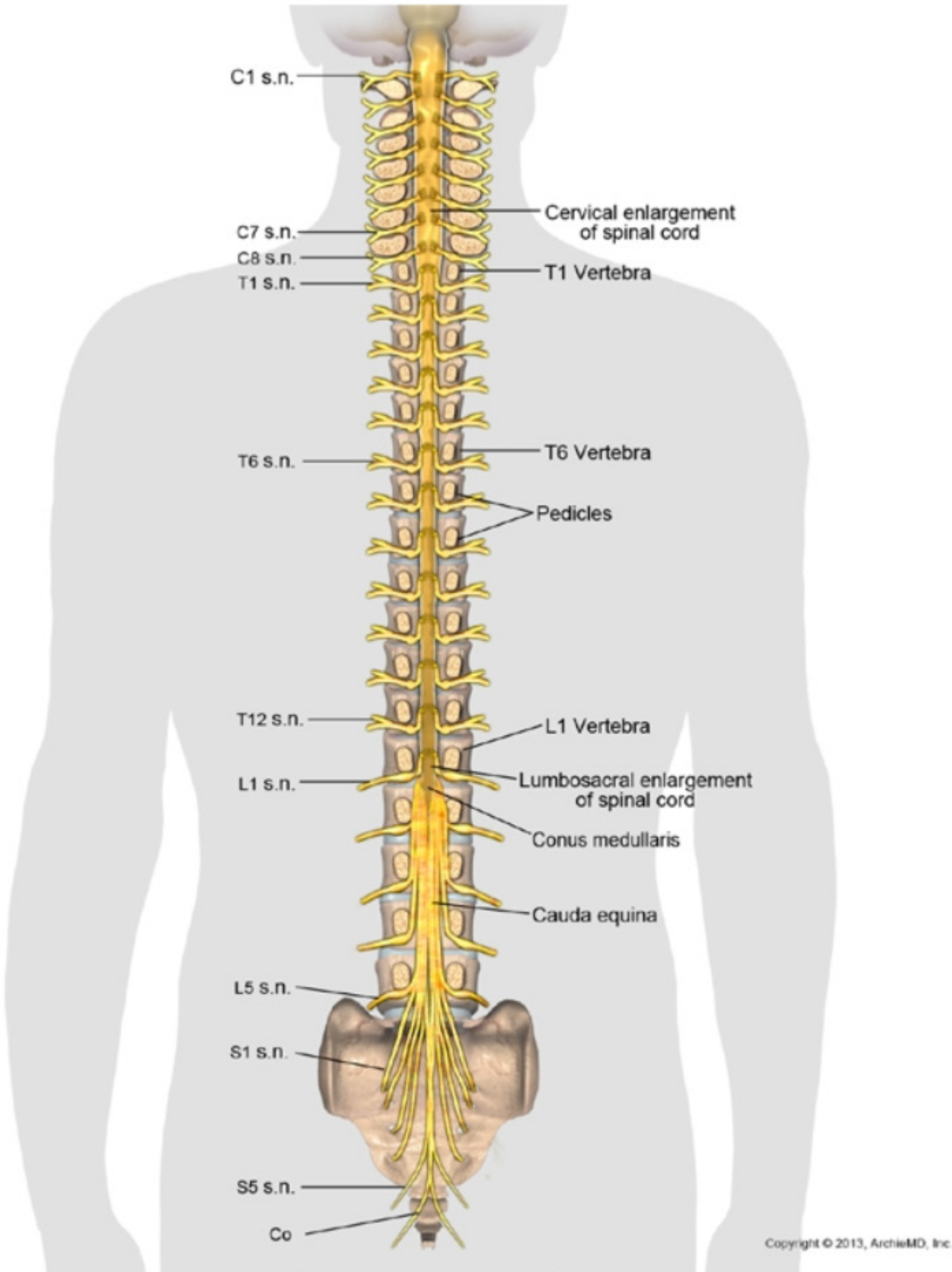

▲ **Figure 5–1.5** Spinal Cord in the Vertebral Canal

Please visit us at www.Groupinsiders.com

© DeVry/Becker Educational Development Corp. All rights reserved.

The spinal cord occupies the upper two thirds of the vertebral canal of the vertebral column. The vertebral canal also contains the meninges, meningeal spaces, and roots of the spinal nerves.

- The spinal cord is cylindrical and is covered by three layers of meninges. Cervical and lumbar enlargements on the spinal cord give rise to the large mass of nerves supplying the upper and lower limbs, respectively.
- Distally, the cord ends in a cone-shaped structure called the *conus medullaris*, which usually terminates at the L1-L2 vertebral level in the adult. In the newborn, the cord can extend as low as the L3-L4 vertebrae.
- The spinal cord develops segmentally and has cervical (7), thoracic (12), lumbar (5), sacral (5), and coccygeal (1) segments that give rise to the 31 paired spinal nerves.

1.6 Meninges

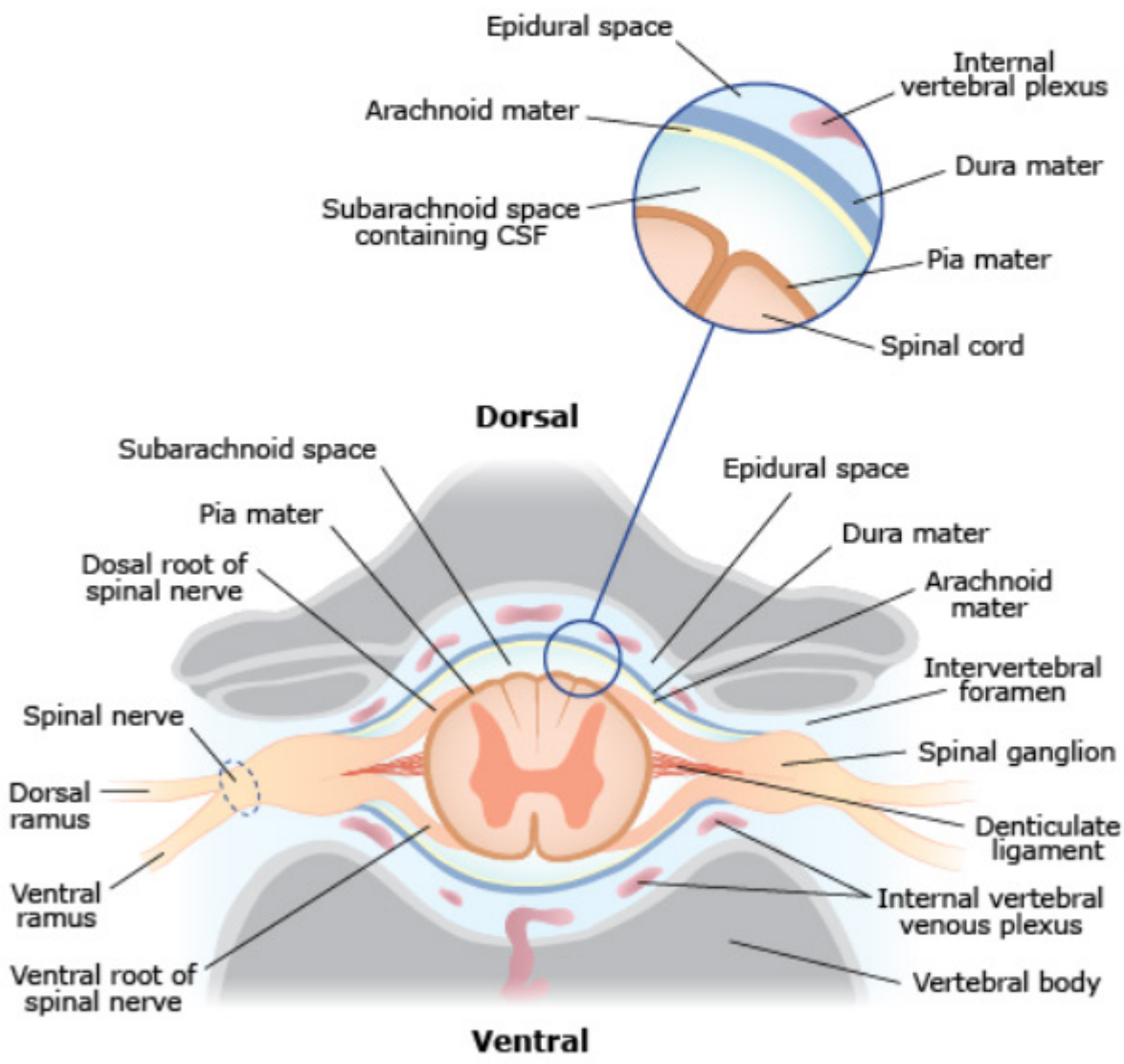

▲ **Figure 5–1.6** Meninges

Please visit us at www.Groupinsiders.com

© DeVry/Becker Educational Development Corp. All rights reserved.

The meninges form three membranes (*pia mater*, *dura mater*, and *arachnoid*), which surround the cord and provide protection and stability for the spinal cord.

- **Pia Mater:** Pia mater is the innermost layer that is tightly attached to the surface of the cord and cannot be peeled away. It encloses the small blood vessels on the surface of the cord.
  - The pia mater covers the spinal cord until the cord terminates at the L1–L2 vertebral level.
  - The pia mater forms two special connective structures related to the cord:
    - **Denticulate Ligaments:** These are bilateral extensions of the pia mater that extend on both sides of the midpoint of the cord. The denticulate ligaments separate the ventral and dorsal roots of the spinal nerves. There are toothpick-like processes of the denticulate ligaments at each interval between spinal nerves that tack the cord to the dura mater to help stabilize the position of the cord.
    - **Filum Terminale:** This is the continuation of pia mater from the tip of the conus medullaris at the L2 vertebra. It forms a single strand that extends through the sacral hiatus to attach distally to the coccyx. The filum terminale tethers the cord to the coccyx. Proximally the filum is part of the *cauda equina* (horse's tail), and distally it is covered by dura and arachnoid, where all three layers are referred to as the coccygeal ligament. The cauda equina consists of the lumbar and sacral dorsal and ventral nerve roots that surround the filum terminale within the dural sac below the conus medullaris.
- **Dura Mater:** The dura is the dense, strong outermost layer of meninges that surrounds the spinal cord.
  - It extends distally to the *S2 vertebral level*, where it closes off to form the distal end of the dural sac.
  - Dura mater forms dural sleeves around the exit of each of the spinal nerves.
  - The dura mater passes through the foramen magnum, where it continues as the meningeal layer of cranial dura.
- **Arachnoid:** The arachnoid is a transparent, delicate covering of the cord that lies between the dura and pia mater. In life, the pressure of the subarachnoid space pushes the arachnoid against the inner surface of the dura mater. The arachnoid follows the inner surface of the dura mater and also extends to the S2 vertebral level.

Please visit us at www.Groupinsiders.com

© DeVry/Becker Educational Development Corp. All rights reserved.

1.7 Meningeal Spaces

There are two important spaces related to the meninges (Figure 5–1.7).

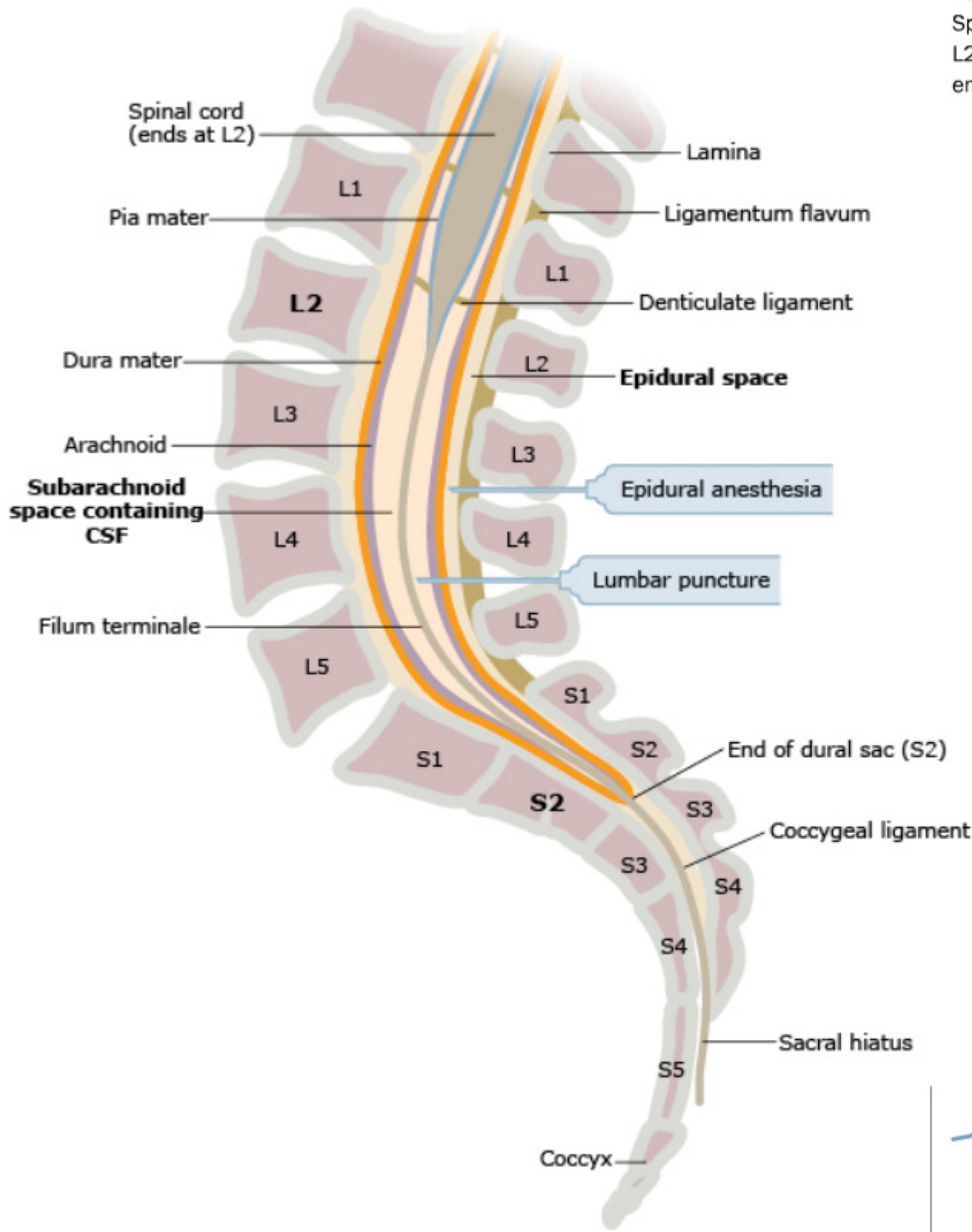

▲ **Figure 5–1.7** Meningeal Spaces

- The *subarachnoid space* is found within the dural sac between the pia mater and the arachnoid membranes and extends distally to the S2 vertebral level. It is a pressurized space containing cerebrospinal fluid (CSF).
- The epidural space is external to the dura mater and is located between the dura and the periosteum of the vertebral column. It contains epidural fat that protects the cord and the *internal vertebral venous plexus*, which can provide a route of metastasis of cancer cells. The epidural space can be used as a site for injection of anesthetic agents.

Important Concept

Spinal cord terminates at the L2 vertebral level and dural sac ends at the S5 vertebral level.

Clinical Application

The internal vertebral venous plexus can provide a route of metastasis of cancer from breasts, lungs, and prostate gland to the brain. The veins of the internal vertebral plexus connect with veins in the body cavities and are continuous with the cranial dural venous sinuses through the foramen magnum.

Please visit us at www.Groupinsiders.com

© DeVry/Becker Educational Development Corp. All rights reserved.

1.8 Lumbar Puncture and Anesthesia

Lumbar puncture is performed to withdraw cerebrospinal fluid or to inject medications or anesthesia (Figure 5–1.8).

- Lumbar puncture is commonly performed at the L4 vertebral level, which is easily identified on the dorsal midline by drawing a horizontal line at the level of the iliac crest.
- Anesthetic can be injected into either the epidural or subarachnoid space. Either one can be used for childbirth.
- The *interlaminar spaces* are covered by the *ligamentum flavum* on either side of the midline. The ligamentum flava extend between adjacent laminae and close the posterior aspect of the vertebral canal.
- In a lumbar puncture to either side of the midline, the needle passes through the interlaminar space and ligamentum flavum.
- In a lumbar puncture to either side of the midline, the needle will pass through the:
  - Skin
  - Superficial and deep fascia
  - Muscle
  - Ligamentum flavum at the interlaminar space
  - Epidural space
  - Dura mater and arachnoid
  - Subarachnoid space

Caudal (epidural) anesthesia can be performed by injection via the sacral hiatus into the epidural space.

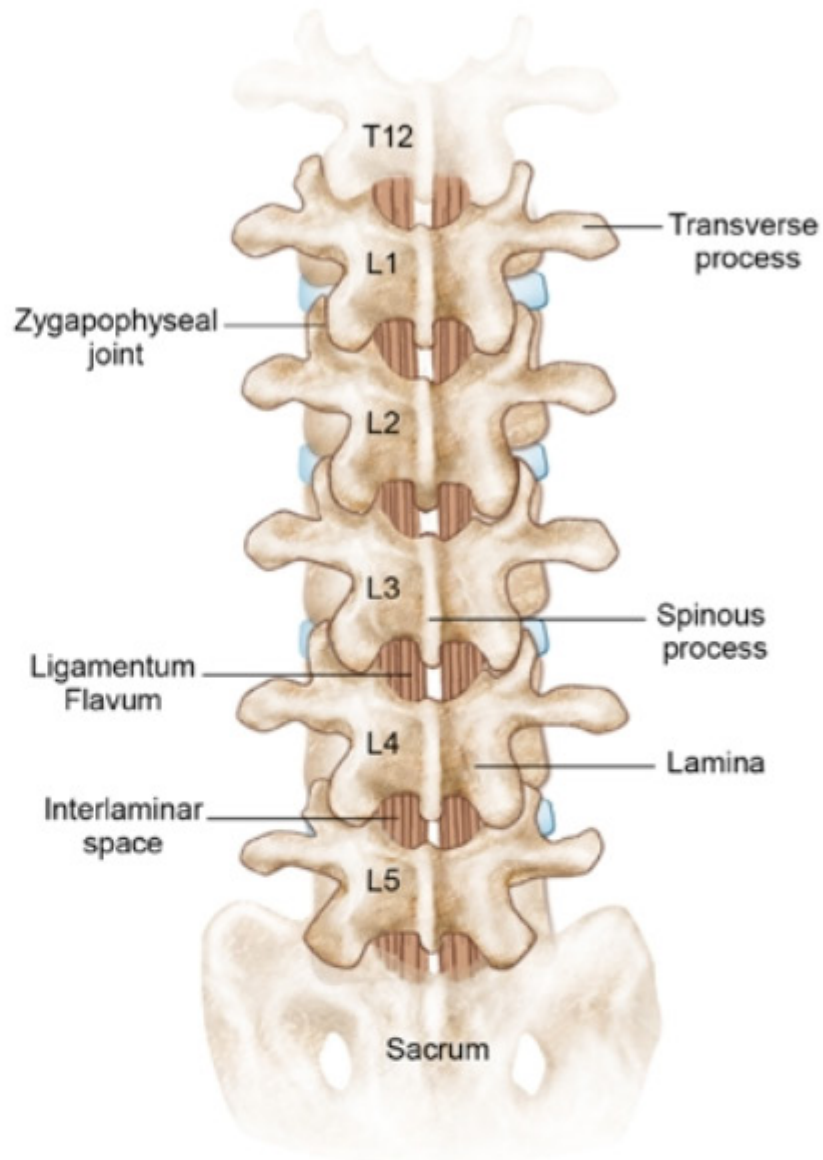

▲ **Figure 5–1.8** Interlaminar Spaces

Please visit us at www.Groupinsiders.com

© DeVry/Becker Educational Development Corp. All rights reserved.

2 Spinal Nerves

The nervous system is divided into a central nervous system (CNS) formed by the brain and spinal cord and the peripheral nervous system (PNS) consisting of spinal nerves, cranial nerves, and their associated ganglia. Although the details of the nervous system will be discussed later in neuroscience, here is a brief overview of spinal nerves.

There are 31 pairs of spinal nerves segmentally derived from the 31 segments of the spinal cord (8 cervical, 12 thoracic, 5 lumbar, 5 sacral, and 1 coccygeal).

- The spinal nerves exit the intervertebral foramina and distribute somatic and visceral innervations throughout the PNS.
- The somatic pathways mediate innervation for skeletal muscles and conscious sensation. In contrast, visceral pathways mediate motor and sensory innervation for visceral structures.

The major parts of a typical spinal nerve include:

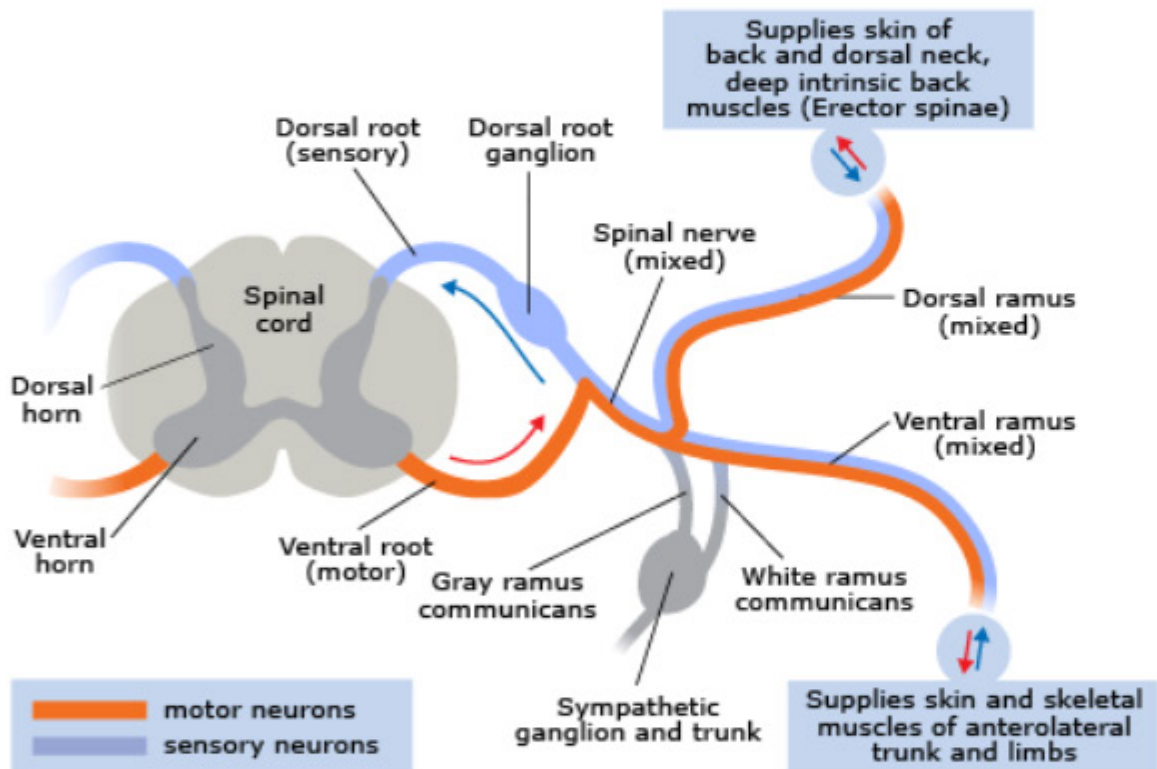

▲ **Figure 5–2.0** Spinal Nerve

- **Dorsal Root:** The dorsal roots attach to the dorsal surface of the cord and transmit afferent (sensory) information from peripheral sensory receptors to the spinal cord. Each dorsal root contains a dorsal root ganglion that houses the cell bodies of the sensory neurons coursing in the dorsal root (pseudounipolar or unipolar neurons).
- **Ventral Root:** The ventral roots attach to the ventral surface of the cord and distribute motor innervation from the CNS to the periphery. The cell bodies of these motor neurons are located within the gray matter of the spinal cord.

Please visit us at www.Groupinsiders.com

© DeVry/Becker Educational Development Corp. All rights reserved.

- **Spinal Nerve:** Immediately distal to the dorsal root ganglion, the dorsal and ventral roots merge to form the spinal nerve that exits at the intervertebral foramen. Spinal nerves are now mixed, carrying motor and sensory fibers.
- **Rami:** Distal to the intervertebral foramen, the spinal nerve divides into its two divisions that distribute neurons throughout the PNS:
  1. **Dorsal Rami (31):** Provide segmental motor and sensory innervation for the skin of the dorsum, the deep skeletal muscles of the back and posterior neck, and the joints of the vertebral column.
  2. **Ventral Rami (31):** Provide motor and sensory innervation for the skin and muscles of the anterior and lateral trunk and limbs. Many of the ventral rami fuse together to form peripheral nerve plexuses (brachial, cervical, and lumbosacral). Other ventral rami remain single and form intercostal and subcostal nerves.

The spinal nerves are connected to the sympathetic chain via white and gray rami communicantes.

2.1 Exit of Spinal Nerves From Vertebral Column

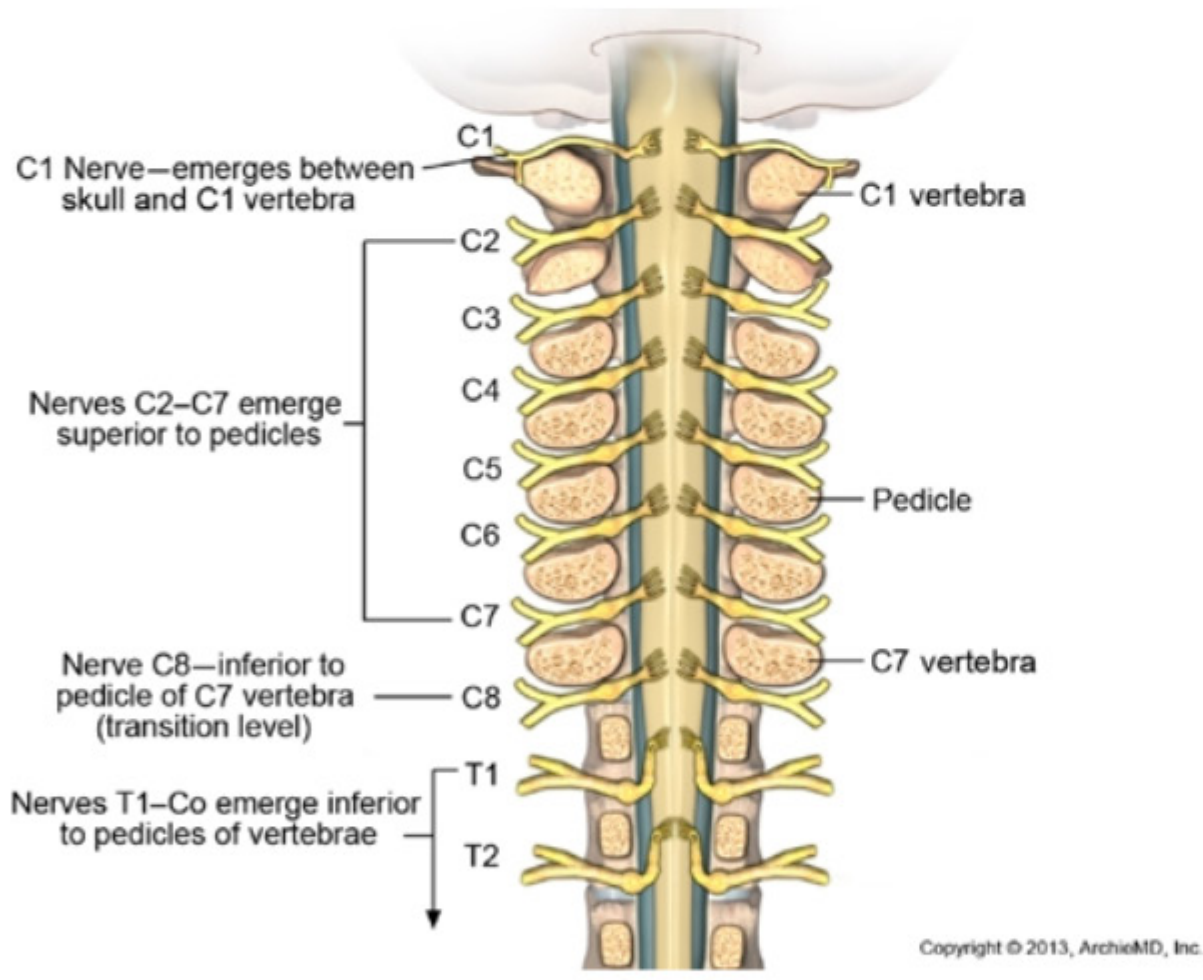

▲ **Figure 5–2.1** Exit of Spinal Nerves From Vertebral Column

- Cervical spinal nerves C1 to C7 exit the vertebral column superior to the pedicles of the vertebrae.
- The C8 spinal nerve is the transition cervical spinal nerve. The C8 nerve exits through the intervertebral foramen inferior to the C7 pedicle. Remember that there are eight cervical nerves but seven cervical vertebrae.
- All remaining spinal nerves beginning at T1 and below pass through the intervertebral foramen inferior to the pedicles.

Please visit us at www.Groupinsiders.com

© DeVry/Becker Educational Development Corp. All rights reserved.

1 Introduction

The nervous system is divided structurally into a *central nervous system* (CNS) formed by the brain and spinal cord, and a *peripheral nervous system* (PNS) consisting of spinal nerves, cranial nerves, and their attached ganglia. Ganglia are defined as a collection of nerve cell bodies in the PNS, and are divided into two types: *sensory* and *motor* (discussed later).

Functionally, the nervous system is also divided into the *somatic* and *visceral nervous systems*. The somatic pathways mediate voluntary functions, including (1) the innervation of skeletal muscles and (2) conscious sensations from peripheral receptors in skin, muscles, tendons, and capsules.

In contrast, visceral pathways of the *autonomic nervous system* (ANS), for the most part, mediate involuntary motor (smooth and cardiac muscle and glands) and sensory innervation from visceral structures. Both the somatic and visceral systems use efferent (motor) and afferent (sensory) neurons.

1.1 Functional Organization of the Autonomic Nervous System

The ANS provides visceral innervation to visceral structures and systems of the body to control and regulate internal homeostasis. It consists of circuits located within both the central nervous system and the peripheral nervous system.

USMLE® Key Concepts

For Step 1, you must be able to:

- Explain the functional organization and functions of the autonomic nervous system (ANS).
- Identify the two types of visceral motor neurons of the ANS, their locations, and distributions.
- List the different types of ganglia and their role in the peripheral and autonomic nervous system.
- Describe the general organization and distributions of the sympathetic and parasympathetic nervous systems.

Connection to Neuroscience

The CNS circuits of the ANS will be reviewed in the neuroscience section of this program.

Please visit us at www.Groupinsiders.com

© DeVry/Becker Educational Development Corp. All rights reserved.

1.2 Visceral Afferents

The cell bodies of the *visceral afferent fibers* are located in sensory ganglia of cranial nerves or in dorsal root ganglia (DRG) of spinal nerves. The visceral sensory neurons of the ANS transmit visceral sensations from sensory receptors of viscera to the CNS. Most of the visceral sensations are mainly concerned with visceral pain and pressure and visceral reflexes.

Important Concept

Visceral motor fibers of the ANS innervate three main targets: cardiac muscle, smooth muscle and glands.

1.3 Visceral Motor

The *visceral efferent* pathways of the ANS consist of a sequence of two motor neurons that course between the CNS and the targets of the ANS (*smooth muscle, cardiac muscle,* and *secretomotor to glands*). The first, the *preganglionic neuron,* and the second, the *postganglionic neuron,* course through the PNS to reach their targets.

- *Preganglionic neurons* have their cell bodies *located in the CNS*. The axons exit the CNS and course with either spinal or cranial nerves in the peripheral nervous system. These axons will synapse on the postganglionic neurons within motor ganglia.
- *Postganglionic neurons* have their cell bodies *located in motor (autonomic) ganglia* within the PNS. The axons of these neurons leave the motor ganglia and continue peripherally to reach the targets.

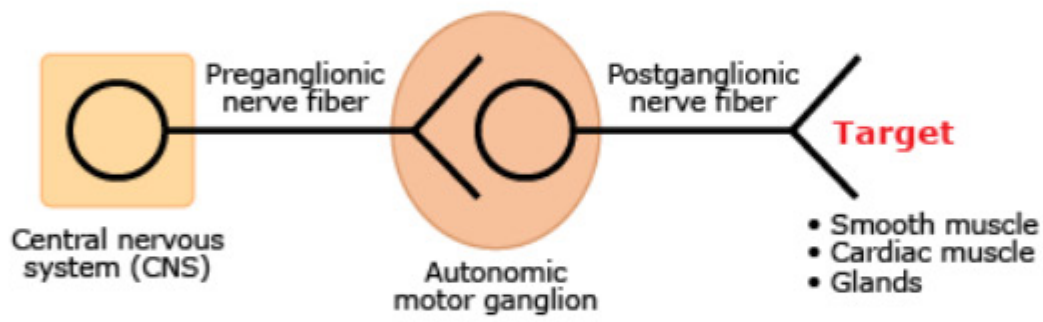

▲ **Figure 6–1.3** Neurons of the Autonomic Nervous System

1.4 Ganglia

Ganglia are a collection of neuron cell bodies of common function in the PNS and are divided into two types.

1. **Sensory Ganglia:** Contain pseudounipolar neuron cell bodies with no synapse:
   - **a.** Spinal nerves—dorsal root ganglia
   - **b.** Cranial nerves—named for each CN
2. **Motor Autonomic Ganglia:** Contain postganglionic neuron cell bodies of the ANS with a synapse:
   - **a.** Chain (paravertebral)—Sympathetic
   - **b.** Collateral (prevertebral)—Sympathetic
   - **c.** Terminal—Parasympathetic

Please visit us at www.Groupinsiders.com

© DeVry/Becker Educational Development Corp. All rights reserved.

1.5 Comparisons of Somatic and Visceral Neurons

In comparison, the *somatic motor pathway* (GSE) of peripheral nerves consists of a single efferent neuron, with its cell body located in the CNS and its axon coursing in the PNS to innervate skeletal muscles at the motor end plate.

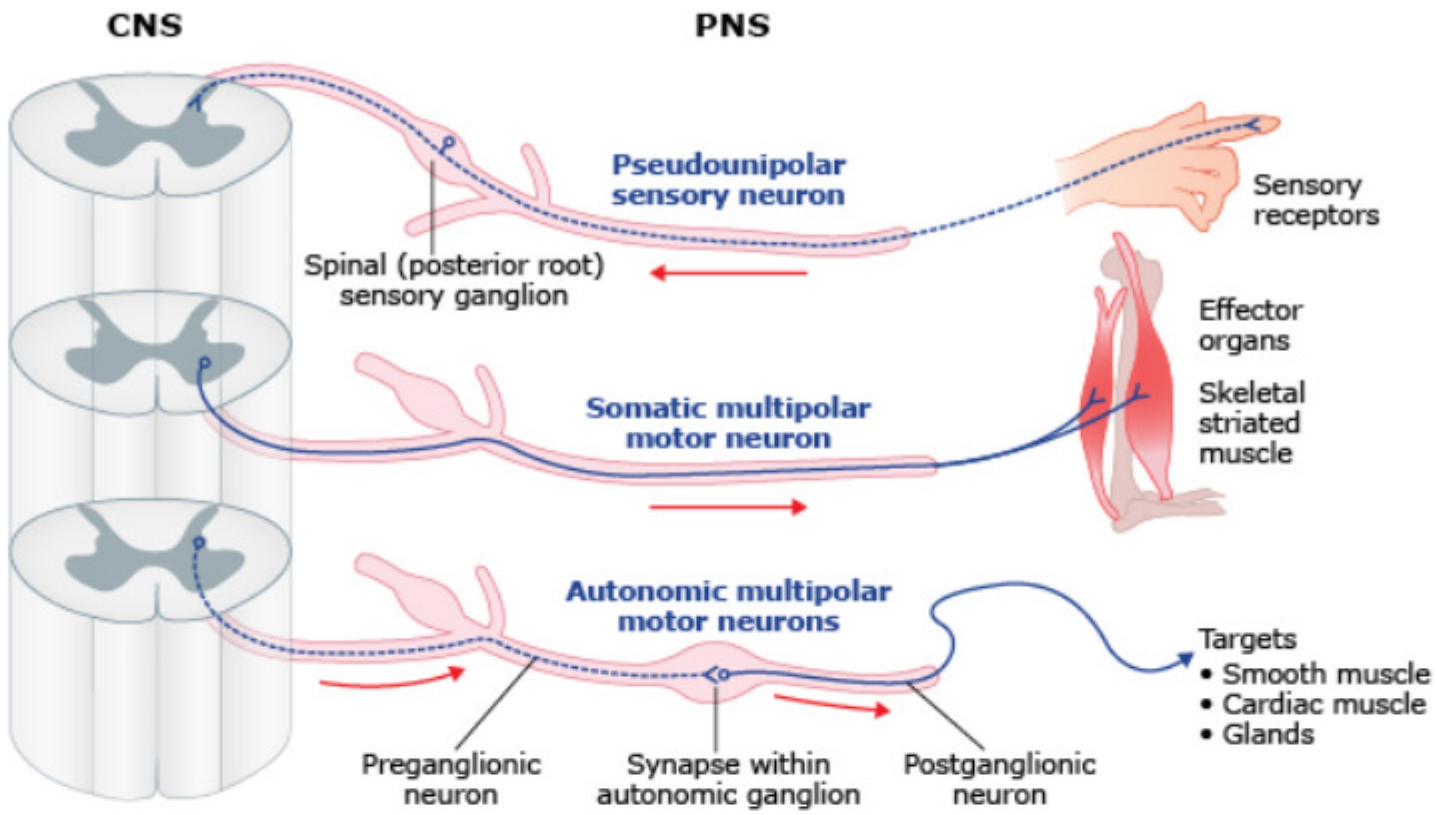

▲ **Figure 6–1.5** Comparison of Somatic and Visceral Neurons

Please visit us at www.Groupinsiders.com

© DeVry/Becker Educational Development Corp. All rights reserved.

2 Divisions of the ANS: Sympathetic and Parasympathetic Nervous Systems

Visceral motor innervation provided by the ANS is subdivided into two components: *sympathetic* (thoracolumbar outflow) and *parasympathetic* (craniosacral outflow) *nervous systems*. These two systems provide visceral motor innervation to three main targets: smooth muscle, cardiac muscle, and glands.

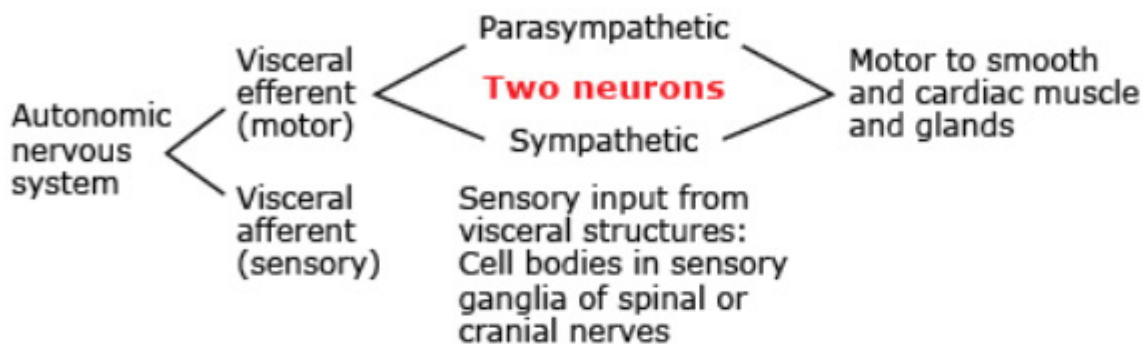

▲ **Figure 6–2.0** Overview of Autonomic Nervous System

The sympathetic and parasympathetic systems differ in organization, location of preganglionic and postganglionic nerve cell bodies, neurotransmitters, and function. Many, but not all, visceral targets innervated by the ANS receive both sympathetic and parasympathetic fibers.

2.1 Sympathetic Nervous System

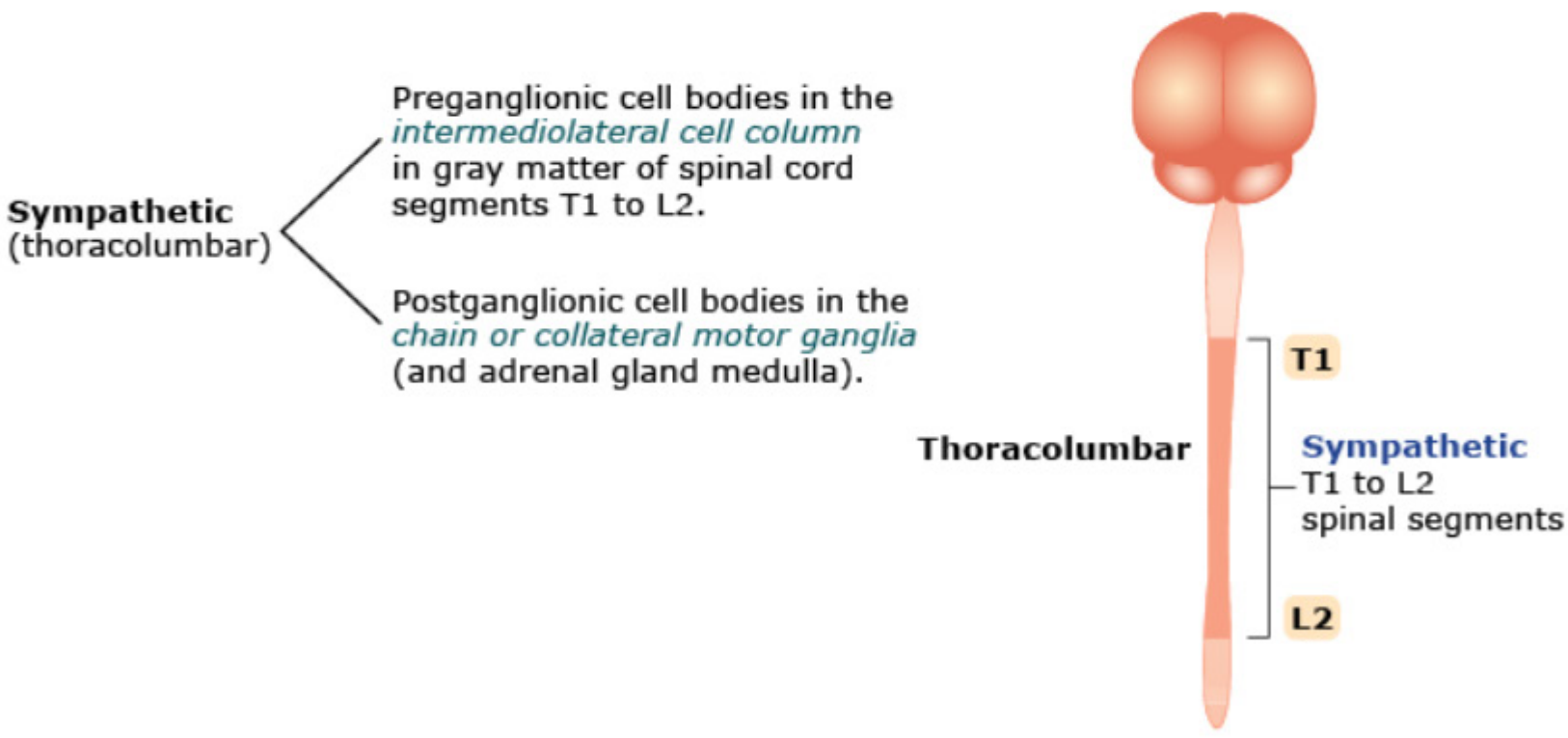

▲ **Figure 6–2.1A** Sympathetic Nervous System

Please visit us at www.Groupinsiders.com

© DeVry/Becker Educational Development Corp. All rights reserved.

The sympathetic nervous system supplies visceral structures located throughout the body in the skin and deeper visceral systems of the body. The sympathetic motor system is often described as providing *fight or flight*, or catabolic functions necessary to prepare the body for immediate energy and emergencies.

- The *sympathetic preganglionic nerve cell bodies* are located in the *lateral horn gray matter of the thoracic and upper two lumbar spinal cord segments* (T1–L2). These axons pass through ventral roots, spinal nerves, and white rami communicantes to enter the sympathetic chain ganglia.
- The sympathetic postganglionic nerve cell bodies are located in one of two types of motor ganglia in the PNS:
  1. *Chain (Paravertebral) Ganglia*: Located on the sympathetic chain.
  2. *Collateral (Prevertebral) Ganglia*: Found below the diaphragm in the abdominal and pelvic cavities.

The general distribution of the sympathetic nervous system is summarized in Table 6–2.1 and Figure 6–2.1B.

Important Concept

Lumbar splanchnic and thoracic splanchnic nerves do not synapse in sympathetic chain ganglia but continue beyond the chain ganglion as splanchnic nerves that synapse in collateral ganglia.

▼Table 6–2.1 Distribution of Sympathetic (Thoracolumbar) Nervous System

Preganglionic Cell Bodies (CNS)	Postganglionic Cell Bodies (Ganglia)	Innervation—Target
Spinal cord segments T1–L2	Chain (paravertebral ganglia)	Smooth muscle and glands of *body wall and limbs*
Spinal cord segments T1–T2	Chain (paravertebral ganglia)	Smooth muscle and glands of *head*
Spinal cord segments T1–T5	Chain (paravertebral ganglia)	Smooth and cardiac muscle and glands of *thoracic viscera*
Thoracic splanchnic nerves T5–T12	Collateral (prevertebral) ganglia (celiac, superior mesenteric, aorticorenal)	Smooth muscle and glands of *foregut and midgut*
Lumbar splanchnic nerves L1–L2	Collateral (prevertebral) ganglia (inferior mesenteric and pelvic ganglia)	Smooth muscle and glands of *pelvic viscera and hindgut*

Four patterns (regions) of sympathetic innervation:

1. To visceral structures of body wall of limbs, trunk and neck
2. To visceral structures of head
3. To viscera of thorax
4. To viscera of abdomen and pelvis

Chain (paravertebral) ganglia

Collateral (prevertebral) ganglia

Please visit us at www.Groupinsiders.com

© DeVry/Becker Educational Development Corp. All rights reserved.

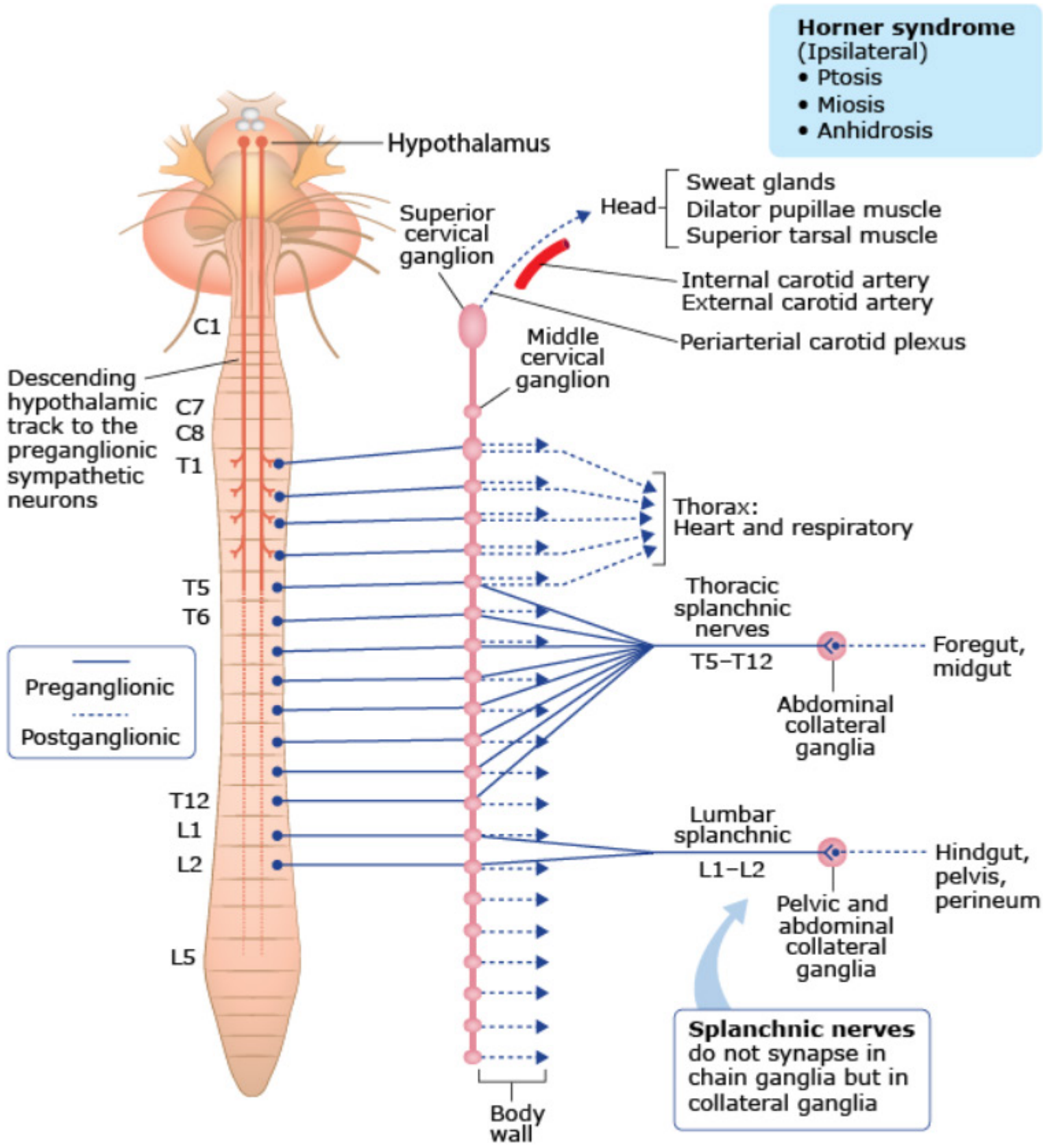

The **preganglionics** derive from T1–L2. The **postganglionics** leave sympathetic chain in all 31 gray rami to rejoin spinal nerves for distribution to body wall and limbs.

▲ **Figure 6–2.1B** Sympathetic Pathways

Please visit us at www.Groupinsiders.com

© DeVry/Becker Educational Development Corp. All rights reserved.

Once preganglionic sympathetic fibers enter the sympathetic chain ganglia via the white rami communicantes, these preganglionics have three ways to synapse with postganglionics:

1. Synapse in the chain ganglia at the level where they enter.
2. Ascend or descend the chain and synapse at higher or lower chain ganglia.
3. Pass through the chain ganglia *without synapse* to become *preganglionic splanchnic nerves*, which leave the sympathetic chain and synapse in collateral ganglia in the abdomen or pelvis. Two major splanchnic nerves of the sympathetic nervous system are the:
   - Thoracic splanchnic nerves (T5–T12)
   - Lumbar splanchnic nerves (L1–L2)

Important Concept

T1—L2 preganglionic sympathetic fibers enter the sympathetic chain ganglia via white rami communicans. The fibers can synapse at their level of entry or ascend or descend the chain and synapse at another level or pass through sympathetic chain without synapse as a splanchnic nerve.

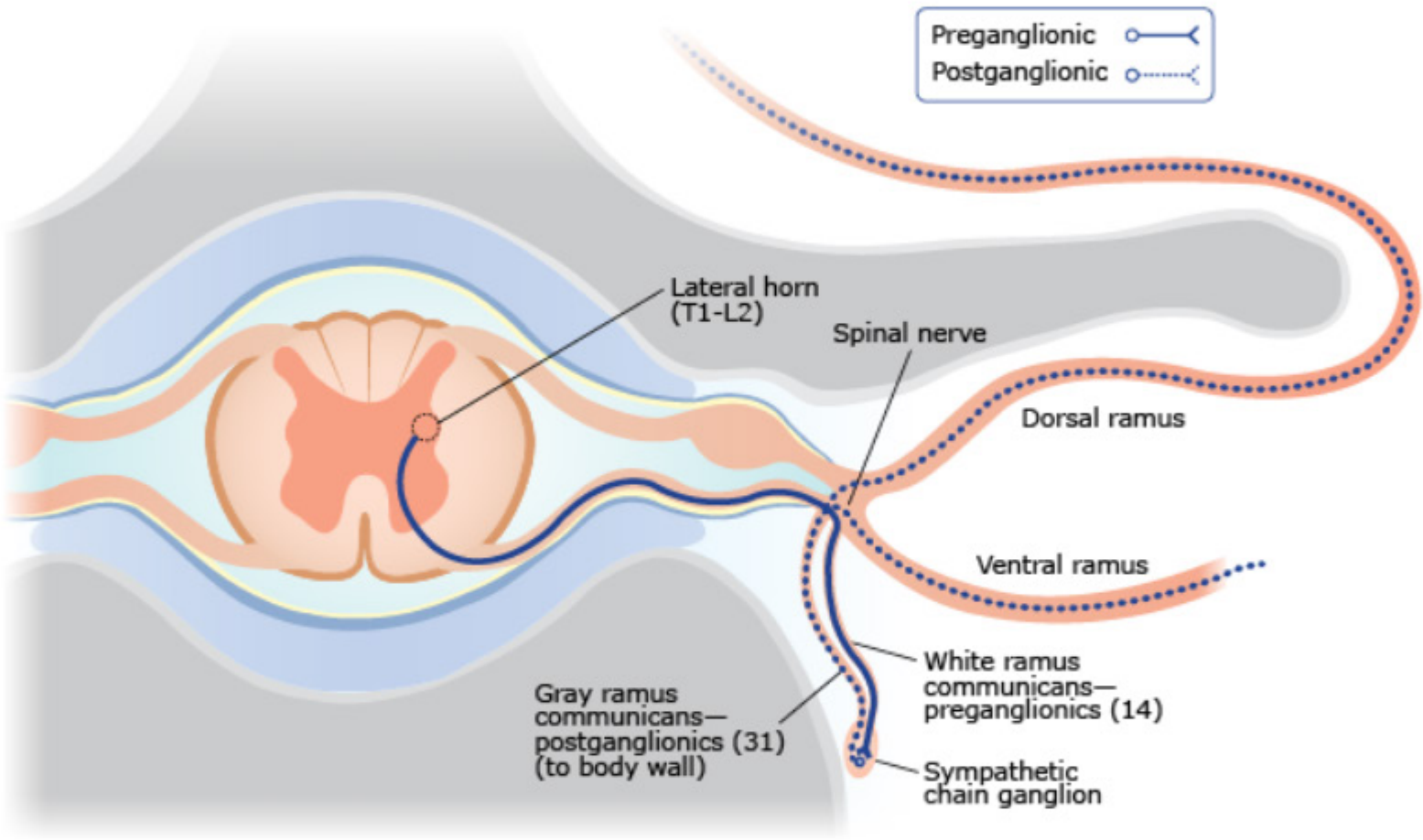

▲ **Figure 6–2.1C** Sympathetic Outflow From Spinal Cord

Please visit us at www.Groupinsiders.com

© DeVry/Becker Educational Development Corp. All rights reserved.

2.2 Parasympathetic Nervous System

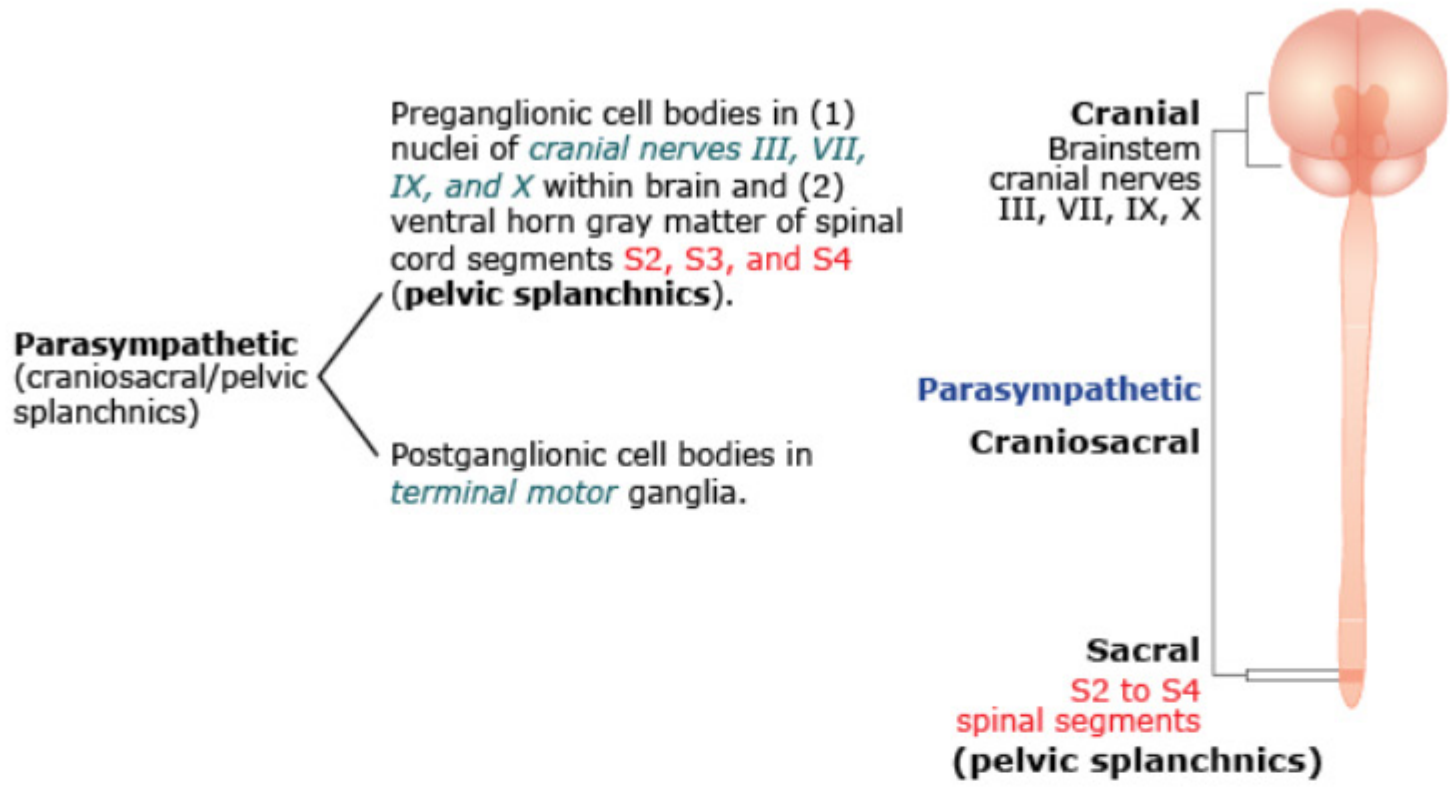

▲ **Figure 6–2.2A** Parasympathetic Nervous System Overview

The *parasympathetic nervous system* supplies visceral structures of the body except for the body wall and limbs (sympathetic only). The parasympathetic motor system functions primarily in normal maintenance of visceral systems and conserving energy.

- The *parasympathetic preganglionic nerve cell bodies* are located in two sites within the central nervous system:
  - Brainstem: Specifically in the parasympathetic nuclei of four cranial nerves: III, VII, IX, and X
  - Spinal Cord Segments: *S2*, *S3*, and *S4* (pelvic splanchnics)
- The *parasympathetic postganglionic nerve cell bodies* are located in terminal motor (terminal) ganglia within the PNS. *Terminal ganglia* are usually found on the surface of the viscera or embedded in the wall of the viscera innervated. Also, there are four parasympathetic motor ganglia in the head associated with cranial nerves III, VII, IX, and X.

The general distribution of the parasympathetic nervous system is summarized in Table 6–2.2 and Figure 6–2.2B.

▼ **Table 6–2.2** Distribution of the Parasympathetic (Craniosacral) Nervous System

Preganglionic Cell Bodies (CNS)	Postganglionic Cell Bodies (Ganglia)	Innervation–Target
Cranial nerves III, VII, IX	Four motor ganglia of head (ciliary, submandibular, pterygopalatine, otic)	Smooth muscle and glands of *head*
Cranial nerve X	Terminal ganglia (within wall or on surface of viscera)	Smooth and cardiac muscle and glands of *thoracic, foregut,* and *midgut* viscera
Pelvic splanchnic nerves S2, S3, S4	Terminal ganglia (within wall or on surface of viscera or scattered in pelvic floor)	Smooth muscle and glands of *pelvic viscera* and *hindgut*

Please visit us at www.Groupinsiders.com

© DeVry/Becker Educational Development Corp. All rights reserved.

Three patterns (regions) of parasympathetic innervation:

1. To visceral structures of head
2. To viscera of thorax and upper abdomen
3. To viscera of lower abdomen and pelvis

Terminal ganglia

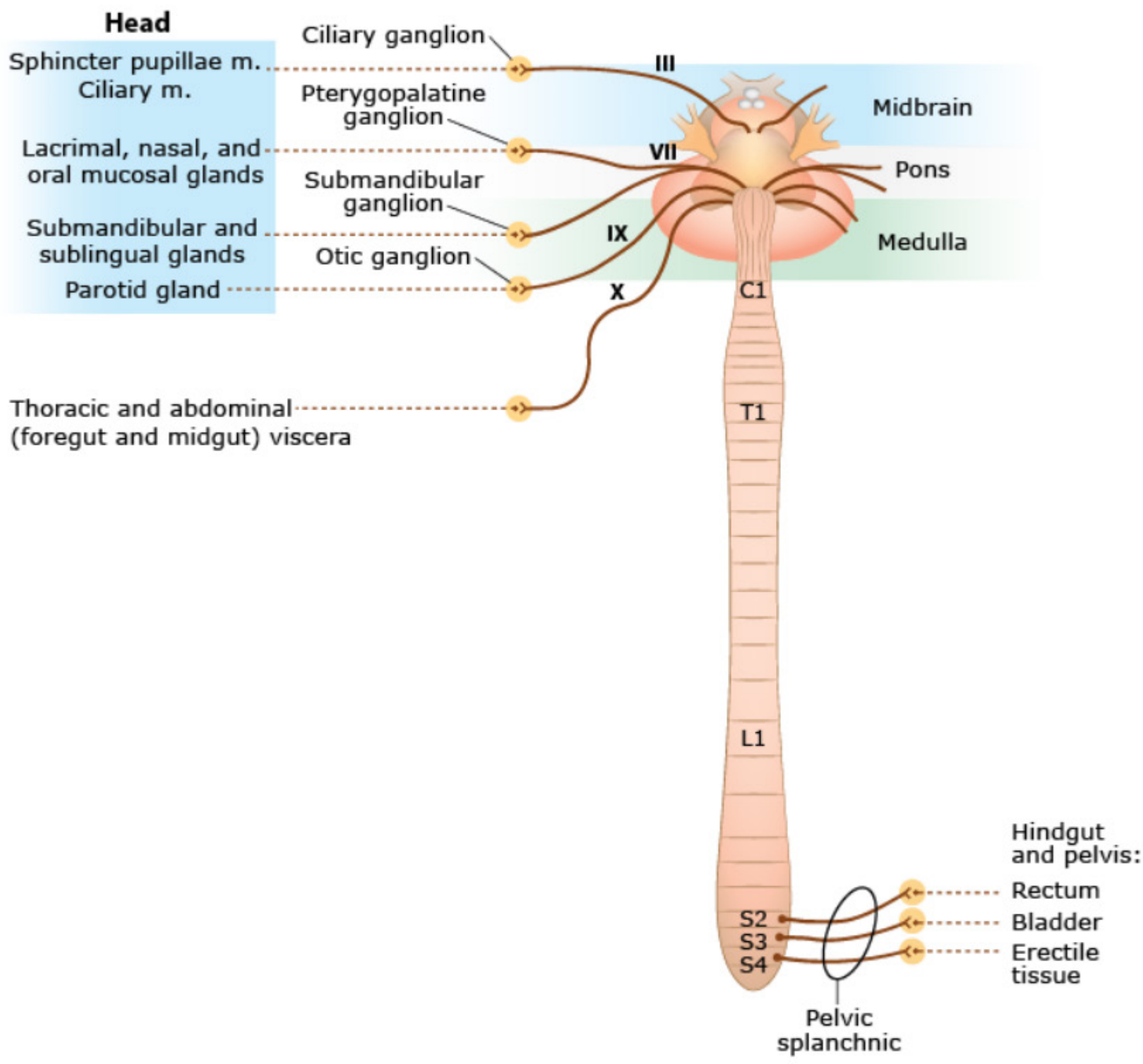

▲ **Figure 6–2.2B** Parasympathetic Nervous System

Please visit us at www.Groupinsiders.com

© DeVry/Becker Educational Development Corp. All rights reserved.

Review Questions Chapters 5–6

1. A patient admitted to a hospital is thought to have meningitis. A lumbar puncture is performed. When obtaining a sample of cerebrospinal fluid, where should the tip of the needle be placed?

A. Immediately deep to the posterior longitudinal ligament
B. Immediately superficial to the ligamentum flavum
C. In the epidural space
D. Between ligamentum flavum and dura mater
E. Immediately deep to the arachnoid membrane

2. A 45-year-old patient is admitted to the hospital following sever back trauma resulting in severe pain in the back and upper limb. Radiographic images indicate a herniated nucleus pulposus of the intervertebral disk between the C5 and C6 vertebrae. Which of the following is the most likely condition that would be seen in the patient?

A. Altered sensation in the C5 dermatome
B. Weakness of muscles innervated by the C7 spinal cord segment
C. Weakness of muscles innervated by the C5 spinal cord segment
D. Altered sensation in the C6 dermatome
E. Damage to the sympathetic innervation to the thorax

3. A 25-year-old male is brought to the emergency room following a car accident, which crushed the lumbar region of his back. In a few days the patient presents with an atonic bladder (inability to contract the bladder). Which of the following possibly could have been damaged as a result of the injury?

A. Lumbar chain ganglia
B. Lower lumbar cord segments
C. S2, S3, and S4 cord segments
D. Collateral (prevertebral) pelvic ganglia
E. Vagus nerve

Please visit us at www.Groupinsiders.com

© DeVry/Becker Educational Development Corp. All rights reserved.

Chapters 5–6 Review Questions

4. A patient presents with metastatic carcinoma, which has resulted in massive enlargement of the lymph nodes along the carotid sheath, causing compression of the adjacent sympathetic chain. Compression of the cervical sympathetic chain would more likely damage which of the following types of sympathetic fibers?

A. Ascending postganglionic fibers from upper thoracic spinal cord segments
B. Ascending preganglionic fibers from upper thoracic spinal cord segments
C. Ascending preganglionic fibers from L1 and L2 cord segments
D. Descending preganglionic fibers from upper cervical spinal cord segments
E. Descending postganglionic fibers from upper cervical spinal cord segments

5. A 55-year-old female goes to her physician because of a painful eye. The examination reveals a dry cornea with ulcerations due to a loss of lacrimation. Assuming that the dry cornea is due to damage to postganglionic autonomic fibers that supply the lacrimal gland, which of the following nerve structures is damaged?

A. Vagus nerve
B. Pterygopalatine ganglion
C. Glossopharyngeal nerve
D. Otic ganglion
E. Oculomotor nerve

Please visit us at www.Groupinsiders.com

© DeVry/Becker Educational Development Corp. All rights reserved.

Review Answers Chapters 5–6

1.The correct answer is E. When performing a lumbar puncture, the needle passes through the superficial tissues, the ligamentum flavum, the epidural space, and then through the dura mater and arachnoid to enter the subarachnoid space where the CSF is located.

2. The correct answer is D. In the cervical and the lumbar regions, the nucleus pulposus will protrude posterolaterally and compress the spinal nerve roots numbered one number below the herniated disk. Thus, with disk herniation between the C5 and C6 vertebrae, the C5 disk will compress the C6 nerve roots affecting the motor and sensory functions of that nerve.

3. The correct answer is C. The accident compressed sacral cord segments 2, 3, and 4, which give origin to the pelvic splanchnic nerves. The pelvic splanchnics are preganglionic parasympathetic nerves which synapse on postganglionic neurons in pelvic ganglia. These postganglionic fibers provide innervation to the smooth muscle fibers (detrusor muscle) in the wall of the urinary bladder that are responsible for emptying the bladder during micturition.

4. The correct answer is B. The sympathetic chain is involved in distributing fibers to the targets of the sympathetic nervous system. The sympathetic fibers within the cervical chain are primarily ascending preganglionic fibers that reach one of the three cervical chain ganglia, where they synapse with postganglionic neurons. These postganglionic fibers are mostly destined for body wall, thorax, and head targets.

5. The correct answer is B. The seventh cranial nerve has two parasympathetic pathways that provide secretomotor innervation to glands in the head primarily involved with salivation (submandibular and sublingual glands) and lacrimation. For lacrimal gland innervation, preganglionic parasympathetic fibers of CVII will synapse with postganglionic neurons in the pterygopalatine ganglion, which then supply the lacrimal gland and other glands of the oral and nasal mucosa.

Please visit us at www.Groupinsiders.com

© DeVry/Becker Educational Development Corp. All rights reserved.

1 Thoracic Wall

1.1 Skeleton of the Chest Wall

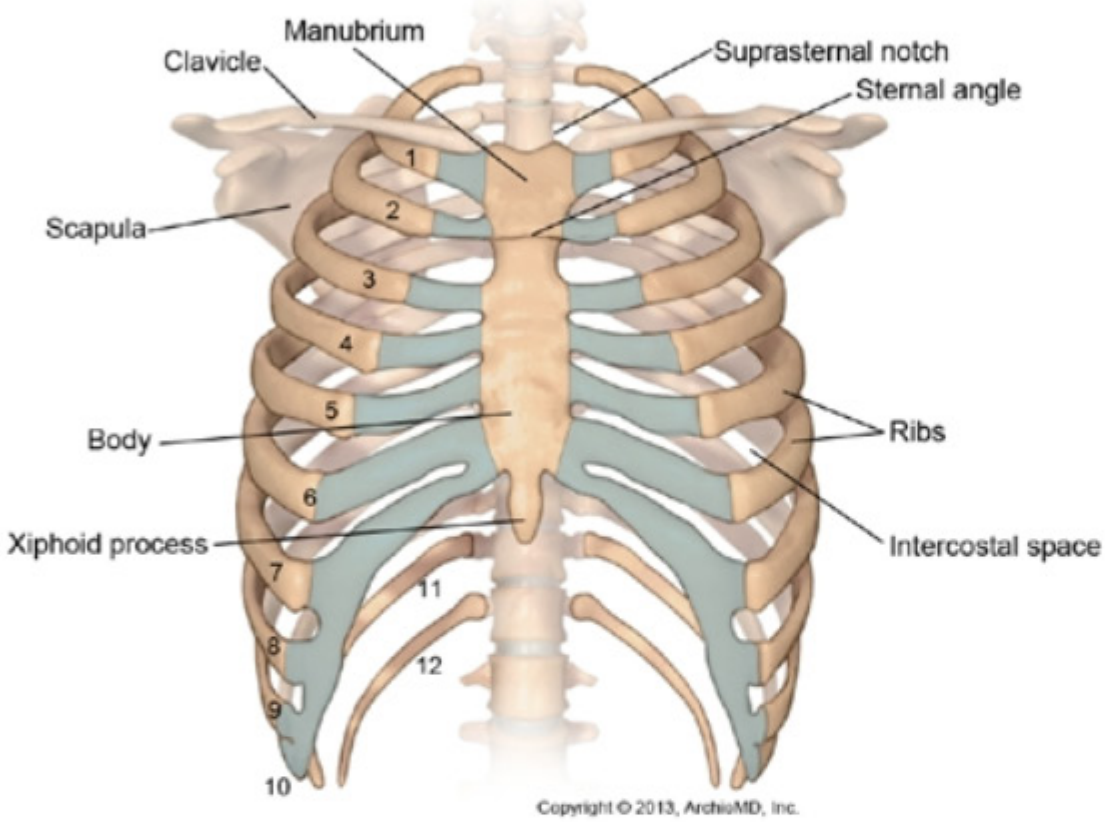

▲ **Figure 7–1.1** Thoracic Wall

- The skeleton of the chest wall includes 12 pairs of ribs, 12 thoracic vertebrae, and the sternum.
- Ribs 1–7 are true ribs, with direct attachment to the sternum; ribs 8–10 are false ribs, with indirect attachments to the sternum; and ribs 11–12 are floating ribs that do not connect to the sternum.
- The *sternal angle of Louis* is located at the junction of the manubrium and body of the sternum (second rib) and provides an important landmark on the anterior chest wall. It is located at the horizontal plane that passes posteriorly through the disk between the T4 and T5 vertebrae. Several anatomical landmarks are found at the plane of the sternal angle:
  - It is where the second rib attaches to the sternum.
  - It is the level where the trachea bifurcates into the right and left primary bronchi.
  - The aortic arch begins and ends at this level.
- The *superior thoracic aperture* connects the thoracic cavity with the neck. It is bounded by the first rib, superior surface of the manubrium, and the T1 vertebra.
- The *inferior thoracic aperture* is closed by the diaphragm.

USMLE® Key Concepts

For Step 1, you must be able to:

- Identify the thoracic cavity and its compartments in cross-sectional images.
- Describe the lymphatics draining the mammary gland and their role in metastatic disease.
- Explain the development of the respiratory system and birth defects of the lungs.
- Identify the pleural membranes and their relationship to the lungs.
- Explain the external features of the heart and how they relate to radiology.
- Describe the arterial and venous circulation of the heart and the various heart defects of the atria, ventricles, and great vessels.

Please visit us at www.Groupinsiders.com

© DeVry/Becker Educational Development Corp. All rights reserved.

1.1.1 Intercostal Spaces

There are 11 intercostal spaces located between the ribs of the chest wall.

- Each typical space contains three layers of intercostal muscles with their fascia.
- On the inferior border of the ribs, the *costal groove* contains the *intercostal nerve* and *vessels*. The intercostal veins are inferior, and the nerves are superior.
- The costal groove is located at the upper aspect of the intercostal spaces (the lower margin of the ribs). A nerve block is done at the *upper part* of the space close to the nerve. However, instruments are inserted through the *lower part* of the space to avoid damage to the nerve and vessels.
- The 11 intercostal nerves are the ventral rami of the T1–T11 thoracic spinal nerves. The subcostal nerve is the ventral ramus of T12. These nerves innervate the muscles of the anterolateral chest and abdominal wall.
- Blood supply to the intercostal spaces is provided anteriorly by the internal thoracic artery and posteriorly primarily from the descending aorta.

Important Concept

To prevent damage to the intercostal nerve, surgical procedures are done at the lower part of the intercostal space. For anesthesia, a nerve block is done at the upper aspect of the intercostal space.

1.2 Thoracic Cavity

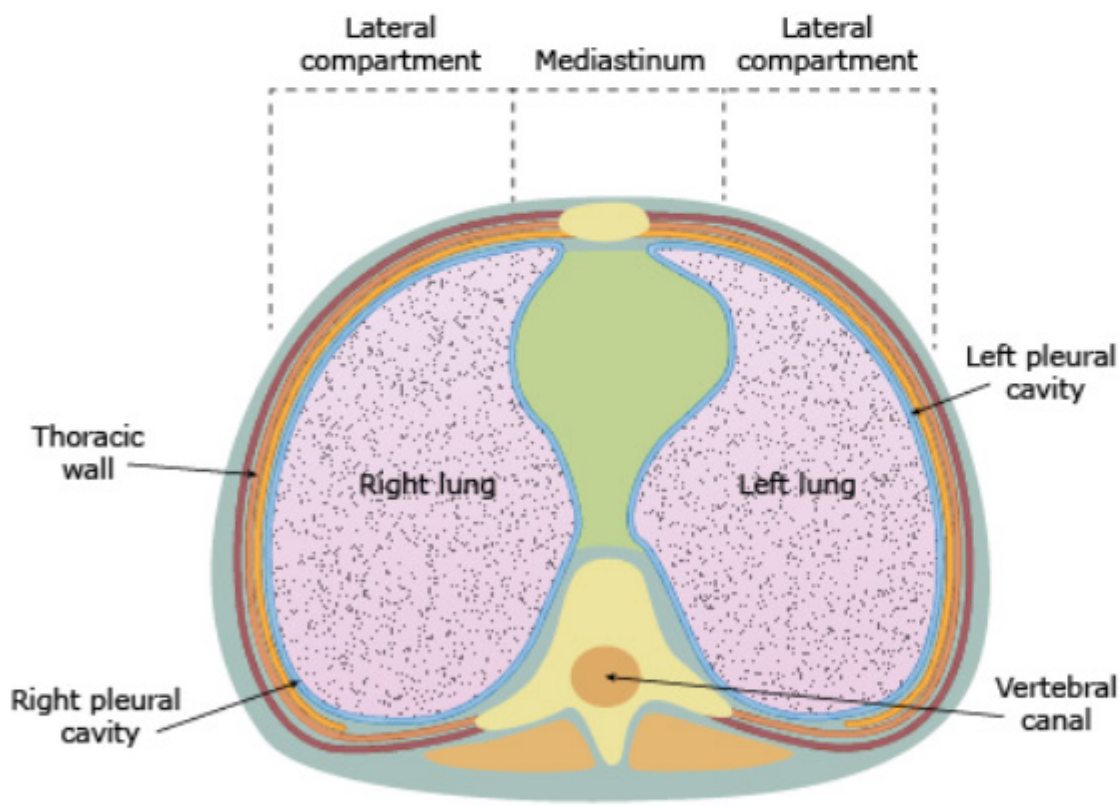

▲ **Figure 7–1.2** Thoracic Cavity

The *thoracic cavity* is the space enclosed by the chest wall. It is divided into *three compartments*: two *lateral compartments* containing the lungs and pleura, and a *central compartment*, called the *mediastinum*, that houses the major thoracic viscera except for the lungs. The mediastinum is located in the midline between the two lungs and extends from the superior thoracic aperture to the diaphragm (discussed later).

Please visit us at www.Groupinsiders.com

© DeVry/Becker Educational Development Corp. All rights reserved.

1.3 Mammary Gland

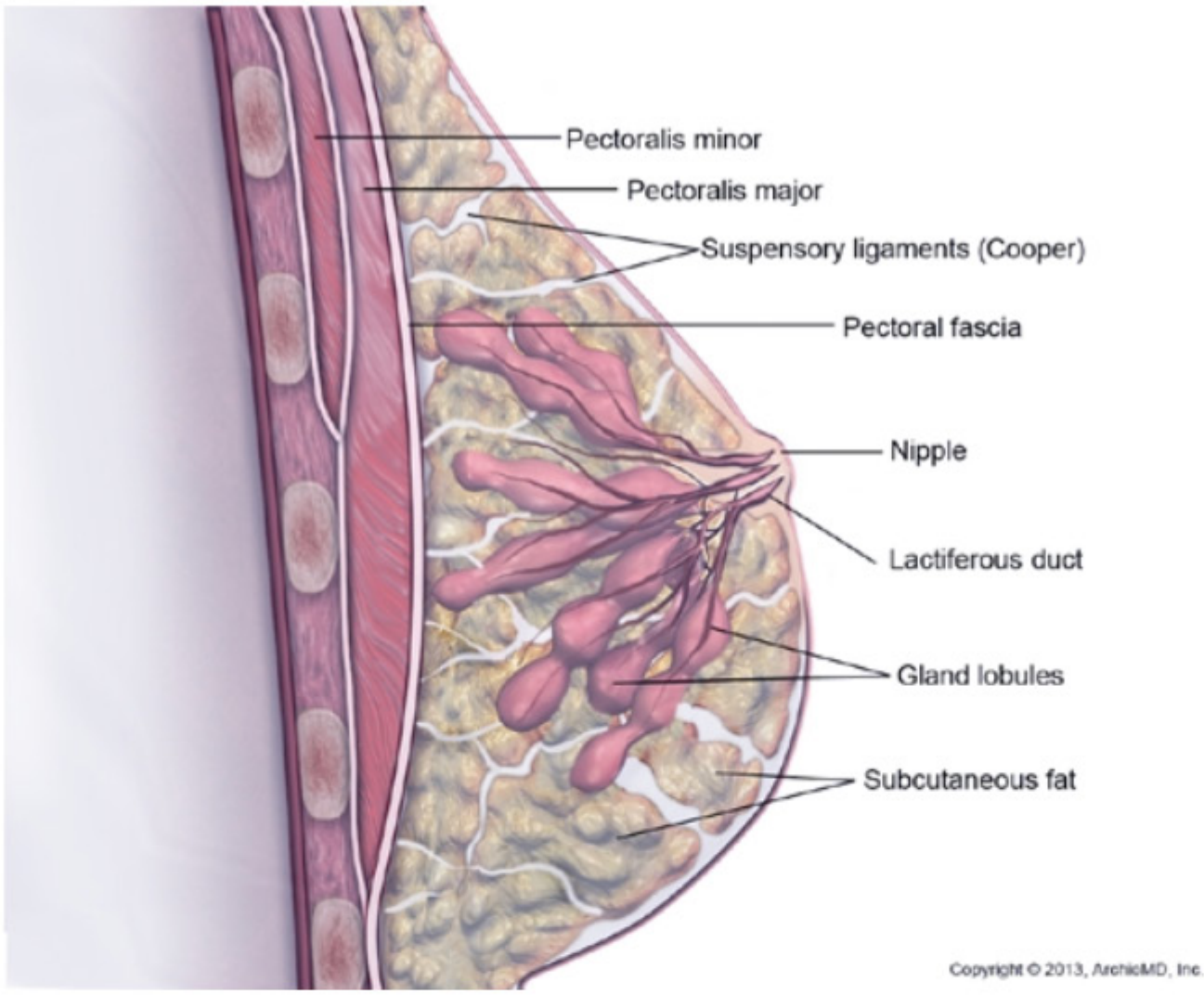

▲ **Figure 7–1.3** Mammary Gland

The breasts are modified sweat glands that lie in the superficial fascia of the anterior chest wall overlying the second to the sixth ribs. The mammary glands are divided into upper, lower, lateral, and medial quadrants.

- *Suspensory ligaments* (of Cooper) firmly attach the gland to the skin and support the breast. Tumors of the breast put tension on the Cooper ligaments resulting in *dimpling of the skin* (orange peel).
- *Axillary tail* of the breast extends superolaterally into the axilla.
- Fifteen to 20 lactiferous ducts converge onto nipple (at the fourth intercostal space in both males and nulliparous, non-obese females). Most carcinomas begin in these ducts.
- Retromammary space is formed between the breast and the deep pectoral fascia. Carcinoma can invade this space.

1.3.1 Blood Supply and Lymphatics of the Breast

- Arteries:
  - Perforating branches of *internal thoracic artery*.
  - *Lateral thoracic branch* of axillary artery.

Please visit us at www.Groupinsiders.com

© DeVry/Becker Educational Development Corp. All rights reserved.

1.4 Lymphatic Drainage

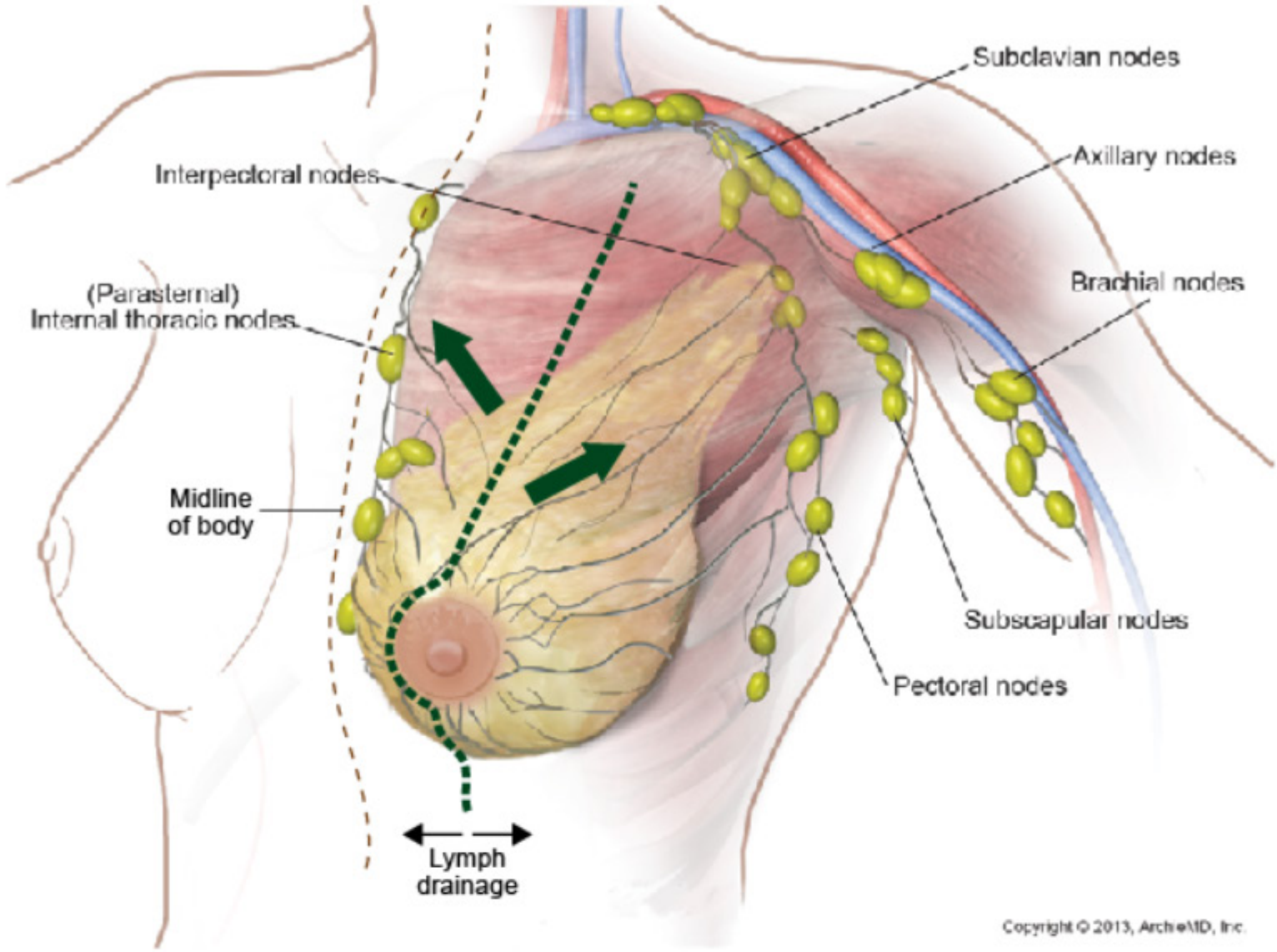

▲ **Figure 7–1.4** Lymphatics of Mammary Gland

- Facilitates metastasis of breast cancer.
- Lymphatic drainage of the lateral three fourths of the breast is to the *axillary lymph nodes*. The first nodes to receive lymphatic drainage are the pectoral nodes.
- The *medial one fourth* of the gland drains to the *parasternal nodes*.
- Lymphatics may cross the midline to the opposite breast.
- Cancer develops more often in the upper lateral aspect of the breast.

Clinical Application

The lateral thoracic artery supplies the lateral aspect of the gland. The vessel courses on the lateral thoracic wall with the *long thoracic nerve* (innervates the *serratus anterior muscle*) and close to the thoracodorsal nerve (innervates the *latissimus dorsi* muscle). During a mastectomy, damage to these nerves can produce winged scapula (long thoracic nerve) and weakness in the extension and medial rotation of the arm (thoracodorsal nerve).

Please visit us at www.Groupinsiders.com

© DeVry/Becker Educational Development Corp. All rights reserved.

2 Lungs and Pleurae

2.1 Development of the Lower Respiratory Tract

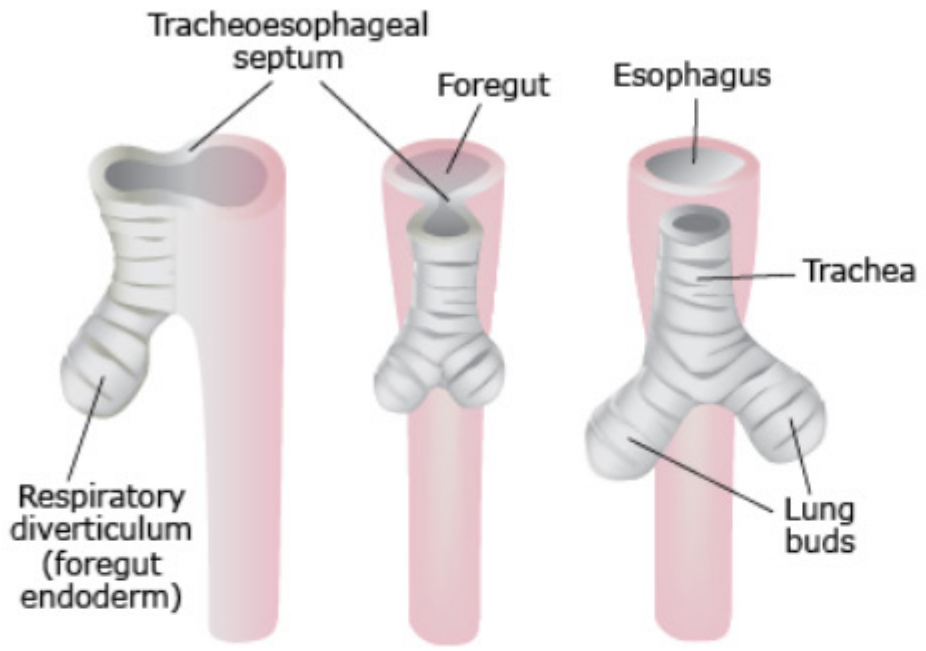

▲ **Figure 7–2.1A** Development of Trachea and Lungs

The lower respiratory system begins its development in the fourth week from a single *respiratory diverticulum* of *endoderm* from the ventral surface of the *esophagus* (foregut).

- The respiratory diverticulum lengthens to form the *lung bud*.
- The lung bud then bifurcates into two *bronchial (lung) buds*. The bronchial buds continue to divide through a series of divisions over time to develop into the respiratory tree.
- By the 25th week, 17–18 generations of branching have occurred. Type I and Type II pneumocytes are developed and are able for gas exchange and production of surfactant by the *25th week*.
- Since the respiratory system develops from the foregut, initially there is an open communication between the trachea and the foregut. This communication is closed by the growth of a mesodermal septum called the *tracheoesophageal septum*.

Important Concept

Endoderm of foregut forms the lower respiratory tract, liver and biliary tree, and pancreas.

Clinical Application

By weeks 25–26 of development, the lungs have developed sufficiently to be able to exchange gases, and a premature infant can survive with proper support.

Please visit us at www.Groupinsiders.com

© DeVry/Becker Educational Development Corp. All rights reserved.

Clinical Application

Tracheoesophageal Fistula

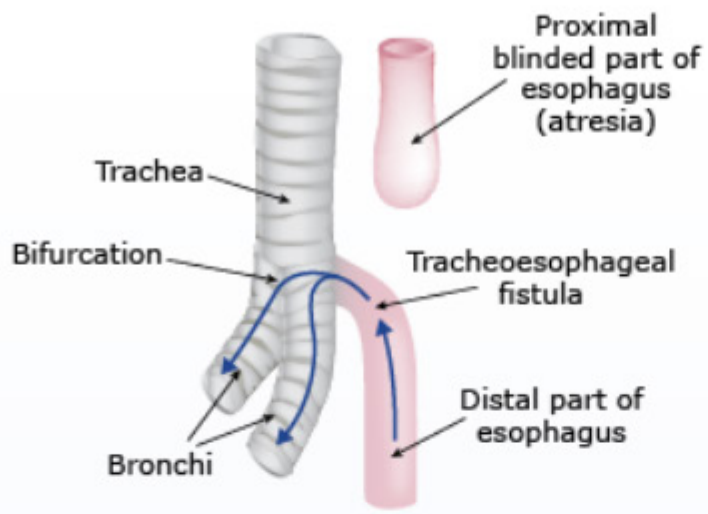

▲ **Figure 7–2.1B** Tracheoesophageal Fistula

A *tracheoesophageal fistula* is an abnormal opening that occurs between the trachea and esophagus as a result of an abnormal development of the tracheoesophageal septum. Clinical features usually include:

- Most common anomaly of the lower respiratory tract.
- More commonly affects males.
- Usually associated with esophageal atresia that results in *polyhydramnios.*
- Newborns have difficulty swallowing and regurgitate milk when fed.
- Gastric contents can reflux from the stomach through the fistula into the lungs.

Pulmonary Hypoplasia

Underdevelopment of lungs occurs with:

- Congenital diaphragmatic hernia resulting in viscera of abdomen herniating into thoracic cavity.
- Bilateral renal agenesis resulting in oligohydramnios, which causes increased pressure on the thoracic wall of the fetus and Potter sequence.

Please visit us at www.Groupinsiders.com

© DeVry/Becker Educational Development Corp. All rights reserved.

3 Serous Membranes and Pleura

In the body cavities, three double-wall serous membranes cover the lungs (*pleura*), heart (*pericardium*), and abdominal viscera (*peritoneum*). These membranes provide a mechanism of friction reduction so these viscera can move freely without damage. Each of these membranes is formed by an outer layer (*parietal*) that is continuous with the inner layer (*visceral*). Between the two layers there is thin space that contains a thin layer of serous fluid.

3.1 Pleura

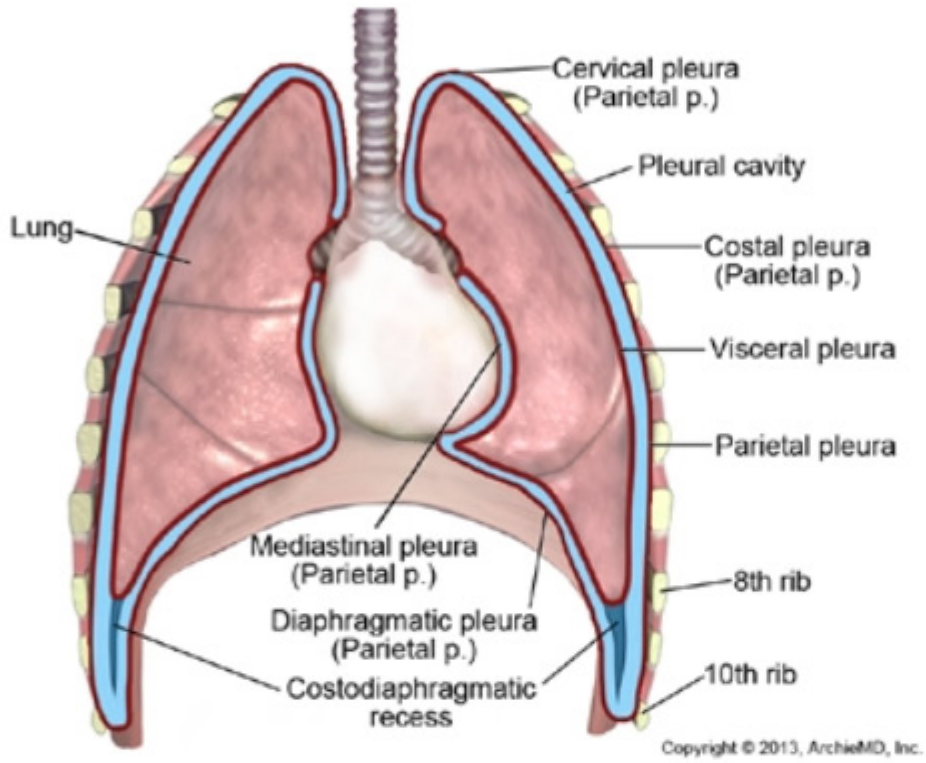

▲ **Figure 7–3.1A** Pleurae

The *pleurae* are the membranes that surround the lungs. They are found with the lungs in each of the two lateral compartments of the chest cavity.

- The *parietal pleura* is the outermost layer that lines the chest wall (costal pleura), diaphragm (diaphragmatic pleura), and mediastinum (mediastinal pleura). The apex of the lung is covered by the cervical parietal pleura, which extends superiorly into the root of the neck above the first rib. The parietal pleura reflects to become the visceral pleura at the hilum of the lung.
- The *visceral pleura* adheres tightly to all areas of the surface of the lung. It is continuous with the parietal layer at the hilum of the lung.
- The *pleural cavity* is the potential space between the parietal and visceral layers. Negative pressure develops within the pleural cavity during inspiration and keeps the lung inflated.
- The parietal pleura receives *somatic innervation* from the *intercostal nerves* (costal pleura) and *phrenic nerves* (diaphragmatic and mediastinal pleurae). These parietal pleurae are sensitive to pain.
- The visceral pleura receives innervation from *visceral sensory autonomic nerves* and is not sensitive to pain.

Please visit us at www.Groupinsiders.com

© DeVry/Becker Educational Development Corp. All rights reserved.

- *Pleural recesses* are narrow, potential spaces of the pleural cavity that the lungs do not completely descend into during quiet respiration. There are two pleural recesses:

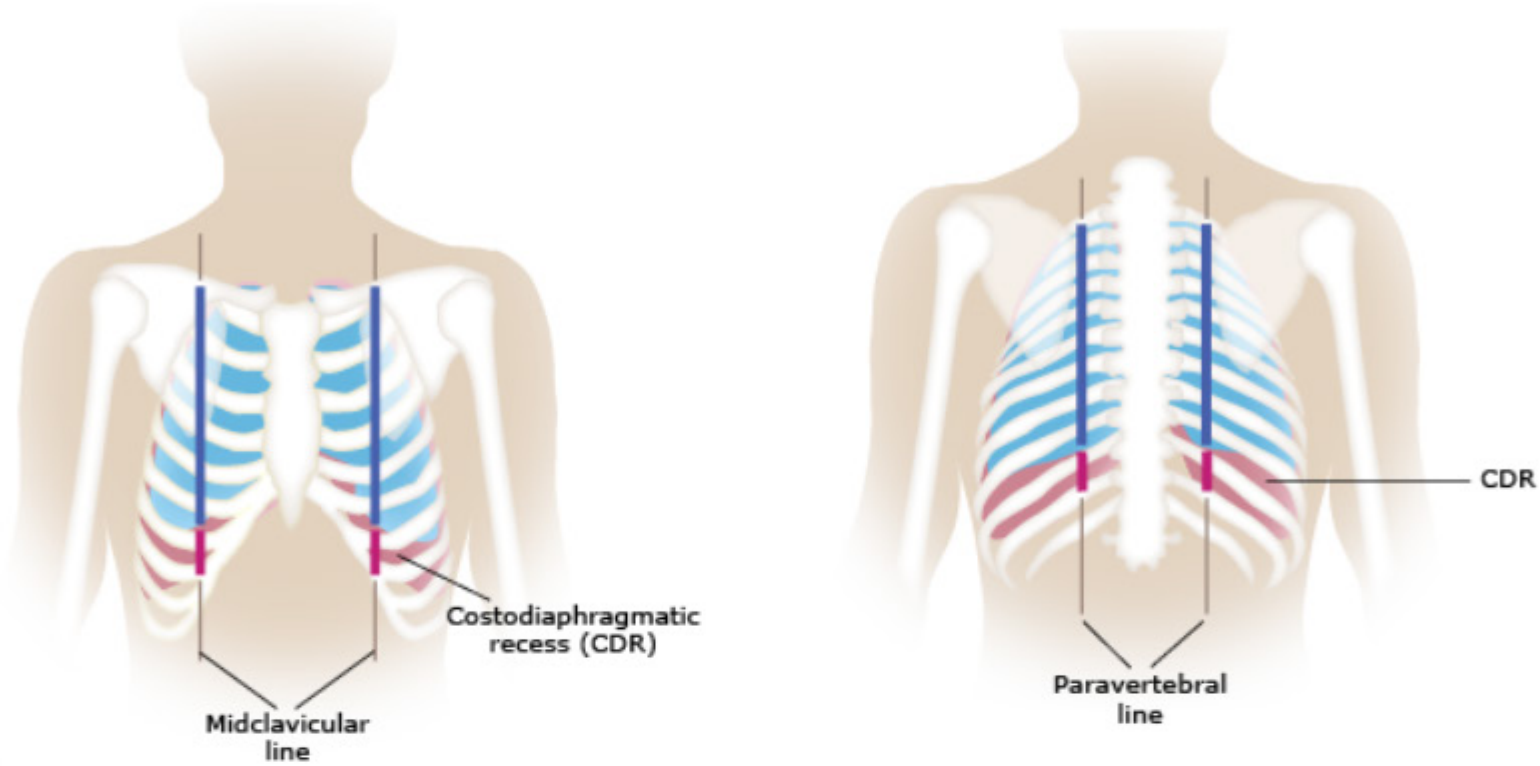

▲ **Figure 7–3.1B** Pleural Spaces

  - The *costodiaphragmatic recess* is at the base of the lung where the reflections of the diaphragmatic and costal pleurae are in contact with each other. In a vertical position, this is where excess pleural fluid collects in a patient.
  - The *costomediastinal recess* is between the reflection of the coastal and mediastinal pleurae. On the left, the lingula of the lung fills this recess during deep inspiration.

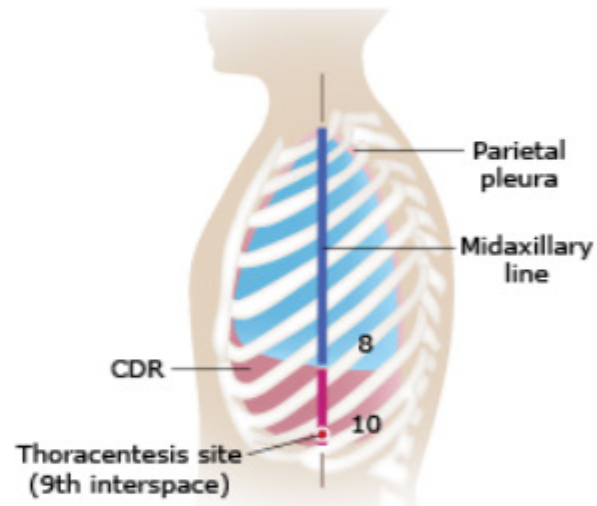

- There is a *two-rib interval* of separation between the inferior extent of the lungs, covered by visceral pleura, and the inferior extent of the parietal pleura. The relationships at the *midclavicular line*, *midaxillary line*, and *paravertebral line* in the chest wall are shown in Table 7–3.1.
- Dorsal surgical approach to the kidneys at the lower ribs may damage the pleura.

▼ **Table 7–3.1** Pleural Cavity Boundaries and Reference Points

Reference Line	Lung and Visceral Pleura	Parietal Pleura
Midclavicular line	6th rib	8th costal cartilage
Midaxillary line	8th rib	10th rib
Paravertebral line	10th rib	12th rib

Please visit us at www.Groupinsiders.com

© DeVry/Becker Educational Development Corp. All rights reserved.

Clinical Application

Pneumothorax

If air enters the pleural cavity, the negative pressure is lost, and the lungs will collapse. The patient will have compromised breathing and shortness of breath.

1. Open pneumothorax occurs when the chest wall and parietal pleura are open to the outside atmosphere following a chest wound. The negative pleural pressure is lost, and the lung on the damaged side will collapse.
   - During inspiration, air is sucked into the pleural cavity and pushes the heart and other mediastinal structures toward the opposite side, compressing the opposite lung.
   - During expiration, air is expelled through the wound and the mediastinal structures, and the opposite lung will shift back to the normal position.
2. Tension pneumothorax occurs when a piece of tissue covers the wound, allowing air to enter the pleural cavity with inspiration. Upon expiration, the inspired air is trapped and cannot escape the pleural cavity. Thus, with each inspiration, the pressure builds and pushes the collapsed lung and other mediastinal structures to the opposite side, resulting in severe decreased cardiac output and respiratory function. This type of pneumothorax can be life threatening.
3. Spontaneous pneumothorax occurs internally when a bleb on the surface of the lung ruptures, allowing air to enter the pleural space and causing collapse of the lung. The common site of spontaneous pneumothorax is on the upper lobe of the lung.

Pleurisy (Pleuritis)

- Pleurisy is inflammation of the pleural layers that can result in adhesions forming between the two layers.
- Somatic pain develops in the parietal pleura upon inspiration when tension is placed on the adhesions.
- Inflammation of the visceral layers produces no pain.
- Costal pain of the parietal layer is associated with sharp pain on the lateral chest wall when *costal pleura* is involved *(intercostal nerves)*. When the *mediastinal* and *diaphragmatic pleurae* (*phrenic nerve*; C3, C4, and C5) are involved, there is referred pain to the dermatomes of the shoulder region.

Thoracentesis

- Removal of excess pleural fluid is usually made by inserting a needle into the costodiaphragmatic recess through the eighth or ninth intercostal space at the midaxillary line. This avoids penetration of the liver and lung. The needle is inserted at the lower aspect of the intercostal space (upper border of the rib) to avoid damage to the intercostal nerves and vessels in the costal groove.

Please visit us at www.Groupinsiders.com

© DeVry/Becker Educational Development Corp. All rights reserved.

4 Lungs

Each lung has *costal*, *mediastinal*, and *diaphragmatic* surfaces. The *apex* of the lung projects into the root of the neck, and the *base* of the lung rests on the diaphragm.

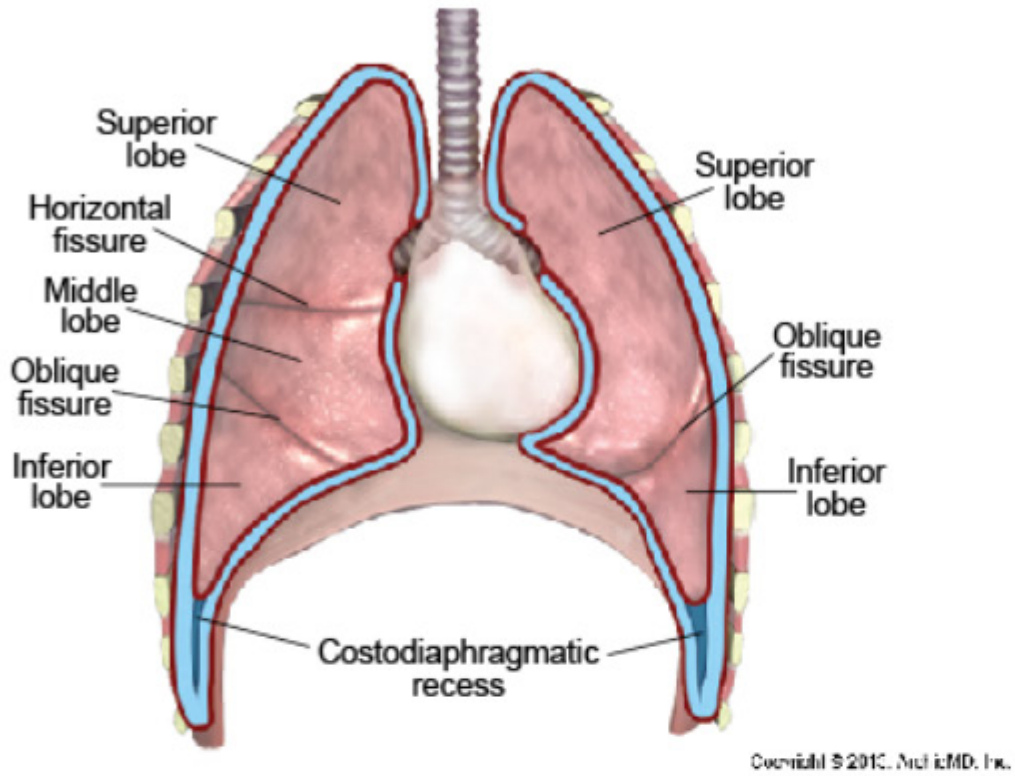

▲ **Figure 7–4.0** Lobes of Lungs

- The *hilum* of the lung is on the medial surface and is where neurovascular structures, primary bronchi, and lymphatics enter or leave the lung.
- The *right lung* is larger and is divided into three lobes (*superior*, *middle*, and *inferior*) that are separated by the *horizontal* and *oblique* fissures.
- The *left lung* is divided into two lobes separated by the *oblique fissure*. The superior lobe of the left lung contains the *lingual*, which corresponds to the middle lobe of the right lung.
- The horizontal fissure of the right lung follows the curve of the *fourth rib* and separates the *superior* and *middle lobes*. The *middle lobe* is located between the fourth and sixth ribs.
- The *oblique fissure* of both lungs courses inferiorly and anteriorly, crossing the *fifth intercostal space* in the midclavicular line, and ends medially at the costal cartilage of the *sixth rib*.
- The inferior lobe of both lungs primarily projects to the *dorsum*.

Clinical Application

Breath Sounds

- Breath sounds from the upper lobe of each lung can be auscultated on the anterior chest wall above the fourth rib.
- Breath sounds from the middle lobe on the right lung can be auscultated on the anterior chest wall below the fourth rib.
- Breath sounds from the inferior lobe of each lung can be auscultated on the posterior aspect of the back.

Foreign Object Aspiration

- When a person is vertical, an aspirated object usually drops into the *right main bronchus* and lodges in the *posterior basal bronchopulmonary segment* of the *right lower lobe*. If the person is supine, the object usually falls into the superior bronchopulmonary segment of the right lower lobe.

Please visit us at www.Groupinsiders.com

© DeVry/Becker Educational Development Corp. All rights reserved.

4.1 Lymphatic Drainage of Lungs

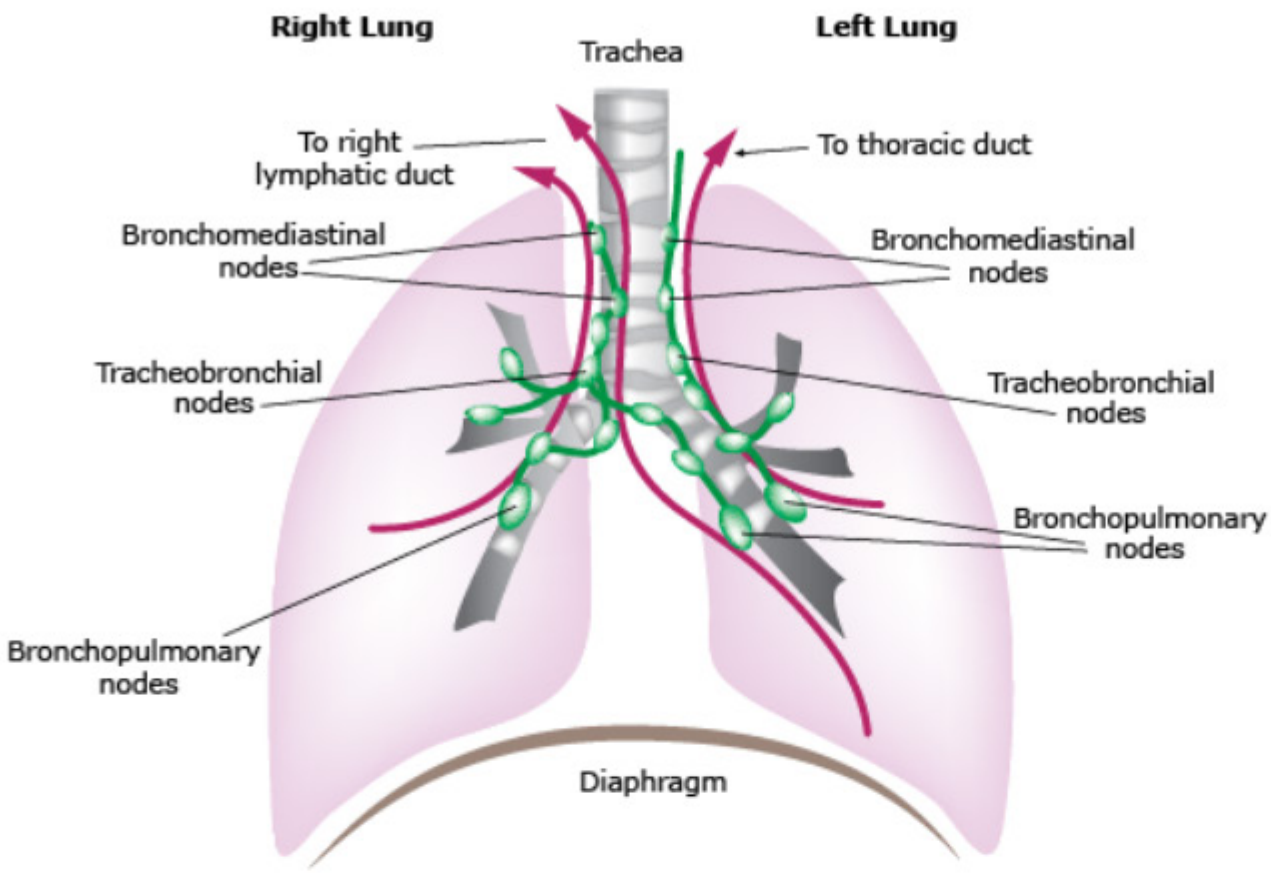

▲ **Figure 7–4.1A** Lymphatics of Lungs

- Deep lymphatics follow the bronchioles and bronchi to the hilum, where they drain into the *bronchopulmonary nodes*. These nodes drain into *tracheobronchial nodes* at the bifurcation of the trachea.
- Lymphatics ascend on each side of the trachea in the *bronchomediastinal nodes* that drain into the right and left *bronchomediastinal trunk*.
- On the right side, the bronchomediastinal trunk drains into the *right lymphatic duct*. On the left side, the trunk drains into the *thoracic duct*.
- Some lymphatics from the inferior lobe of the left lung can cross over and follow the right lymphatic pathway.

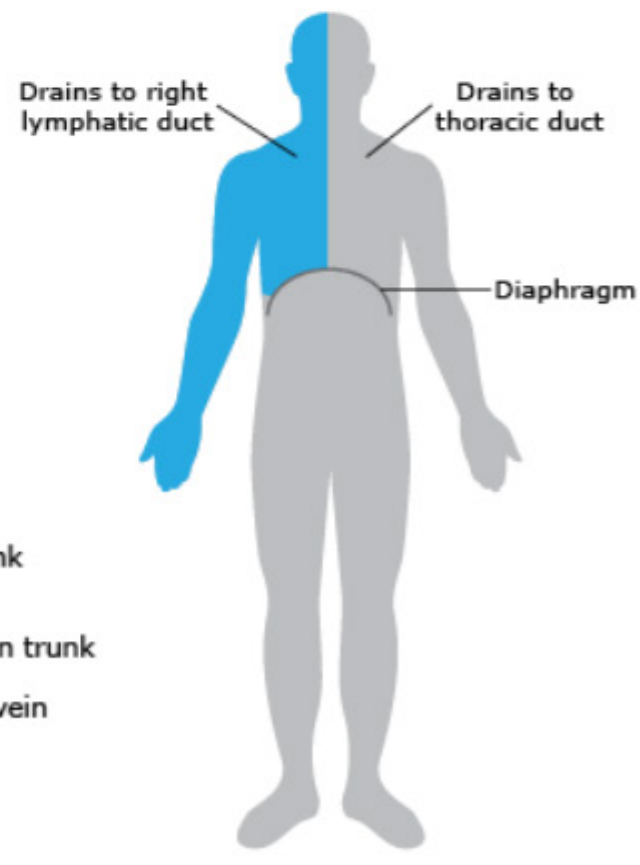

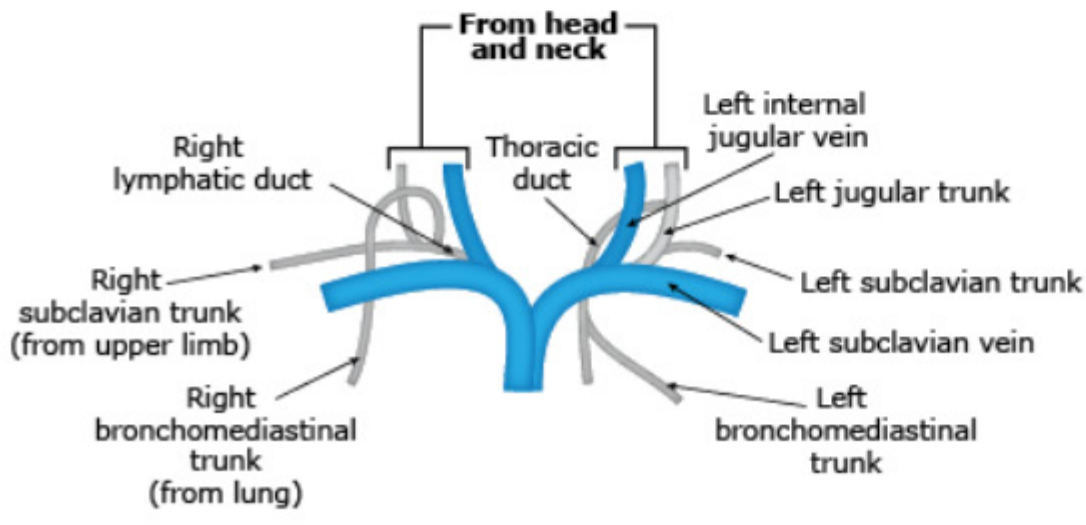

▲ **Figure 7–4.1B** Drainage of Thoracic Duct

Please visit us at www.Groupinsiders.com

© DeVry/Becker Educational Development Corp. All rights reserved.

5 Mediastinum and Development of the Heart

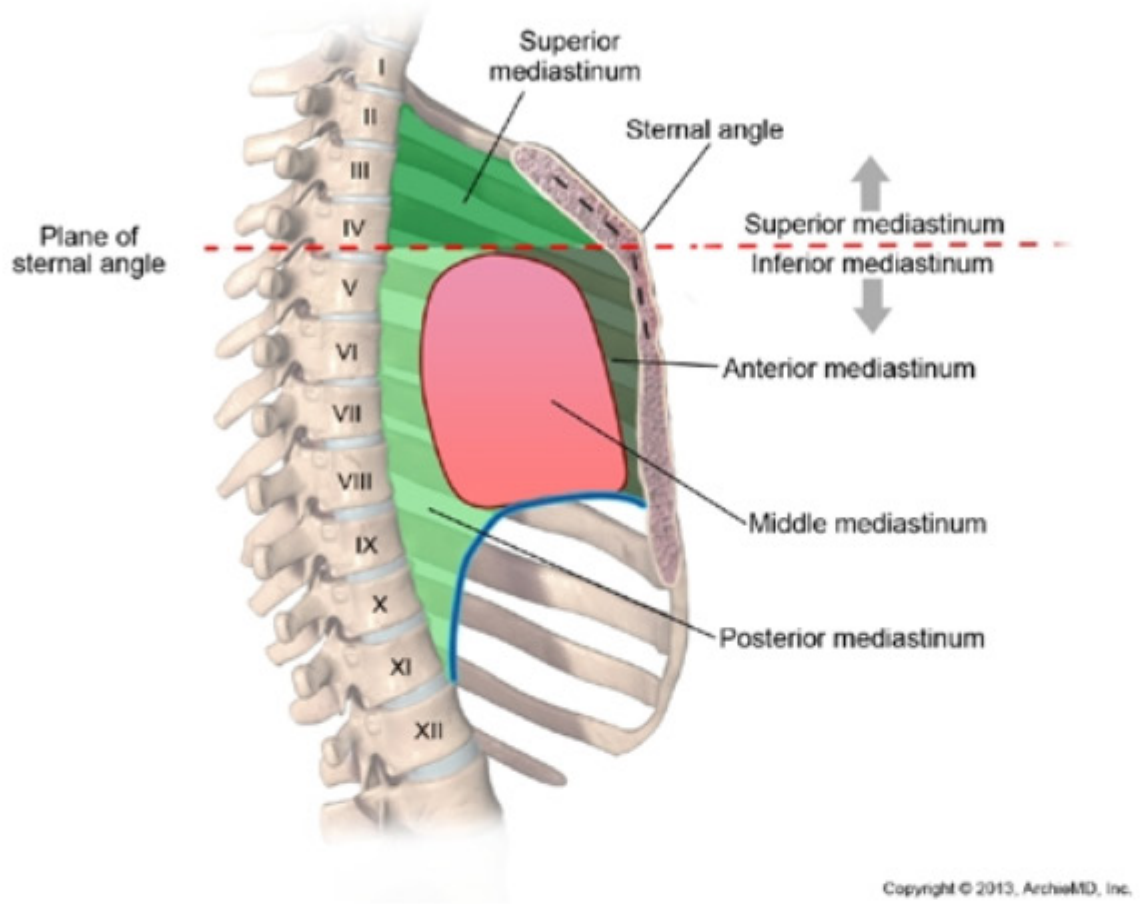

▲ **Figure 7–5.0** Mediastinal Compartments

The *mediastinum* is the midline space or compartment of the thoracic cavity located between the two lungs and pleural cavities. The mediastinum is bounded *anteriorly* by the sternum and *posteriorly* by the 12 thoracic vertebrae. *Inferiorly,* the mediastinum is closed by the diaphragm, and *superiorly* it is open through the superior thoracic aperture into the neck. The mediastinum contains most of the thoracic viscera except for the lungs and pleurae.

The mediastinum is divided into *superior* and *inferior divisions* by a horizontal plane that passes between the *sternal angle of the sternum* anteriorly and the *intervertebral disk, between T4 and T5 vertebrae* posteriorly. The inferior mediastinum is divided into *anterior, middle,* and *posterior* mediastina.

Please visit us at www.Groupinsiders.com

© DeVry/Becker Educational Development Corp. All rights reserved.

5.1 Middle Mediastinum and Development of the Heart

The middle mediastinal compartment houses the heart and the great vessels and the pericardium covering the heart.

5.1.1 Early Development: Heart Tube Formation

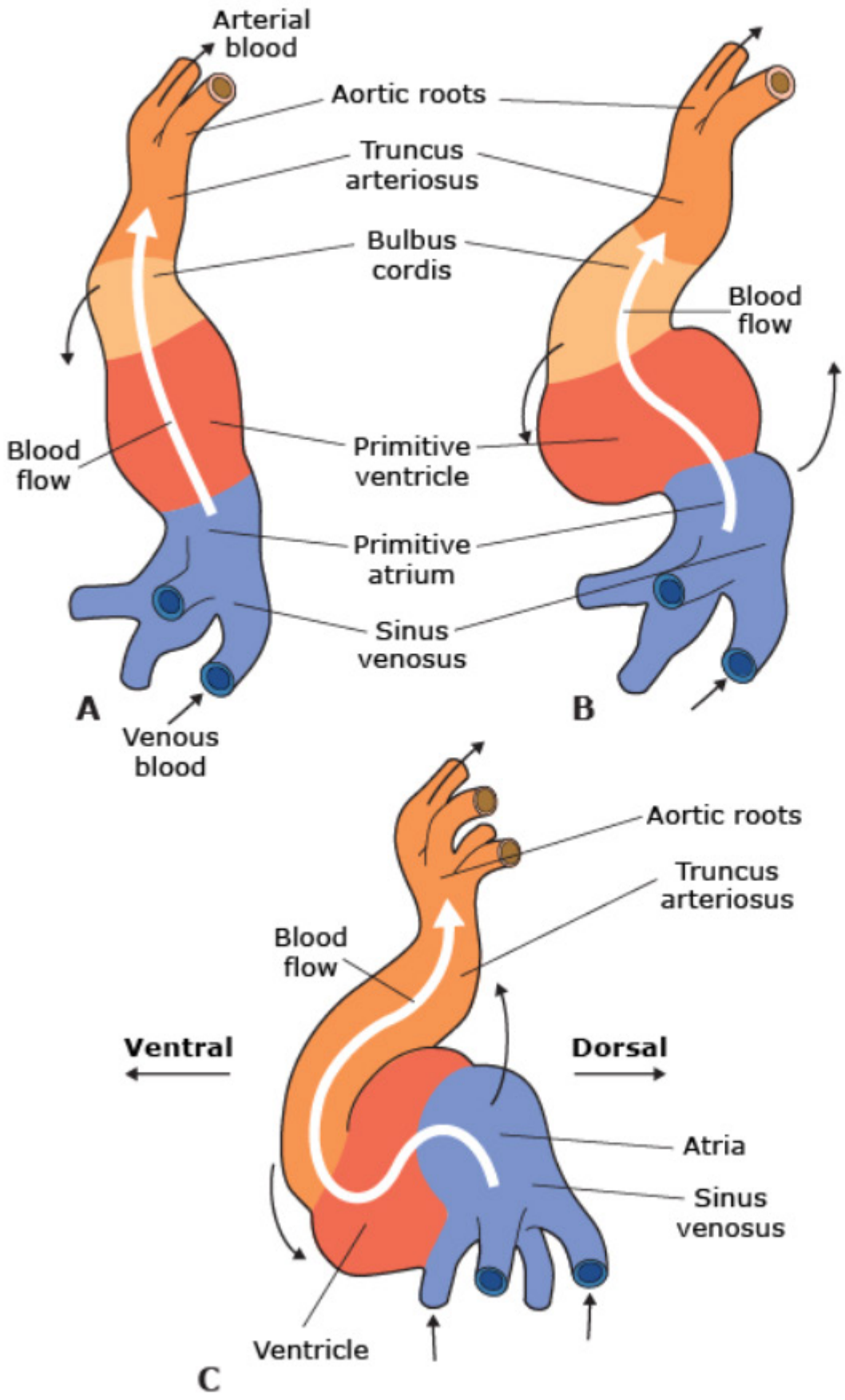

▲ **Figure 7–5.1A** Heart Tube and Early Heart Development

Please visit us at www.Groupinsiders.com

© DeVry/Becker Educational Development Corp. All rights reserved.

The cardiovascular system begins to develop in the middle of the third week immediately following gastrulation. Condensation of *splanchnic mesoderm* in the cardiogenic area anterior to the prechordal plate (buccopharyngeal membrane) forms paired cardiac tubes that fuse in the midline to form the *primitive heart tube*. As a result of cephalic folding of the embryo, the heart is pulled first to the cervical region and then to the thorax.

- The heart tube elongates and develops into a series of embryonic dilations, which are shown in Figure 7–5.1A.
- The adult derivatives of the embryonic parts of the heart tube are shown in Table 7–5.1.
- During the fourth week, the heart tube undergoes a U-shape looping and folding. The venous and atrial end of the tube moves superiorly and posteriorly to the left, while the truncus and ventricular end of the tube moves inferiorly and ventrally to the right. Note that the atria will be located dorsally.
- *Neural crest cells* migrate into two areas of heart development (*truncus arteriosus* and *endocardial cushions*) and significantly contribute to development of the heart.

Important Concept

The right atrium is formed by absorption of the pulmonary veins into the wall.

▼Table 7–5.1A Fate of Five Dilatations of the Primitive Heart Tube

Embryonic Dilatation	Adult Structure
Truncus arteriosus (Neural Crest)	Aorta, Pulmonary artery, Semilunar Valves
Bulbus cordis	Conus arteriosus of right ventricle and aortic vestibule of left ventricle
Primitive ventricle	Main chambers of right and left ventricles
Primitive atrium	Trabeculated parts of right and left atrium
Sinus venosus	Right—Sinus venarum (smooth part of right atrium), Left—Coronary Sinus

Please visit us at www.Groupinsiders.com

© DeVry/Becker Educational Development Corp. All rights reserved.

5.1.2 Prenatal Circulation

Before birth, the placenta provides high-oxygen-saturated blood (about 80%) to the fetus via the umbilical vein. In fetal circulation, three shunts develop that bypass blood around the lungs and liver. In fetal circulation, right heart pressures are higher than on the left side due to the high volume of blood coming from the placenta and increased pulmonary resistance.

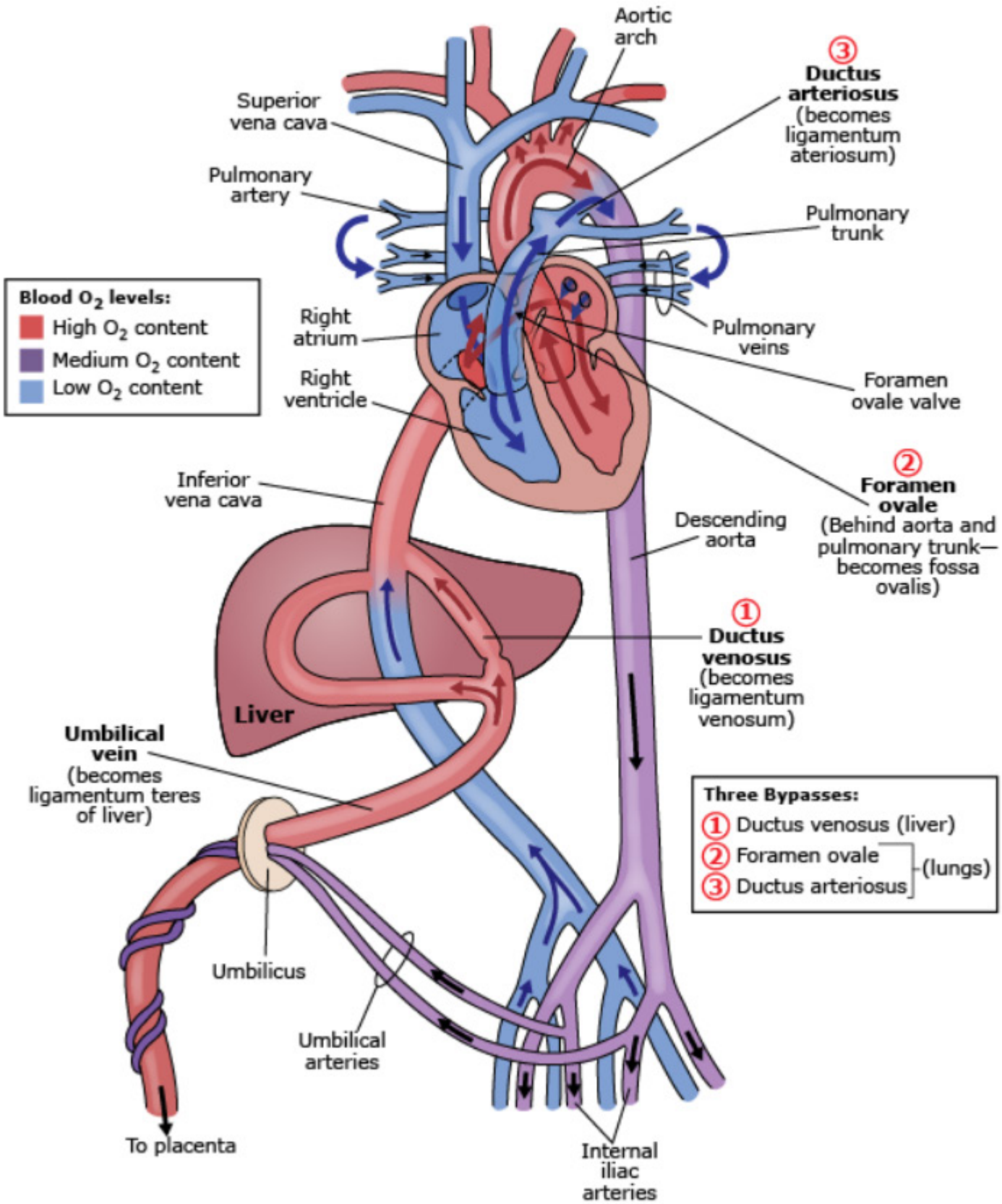

▲ **Figure 7–5.1B** Prenatal Circulation

Please visit us at www.Groupinsiders.com

© DeVry/Becker Educational Development Corp. All rights reserved.

The three important shunts during fetal circulation are the:

1. Ductus Venosus

- Shunts blood from the umbilical vein to the inferior vena cava and partially bypasses hepatic circulation.
- Obliterates at birth and becomes the *ligamentum venosum.*

2. Foramen Ovale

- Shunts blood from the *right atrium to the left atrium* during fetal life, bypassing the pulmonary circulation. This shunting occurs because the right atrial pressure is higher than the left atrial pressure in fetal circulation.
- Shunts high oxygenated blood coming from the placenta to the left side of heart for systemic output until the moment of birth.
- Becomes the *fossa ovalis* after birth.

3. Ductus Arteriosus

- Shunts blood from the pulmonary trunk to the aorta, bypassing the pulmonary circulation
- Closes after birth and becomes the *ligamentum arteriosum*

▼Table 7–5.1B Postnatal Remnant of Prenatal Vessels

Prenatal Vessels	Postnatal Structure
Closure of right and left umbilical arteries	Medial umbilical ligaments
Closure of the umbilical vein	Ligamentum teres of liver
Closure of ductus venosus	Ligamentum venosum
Closure of foramen ovale	Fossa ovalis
Closure of ductus arteriosus	Ligamentum arteriosum

Important Concept

Three vascular bypass shunts develop during prenatal circulation:

- Ductus venosus—bypasses liver
- Foramen ovale—bypasses lungs
- Ductus arteriosus—bypasses lungs

Please visit us at www.Groupinsiders.com

© DeVry/Becker Educational Development Corp. All rights reserved.

5.1.3 Postnatal Circulation

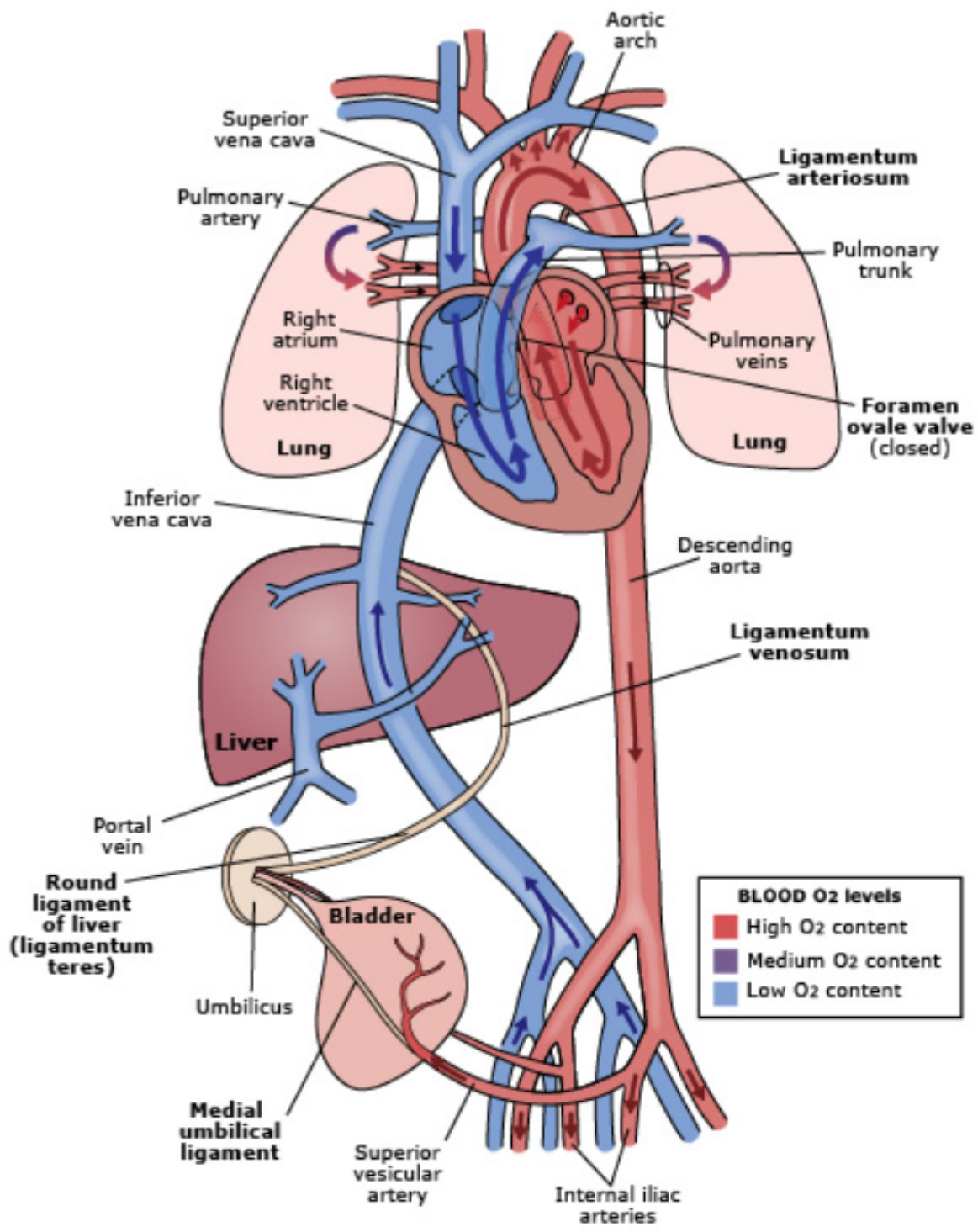

▲ **Figure 7–5.1C** Postnatal Circulation

Changes in circulation at birth are due to loss of placental blood flow, beginning of respiration, reduction of pulmonary resistance, and the reversal of pressures resulting in left heart pressures becoming higher than right. The following changes occur:

- *Closure of foramen ovale* (fossa ovalis) results from increased pressure in the left atrium.
- *Closure of the ductus arteriosus* (ligamentum arteriosum) results from the contraction of its muscular wall.
- *Closure of the ductus venosus* (ligamentum venosum) results from contraction of its muscular wall.
- *Closure of the umbilical vein* becomes the ligamentum teres of the liver.
- *Closure of the umbilical artery* becomes the medial umbilical ligament.

Please visit us at www.Groupinsiders.com

© DeVry/Becker Educational Development Corp. All rights reserved.

6 Septation of the Heart Tube

The original heart tube develops as a common chamber except for the sinus venosus that originally develops right and left. The heart tube undergoes major septation events to divide it into a right and left heart. The atrial, ventricular, and truncal septations occur concurrently. Most of the major partitioning of the heart occurs in the fourth and fifth weeks and is usually completed by the eighth week.

6.1 Septation of the Atria

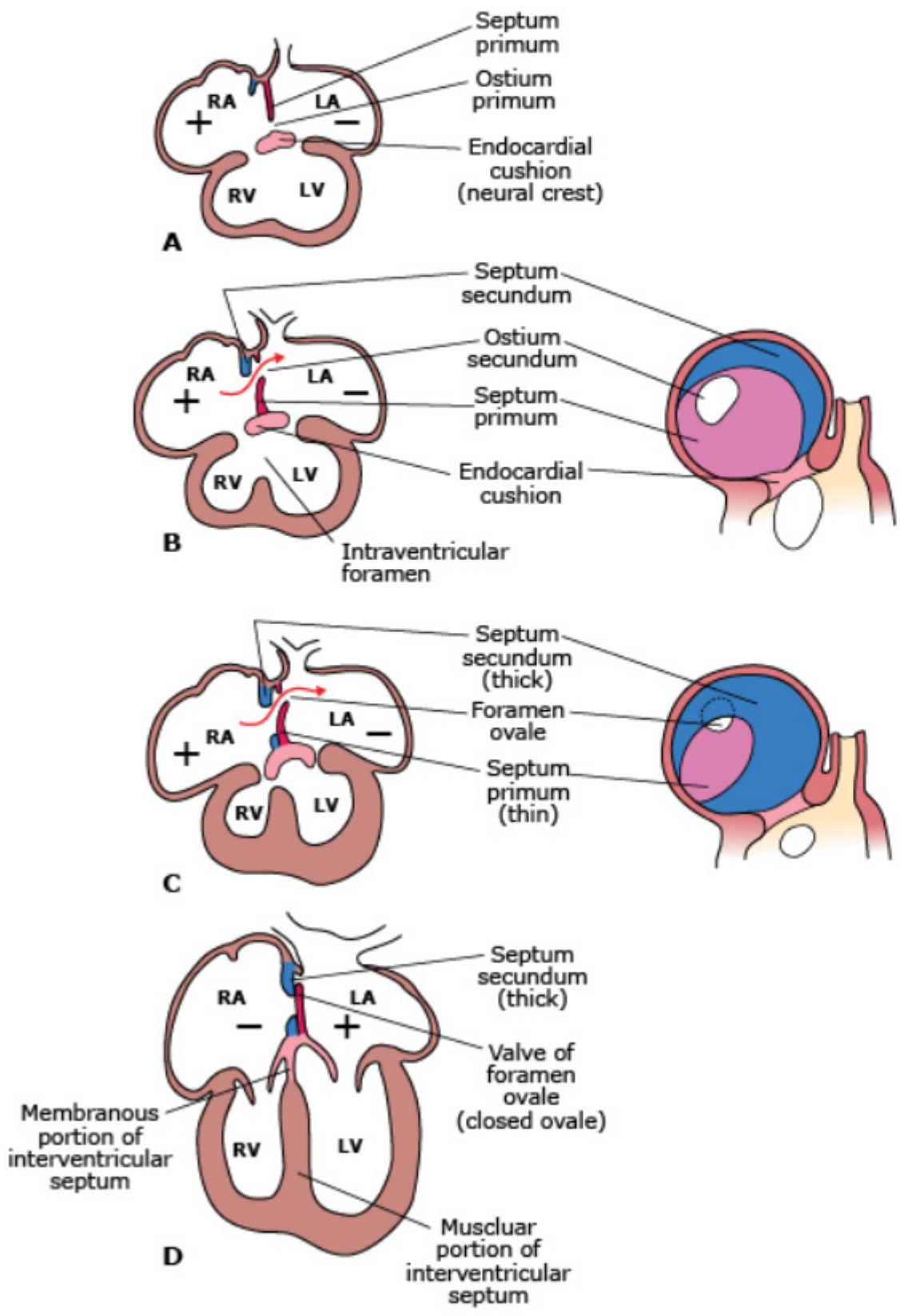

▲ **Figure 7–6.1A** Atrial Septation

Please visit us at www.Groupinsiders.com

© DeVry/Becker Educational Development Corp. All rights reserved.

Complete septation of the atria does not occur until birth. During fetal circulation, it is critical that there is continuous right to left shunting (foramen ovale) across the interatrial wall to provide oxygenated blood to the left heart and systemic circulation. Atrial septation involves the formation of two foramina and two septa and the foramen ovale. The major events and structures of atrial septation include:

- **Septum Primum:** Septum primum grows downward toward the endocardial cushion from the roof of the primitive atrium. Initially, that is a space between the first septum and the endocardial cushion called the foramen primum.
- **Foramen Primum:** The foramen primum is closed by the fusion of the septum primum with the endocardial cushion a short time later. Neural crest cells migrate into the endocardial cushion. The endocardial cushion contributes to the right and left atrioventricular canals, the atrioventricular valves, membranous part of the interventricular septum, and the aorticopulmonary septum.
- **Foramen Secundum:** The foramen secundum forms in the upper part of septum primum as a result of programmed cell death. This new opening is the second foramen; it shunts blood right-to-left.
- **Septum Secundum:** The septum secundum grows from the roof downward to the right of the first septum and overlaps the septum primum. They later fuse and form the atrial septum.
- **Foramen Ovale:** Foramen ovale is the oval opening in the septum secundum as it overlaps the foramen secundum that provides flow between the two atria.

At birth, there is a reversal of atrial pressures, with left atrial pressure going higher than the right atrium. This results in the closure of foramen ovale. This change in pressure is due to the decrease in the volume of blood and pressure in the right atrium with the cutting of the umbilical vein and the opening of the pulmonary circuit, and the decrease in pulmonary resistance.

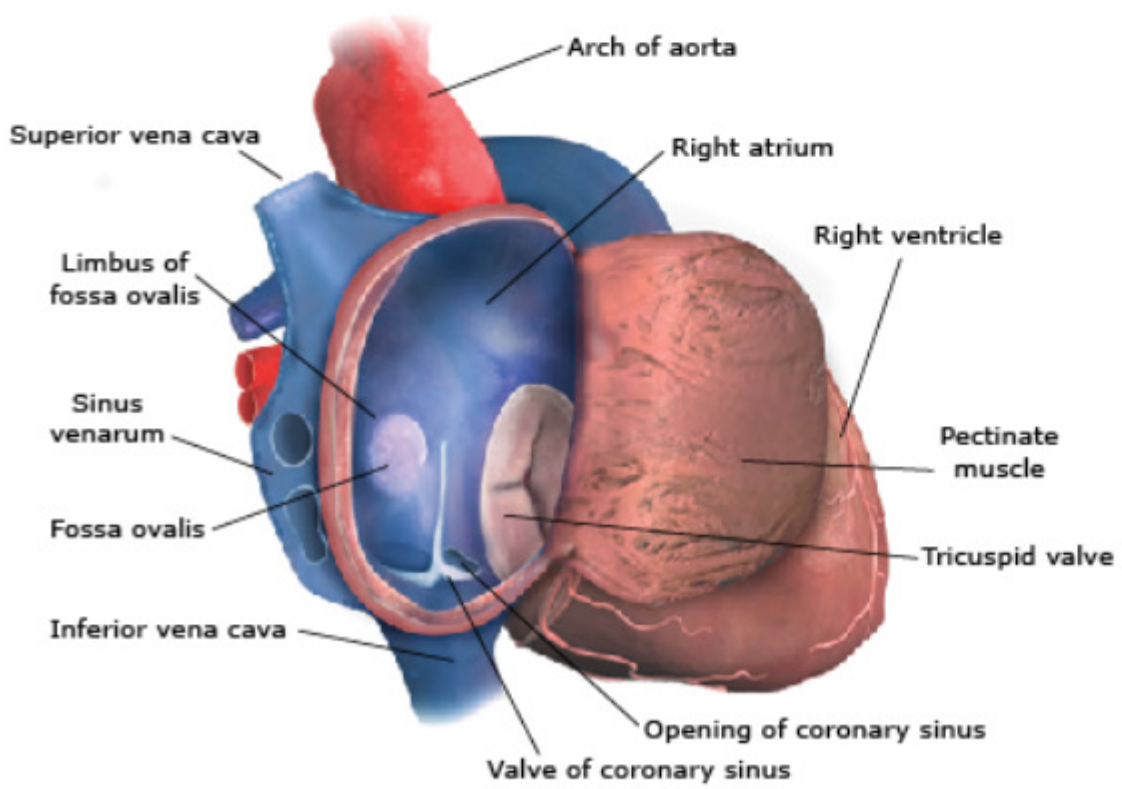

▲ **Figure 7–6.1B** Adult Right Atrium

Important Concept

During fetal life it is necessary to continually shunt blood from the right to the left atrium to bring freshly oxygenated blood to the left heart for systemic circulation.

Please visit us at www.Groupinsiders.com

© DeVry/Becker Educational Development Corp. All rights reserved.

6.2 Atrial Septal Defects

Atrial septal defects (ASD) occur more common in female than in male infants (2:1). These defects result in postnatal *left-to-right shunting* and are *non-cyanotic defects*. Two of the more common ASDs are the *secundum* and *primum types of ASDs*.

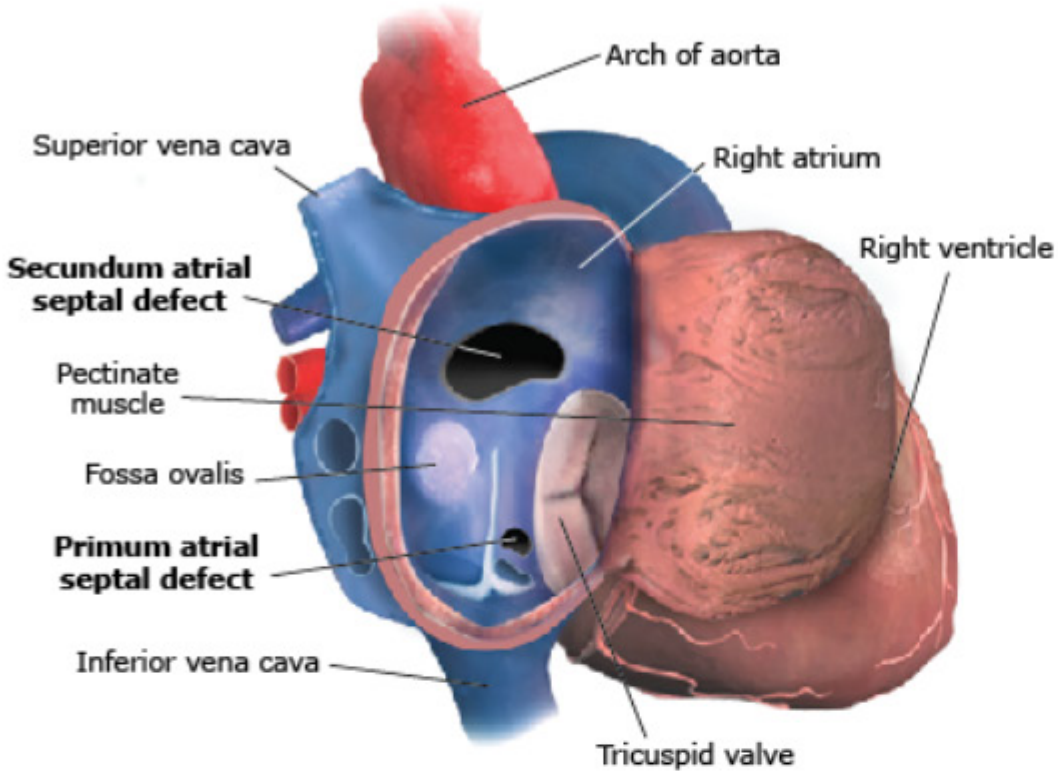

▲ **Figure 7–6.2** Atrial Septal Defects

6.2.1 Secundum ASD

- Most common type of ASD.
- Blood shunts from *left to right* and is *non-cyanotic*.
- Caused by excessive absorption of the septum primum or by reduced development of the septum secundum or both, resulting in a *patent foramen ovale*.
- Defect is located above the fossa ovalis in the upper part of the interatrial wall.
- Defect may not be symptomatic until later in life.

6.2.2 Primum ASD

- Less common than the secundum defect.
- Occurs when the septum primum and the endocardial cushions fail to fuse and is found in the *lower aspect* of the atrial septum below the fossa ovalis.
- Results in a *patent foramen primum* with *left-to-right shunting* and is *non-cyanotic*.
- Involves the *endocardial cushions* and *failure of neural crest cells* to migrate into the cushion.
- May be associated with a membranous interventricular defect and atrioventricular valve defects.

Clinical Application

In newborn heart defects, postnatal right-to-left shunts result in cyanotic conditions, and postnatal left-to-right shunts result in non-cyanotic conditions.

Please visit us at www.Groupinsiders.com

© DeVry/Becker Educational Development Corp. All rights reserved.

6.3 Septation of Ventricles

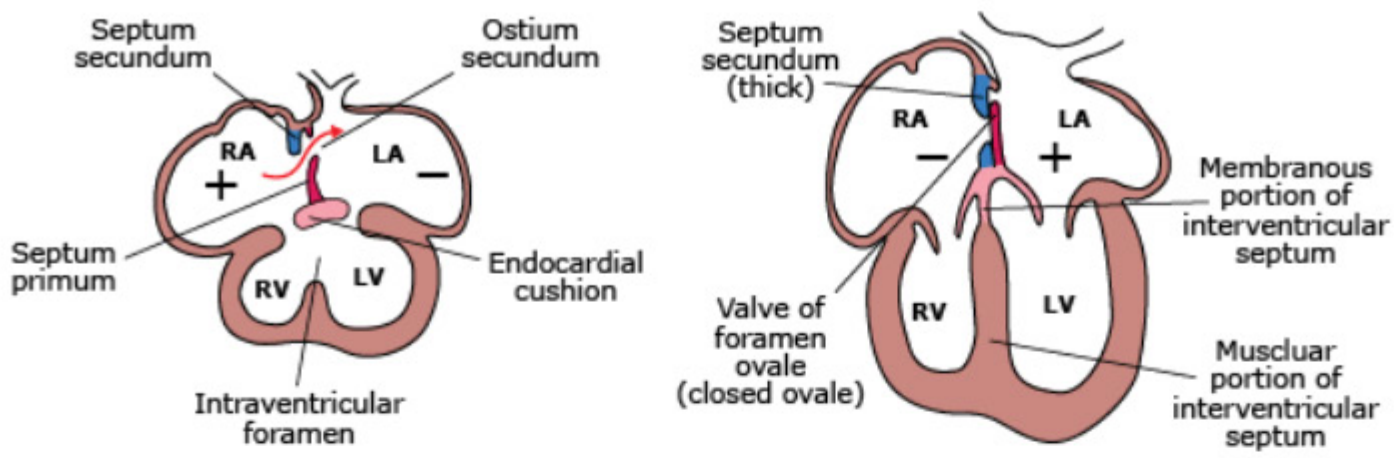

▲ **Figure 7–6.3** Ventricular Septation

Unlike atrial septation, ventricular septation occurs completely without any prenatal shunting before birth. The fully developed interventricular septum is formed by two components: mostly by a thick *muscular part* and a thin, non-muscular *membranous part* at the superior end.

- The *muscular part of the septum* forms by an upward growth of muscle from the floor of the primitive ventricle toward the endocardial cushion. It does not reach the cushion and leaves an open IV foramen.
- The *membranous part* forms mostly from the bulbar ridges (site of *neural crest* migration) of the *endocardial cushions*. The membranous part closes the IV foramen and completes ventricular septation.

6.4 Ventricle Septal Defects

Ventricular septal defects (VSD) are the most common of the significant newborn heart defects, being more prevalent in males.

- *Membranous septal defects* are the most common VSD and result from the *failure of neural crest cells* to migrate into the cushion.
- Results in a *left-to-right shunting* of blood at birth and is non-cyanotic. Over time, the increased pulmonary blood flow causes pulmonary hypertension due to hyperplasia of the intima of the pulmonary artery and the narrowing of its lumen. Ultimately, increased pulmonary resistance causes the right ventricular pressure to increase and reverse the shunting from to *right to left* and *cyanosis*. This reversed shunting is called the *Eisenmenger complex*, or *late cyanosis*.

Please visit us at www.Groupinsiders.com

© DeVry/Becker Educational Development Corp. All rights reserved.

6.4.1 Closure of the Ductus Arteriosus

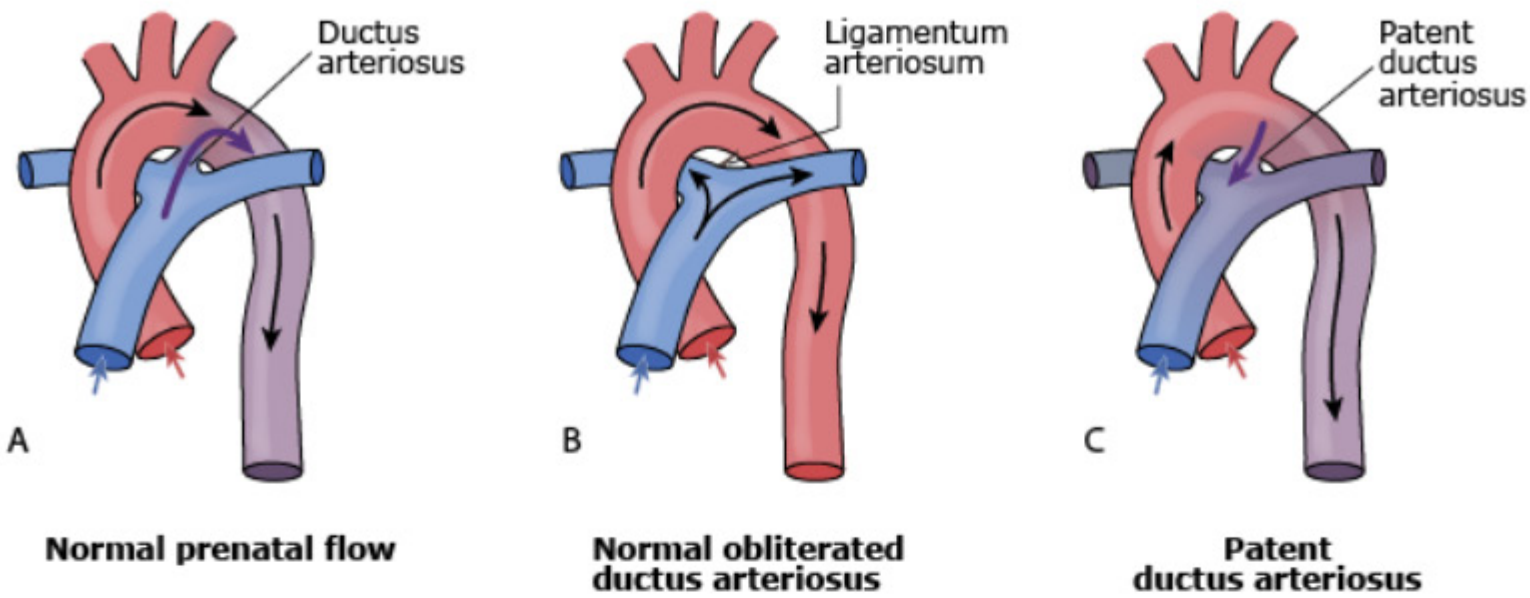

▲ **Figure 7–6.4** Ductus Arteriosus

In fetal circulation, the *ductus arteriosus* provides shunting of blood between the pulmonary artery and the aorta, bypassing pulmonary flow. After birth, the ductus arteriosus should close down within the first day due to the contraction of smooth muscle, and forms the ligamentum arteriosum.

- A *patent ductus arteriosus* (PDA) occurs when the ductus fails to close.
- Results in postnatal *left-to-right shunting* and *non-cyanosis. Note that the shunting is now from the aorta to the pulmonary circulation.*
- Common in premature births and in mothers with rubella infection.
- Closed medically with prostaglandin inhibitors.
- Produces a machine-like continuous murmur.

Please visit us at www.Groupinsiders.com

© DeVry/Becker Educational Development Corp. All rights reserved.

6.5 Septation of the Truncus Arteriosus

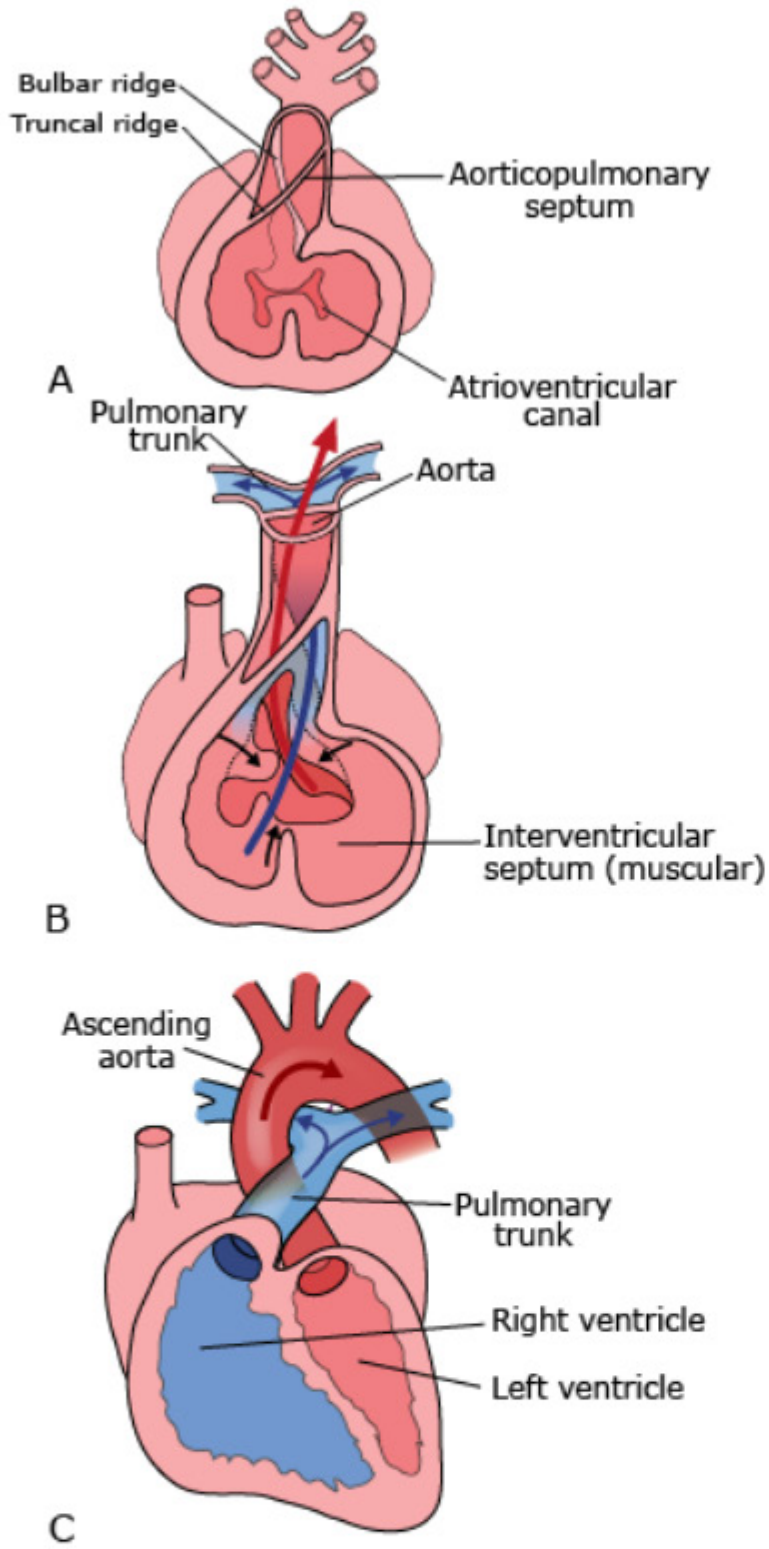

▲ **Figure 7–6.5A** Truncus Arteriosus Septation

During the fifth week, pairs of ridges develop from the endocardial cushion and form on the walls of the truncus. The ridges twist around each other as they grow and form a *spiral septum* within the truncus called the *aorticopulmonary septum* (AP).

- The spiral septation of the truncus results in the formation of the *aorta* and *pulmonary trunks* and the semilunar valves.
- Migration of neural crest cells into the endocardial cushions contributes to the formation of the *aorticopulmonary septum*, and the neural crest cells play an important role in the development of the septum.

Important Concept

Migration of neural crest cells is critical for normal septation of the truncus arteriosus.

Please visit us at www.Groupinsiders.com

© DeVry/Becker Educational Development Corp. All rights reserved.

Clinical Application

Defects in the development of the aorticopulmonary septum result in three significant *cyanotic congenital heart defects* at birth. Each of these abnormalities *has right-to-left shunting*, thus producing cyanosis. Since each of these defects involves the endocardial cushion, they are all related to *failure of neural crest cells to migrate to the cushion*.

A. Tetralogy of Fallot

Tetralogy of Fallot is the most frequently occurring defect of the truncus arteriosus and results from a *misalignment and anterior displacement of the AP septum* to the right.

- Produces four classic defects: (1) pulmonary stenosis, (2) overriding aorta, (3) membranous septal defect, and (4) hypertrophied right ventricular wall.
- Causes *right-to-left shunting* with variable degrees of *cyanosis* that usually is not present at birth.

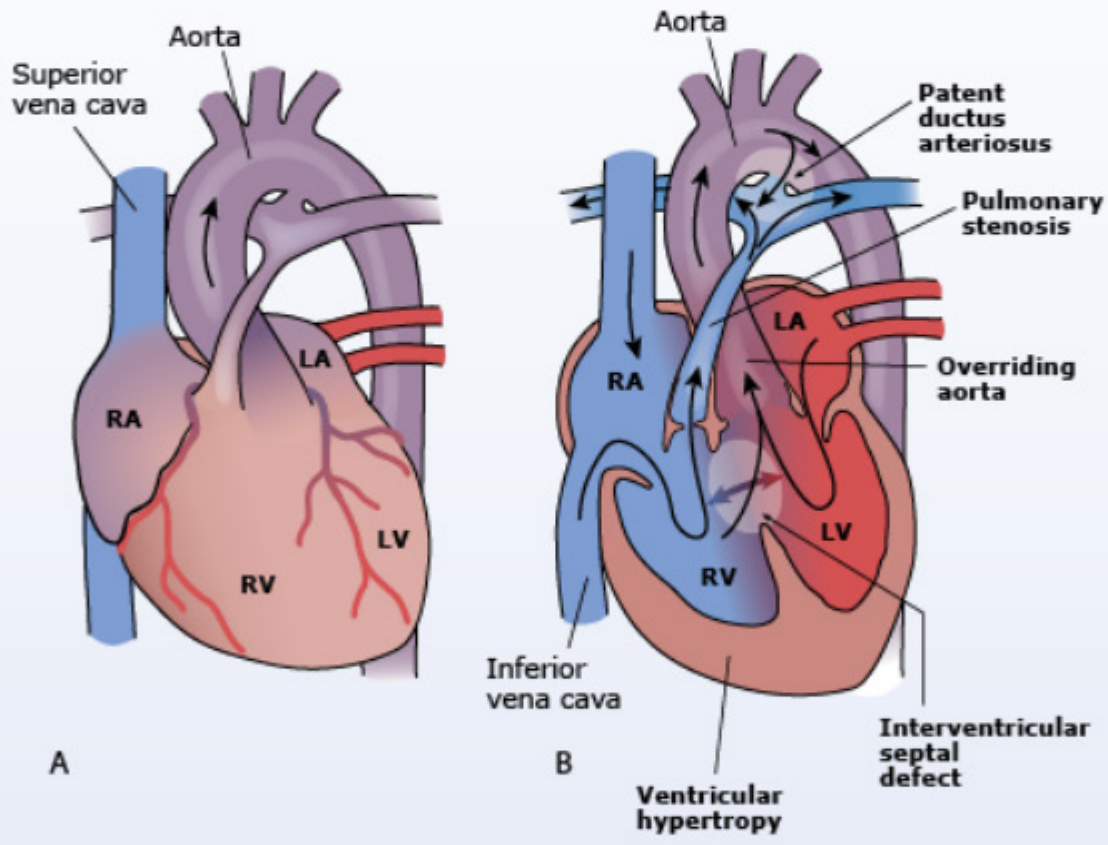

▲ **Figure 7–6.5B** Tetralogy of Fallot

(continued on next page)

Please visit us at www.Groupinsiders.com

© DeVry/Becker Educational Development Corp. All rights reserved.

Clinical Application *(continued)*

B. Transposition of the Great Vessels

Transposition of the great vessels is the most common cause of severe cyanosis in a newborn. These infants have a high mortality rate. Transposition of the great vessels occurs when the aorticopulmonary septum fails to spiral.

- Results in the aorta arising from the right ventricle and the pulmonary trunk from the left ventricle.
- Causes *right-to-left shunting* and *severe cyanosis.*
- Occurrence of VSD, ASA, or PDAs in these newborns allows some exchange of oxygenated blood and survival.

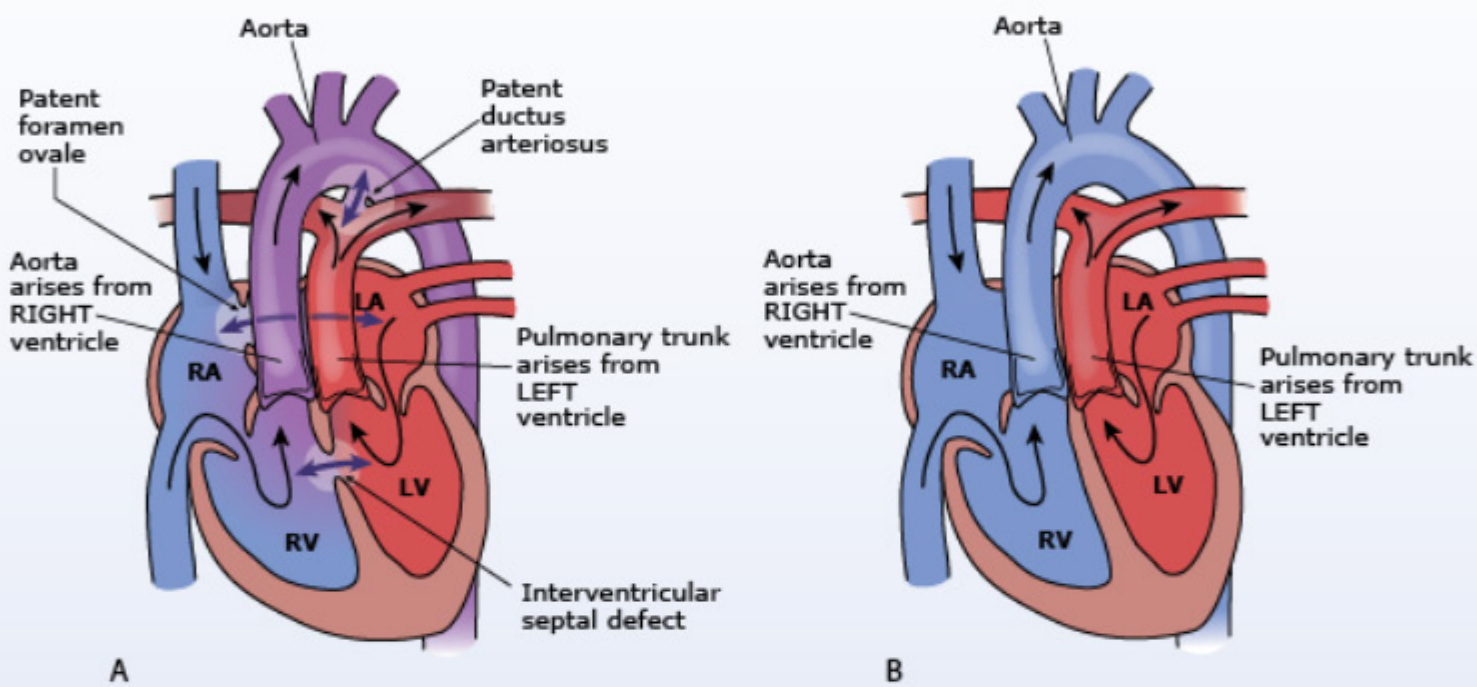

▲ **Figure 7–6.5C** Transposition of Great Vessels

(continued on next page)

Please visit us at www.Groupinsiders.com

© DeVry/Becker Educational Development Corp. All rights reserved.

Clinical Application *(continued)*

C. Persistent Truncus Arteriosus

Persistent truncus arteriosus results from partial failure of the AP septum to form and divide the truncus arteriosus into the aorta and pulmonary trunk.

- A single, common arterial trunk arises from the heart and supplies all of the circulations.
- Results in a *right-to-left shunting* with *cyanosis*.
- There is always a membranous VSD, and the large single trunk straddles the VSD.
- Often the truncus will eventually divide into some form of an aorta and pulmonary trunk as it leaves the heart.

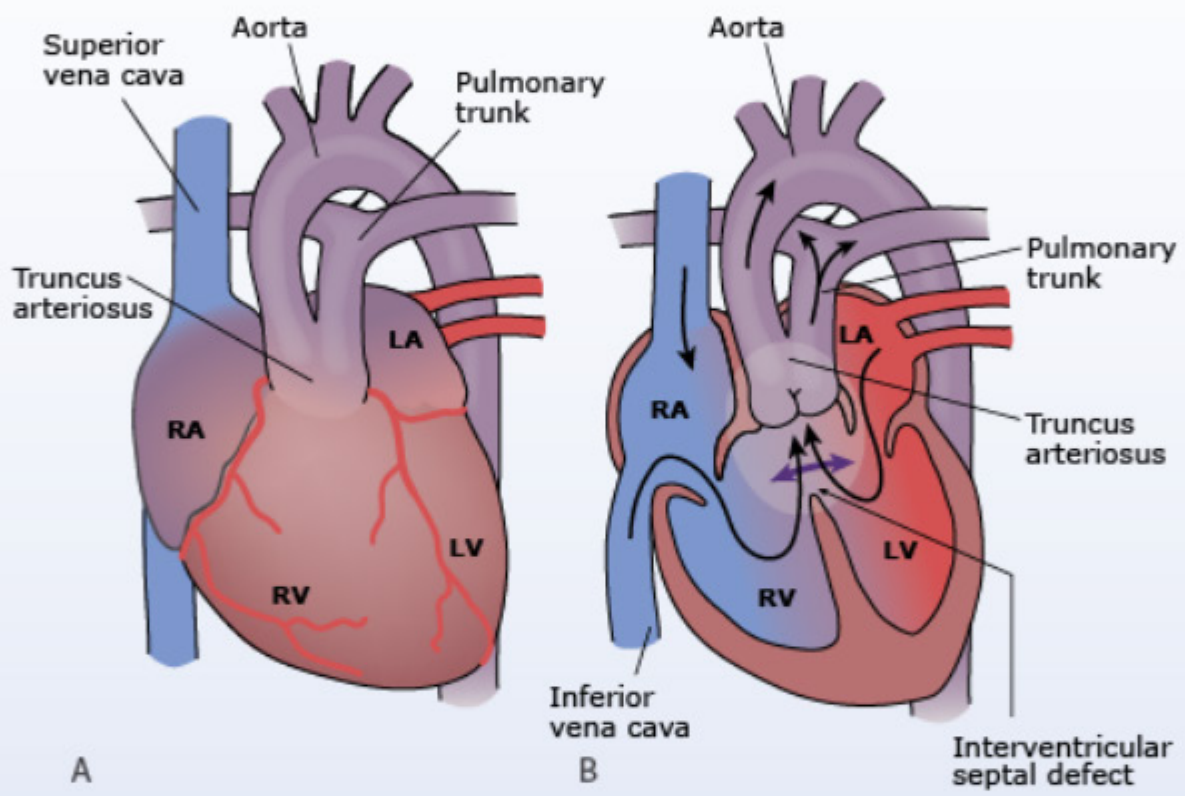

▲ **Figure 7–6.5D** Persistent Truncus Arteriosus

Please visit us at www.Groupinsiders.com

© DeVry/Becker Educational Development Corp. All rights reserved.

7 Adult Heart

7.1 Pericardium

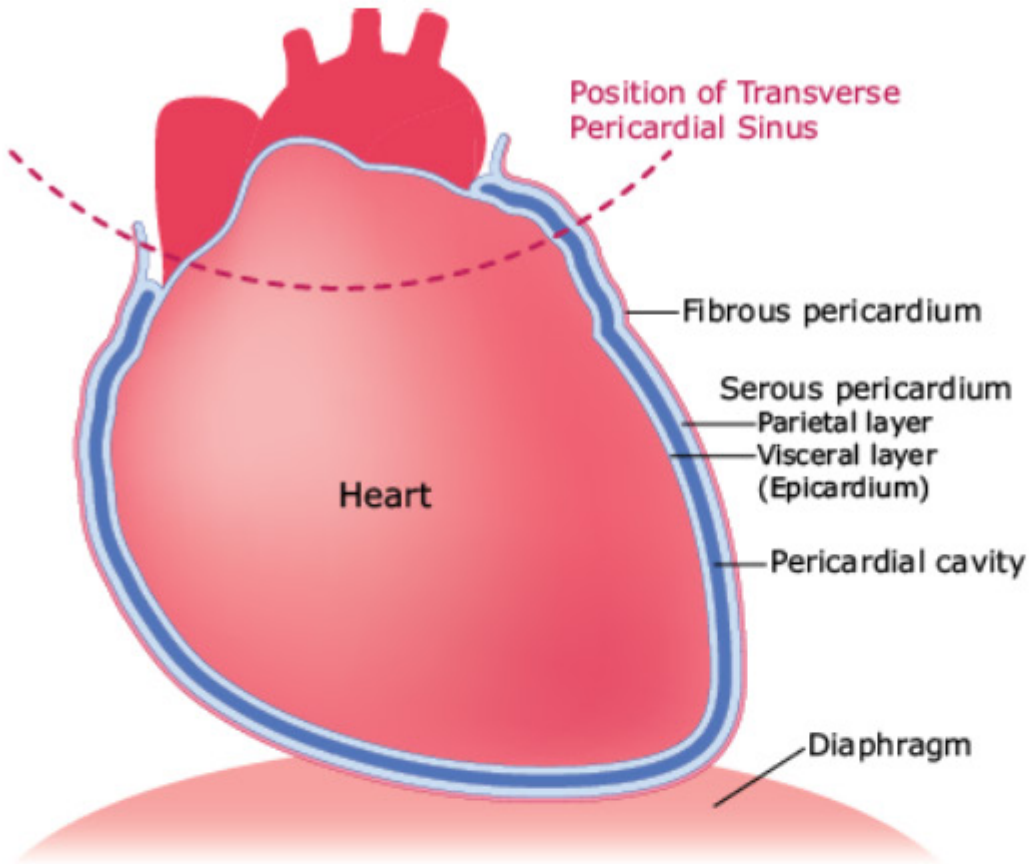

▲ **Figure 7–7.1** Pericardium

The pericardium is the fibroserous covering of the heart and great vessels within the middle mediastinum. Unlike the pleura and peritoneum, the pericardium is composed of three layers.

- **Fibrous Pericardium**
  - The outer, dense sac that is attached to the central tendon of the diaphragm below and to the adventitia of the great vessels at the superior aspect of the heart.
  - The fibrous pericardial sac serves to help maintain the position of the heart in the middle mediastinum.
- **Parietal Serous Pericardium**
  - Lines the inner surface of the fibros pericardium and reflects it onto the surface of the heart as the visceral pericardium at the great vessels.
- **Visceral Serous Pericardium**
  - Is tightly attached to and covers the surface of the myocardium (epicardium).

Clinical Application

Cardiac tamponade is caused by a rapid influx of fluid or blood into the pericardial cavity. The fluid compresses the heart, reducing cardiac output and increasing venous pressure, indicated by distention of the jugular vein.

To remove the excess fluid, a *pericardiocentesis* is performed by placing a needle through the fifth intercostal space to the left of the xiphisternal junction. The needle passes through the cardiac notch of the left lung to reach the pericardium.

Please visit us at www.Groupinsiders.com

© DeVry/Becker Educational Development Corp. All rights reserved.

7.2 Pericardial Cavity

The *pericardial cavity* lies between the visceral and parietal layers of the serous pericardium. It is a thin space that contains a small amount of serous fluid that provides friction-free movement of the heart during contraction.

- During heart development, the pericardial cavity is enlarged to form two sinuses.
  - The *transverse pericardial sinus* is located posterior to the aorta and pulmonary arteries but anterior to the superior vena cava and superior to the left atrium. The sinus is clinically significant because a surgeon can place a finger through the sinus to separate arteries from veins.
  - The *oblique pericardial sinus* is a cul de sac related to the diaphragmatic surface of the heart found between the pulmonary veins.

7.3 Exterior of the Heart

7.3.1 Borders of the Heart

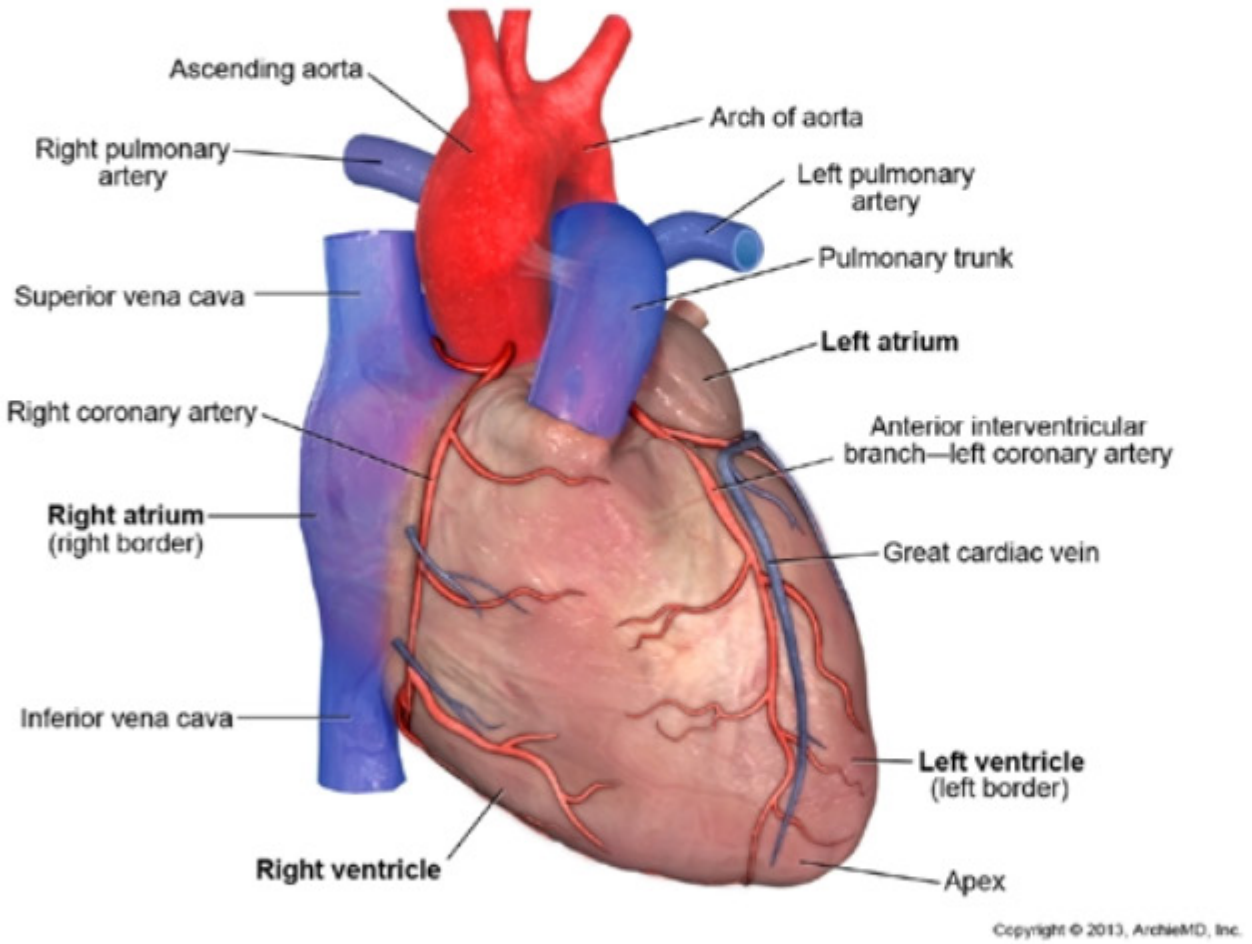

▲ **Figure 7–7.3A** Anterior Surface of the Heart

- **Right Border:** Is formed by the *right atrium* on the right aspect of the heart between the superior and inferior vena cava.
- **Left Border:** Is formed by the *left ventricle*.
- **Apex:** Is formed by the inferior angle of the *left ventricle* in the fifth intercostal space at the midclavicular line.

Please visit us at www.Groupinsiders.com

© DeVry/Becker Educational Development Corp. All rights reserved.

7.3.2 Surfaces of the Heart

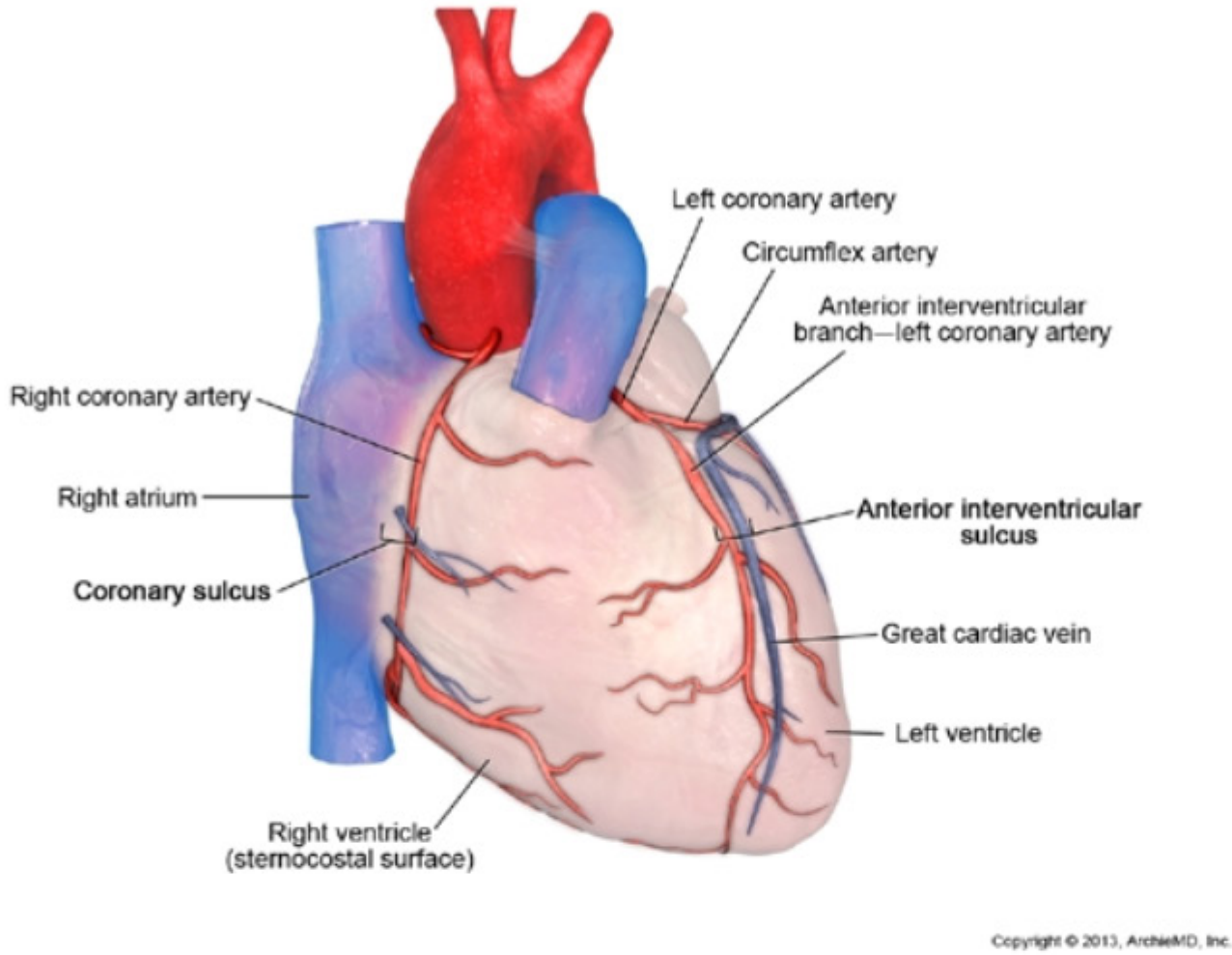

▲ **Figure 7–7.3B** External Heart: Anterior and Sulci

- **Anterior (Sternocostal) Surface:** This surface is formed primarily by the *right ventricle*, which lies just posterior to the body of the sternum.
- **Posterior (Base) Surface:** This surface is formed mainly by the *left atrium* and is related posteriorly to the esophagus and the posterior mediastinum.
- **Inferior (Diaphragmatic) Surface:** This surface rests on the diaphragm and is formed mainly by the *left ventricle*.

Please visit us at www.Groupinsiders.com

© DeVry/Becker Educational Development Corp. All rights reserved.

7.3.3 Sulci of the Heart

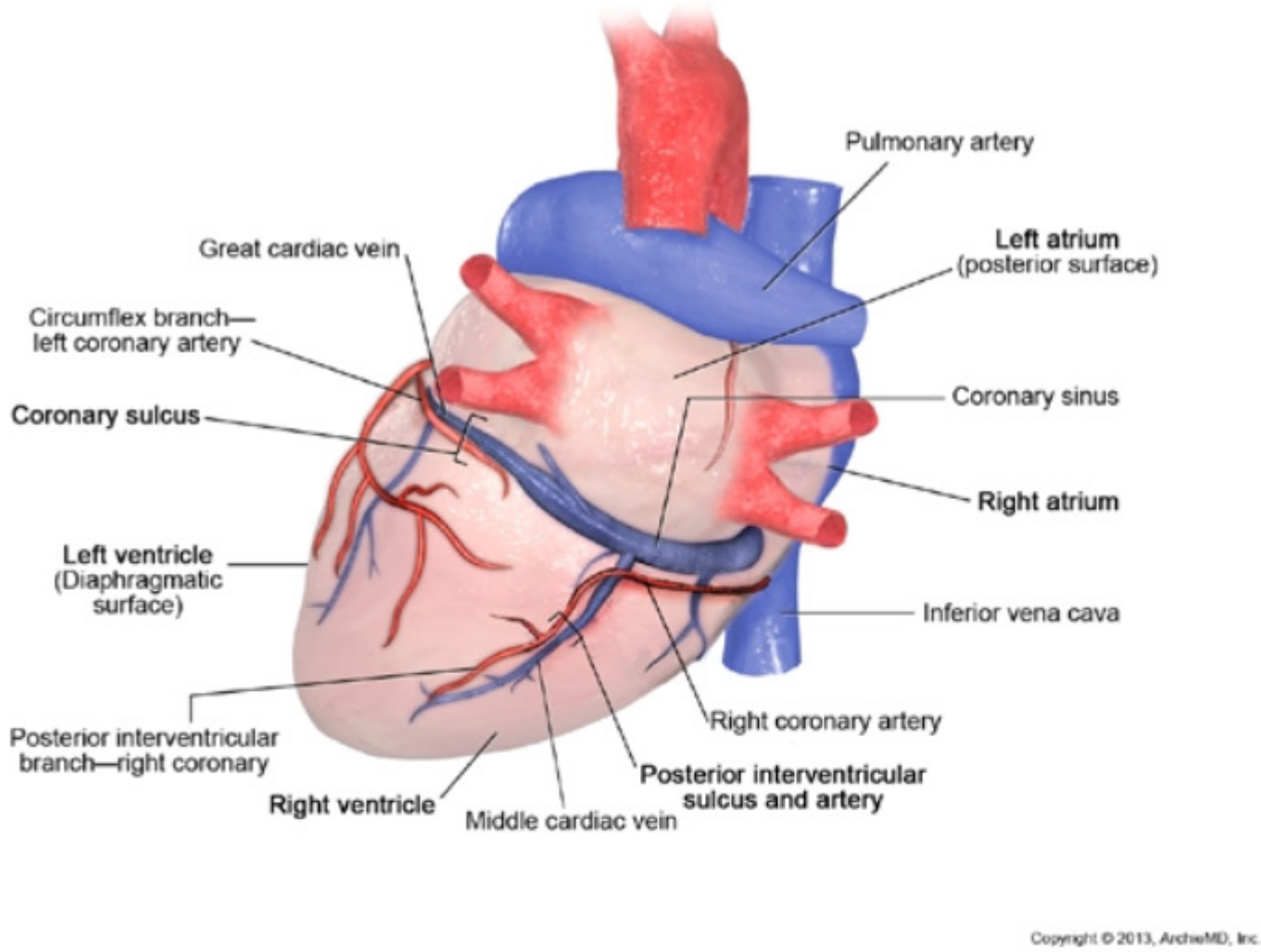

▲ **Figure 7–7.3C** External Heart: Posterior and Sulci

The sulci are the grooves that run on the surface of the heart and contain epicardial fat and the distribution of the vascular system to the myocardium. The position of the sulci indicates the orientation of the underlying four chambers of the heart.

- The *coronary sulcus* (atrioventricular sulcus) almost completely encircles the upper aspect of the heart and separates the atria above from the ventricles below.
- The *anterior interventricular sulcus* is located on the sternocostal surface, separating the right and left ventricles and indicating the position of the interventricular septum.
- The *posterior interventricular sulcus* is found on the diaphragmatic surface and separates the right and left ventricles.

Please visit us at www.Groupinsiders.com

© DeVry/Becker Educational Development Corp. All rights reserved.

7.4 Projection of the Surface Anatomy of Heart on Anterior Chest Wall

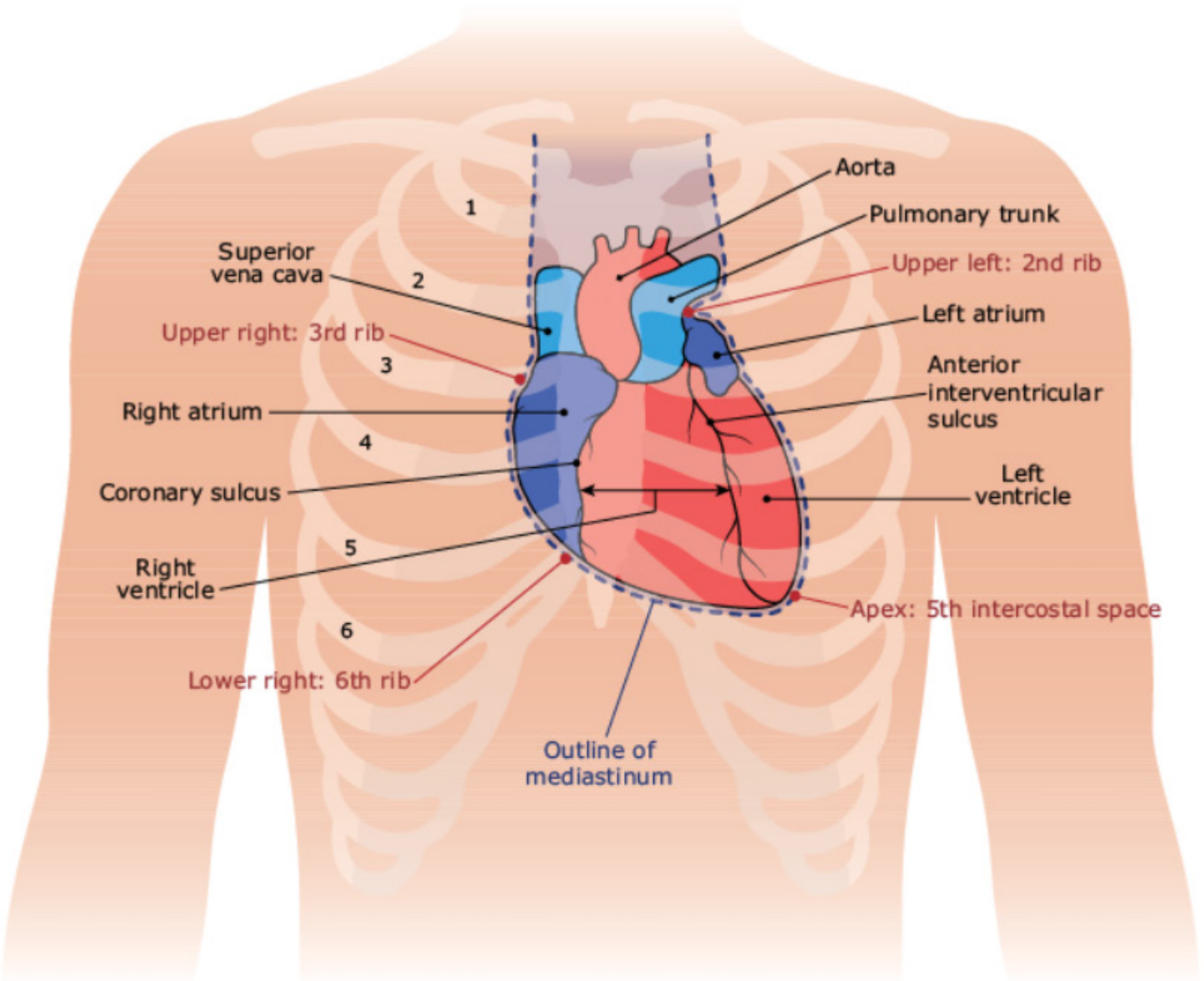

▲ **Figure 7–7.4** Surface Anatomy of the Heart

Projection of the heart to the anterior chest wall is important in evaluating penetrating wounds to the chest wall and cardiac imaging.

- **Right Border:** Extends between the right third rib and the sixth rib at the right parasternal border.
- **Above the Third Rib:** The superior vena cava courses deep to the costal cartilage of the right first and second ribs at the right parasternal border.
- **Left Border:** Extends between the left second rib and the fifth intercostal space at the midclavicular line.
- Note that the *right ventricle* is deep to the left parasternal border.

Please visit us at www.Groupinsiders.com

© DeVry/Becker Educational Development Corp. All rights reserved.

7.5 Interior of the Heart

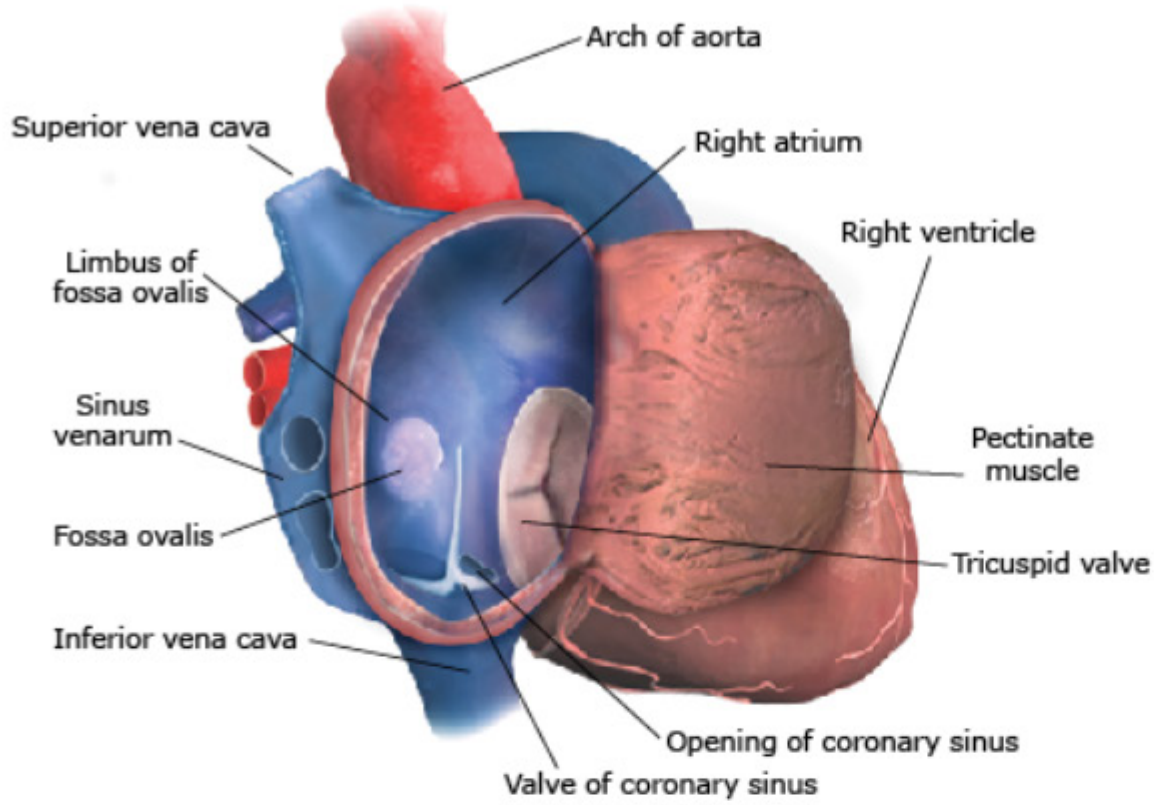

▲ **Figure 7–7.5A** Interior Heart

7.5.1 Right Atrium

- **Pectinate Muscles:** Small, comb-like bundles of cardiac muscle found in the auricle and anterior wall.
- **Sinus Venarum:** The large smooth area of the atrial wall that developed from the right sinus venosus.
- **Crista Terminalis:** A muscular ridge separating the smooth area from the pectinate muscles.
- **Fossa Ovalis:** A thumb-shaped area on the interatrial wall indicating the position of the foramen ovale in fetal life.
- Right atrioventricular opening.
- Opening of the coronary sinus.
- Openings of the superior and inferior vena cava.

Clinical Application

Penetrating wounds to the right parasternal border above the third rib would penetrate the superior vena cava, and those between the third and sixth ribs would penetrate the right atrium.

Please visit us at www.Groupinsiders.com

© DeVry/Becker Educational Development Corp. All rights reserved.

7.5.2 Right Ventricle

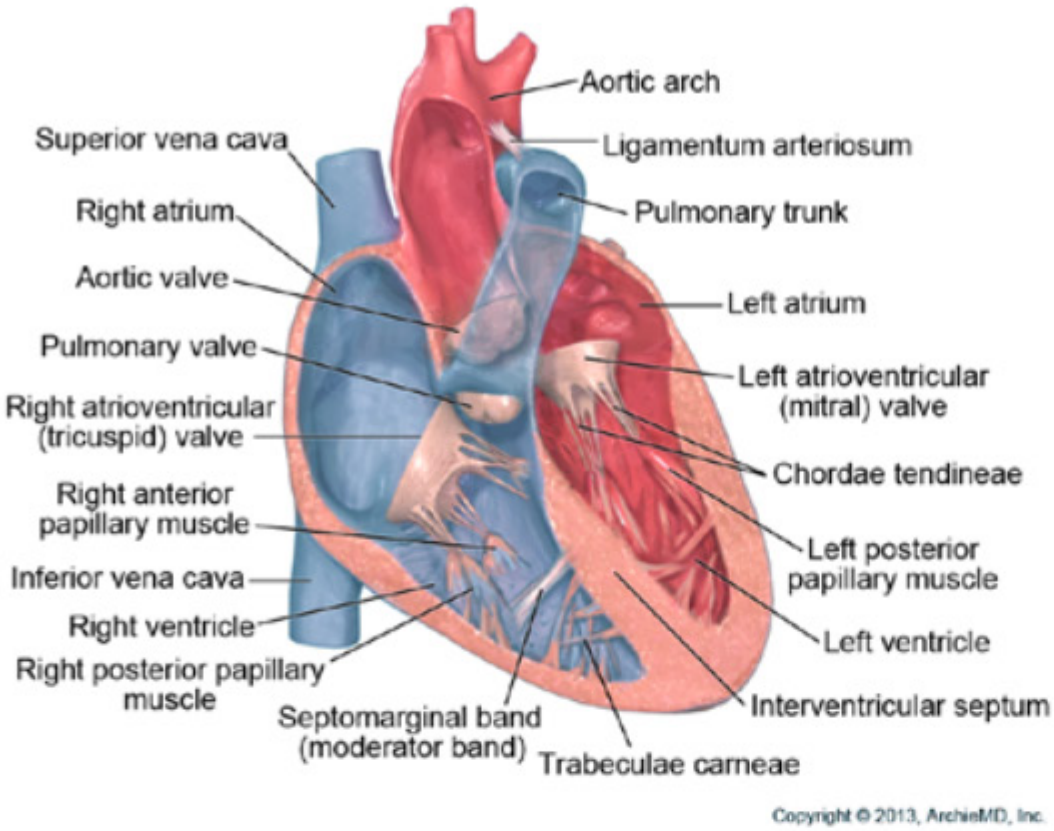

▲ **Figure 7–7.5B** Structures of Left and Right Ventricles

- **Trabeculae Carneae:** Bundles of interlacing cardiac muscle on inner wall of right ventral.
- **Papillary Muscle:** Cone-shaped muscles with bases attached to the walls of the ventricle. Tips of the papillary muscle are attached to the chordae tendineae.
- **Chordae Tendineae:** Connective tissue cords that attach the tips of the papillary muscles to the margins of the AV cusps. Prevents AV cusps from everting back into the atrium.
- **Septomarginal (Moderator) Band:** Bundle of cardiac muscle from the interventricular septum to the base of the anterior papillary muscle. The band carries components of the conduction system to the right ventricle.
- **Tricuspid Valve:** Formed by three leaflets and is between the right atrium and right ventricle.

7.5.3 Left Atrium

- **Pectinate muscles**
- **Left atrioventricular opening**
- **Is most dorsal of the chambers of the heart**
- **Opening of the pulmonary veins**

7.5.4 Left Ventricle

- **Trabeculae carneae**
- **Papillary muscles**
- **Chordae tendineae**
- **Bicuspid (Mitral) Valve:** Formed by two leaflets and is between the left atrium and left ventricle

Please visit us at www.Groupinsiders.com

© DeVry/Becker Educational Development Corp. All rights reserved.

7.6 Auscultation of Heart Sounds

Closure of the AV valves produces the S1 heart sounds, and closure of the semilunar valves produces the S2 heart sounds. Heart sounds are best heard by placing the stethoscope over the chest wall slightly downstream from the location of the valve. The scope is placed over the intercostal space, not the ribs.

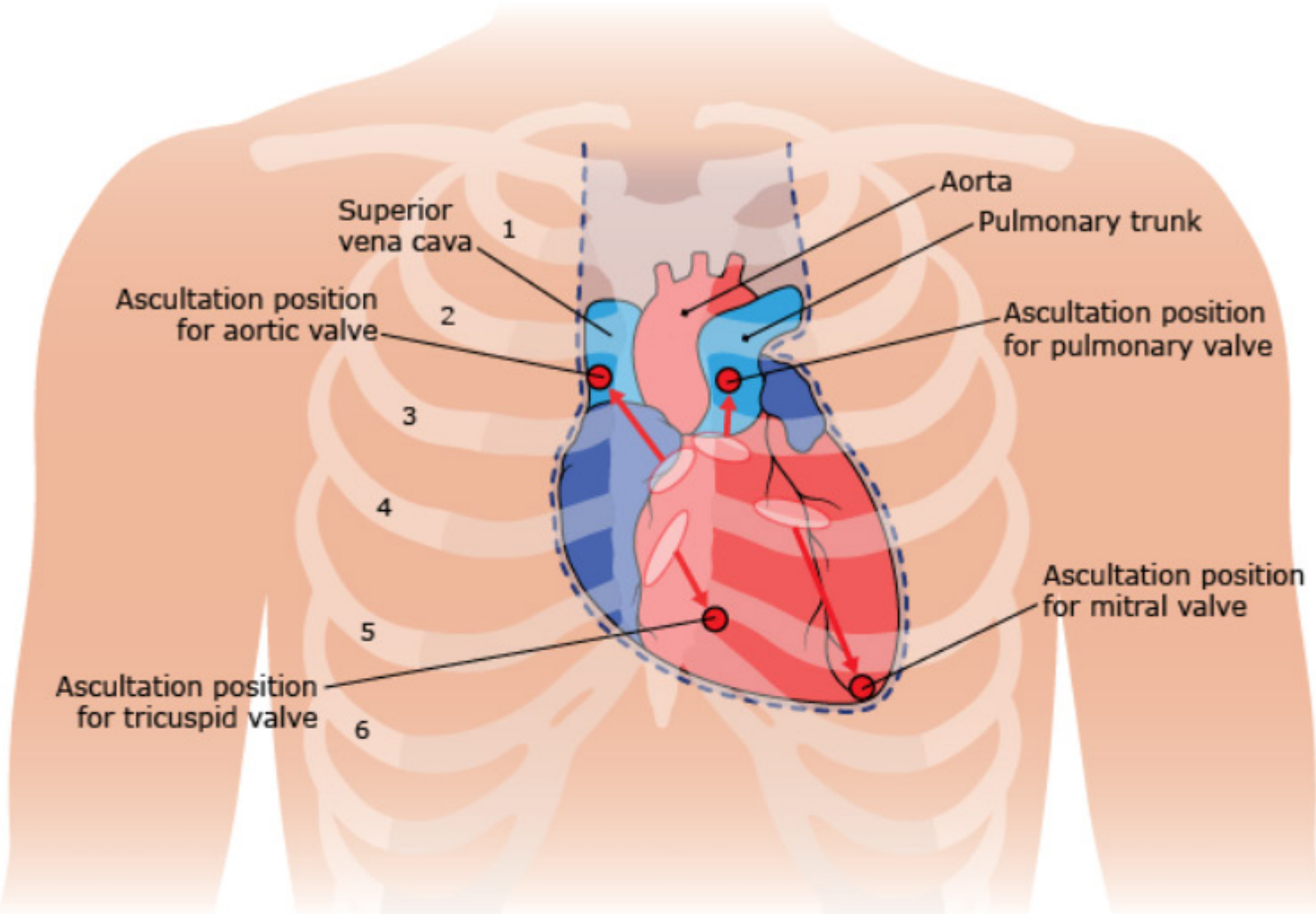

▲ **Figure 7–7.6** Heart Sounds

Important Concept

Heart Valves:

A. Semilunar valves
- Aortic
- Pulmonary

B. Atrioventricular
- Mitral or Bicuspid—left heart
- Tricuspid—right heart

Please visit us at www.Groupinsiders.com

© DeVry/Becker Educational Development Corp. All rights reserved.

7.7 Blood Supply to the Heart

7.7.1 Coronary Arteries

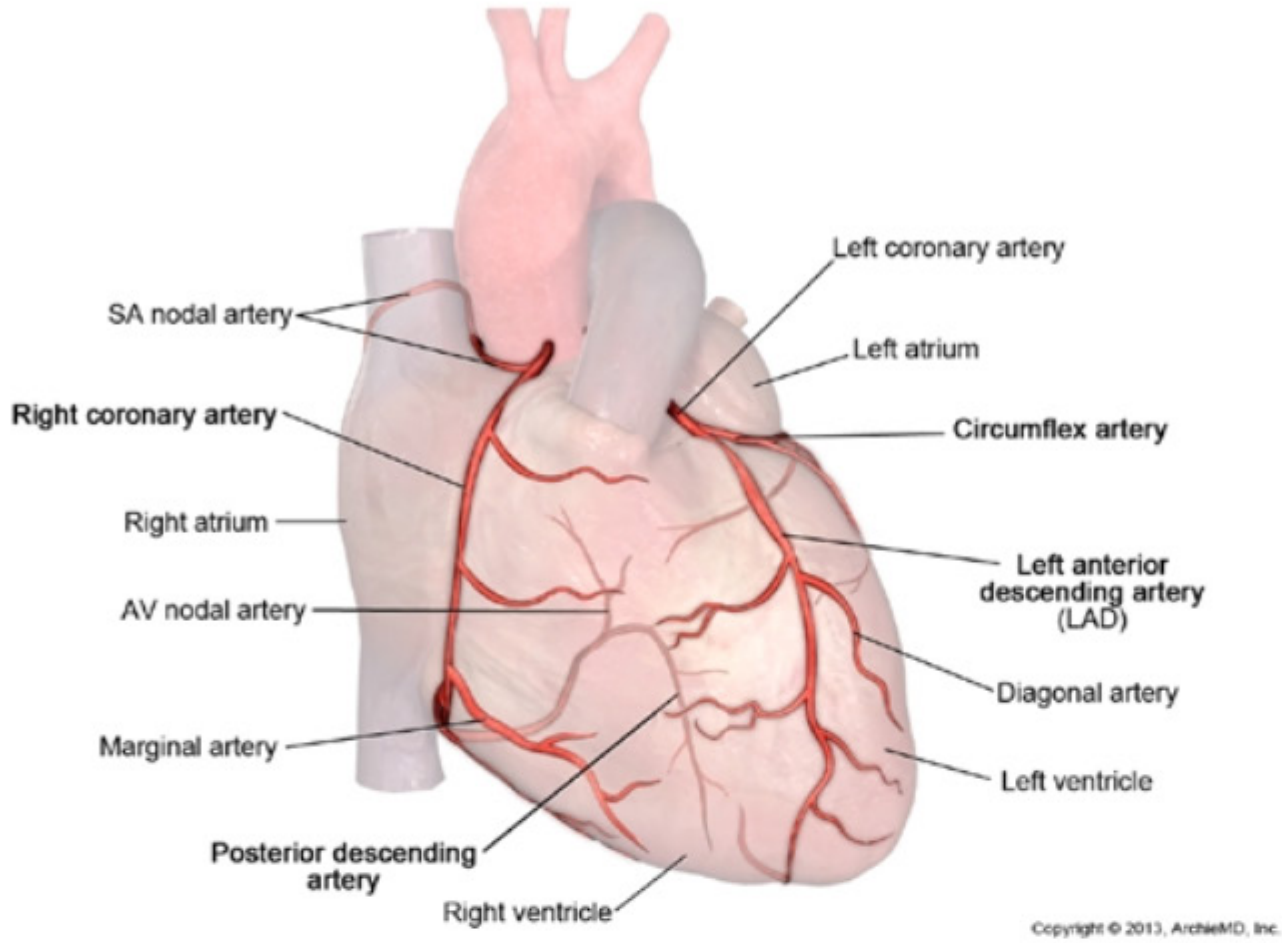

▲ **Figure 7–7.7A** Coronary Arteries

The myocardium receives its oxygenated blood supply from the *right and left coronary* arteries that arise from the *right and left aortic sinuses of the ascending aorta*, respectively. The coronary arteries receive their maximum blood flow during diastole and their lowest during systole.

7.7.2 Right Coronary Artery

The *right coronary artery* arises from the right side of the ascending aorta and courses in the *coronary sulcus* on the anterior surface of the heart. The right coronary artery then curves around the right border of the heart to continue in the coronary sulcus posteriorly. The distal end of the right artery enters the *posterior interventricular sulcus* to become the posterior interventricular artery.

The right coronary artery has three important clinical branches.

- The *SA nodal artery* is one of the first branches after the right artery leaves the ascending aorta. The SA nodal branch encircles the base of the SVC to supply the SA node of the conduction system.
- The *AV nodal artery* branches from the right coronary artery on the diaphragmatic surface of the heart as the vessel becomes the posterior interventricular artery. The AV nodal artery penetrates the interatrial septum to supply the AV node of the conduction system.
- The *posterior interventricular artery* sends septal branches to supply the posterior third of the interventricular septum.

Please visit us at www.Groupinsiders.com

© DeVry/Becker Educational Development Corp. All rights reserved.

7.7.3 Left Coronary Artery

The *left coronary artery* runs a short distance from the ascending artery between the left auricle and left ventricle within the coronary sulcus and divides into its two terminal branches: *anterior interventricular artery* (left anterior descending artery) and the *circumflex artery*.

The *anterior interventricular artery* descends in the anterior ventricular interventricular sulcus and supplies:

- *Anterior surfaces* of the right and left ventricles.
- *Obtuse (diagonal) branches* to the anterior left ventricular wall.
- *Septal branches* to the anterior two thirds of the interventricular septum and the bundle of His.

The *circumflex artery* courses around the left border of the heart in the coronary sulcus and supplies the left border and posterior aspect of the left ventricle.

7.7.4 Major Cardiac Veins

- The *coronary sinus* is the largest vein draining the heart and courses posteriorly in the coronary sulcus, separating the atria from the ventricles.
  - Develops from the left sinus venosus of the heart tube.
  - The coronary sinus drains into the right atrium and is partially guarded by the valve of the coronary sinus.
  - It receives all of the venous drainage from the heart except for the anterior cardiac veins and thebesian veins.
- The *great cardiac vein* courses with the anterior interventricular artery in the anterior interventricular sulcus on the sternocostal surface of the heart. It ascends into the coronary sulcus and drains into the coronary sinus.
- The *middle cardiac vein* courses with the posterior interventricular artery and drains into the coronary sinus.

Please visit us at www.Groupinsiders.com

© DeVry/Becker Educational Development Corp. All rights reserved.

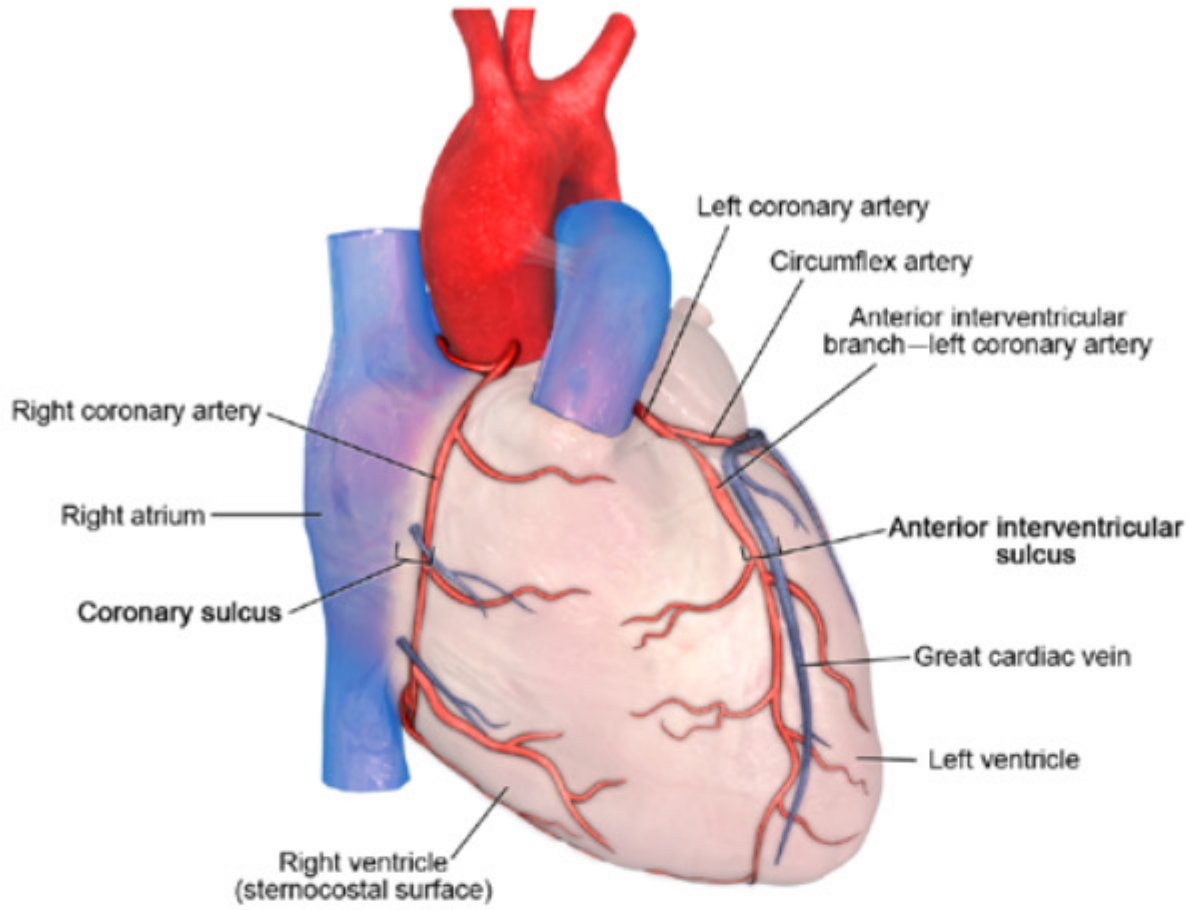

Clinical Application

The anterior interventricular artery is the most common site for coronary occlusion.

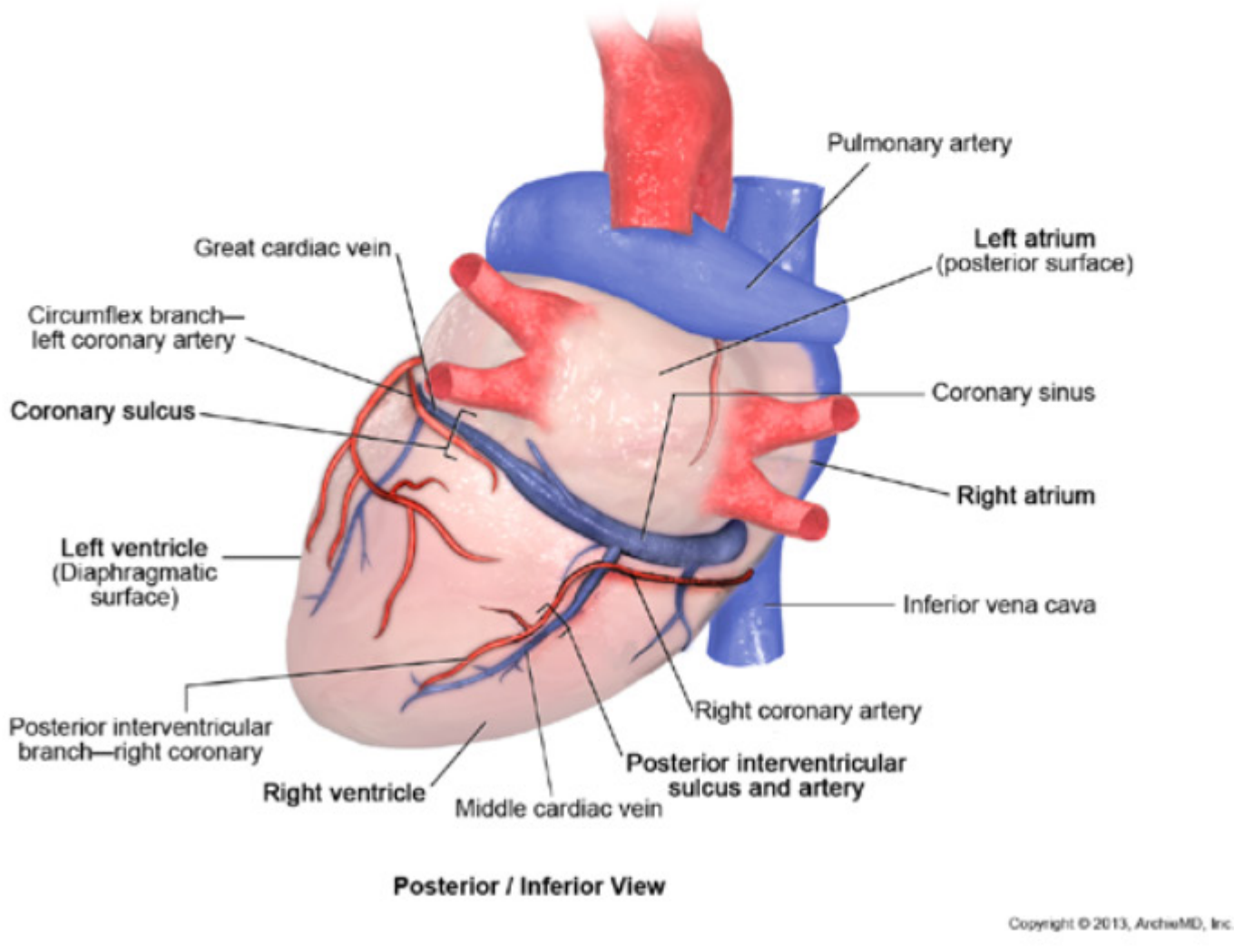

▲ **Figure 7–7.7B** Cardiac Veins

Please visit us at www.Groupinsiders.com

© DeVry/Becker Educational Development Corp. All rights reserved.

7.8 Conduction System of the Heart

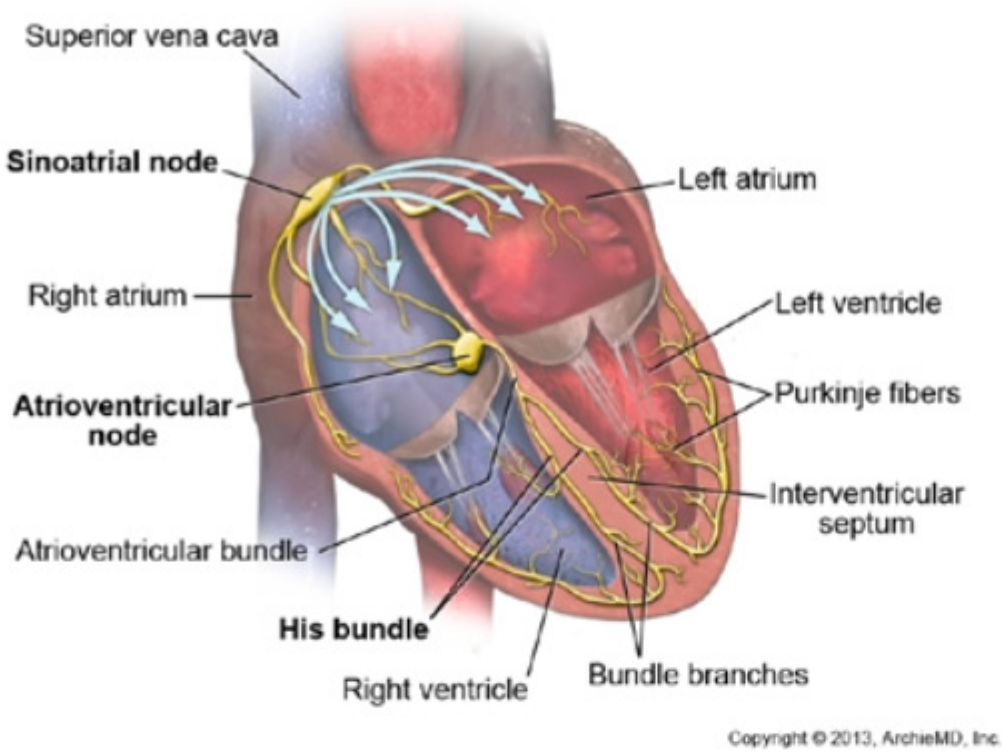

▲ **Figure 7–7.8** Conducting System

The conducting system is composed of modified cardiac muscle that carries the impulses throughout the heart, ensuring that the chambers contract in the correct sequence.

The conducting system is governed by the ANS.

- The vagus nerve provides parasympathetic innervation.
- The thoracic cord segments T1–T5 provide sympathetic innervation.

7.8.1 Sinoatrial Node

The SA node is located on the anterior aspect of the base of the SVC, where it drains into the right atrium. It is referred to as the pacemaker of the heart, because it can initiate the heartbeat. Impulses from the SA node spread throughout the atrial muscle fibers to the AV node. The SA node is supplied by the nodal branch of the right coronary artery.

7.8.2 AV Node

The AV node is located in the lower part of the interatrial septum adjacent to the opening of the coronary sinus. The AV node delays the depolarization from the atria to the ventricles allowing the atria to complete contracting before the ventricles. The AV node is supplied by the nodal branch of the right coronary artery.

7.8.3 AV Bundle of His

The AV bundle is located in the upper part of the interventricular septum, where it divides into *the right and left bundle branches*. The two bundles descend in the interventricular septum to form *Purkinje fibers* that spread throughout the ventricular muscle. The AV bundle is supplied by the septal branches of the anterior interventricular artery.

Please visit us at www.Groupinsiders.com

© DeVry/Becker Educational Development Corp. All rights reserved.

8 Overview of Mediastinum

8.1 Mediastinum

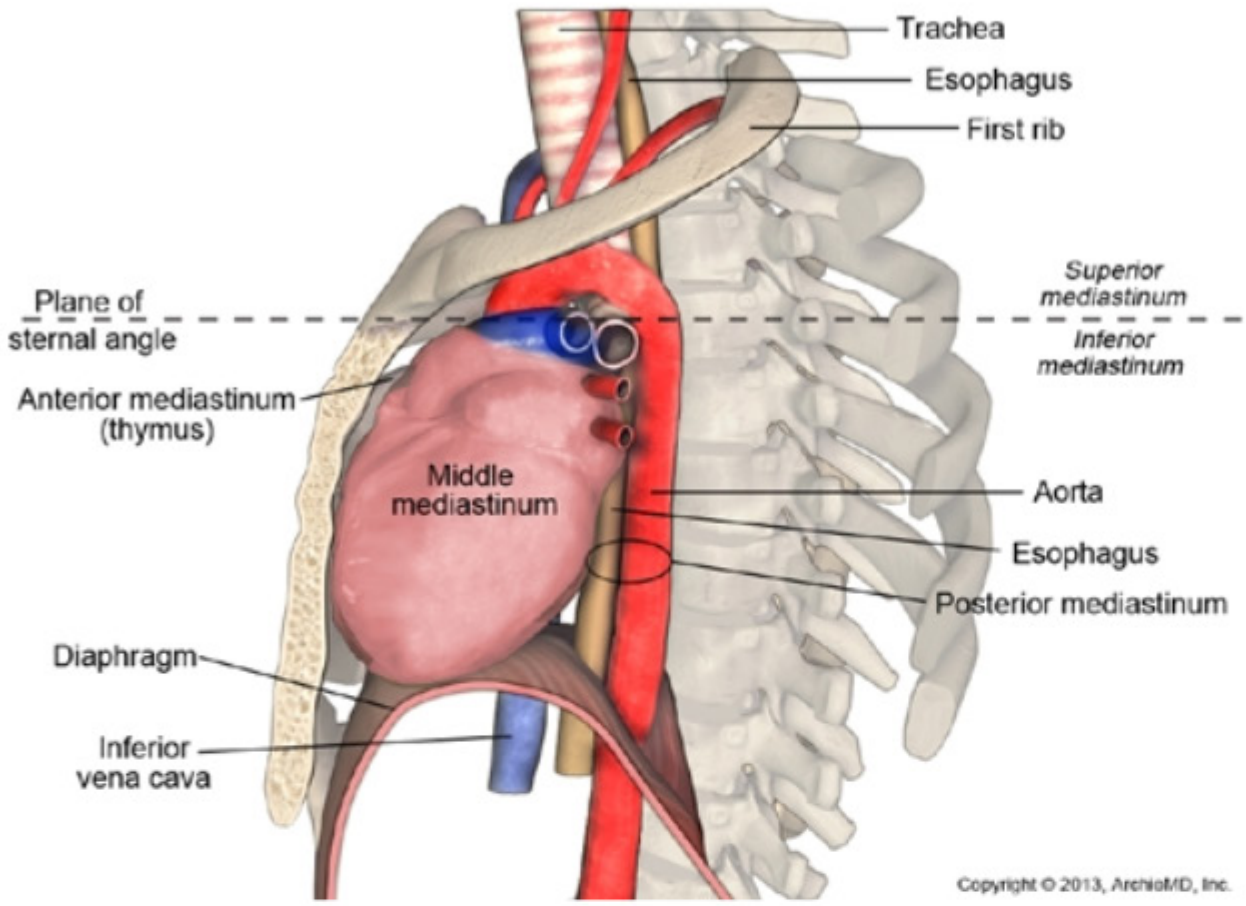

▲ **Figure 7–8.1** Mediastinum

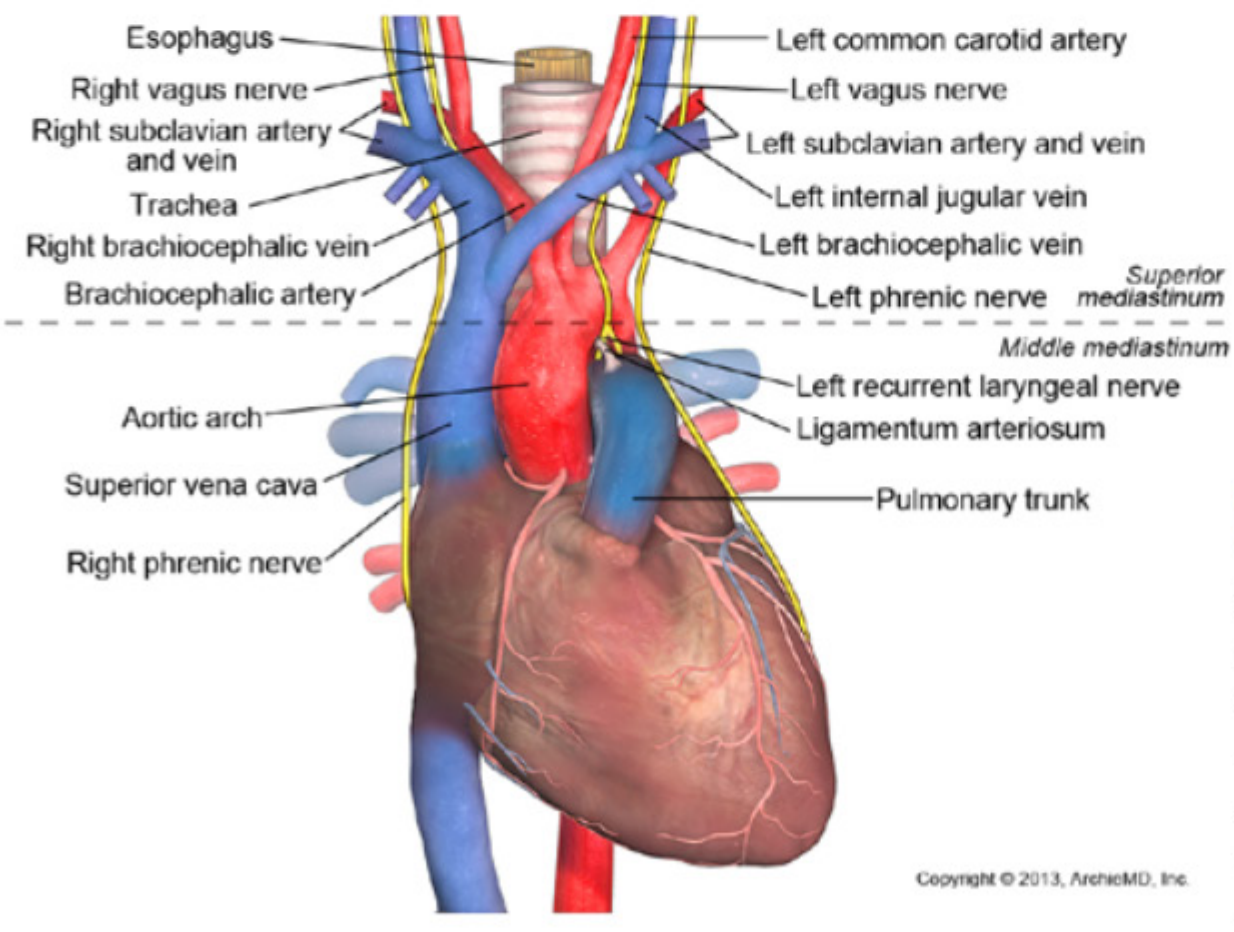

▲ **Figure 7–8.2** Superior Mediastinum

Important Concept

Ventral to Dorsal:

- Sternum
- Thymus
- Brachiocephalic veins
- Aortic arch and branches
- Trachea
- Esophagus
- Vertebra

Please visit us at www.Groupinsiders.com

© DeVry/Becker Educational Development Corp. All rights reserved.

8.2 Superior Mediastinum

The *superior mediastinum* is the region superior to the horizontal plane of the sternal angle. Anteriorly, it is bounded by the manubrium of the sternum and posteriorly by T1–4 vertebrae. The superior mediastinum is continuous superiorly through the superior thoracic aperture (formed by the first rib, sternum, and T1 vertebra) into the neck. The lungs and pleurae form the lateral boundaries.

The relationships of the contents of the superior mediastinum are critical for cross-sectional radiology. These contents are listed below in a ventral-to-dorsal relationship:

- **Sternum**
- **Thymus**
- **Venous Plane:** The veins at this level are the *right and left brachiocephalic veins*.
  - The *right brachiocephalic vein* is shorter and more vertical, while the *left brachiocephalic vein* runs a longer, oblique left-to-right course across the superior mediastinum.
  - The two brachiocephalic veins become confluent *posterior to the first costal cartilage* to form the *superior vena cava* that descends and drains into the right atrium at the third rib.
  - Note that the *aortic arch* is *inferior* to the left brachiocephalic vein, but the three *branches of the aortic arch* (brachiocephalic, left common carotid, left subclavian) arise from the arch *posterior* to the left vein.
- **Arterial Plane:** Formed by the *aortic arch* (inferior to the left brachiocephalic vein) and its three branches (posterior to the left vein): *brachiocephalic*, *left common carotid*, and *left subclavian arteries*.
- **Trachea:** Descends close to the midline and *bifurcates at the T4 vertebral* level in the right and left main (primary) bronchi. Note that as long as a cross-sectional image contains a central trachea in the mediastinum suggest that image is through the superior mediastinum.
- **Esophagus**
- **Vertebrae**

Other structures within the superior mediastinum include the:

- **Azygos Vein:** Drains into the superior vena cava
- Superior **e**nd of the **t**horacic **d**uct
- **Right and Left Phrenic Nerves:** The phrenic nerves derive for the cervical plexus (C3, C4, C5 ventral rami) in the posterior triangle of the neck and descend through the thoracic inlet into the superior mediastinum. The nerves course *ventral* to the hila of the lungs and through the middle mediastinum on the lateral surface of each side of the pericardium to reach the diaphragm.
- **Right and Left Vagus Nerves:** The *right vagus nerve* passes against the right side of the trachea. The *left vagus nerve* crosses the left side of the aortic arch and the ligamentum arteriosum, where the left vagus gives rise to the *left recurrent laryngeal nerve*.
  - Note that the right recurrent laryngeal nerve does not course in the mediastinum because it is a branch of the right vagus superiorly in the neck.

The left vagus nerve and the left recurrent laryngeal nerve are vulnerable to pathologies occurring in the superior mediastinum (aortic aneurysm, metastatic pulmonary cancer). The patient presents with a fixed vocal fold on the left side. Note that the right vocal fold is not involved because the right recurrent nerve is not located in the superior mediastinum. Thyroid surgery can damage either one of the nerves.

Please visit us at www.Groupinsiders.com

© DeVry/Becker Educational Development Corp. All rights reserved.

- The recurrent laryngeal nerves on both sides ascend the neck deep to the thyroid gland to enter the larynx and innervate all of the muscles of the vocal fold except one.
- The two vagus nerves leave the superior mediastinum by passing *posteriorly* to the hila of the lungs and coursing in the posterior mediastinum on the surfaces of the esophagus, where they form the esophageal plexus.

8.3 Posterior Mediastinum

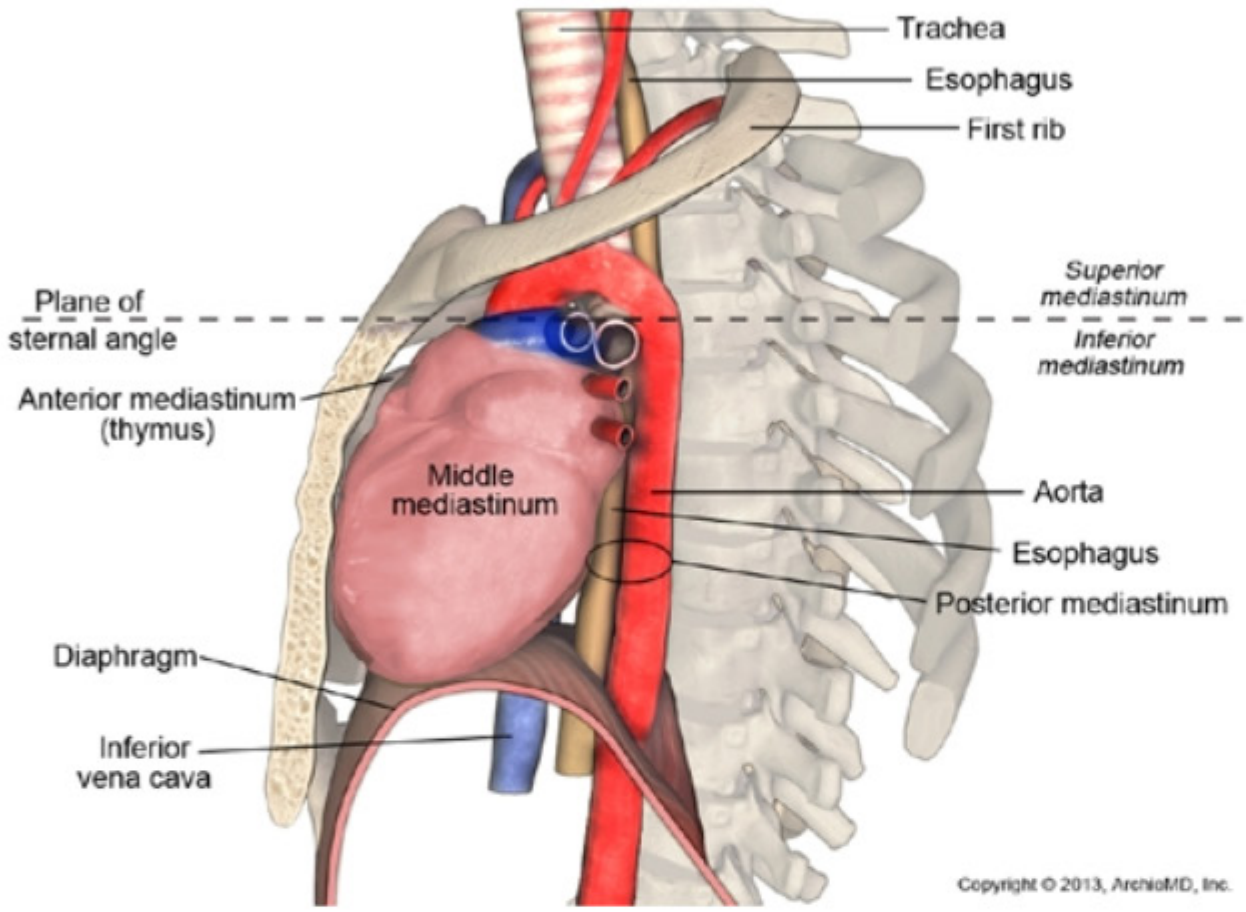

▲ **Figure 7–8.3** Posterior Mediastinum

The *posterior mediastinum* lies inferior to the horizontal plane of the sternal angle and is wedged between the posterior surface of the pericardium of the heart and the thoracic vertebrae T5–T12. Inferiorly, the posterior mediastinum is closed off by the diaphragm.

Structures of the posterior mediastinum include:

- **Thoracic Aorta**
  - Descends on the left side of the vertebrae and passes through the aortic hiatus of the diaphragm at *T12 vertebra*.
  - Provides blood supply to the chest wall (nine posterior intercostal arteries and one subcostal artery).
  - Provides blood supply to lungs and esophagus.
- **Esophagus**
  - Courses posterior to the left bronchus.
  - Courses *posterior to* and indents the *left atrium, an important radiological landmark*.
  - The esophageal nerve plexus (vagus and sympathetic nerves) forms on the anterior and posterior surfaces of the esophagus.
  - Passes through the esophageal hiatus of the diaphragm at the *T10 vertebra*.

Please visit us at www.Groupinsiders.com

© DeVry/Becker Educational Development Corp. All rights reserved.

- **Azygos Venous System**
  - Drains veins of the posterior thoracic wall.
  - Connects with inferior vena cava via veins in the abdomen and drains into the superior vena cava in the mediastinum.
  - Establishes collateral venous connections between the two vena cava.
- **Thoracic Duct**
  - Begins in the abdomen and ascends through the aortic hiatus of the abdomen to enter the posterior mediastinum.
  - Ascends the posterior mediastinum between the aorta and azygos vein.
  - Continues superiorly through the superior mediastinum to drain into the junction of the left subclavian vein and left internal jugular vein.
  - Is the largest lymphatic vessel of the body and drains all of the body except the right chest and the right head and neck.

8.4 Diaphragm

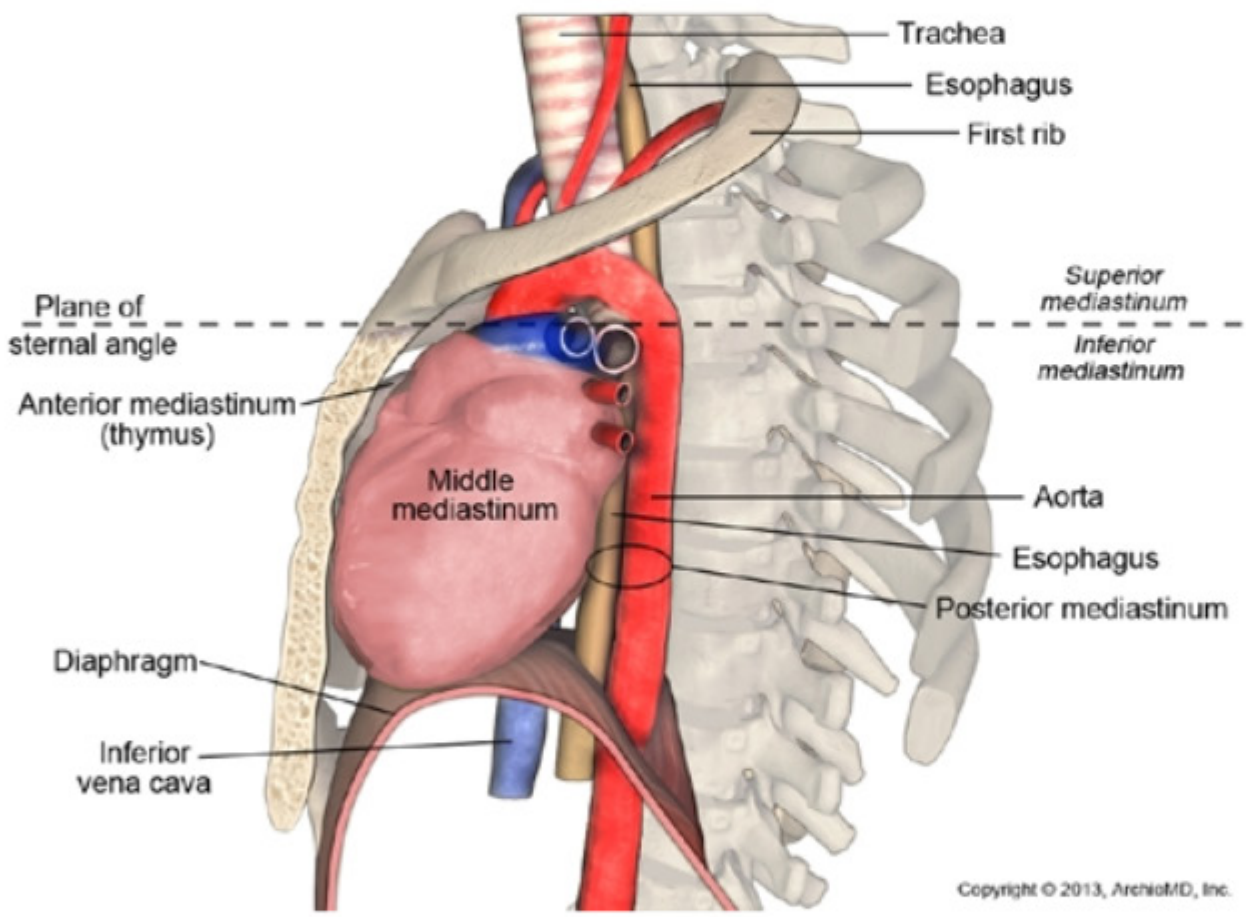

▲ **Figure 7–8.4** Diaphragm

The *diaphragm* separates the thoracic and abdominal cavities, and consists of skeletal muscle and a central tendon.

- The peripheral muscle fibers of the diaphragm attach to the xiphoid process, lower ribs, and the upper three lumbar vertebrae (right and left crura).
- Motor innervation and part of its sensory innervations are provided by the *phrenic nerve (C3, C4, and C5)* of the cervical plexus.

Please visit us at www.Groupinsiders.com

© DeVry/Becker Educational Development Corp. All rights reserved.

- Three apertures are associated with the diaphragm that transmit structures between the thoracic and abdominal cavities.
  - The *caval opening* is at the level of the *T8 vertebra* and transmits the *inferior vena cava* and the right phrenic nerve.
  - The *esophageal opening* is located in the right crus of the diaphragm at the level of *T10 vertebra* and transmits the *esophagus* and the *anterior and posterior vagal trunks*.
  - The *aortic opening* is located at the level of *T12 vertebra* between the two crura of the diaphragm and transmits the aorta, azygos vein, and thoracic duct.

8.4.1 Congenital Diaphragmatic Hernia

A congenital diaphragmatic hernia is usually caused by failure of the pleuroperitoneal membranes to close the pericardoperitoneal canals. The defect results in continuity between the peritoneal and pleural cavities and herniation of the abdominal contents (intestines, stomach, spleen, part of the liver) into the pleural cavity.

The presence of the abdominal viscera hinders the growth of the lung during development, resulting in hypoplastic lung at birth. A significant large defect has a high rate of mortality (75%), due to pulmonary dysfunction.

Esophageal Hernia

An esophageal hernia results from a weakening of the esophageal hiatus that allows the stomach to herniate into the thoracic cavity. The individual will have esophageal reflux, constriction of the esophagus or stomach. Damage to the vagal nerve fibers may occur.

Please visit us at www.Groupinsiders.com

© DeVry/Becker Educational Development Corp. All rights reserved.

9 Radiology Images

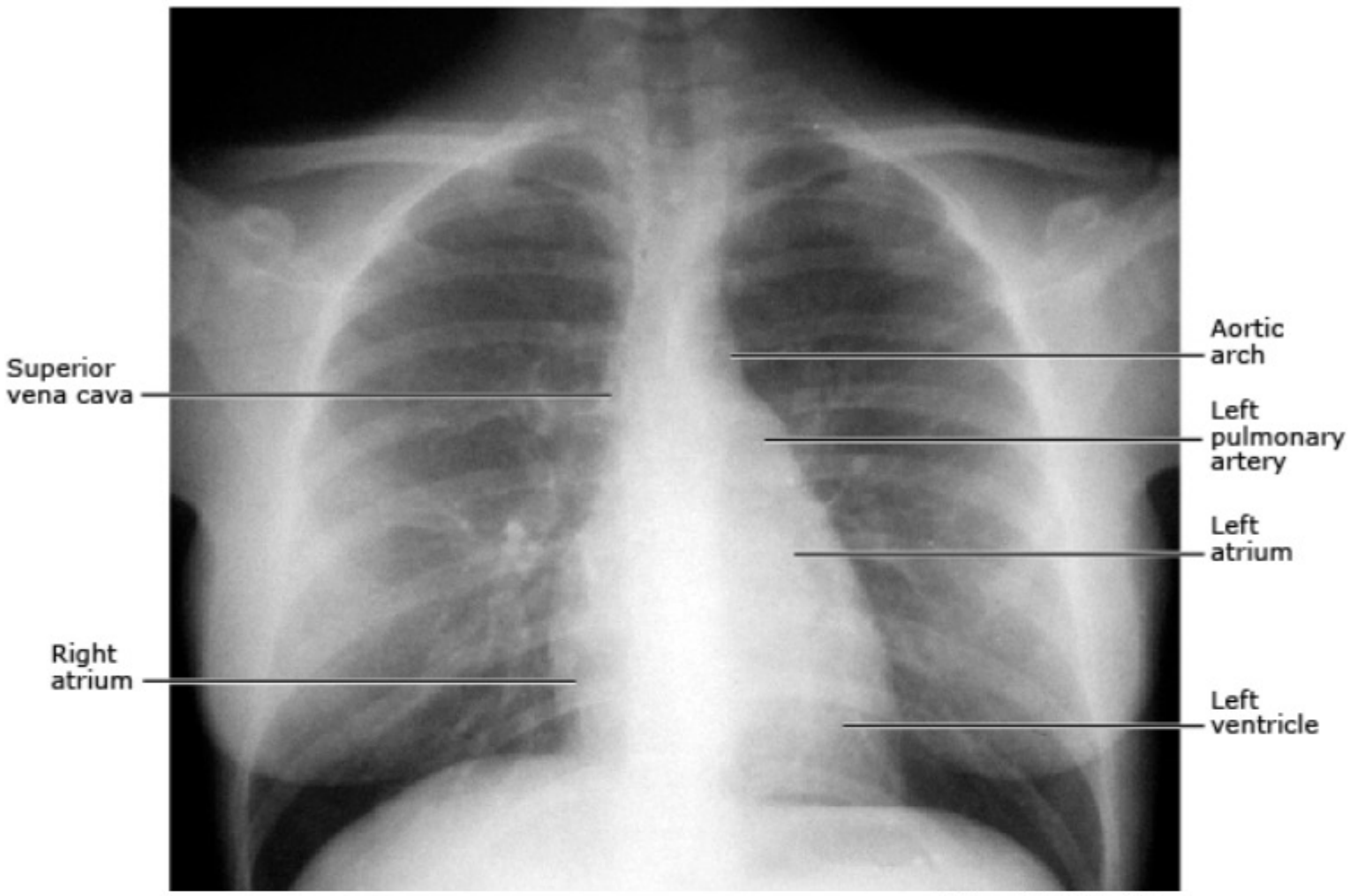

L. Bassett/Visuals Unlimited, Inc.

▲ **Figure 7–9.0A** Anterior Chest

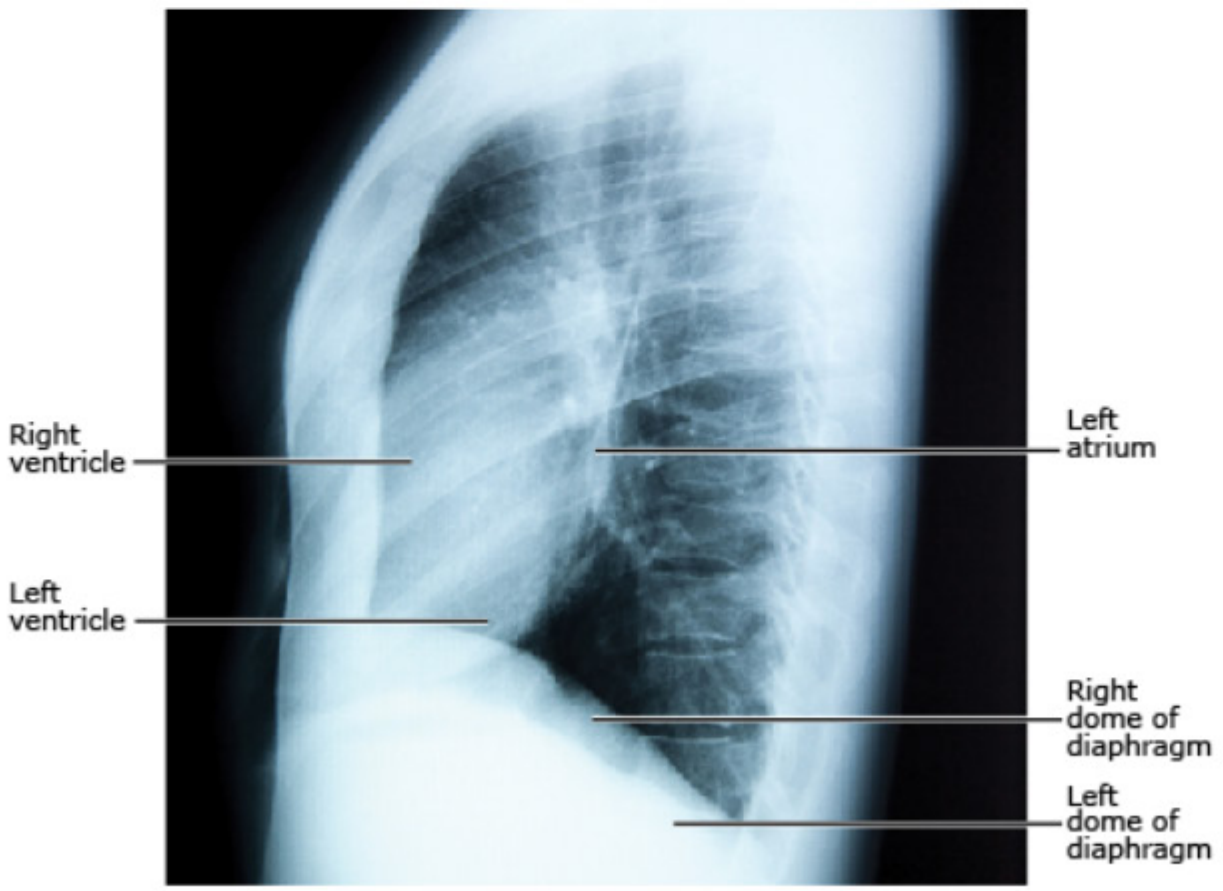

Warrick G./Science Source

▲ **Figure 7–9.0B** Lateral Chest

Please visit us at www.Groupinsiders.com

© DeVry/Becker Educational Development Corp. All rights reserved.

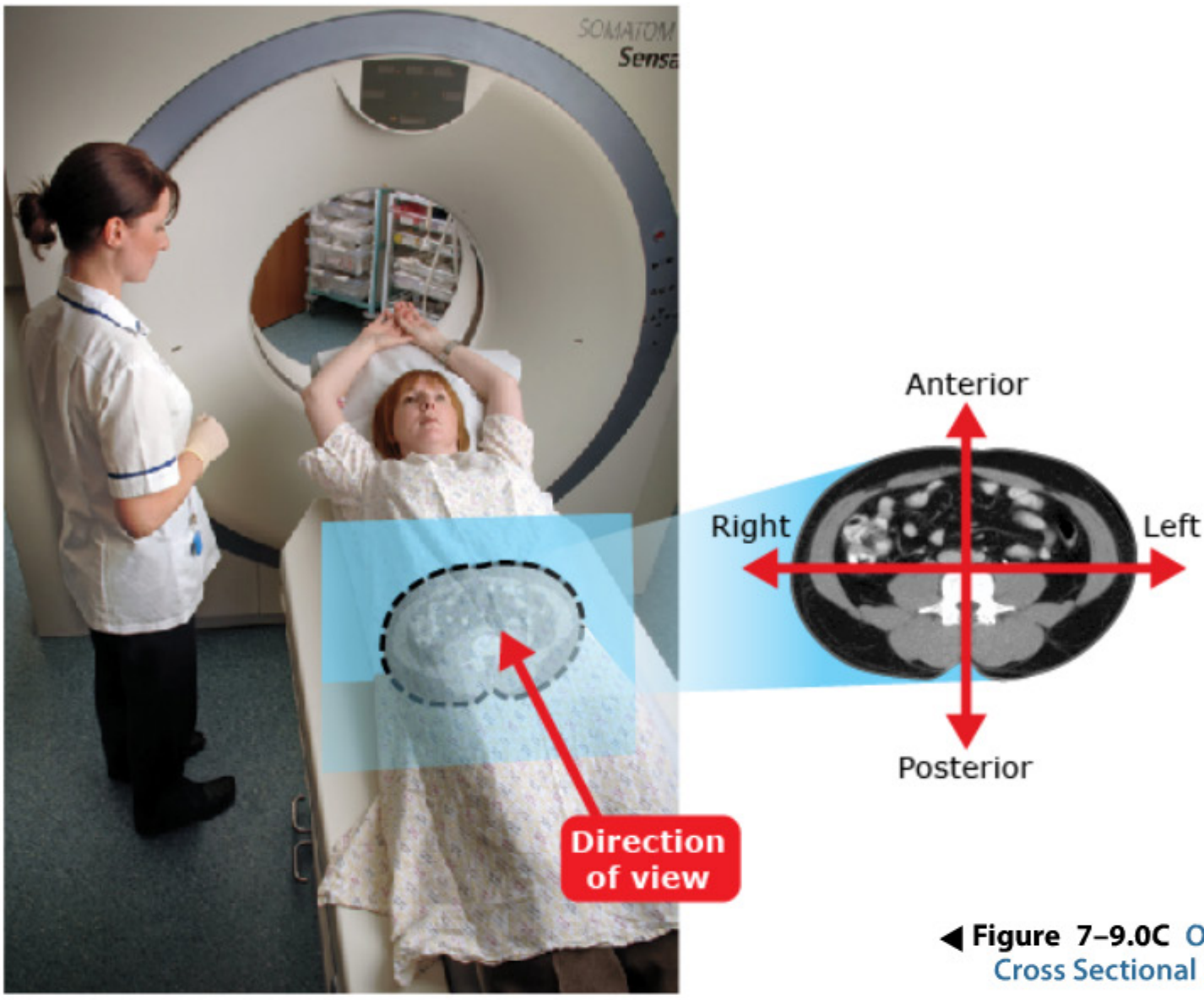

Tim Vernon, LTH NHS Trust/Science Source.

◀ **Figure 7–9.0C** Orientation of Cross Sectional Imaging

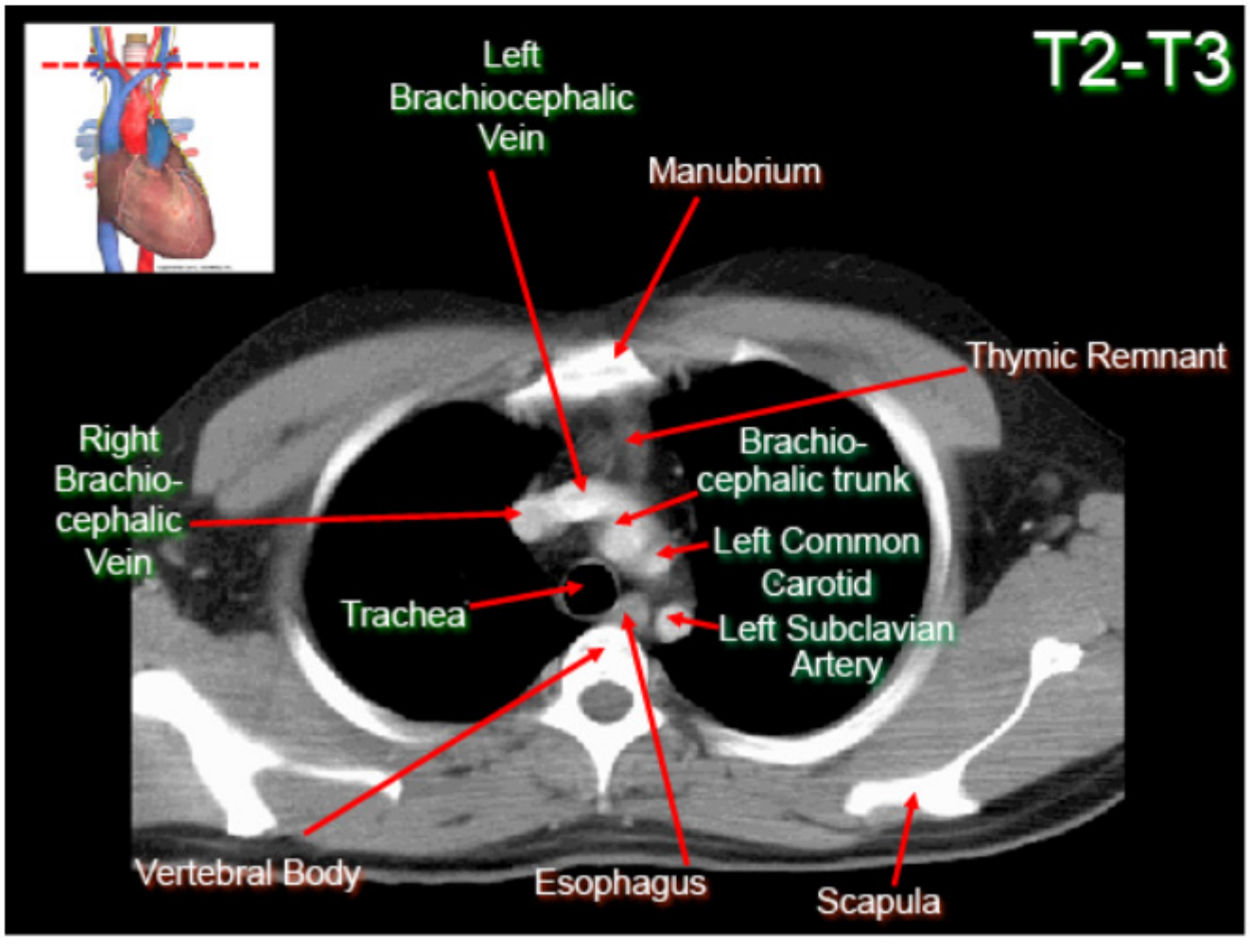

◀ **Figure 7–9.0D** Thorax CT

Please visit us at www.Groupinsiders.com

© DeVry/Becker Educational Development Corp. All rights reserved.

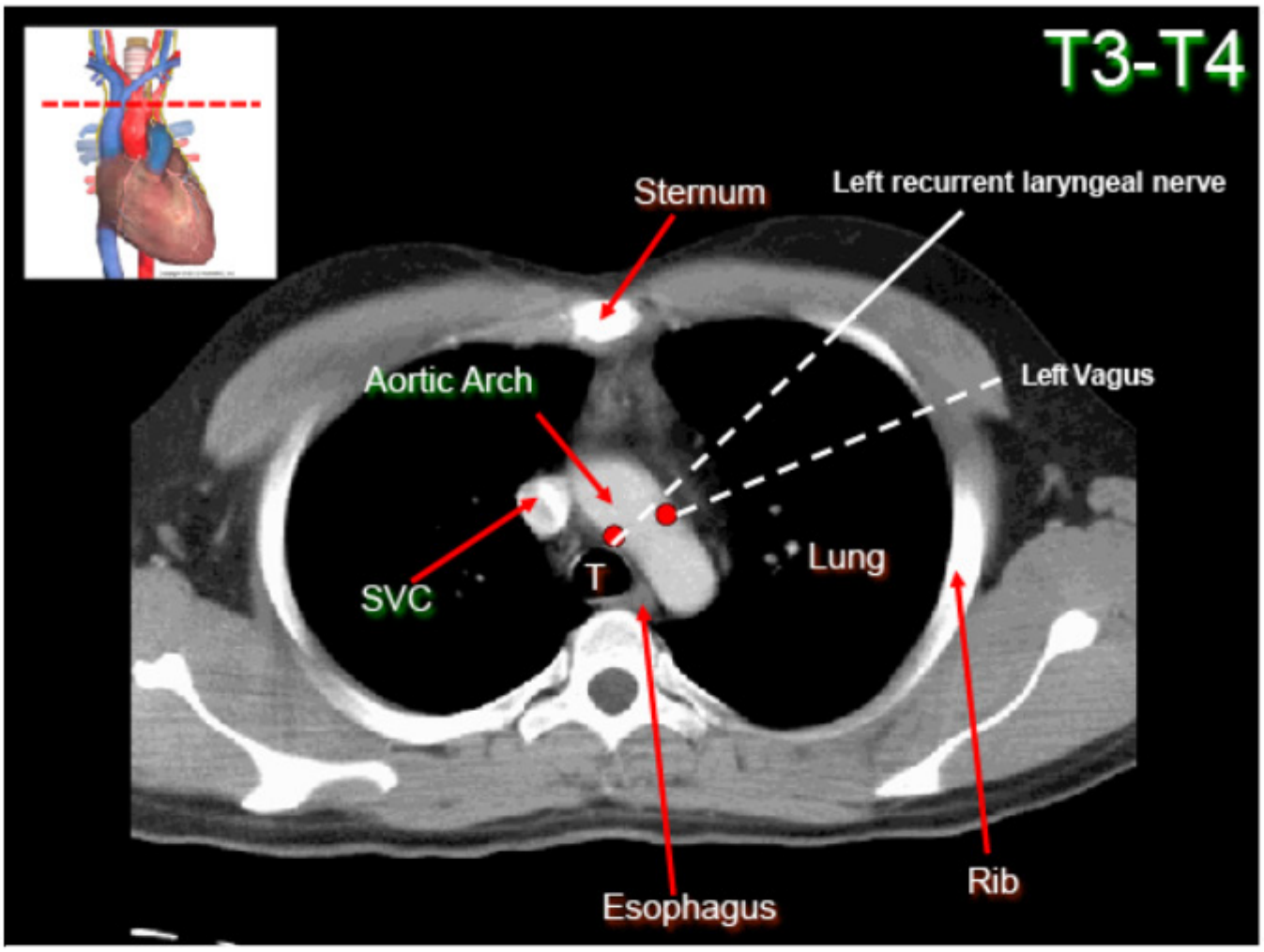

▲ **Figure 7–9.0E** Thorax CT

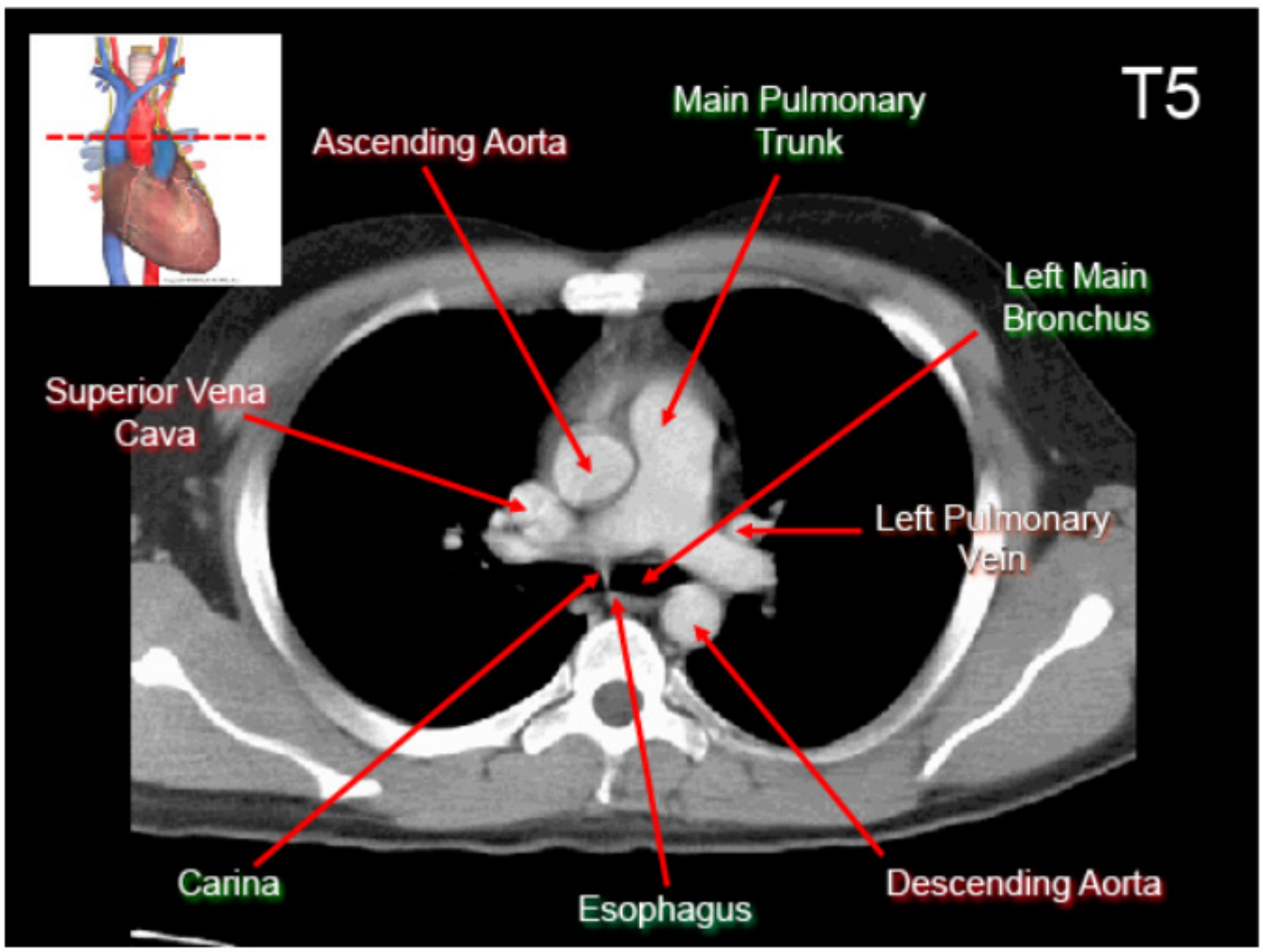

▲ **Figure 7–9.0F** Thorax CT

Please visit us at www.Groupinsiders.com

© DeVry/Becker Educational Development Corp. All rights reserved.

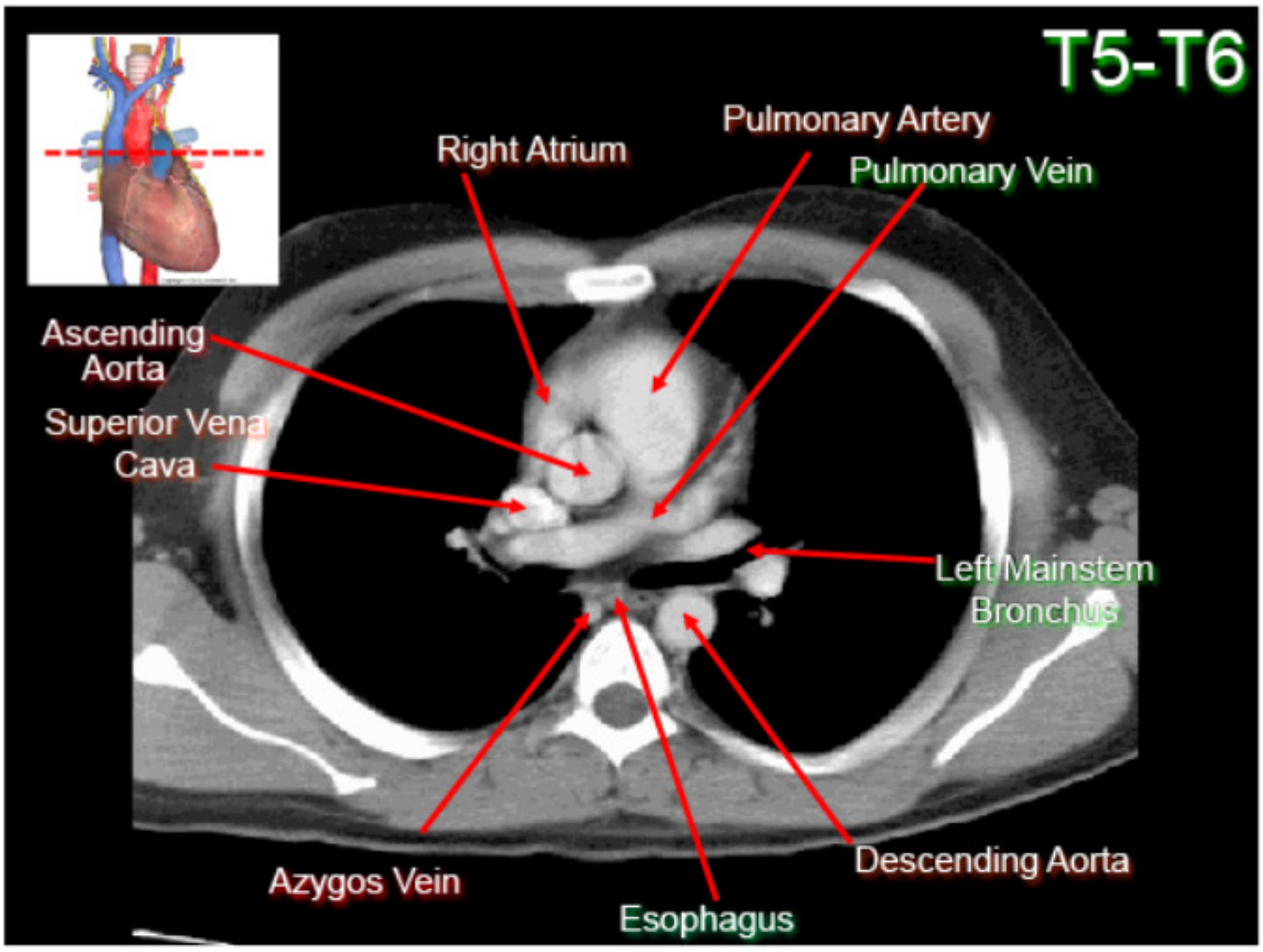

▲ **Figure 7–9.0G** Thorax CT

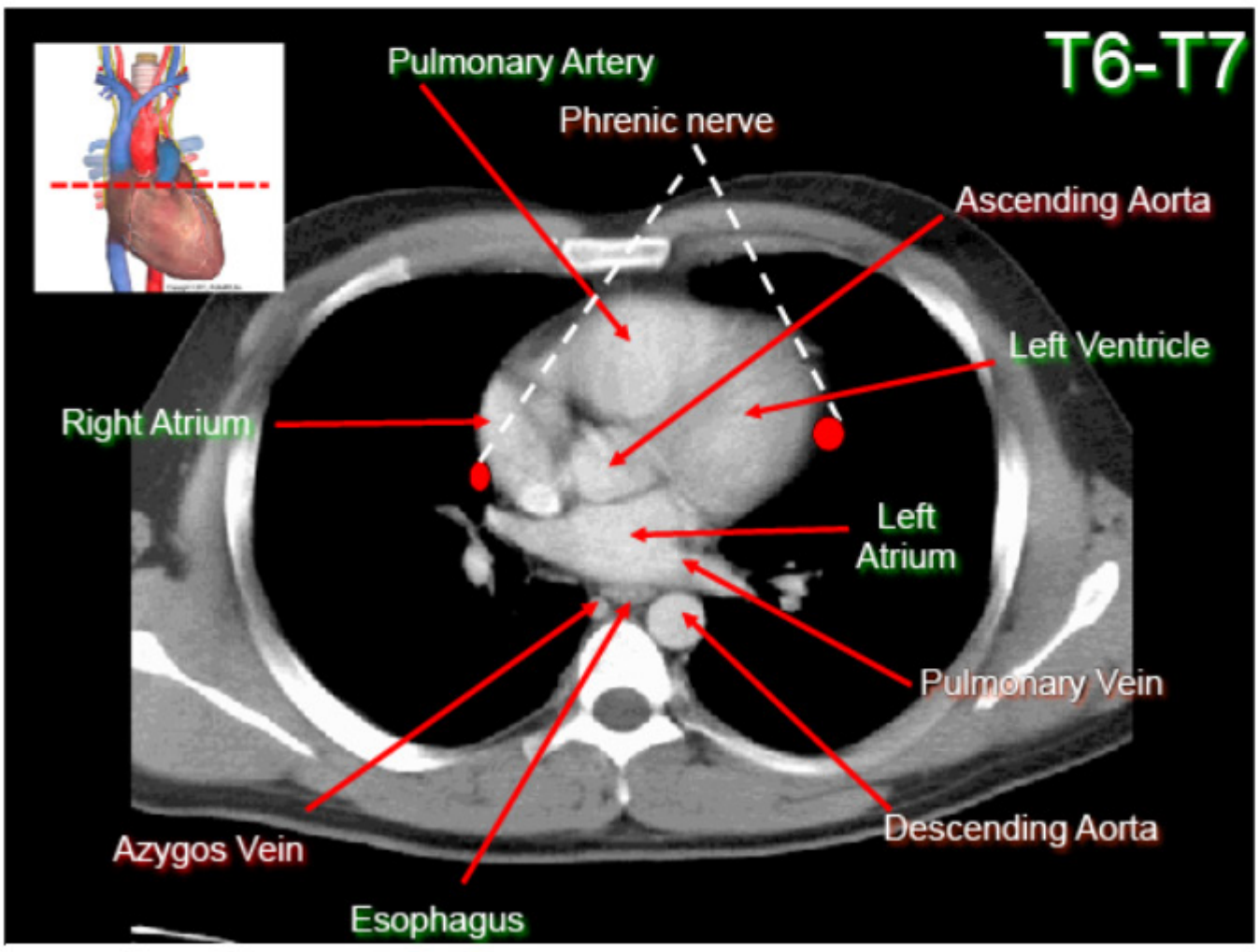

▲ **Figure 7–9.0H** Thorax CT

Please visit us at www.Groupinsiders.com

© DeVry/Becker Educational Development Corp. All rights reserved.

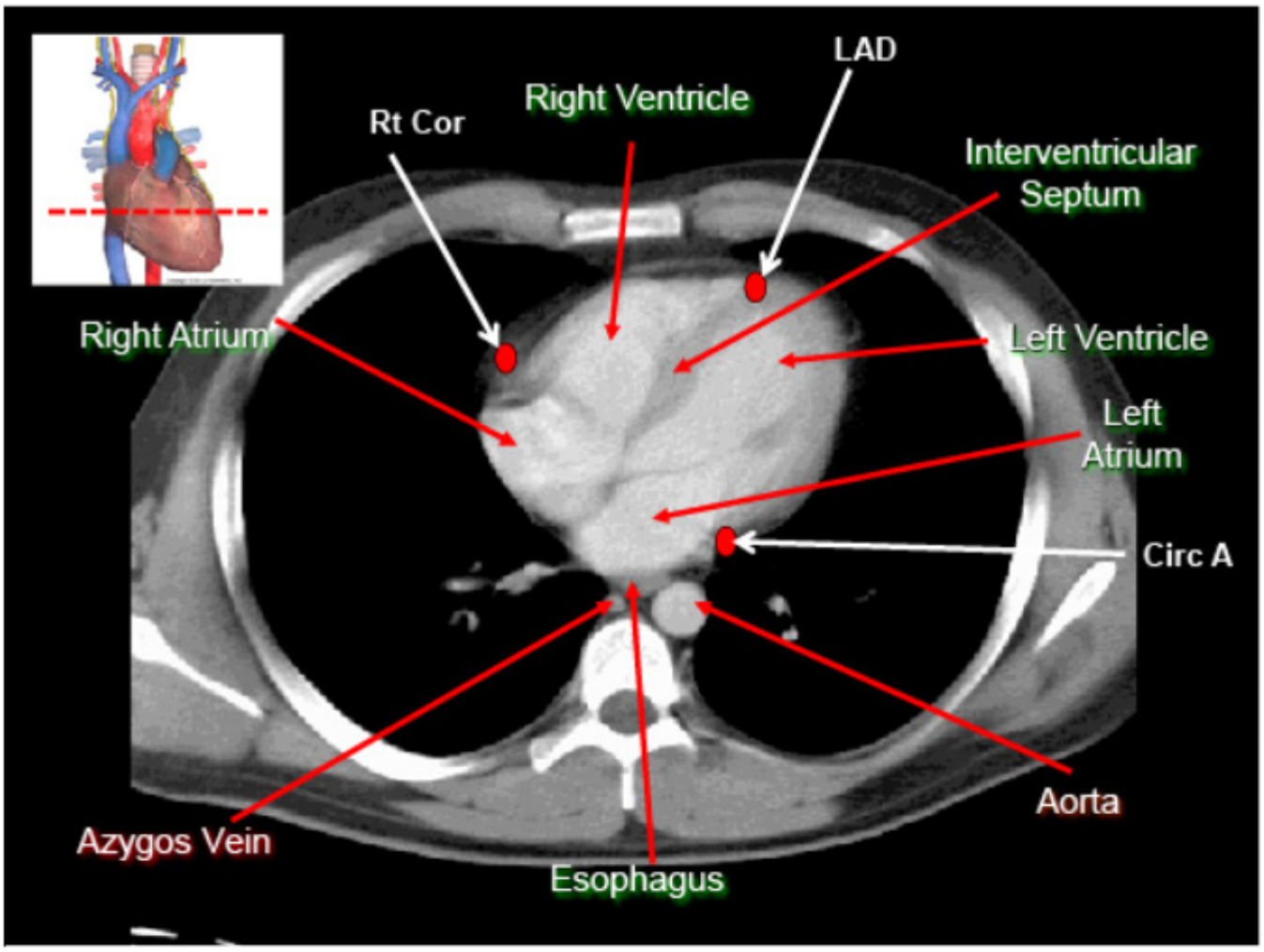

▲ **Figure 7–9.0l** Thorax CT

Please visit us at www.Groupinsiders.com

© DeVry/Becker Educational Development Corp. All rights reserved.

Chapter 7 Review Questions

1. A 45-year-old man comes to the emergency room with crushing chest pain. His lab studies reveal elevated cardiac enzymes suggesting a myocardial infarction. His EKG confirms akinetic segments of the part of the interventricular septum containing the bundle of His. Which coronary vessel is most likely to have been obstructed?

A. Right coronary artery
B. Circumflex coronary artery
C. Posterior interventricular coronary artery
D. Anterior interventricular coronary artery
E. AV nodal artery

2. The ductus arteriosus is one of several vascular shunts that develop during fetal circulation. The function of the ductus arteriosus in the fetus is correctly described by which of the following statements?

A. Shunts deoxygenated blood from the pulmonary veins to the left atrium
B. Shunts deoxygenated blood from the pulmonary artery to the aorta
C. Shunts oxygenated blood from the aorta to the pulmonary artery
D. Shunts oxygenated blood from the pulmonary artery and the aorta
E. Bypasses the lungs with oxygenated blood

Please visit us at www.Groupinsiders.com

© DeVry/Becker Educational Development Corp. All rights reserved.

Review Questions Chapter 7

3. A newborn has right heart enlargement due to shunting of blood from the left to the right atrium. A large, high defect was identified in the upper part of the interatrial septum. Which of the following would be characteristic of this genetic defect?

A. A neural crest migration defect
B. A cyanotic defect
C. A patent first foramen (primum)
D. A patent foramen ovale
E. An interventricular septal defect

4. A patient comes to the emergency room with a knife wound to the chest on the right side of the sternum at the second intercostal space. During surgery, which of the following would have to be repaired to stop the hemorrhaging?

A. Right atrium
B. Superior vena cava
C. Right ventricle
D. Left atrium
E. Right pulmonary veins

5. A 34-year-old male is admitted to the hospital with a large aortic arch aneurysm. Which of the following signs or symptoms would the physician expect to observe in this patient?

A. Decreased emptying of the stomach
B. Paralysis of the right vocal fold
C. Horner syndrome
D. Weakness of diaphragm function
E. Decreased sensitivity of the parietal pleura on the right lung

Please visit us at www.Groupinsiders.com

© DeVry/Becker Educational Development Corp. All rights reserved.

Chapter 7 Review Questions

6. By percussion, the physician is trying to locate the position of the costodiaphragmatic recess on the lateral aspect of the right chest wall. In which of the following locations would the physician expect to identify the recess?

A. Inferior to the fourth rib
B. Superior to the horizontal fissure
C. Superior to the oblique fissure
D. Between the opposed surfaces of the diaphragmatic and mediastinal pleura
E. Inferior to the ninth rib

7. A newborn presents with cyanosis. An echocardiogram indicates a heart anomaly with a right-to-left shunt but without a membranous VSD. Which of the following conditions most likely produced this type of shunt?

A. Secundum atrial septal defect
B. Transposition of the great vessels
C. Interventricular septal defect
D. Tetralogy of Fallot
E. Persistent truncus arteriosus

Please visit us at www.Groupinsiders.com

© DeVry/Becker Educational Development Corp. All rights reserved.

Review Answers Chapter 7

1. The correct answer is C.
The interventricular septum has two blood supplies. The anterior aspect of the interventricular septum that contains the bundle of His is supplied by the anterior interventricular artery (left anterior descending), which is the area indicated by the myocardial infarction in this question. The posterior part of the septum is supplied by the posterior interventricular artery.

2. The correct answer is B. The ductus arteriosus shunts blood in fetal life from the pulmonary trunk to the aorta distal to the origin of the subclavian artery. Most of the blood passing through the ductus is systemic, deoxygenated blood that has returned to the heart through the superior vena cava and passed through the right ventricle into the pulmonary artery.

3. The correct answer is D. The atrial septal defect described is a high septal defect located superior to the limbus and fossa ovalis, indicating that it is a secundum-type atrial septal defect. This defect results from a failure of the septum primum and secundum to overlap during development and thus results in a patent foramen ovale.

4. The correct answer is B. The superior vena cava courses along the right border of the sternum between the first and third ribs. Thus, a stab wound in the right second intercostal space would penetrate the superior vena cava.

5. The correct answer is A. The left vagus nerve descends through the superior mediastinum attached to the left side of the aortic arch. An aneurysm of the arch would damage the left vagus nerve, resulting in decreased parasympathetic innervation and thus reduce peristalsis of the foregut.

6. The correct answer is E. The right costodiaphragmatic recess is located at the base of the right lung between the 8th and 10th ribs at the midaxillary line. It is an expanded area of the pleural cavity into which the lung can expand during inspiration.

7. The correct answer is B. The described newborn cardiac defect is transposition of the great vessels, which is characterized by cyanosis, right-to-left shunting of blood, and it may or may not have a membranous interventricular defect. Transposition is one of several defects of septation of the truncus arteriosus. Tetralogy of Fallot and persistent truncus arteriosus truncal defects will always have a membranous defect.

Please visit us at www.Groupinsiders.com

© DeVry/Becker Educational Development Corp. All rights reserved.

1 Planes and Regions of the Anterior Wall of the Abdomen

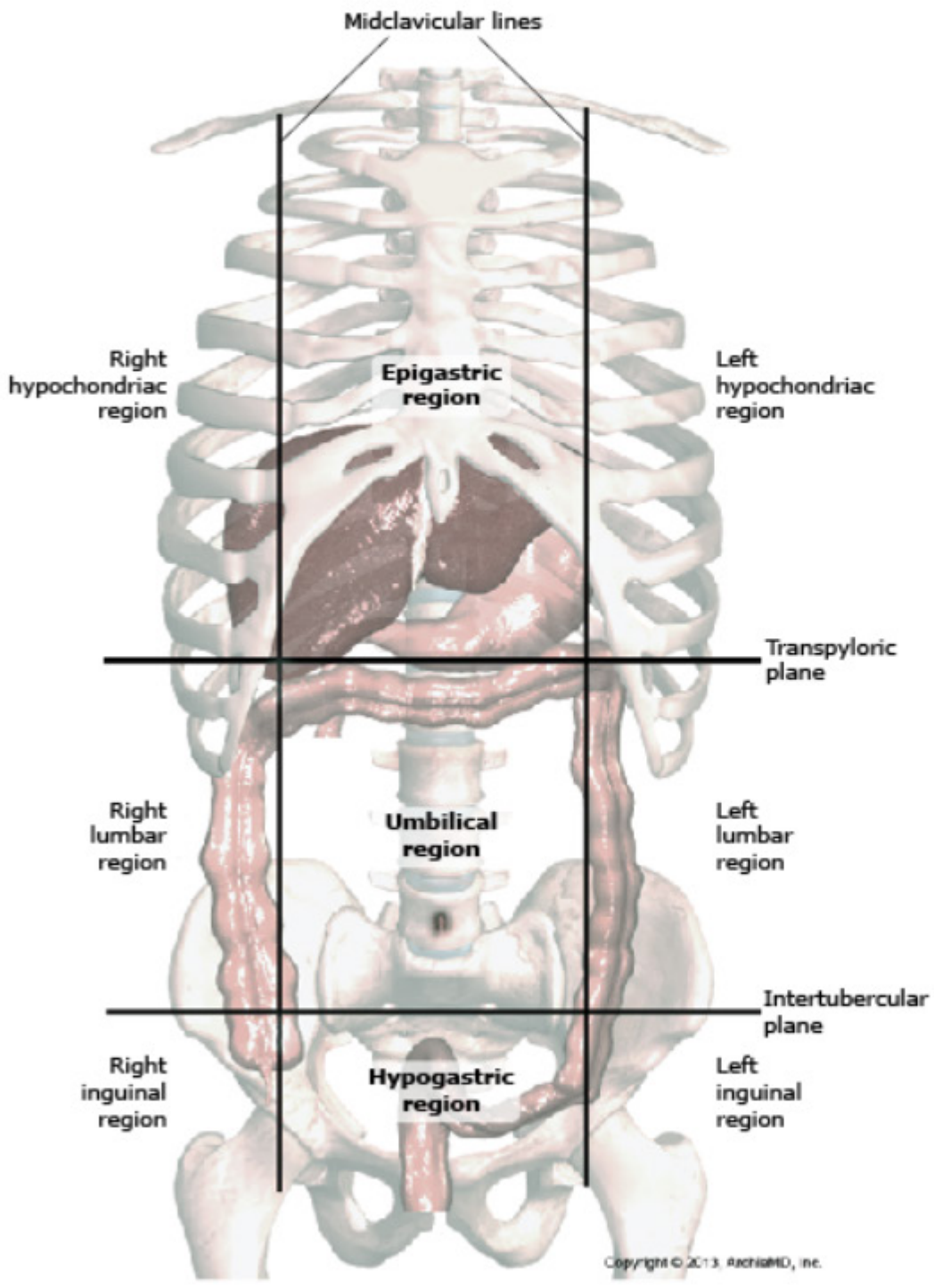

▲ **Figure 8–1.0A** Regions of the Abdomen

For descriptive purposes, the surface anatomy of the anterolateral abdominal wall is typically divided into nine regional divisions by two vertical midclavicular lines and two horizontal lines (transpyloric and intertubercular).

- **Midclavicular Lines:** These vertical paired lines descend through the midpoints of the clavicle and through the midpoints of the inguinal ligament.

USMLE® Key Concepts

For Step 1, you must be able to:

- Identify the inguinal canal and the different types of hernias.
- Explain the development of the GI tract and the major congenital defects of the gut tube.
- Describe the distribution of the peritoneum and the basic components of the mesenteries.
- Explain the innervation and blood supply to the gut tube.
- List the types of venous collateralizations observed in portal hypertension.
- Describe the development of the urinary system.
- Identify the structures of the abdomen on cross-sectional images.

Please visit us at www.Groupinsiders.com

© DeVry/Becker Educational Development Corp. All rights reserved.

- **Transpyloric Plane:** This horizontal plane passing through the *L1 vertebra* is important in radiology. Some of the important relationships at this plane are: pylorus of stomach, first part of duodenum, neck and body of pancreas, origin of superior mesenteric artery, and hila of the kidneys.
- **Intertubercular Plane:** This horizontal plane passes through the tubercles of the iliac crest at the level of L5 vertebra.

The *bone structure* of the pelvis and lower abdominal region is formed by a ring of bone consisting of the hip bone (ileum, ischium, and pubis) and sacrum. The major osseous landmarks are shown in Figure 8–1.0B.

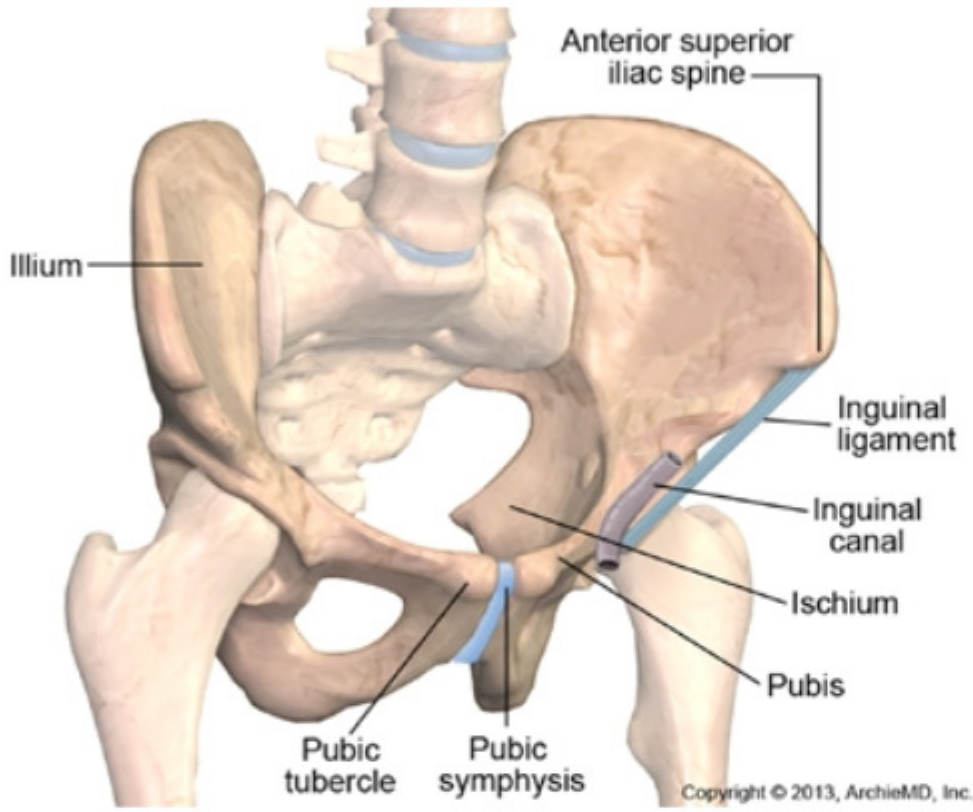

▲ **Figure 8–1.0B** Pelvic Bone

Please visit us at www.Groupinsiders.com

© DeVry/Becker Educational Development Corp. All rights reserved.

2 Layers of the Anterior Body Wall and Their Contributions to the Inguinal Region and Canal

The anterior lateral body wall is formed by eight layers of fasciae and muscles. The innervation of the anterolateral wall is provided by the lower intercostal and subcostal nerves and L1 spinal nerve contributions to the iliohypogastric and ilioinguinal nerves. The blood supply is derived mostly from the superior and inferior epigastric and intercostal arteries.

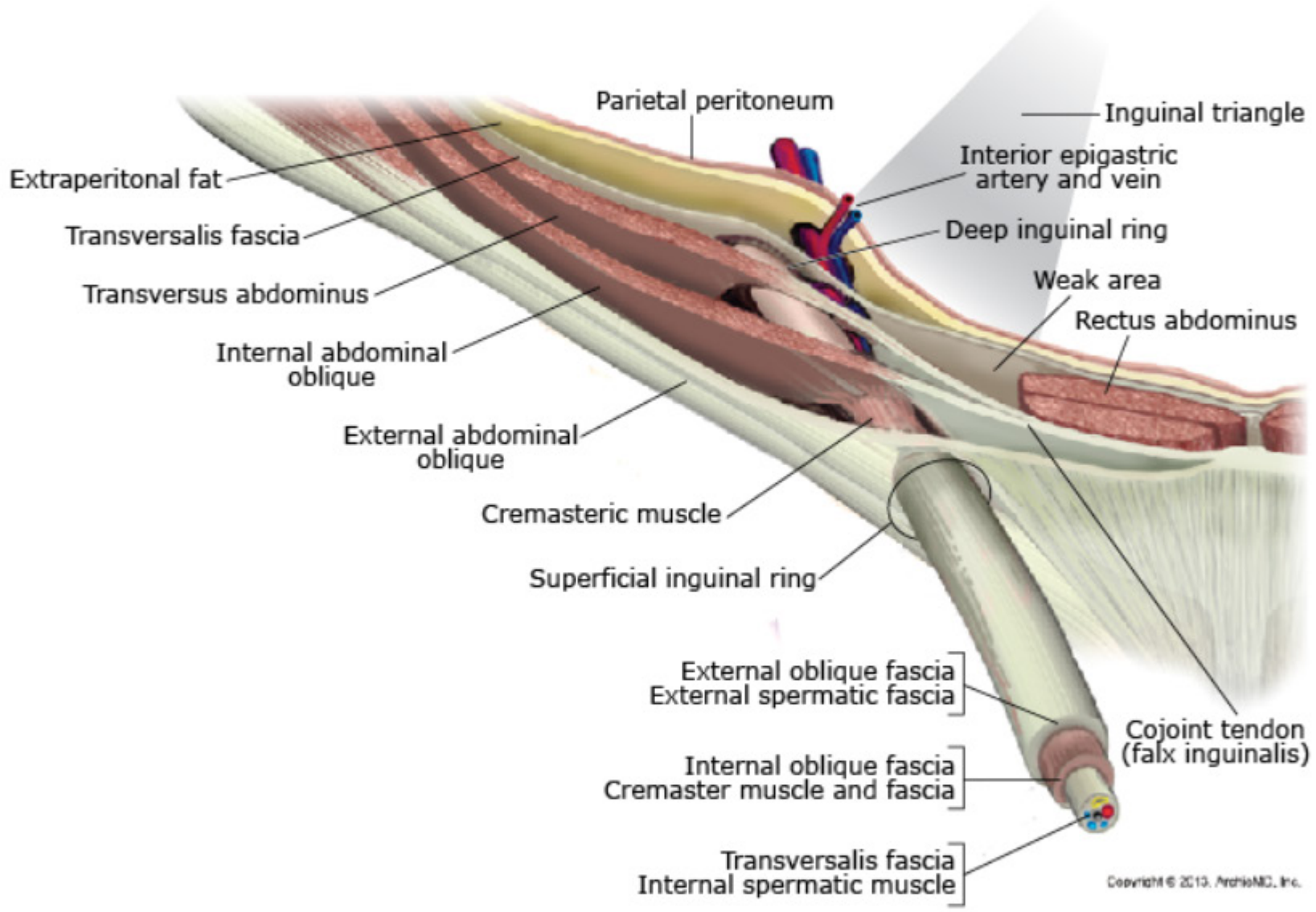

▲ **Figure 8–2.0** Inguinal Canal

Please visit us at www.Groupinsiders.com

© DeVry/Becker Educational Development Corp. All rights reserved.

The superficial to deep layers of the anterior wall are:

1. Skin
2. Superficial fasciae
   - Superficial fatty layer (Camper fascia)
   - Deep membranous layer (Scarpa fascia)
     - Continues into perineum as Colles fascia and into scrotum as tunica dartos layer that contains smooth muscle
3. External abdominal oblique muscle and aponeurosis
   - Forms inguinal ligament
   - Forms superficial inguinal ring
   - Forms external spermatic fascia
4. Internal abdominal oblique muscle and aponeurosis
   - Its aponeurosis joins with those of the transversus abdominis to form the *conjoint tendon (falx inguinalis)* that inserts on the pubic crest.
   - Forms cremaster fascia and muscle
5. Transversus abdominis muscle and aponeurosis
   - Its aponeurosis joins with those of the internal abdominal oblique to form the *conjoint tendon (falx inguinalis)* that inserts on the pubic crest.
   - Do not contribute to a spermatic fascial layer
6. Transversalis fascia
   - Forms the deep inguinal ring
   - Forms internal spermatic fascia
7. Extraperitoneal connective tissue
   - Layer that contains the urogenital ridge where the gonads form during development
8. Parietal peritoneum

Important Concept

Anterior Abdominal Wall Layers

A. Skin

B. Superficial fascia

  1. Camper (fatty)

  2. Scarpa (fibrous)

C. External abdominal oblique muscle and aponeurosis

D. Internal abdominal oblique muscle and aponeurosis

E. Transversus abdominis muscle and aponeurosis

F. Transversalis fascia

G. Extraperitoneal connective tissue (urogenital ridge)

H. Parietal peritoneum

Important Concept

The dartos layer of the wall of the scrotum contains smooth muscle that is innervated by sympathetics of the body wall. The smooth muscle contracts or relaxes to help maintain temperature of the testis about 2 degrees below body temperature.

Please visit us at www.Groupinsiders.com

© DeVry/Becker Educational Development Corp. All rights reserved.

3 Inguinal Canal

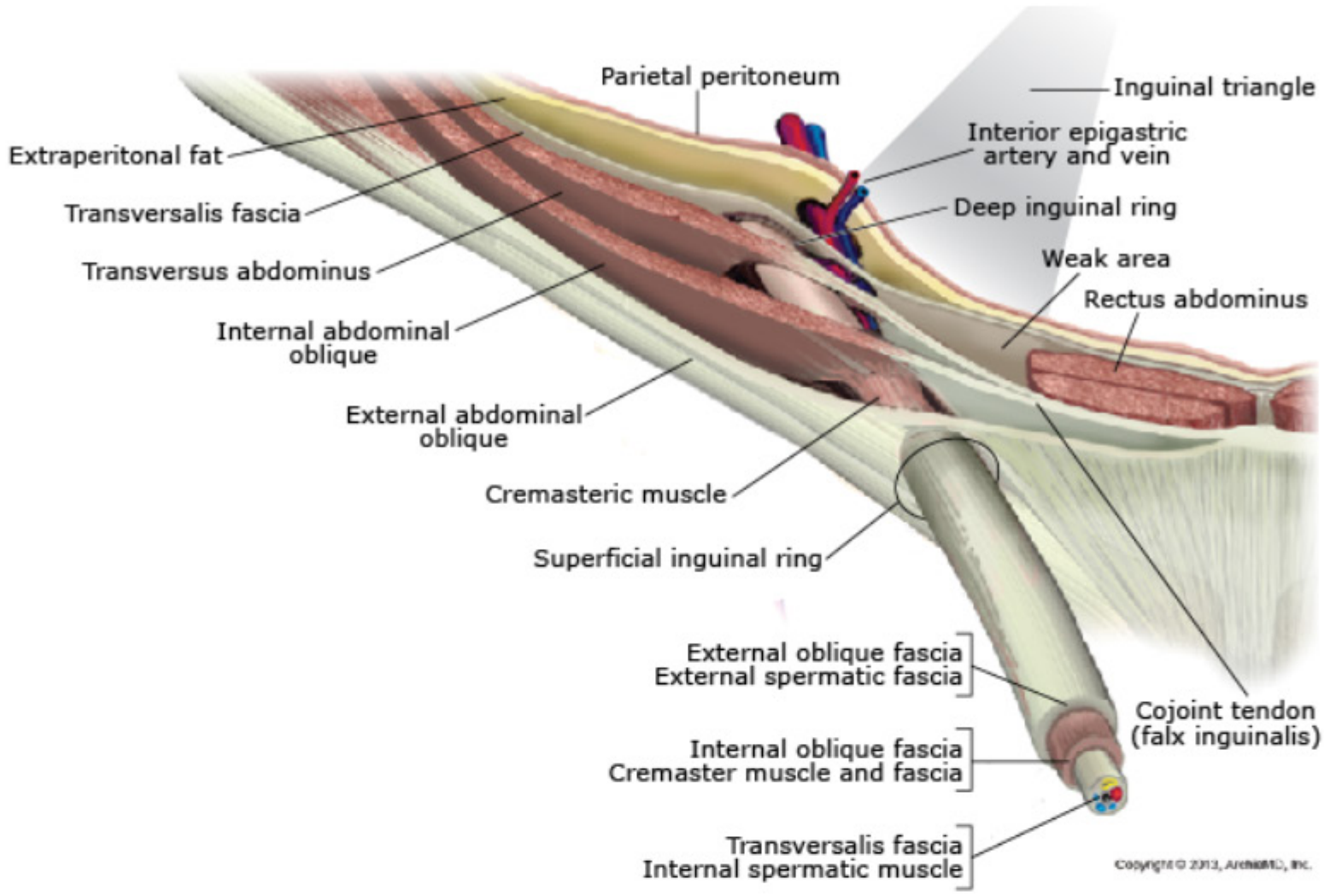

▲ **Figure 8–3.0** Inguinal Canal

The *inguinal canal* is a 4 cm oblique passageway through the inferior region of the anterior abdominal wall. The canal extends between the *deep ring laterally* and the *superficial ring medially* and runs immediately superior to and parallel to the medial half of the inguinal ligament.

The inguinal canal has clinical importance in the male because during testicular descent, the testis passes through the canal to reach the scrotum during the last trimester. In the female, the ovary does not pass through the inguinal canal during ovarian descent.

3.1 Major Features of Inguinal Canal

- **Deep Ring:** The deep ring is formed by an opening and extension of the transversalis fascia and lies lateral to the inferior epigastric vessels immediately superior to the midpoint of the inguinal ligament. It is the beginning of the canal and transmits structures into and out of the canal from the abdominal and pelvic areas.
- **Superficial Ring:** The superficial ring is medial and lies just superior to the pubic tubercle and is formed by an opening of the aponeurosis of the external abdominal oblique muscle.

Please visit us at www.Groupinsiders.com

© DeVry/Becker Educational Development Corp. All rights reserved.

- **Conjoint Tendon (falx inguinalis):** The conjoint tendon is formed by the fused aponeuroses of the internal abdominal oblique and transversus abdominis muscle. The tendon forms a strong area of the medial aspect of the posterior wall of the canal and inserts on the pubic crest.
- **Cremaster Muscle:** The cremaster muscle peels off from the lower fibers of the internal abdominal oblique muscle as it arches over the canal and contributes to the middle layer of the spermatic fascia covering the spermatic cord. The muscle extends into the scrotum, where it forms loops of fibers over the spermatic cord and the testis and serves to elevate the testis as part of the cremaster reflex.

3.2 Boundaries of the Inguinal Canal

The inguinal canal has multiple boundaries, but the two important clinical boundaries are the:

- **Floor:** Formed mostly by the *inguinal ligament*
- **Posterior Wall:** Extends between the deep ring laterally and the conjoint tendon medially. Major structures and relationships of the posterior wall are:
  - The *weak area* is formed by transversalis fascia and peritoneum, and is the site of a direct hernia. The weak area is *medial* to the inferior epigastric vessels.
  - The *inferior epigastric* vessels provide a major contribution to blood supply to the anterior body wall and rectus sheath. The deep ring is *lateral* to the epigastric vessels, and the weak area is *medial* to the epigastric vessels.
  - The *inguinal triangle* (Hesselbach triangle) is the area that a direct hernia passes through. It is bounded by the inferior epigastric vessels laterally, inguinal ligament inferiorly, and the rectus sheath medially.

3.3 Contents of the Inguinal Canal

3.3.1 Male

In the male, the inguinal canal contains the *spermatic cord*, which is covered by three layers of spermatic fascia and has the following contents:

- **Ilioinguinal Nerve:** Passes through the superficial ring but not the deep ring. This nerve is derived from L1 spinal nerve and provides sensory supply for the anterior wall of the scrotum.
- **Testicular Artery:** Branch of the abdominal aorta that descends with the testis.
- **Pampiniform Venous Plexus:** A vine-like collection of veins within the scrotum and spermatic cord that drains the testis. At the deep ring, the plexus condenses and forms the *testicular vein*, which ascends the posterior body wall and drains into the inferior vena cava on the right and the left renal vein on the left side.
- **Vas Deferens:** Enters spermatic cord at the deep ring.
- **Lymphatics:** Drain the testis via the inguinal canal into the *lumbar (aortic) nodes* of posterior body wall. The remainder of the perineum drains primarily into the *superficial inguinal nodes*.

Please visit us at www.Groupinsiders.com

© DeVry/Becker Educational Development Corp. All rights reserved.

- During descent, the testis and spermatic cord become enveloped by three layers of *spermatic fasciae*:
  - **External Spermatic Fascia:** Extension of the aponeurosis of the external abdominal muscle at the superficial ring.
  - **Middle or Cremasteric Muscle and Fascia:** Derived from the internal abdominal muscle and aponeurosis.
  - **Internal Spermatic Fascia:** Extension of transversalis fascia at the deep ring.
- The inguinal canal is a common site for inguinal hernias in the male.

3.3.2 Female

- In the female, the inguinal canal contains the *round ligament of the uterus* and *ilioinguinal nerve* (sensory nerve for small area of skin of anterior surface of the labia). The ilioinguinal nerve passes through the superficial ring, but not the deep ring.

Clinical Application

Varicocele

In the male, engorgement of blood within the pampiniform (vine-like) plexus of veins results in a fluid-filled, enlarged, painful scrotum called a *varicocele*. A varicocele produces scrotal pain and has the appearance of a *bag of worms*. Clinically, a varicocele does not transmit light and reduces in size when the man lies flat. A varicocele can result from defective valves of the veins or left renal problems because the left testicular vein drains into the left renal vein. The right testicular vein drains into the inferior vena cava.

Testicular Cancer

Cancers of the perineum (penis, scrotum, clitoris, labia, and anal canal below pectinate line) initially drain into the *superficial inguinal nodes*. However, note that testicular cancer metastasizes up the spermatic cord to the *aortic (lumbar) nodes* on the posterior abdominal wall.

Cremaster Reflex

Stroking the skin on the medial side of the thigh of a younger male will stimulate the sensory fibers of the ilioinguinal nerve, resulting in the motor fibers of the genital nerve contracting the *cremaster muscle* of the spermatic cord, thus elevating the testis.

Please visit us at www.Groupinsiders.com

© DeVry/Becker Educational Development Corp. All rights reserved.

4 Inguinal Hernia

A protrusion and herniation of the intestines can occur in many places through the body wall. The most common site of herniation in males is the inguinal region due to the inherent weakness of the inguinal canal resulting from descent of the testis. These hernias are found superior to the inguinal ligament.

The characteristics of the two major types of inguinal hernias in males are:

4.1 Indirect Inguinal Hernia

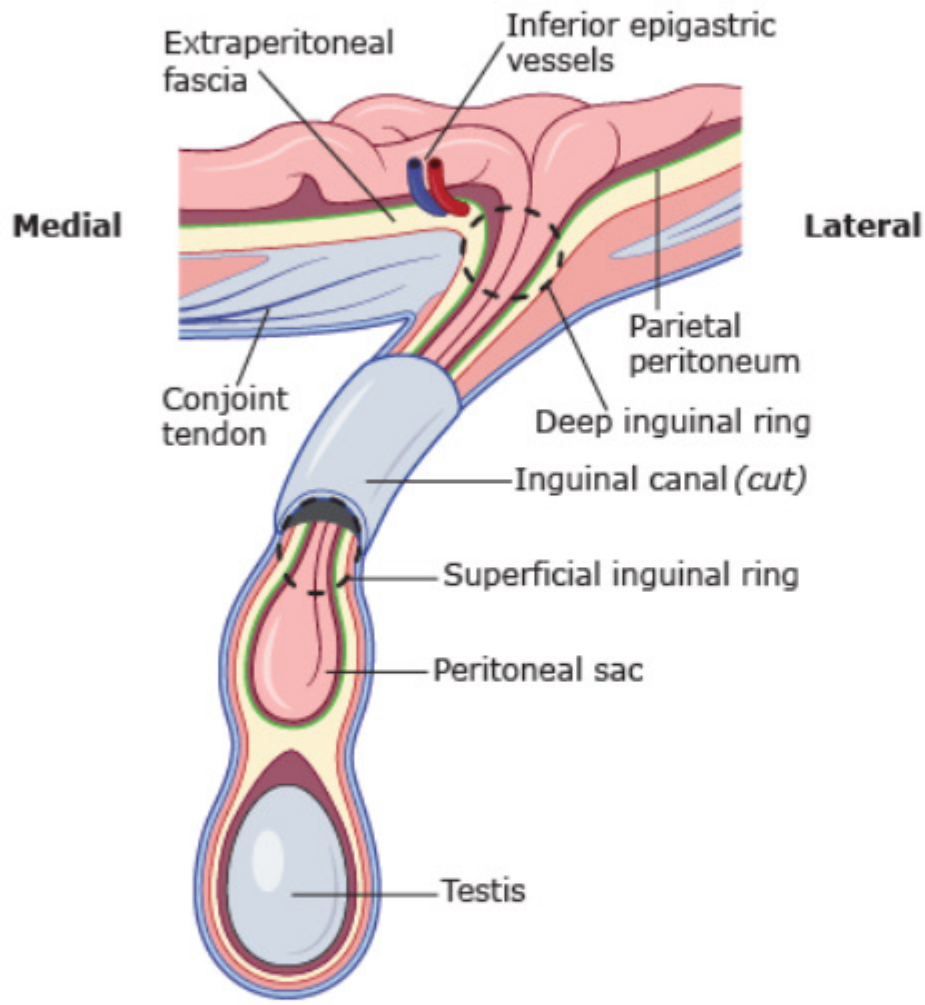

▲ **Figure 8–4.1** Indirect Inguinal Hernia

- Most common hernia in young males.
- Protrudes *lateral to the inferior epigastric vessels*.
- Small intestines herniate through the *deep ring* to enter inguinal canal
- Follows the descent route of the testis and pass through the *superficial ring* to coil into the scrotum.
- Intestines are within the spermatic cord and are *covered by all three layers of spermatic fascia*.

Important Concept

Indirect hernias occur lateral to the inferior epigastric vessels, and direct hernias occur medial to the inferior epigastric vessels within the inguinal triangle which is bounded by rectus sheath (medially), inguinal ligament (inferiorly), and inferior epigastric vessels (laterally).

Please visit us at www.Groupinsiders.com

© DeVry/Becker Educational Development Corp. All rights reserved.

4.2 Direct Inguinal Hernia

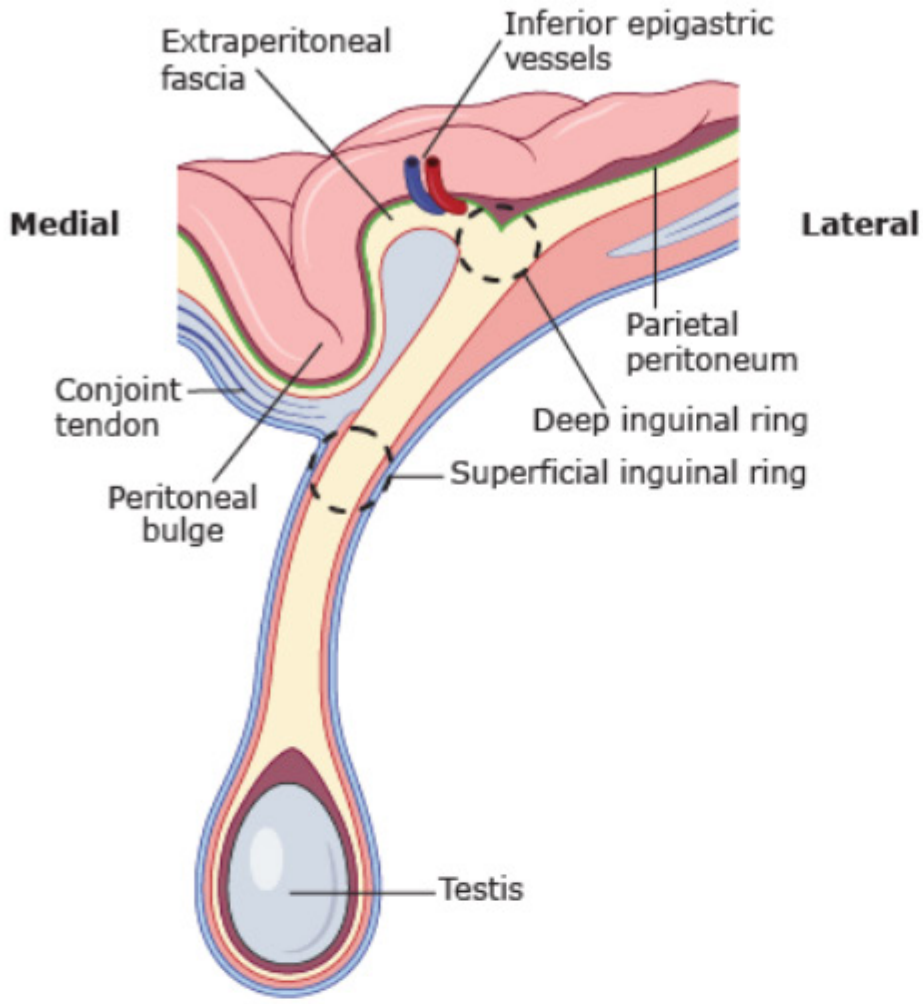

▲ **Figure 8–4.2** Direct Inguinal Hernia

- More common in older men.
- Herniation of gut protrudes through the anterior abdominal wall within the *inguinal triangle* and weak area.
- Herniation protrudes *medial to inferior epigastric artery* through the weak area of posterior wall of inguinal canal.
- Hernia is found on the surface of spermatic cord and may bulge at the superficial ring, but usually does not descend into the scrotum.

Please visit us at www.Groupinsiders.com

© DeVry/Becker Educational Development Corp. All rights reserved.

4.3 Femoral Hernia

- More common in women than men.
- Femoral hernias occur below the inguinal ligament within the *femoral canal*. The femoral canal is the medial compartment of the femoral sheath in the anterior compartment of the thigh and contains the femoral artery, vein, and canal. Note that the femoral sheath does not contain the femoral nerve.
- The herniation is medial to the femoral vein and lateral to the pubic tubercle and lacunar ligament.
- Strangulation of the gut is common in this type of hernia.

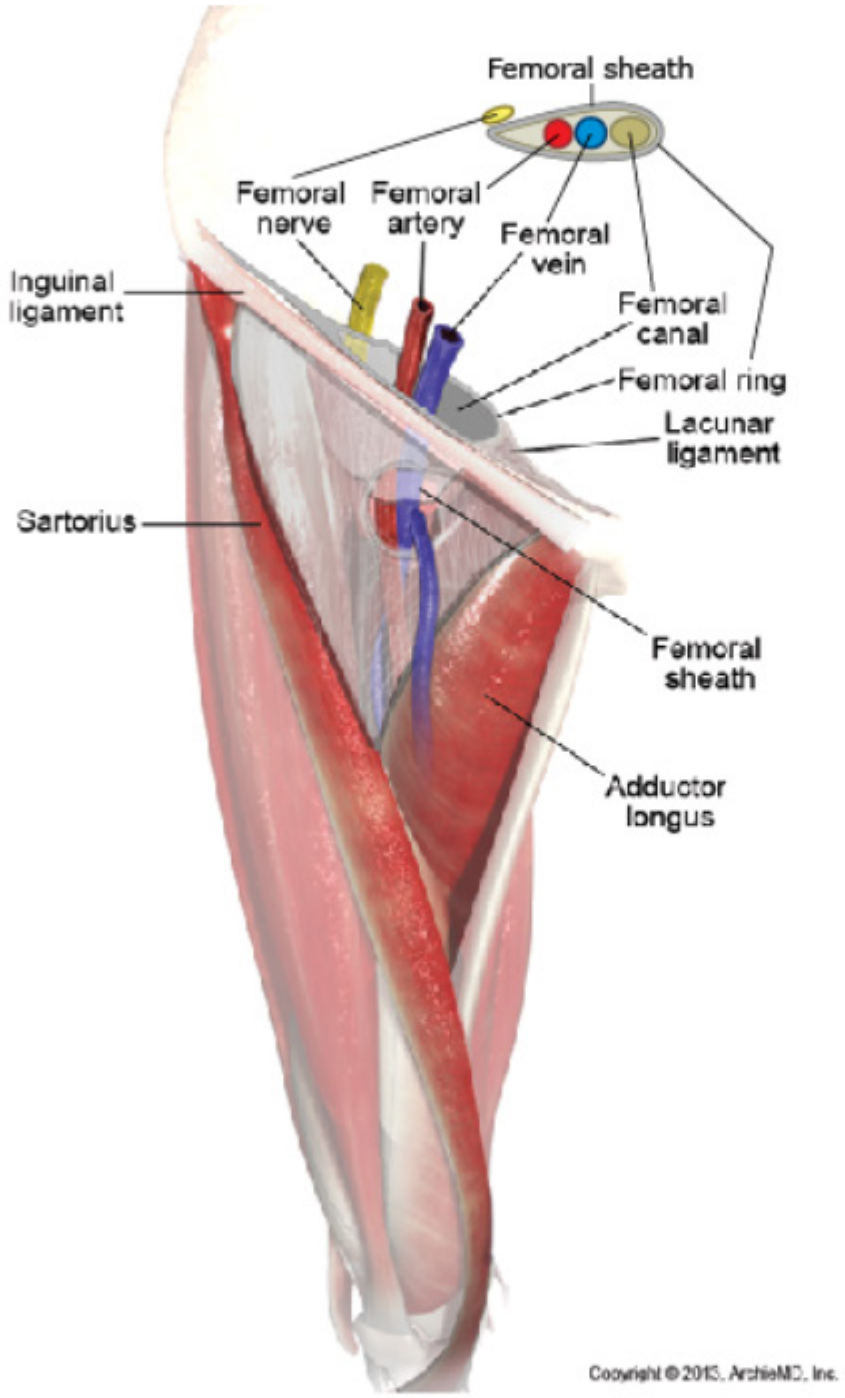

▲ **Figure 8–4.3** Femoral Hernia

Important Concept

The femoral sheath contains the femoral artery and vein and the femoral canal but does not contain the femoral nerve.

Femoral hernias occur below the inguinal ligament and inguinal hernias occur above the inguinal ligament.

Please visit us at www.Groupinsiders.com

© DeVry/Becker Educational Development Corp. All rights reserved.

5 Descent of the Testis

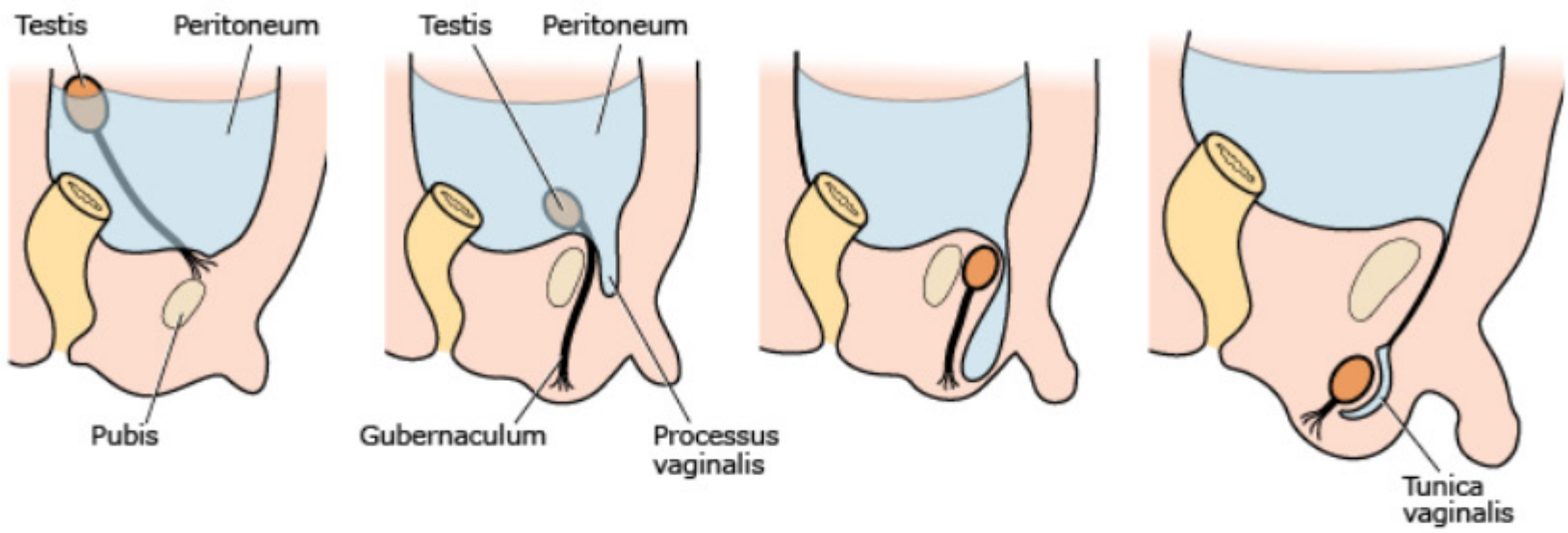

▲ **Figure 8–5.0A** Descent of Testis

The testis develops near the T10 vertebral level within the mesoderm of the urogenital ridge. During the last trimester, the gonad loses its attachment to the ridge and descends around the lateral body wall in the extraperitoneal connective tissue layer to pass through the inguinal canal and into the developing scrotum.

Structures associated with testicular descent are:

- **Gubernaculum:** A condensation of connective tissue that extends from its attachment to the testis into the inguinal region and the developing scrotum. It is mostly removed during descent of the testis. It serves to help guide the testis to the scrotum.
- **Processus Vaginalis:** Forms as an extension of the parietal peritoneum that projects into the developing scrotum. This extension of peritoneum occurs before the descent of the testis and contributes to the formation of the inguinal canal. Initially, the processus vaginalis is an open connection with the abdominal peritoneal cavity and the scrotum.
- As the testis reaches the scrotum, most of the processus vaginalis is obliterated except for the distal end that envelops and covers most of the surface of the testis (*tunica vaginalis*). The tunica vaginalis forms a double-wall sac that contains a thin layer of serous fluid.

Please visit us at www.Groupinsiders.com

© DeVry/Becker Educational Development Corp. All rights reserved.

Clinical Application

Congenital Indirect Inguinal Hernia

If the processus vaginalis fails to close and remains open at birth, a loop of intestines may descend into the scrotum at or shortly after birth, causing a congenital indirect inguinal hernia.

Hydrocele

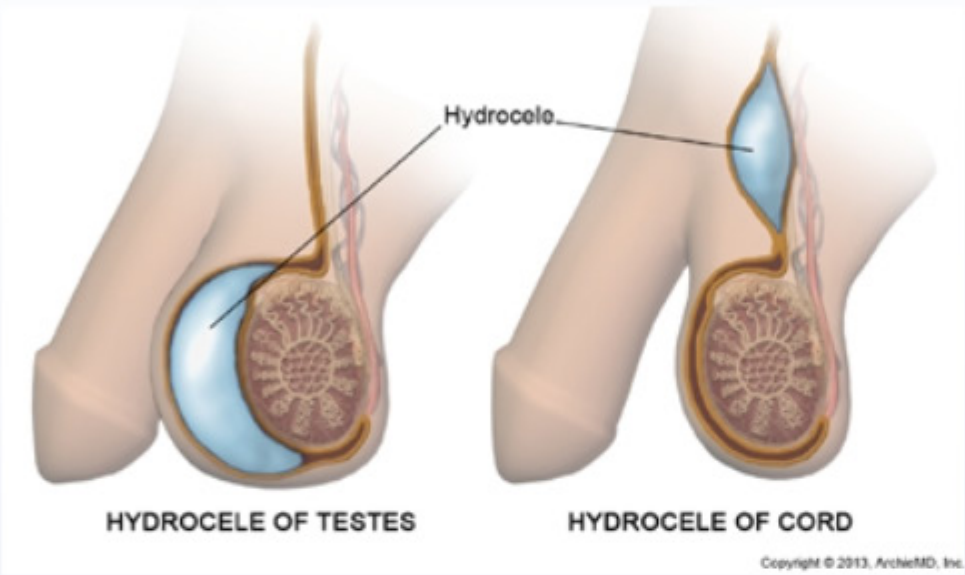

▲ **Figure 8–5.0B** Hydrocele

A *hydrocele* results from an excess accumulation of clear serous fluid in the tunica vaginalis. The testis enlarges, but does not reduce upon lying down, and does transmit light.

Please visit us at www.Groupinsiders.com

© DeVry/Becker Educational Development Corp. All rights reserved.

6 Development of the Gut Tube

▼ **Table 8–6.0** Adult Structures Derived From Each of the Three Divisions of the Primitive Gut Tube

	Foregut	Midgut	Hindgut
Blood Supply	Celiac	Superior mesenteric artery	Inferior mesenteric artery
Parasympathetic Innervation	Vagus nerves	Vagus nerves	Pelvic splanchnic nerves (S2–S4)
Sympathetic Innervation	• Preganglionics: Thoracic splanchnic nerves, T5–T12 • Postganglionic cell bodies: Celiac ganglion	• Preganglionics: Thoracic splanchnic nerves, T5–T12 • Postganglionic cell bodies: Superior mesenteric ganglion	• Preganglionics: Lumbar splanchnic nerves, L1–L2 • Postganglionic cell bodies: Inferior mesenteric ganglion
Referred Pain	Epigastrium	Umbilical	Hypogastrium
Adult Derivatives	• Esophagus • Stomach • Duodenum (first and second parts) • Liver • Pancreas • Biliary apparatus • Gallbladder	• Duodenum (second, third, and fourth parts) • Jejunum • Ileum • Cecum • Appendix • Ascending colon • Transverse colon (proximal two thirds)	• Transverse colon (distal third—splenic flexure) • Descending colon • Sigmoid colon • Rectum • Anal canal (above pectinate line)

Please visit us at www.Groupinsiders.com

© DeVry/Becker Educational Development Corp. All rights reserved.

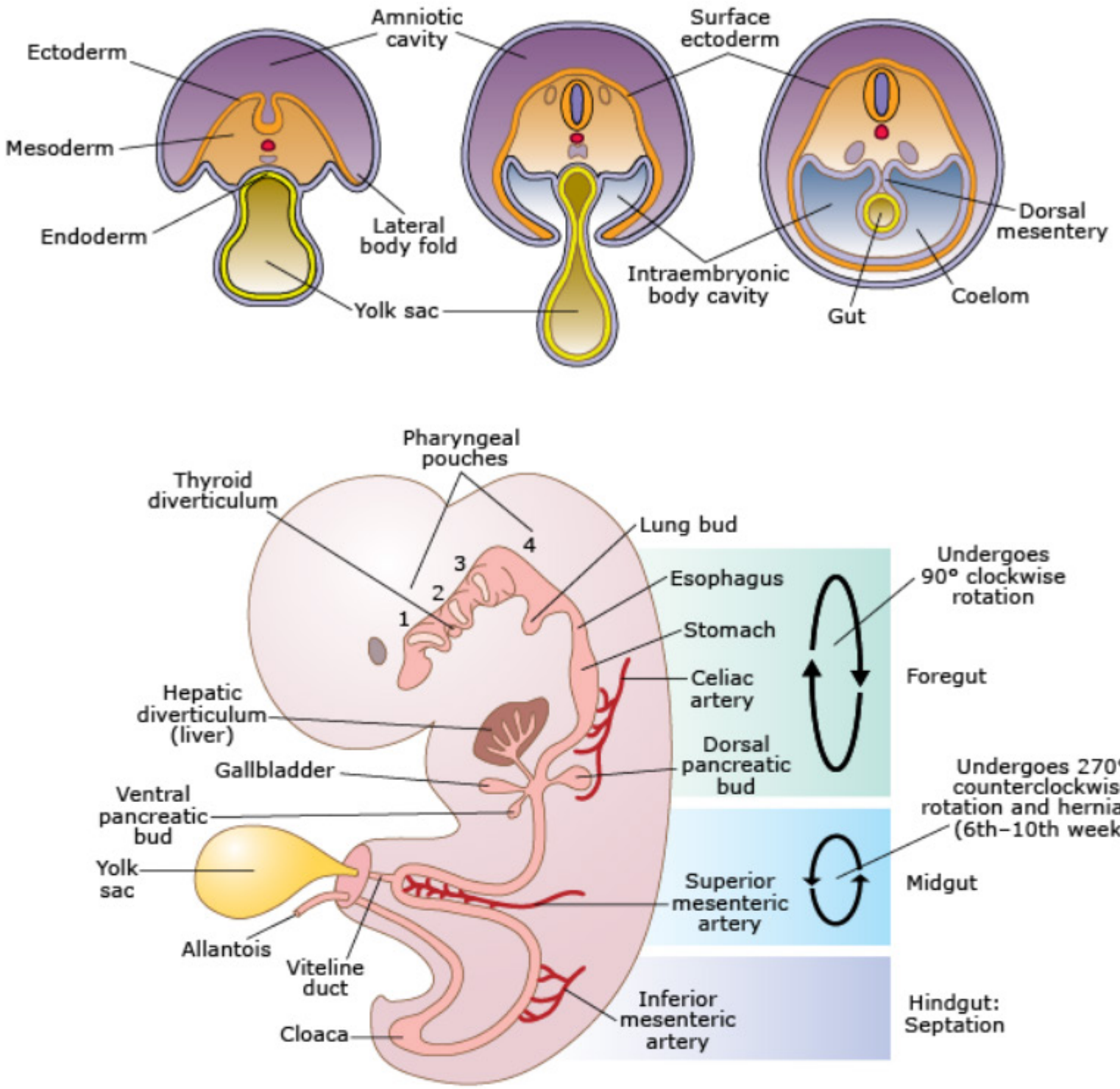

▲ **Figure 8–6.0** Body Foldings

The gut tube begins to form during the fourth week as a result of two body foldings: *lateral body folds* and *craniocaudal body folds*. During the body foldings, the endoderm-lined dorsal aspect of the yolk sac is incorporated into the body of the embryo and forms most of the gut tube.

The developing gut tube is divided into three parts: *foregut*, *midgut*, and *hindgut*. Each of these regions develops a specific blood supply and innervation that is outlined in Table 8–6.0. The epithelium of the gut tube develops from endoderm, but the remainder of the wall (muscle, connective tissue, vascular) develops from mesoderm.

Important Concept

Endoderm of foregut forms the lower respiratory tract, liver and biliary tree, and pancreas.

Please visit us at www.Groupinsiders.com

© DeVry/Becker Educational Development Corp. All rights reserved.

6.1 Peritoneum

The peritoneum is the third of the serous membranes in the body cavities. It is divided into two layers:

- **Parietal Layer:** Lines the abdominal and pelvic walls, and receives somatic innervation and is sensitive to pain.
- **Visceral Layer:** Reflects from the parietal layer from several points, mostly on the posterior body wall. The visceral layer covers the viscera and carries the blood supply and innervation to the viscera.
- The visceral layer has different names as it covers various viscera:
  - *Greater* and *lesser omenta* of the stomach.
  - *Mesocolon* of the transverse and sigmoid colon.
  - Numerous *ligaments* named according to their attachments.

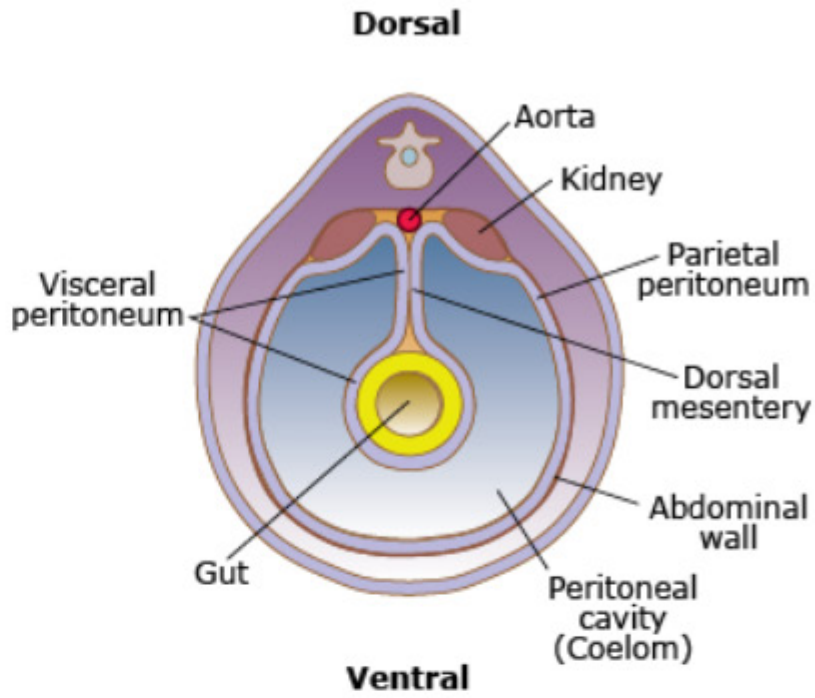

▲ **Figure 8–6.1** Peritoneum

The *peritoneal cavity* is the space between the two layers that contains a thin layer of serous fluid that provides free movement of the viscera. It is divided into a *lesser sac* (omental bursa) and a *greater sac*.

6.1.1 Intraperitoneal and Retroperitoneal Organs

- **Retroperitoneal Viscera:** These viscera are external to the peritoneum and are covered on one surface by parietal peritoneum and are usually immobile organs.
- **Intraperitoneal Viscera:** These viscera are enclosed and suspended by visceral peritoneum from the body wall and are mobile.

▼ **Table 8–6.1** Intraperitoneal and Retroperitoneal Viscera

Interperitoneal	Retroperitoneal
• Stomach • First part of the duodenum (duodenal cap or bulb) • Jejunum • Ileum • Cecum • Appendix • Transverse colon • Sigmoid colon • Liver • Gallbladder • Tail of pancreas • Spleen	• Second, third, and fourth parts of duodenum • Ascending colon • Descending colon • Rectum • Head, neck, body of pancreas • Kidneys • Ureters • Suprarenal gland • Abdominal aorta • Inferior vena cava

Please visit us at www.Groupinsiders.com

© DeVry/Becker Educational Development Corp. All rights reserved.

6.2 Foregut Development

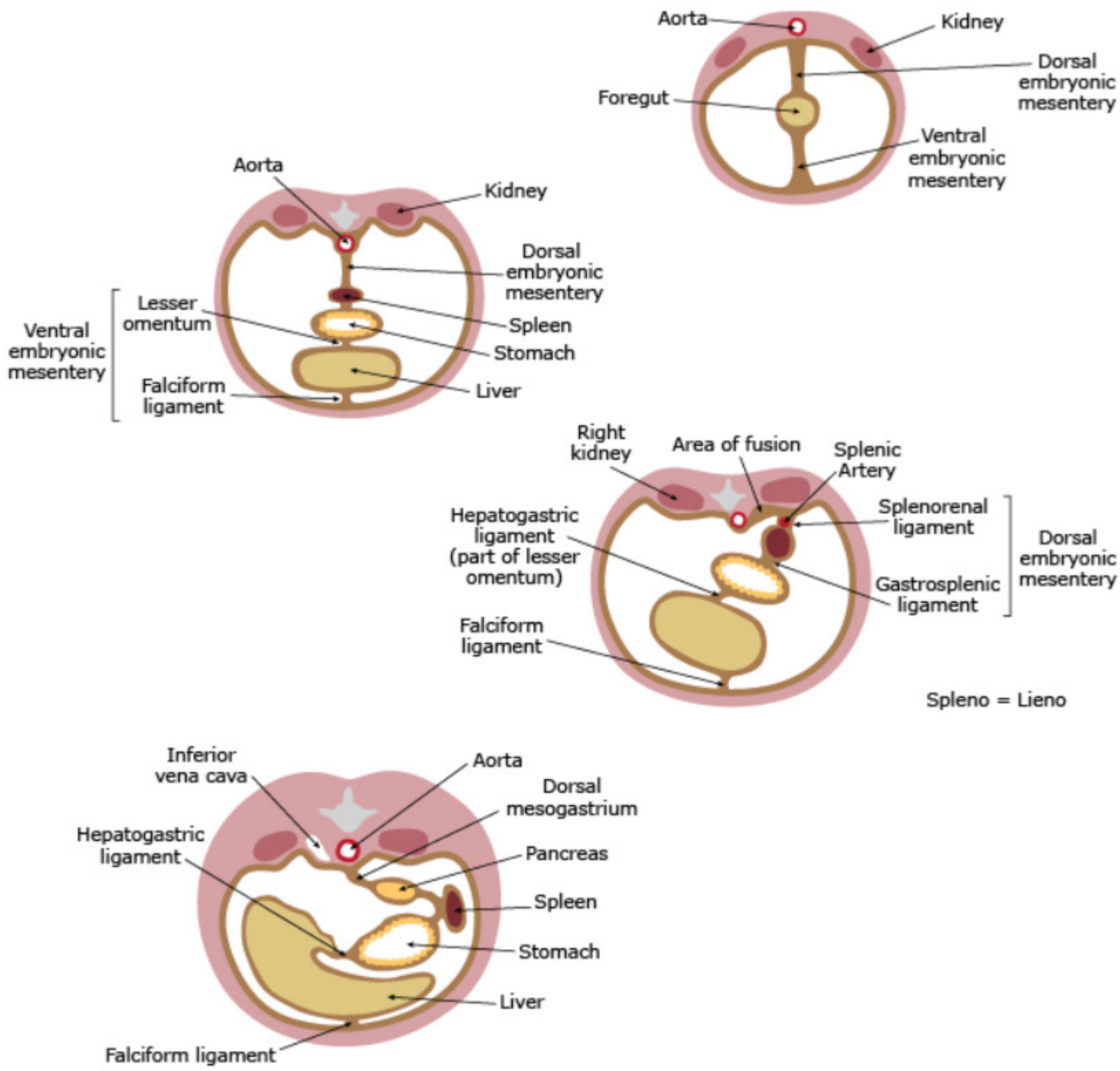

▲ **Figure 8–6.2A** Foregut Development

Please visit us at www.Groupinsiders.com

© DeVry/Becker Educational Development Corp. All rights reserved.

Following the body foldings and the formation of the gut tube, the foregut region will be suspended from the dorsal and ventral body walls by the *dorsal* and *ventral embryonic mesenteries*, respectively.

- The foregut is the only part of the gut tube that is suspended by the ventral embryonic mesentery. However, the entire gut tube is suspended by the dorsal embryonic mesentery.
- The foregut undergoes a 90 degree clockwise rotation to the right along the long axis of the gut tube.
- The liver and biliary systems develop from foregut *endoderm within the ventral embryonic mesentery*.
- The spleen (from mesoderm) and dorsal pancreas (from endoderm) develops *within the dorsal embryonic mesentery*.
- The foregut rotation shifts the ventral embryonic mesentery (future lesser omentum) with the liver to the *right*. The *falciform ligament* and the *lesser omentum (hepatogastric and hepatoduodenal ligaments)* develop from the ventral embryonic mesentery.
- The rotation also moves the dorsal embryonic mesentery to the *left* with the spleen and pancreas. The dorsal mesentery lengthens and contributes to the *greater omentum*, forming the *gastrosplenic* and *splenorenal ligaments*.
- Foregut rotation divides the peritoneal cavity into a *greater peritoneal sac* and a *lesser peritoneal sac (omental bursa)*. The two sacs are connected by the *epiploic foramen (of Winslow)*.

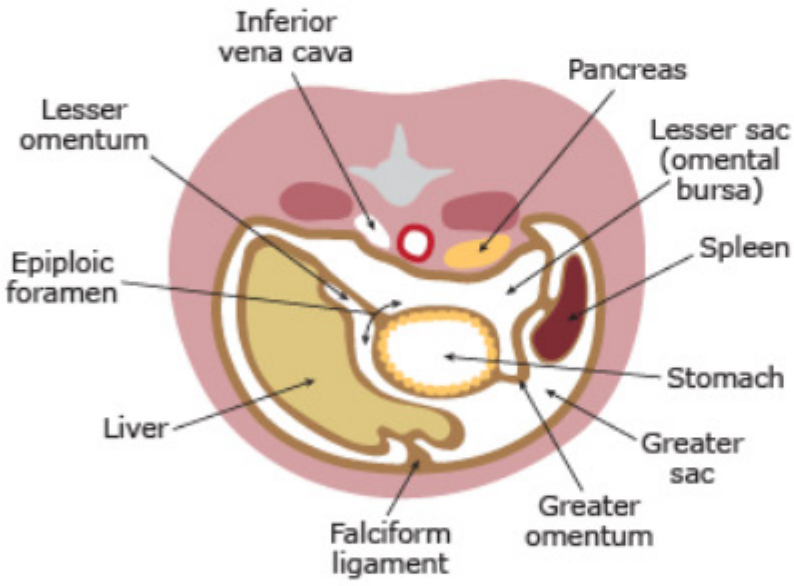

▲ **Figure 8–6.2B** Foregut Development (Detail)

Please visit us at www.Groupinsiders.com

© DeVry/Becker Educational Development Corp. All rights reserved.

6.2.1 Greater and Lesser Omenta and Epiploic Foramen

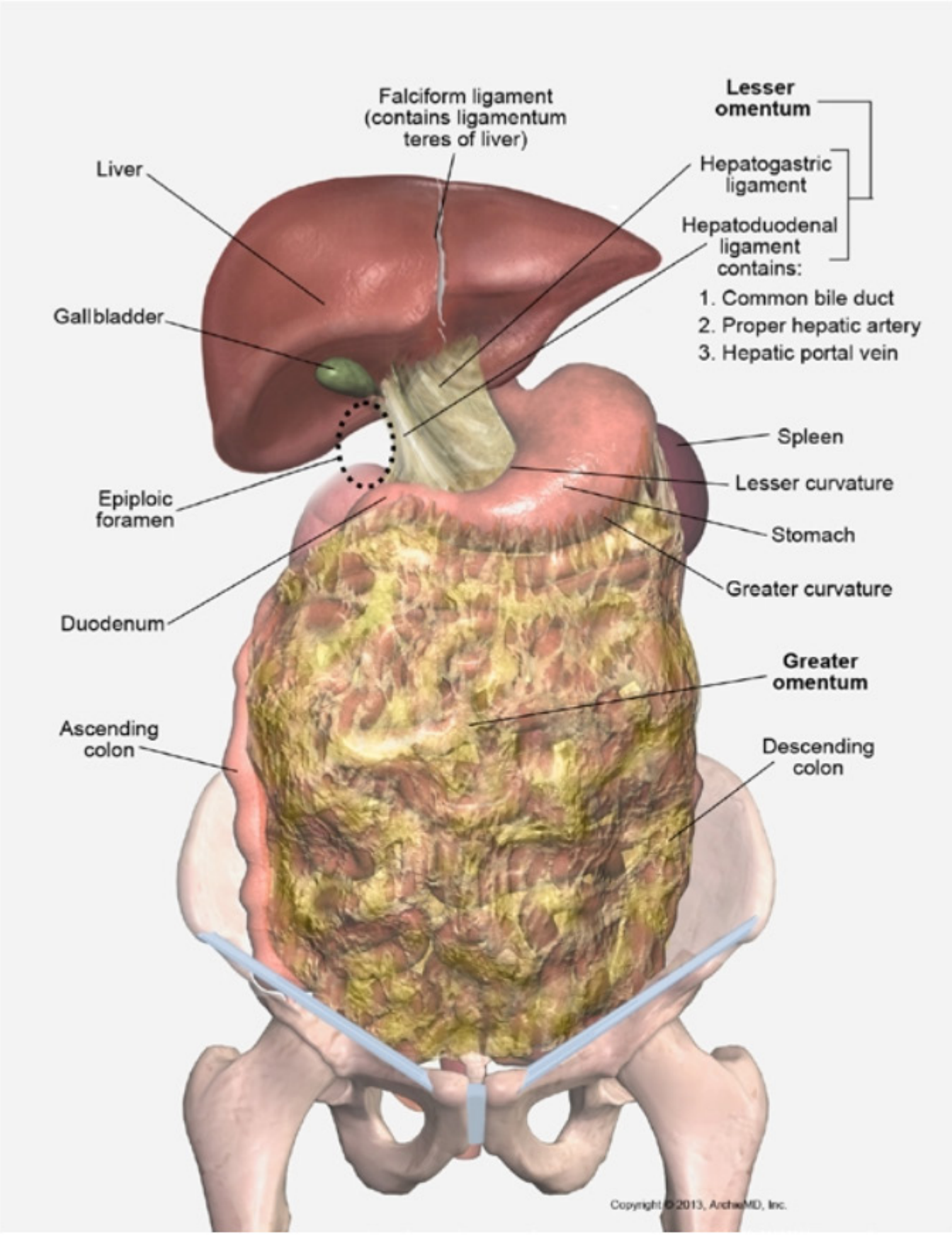

▲ **Figure 8–6.2C** Greater and Lesser Omenta

Please visit us at www.Groupinsiders.com

© DeVry/Becker Educational Development Corp. All rights reserved.

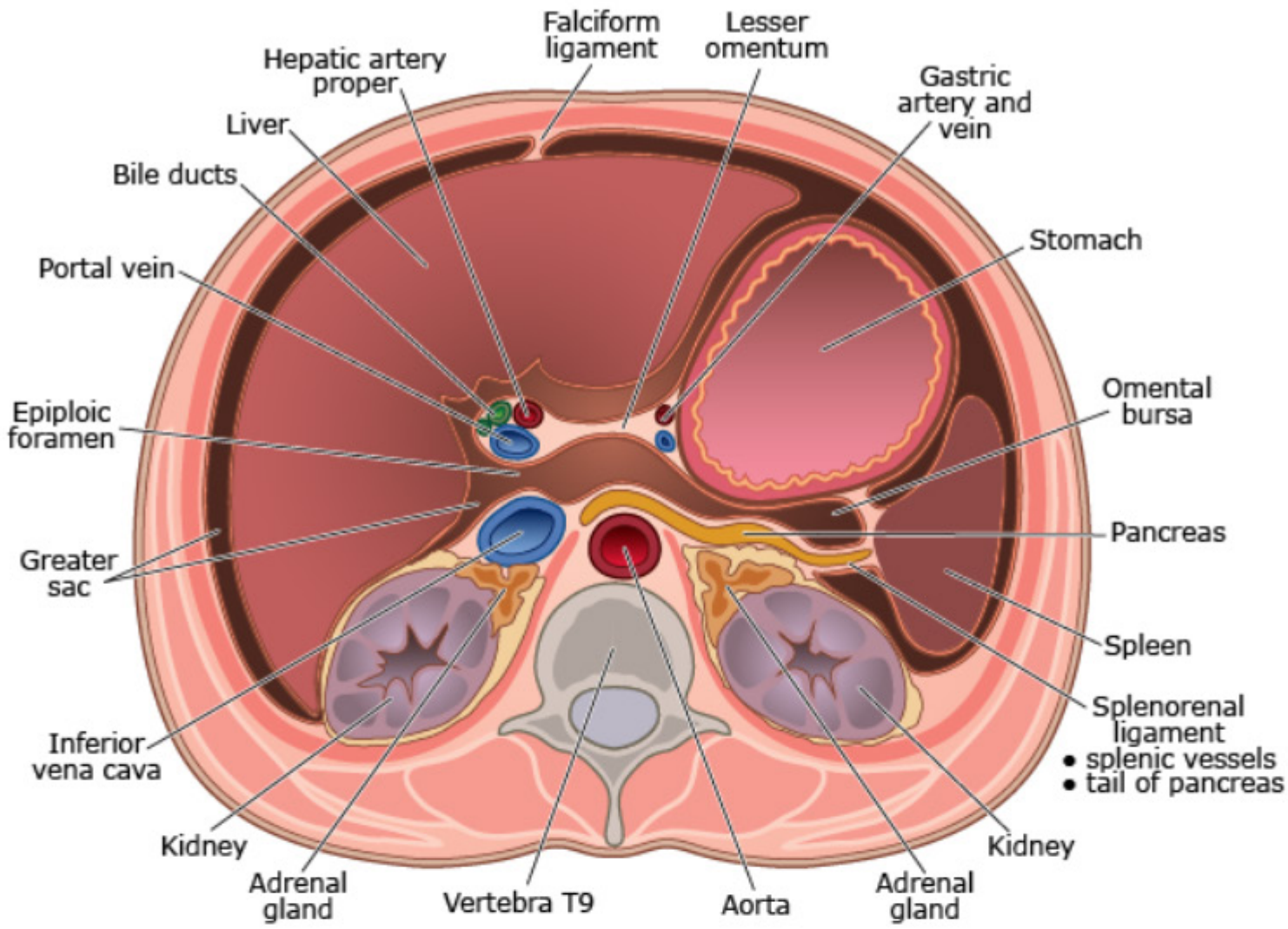

▲ **Figure 8–6.2D** Cross Section of the Abdomen

The *omental bursa (lesser peritoneal sac)* is the cul-de-sac of the peritoneal cavity formed by the rotation of the foregut. The entrance to the omental bursa is the *epiploic foramen*, which is located posterior at the right free edge of the lesser omentum (hepatoduodenal ligament).

Important Relationships

- *Anterior wall of the omental bursa* is formed by the lesser omentum and the posterior wall of the stomach.
- *Posterior wall of the omental bursa* is formed by the body of pancreas, aorta, and left kidney and adrenal gland.
- *Anterior* boundary of the epiploic foramen is formed by the hepatic portal vein in the hepatoduodenal ligament.
- *Posterior* boundary of the epiploic foramen is formed by the *inferior vena cava*.

Clinical Application

Dorsal gastric ulcers that erode posteriorly through the wall of the stomach empty gastric contents into the omental bursa, resulting in peritonitis.

Please visit us at www.Groupinsiders.com

© DeVry/Becker Educational Development Corp. All rights reserved.

7 Three Important Foregut Derivatives

Three visceral diverticula (buds) develop as an *outgrowth of endoderm from the foregut*:

- **Lungs and Lower Respiratory System:** Discussed in the thorax chapter.
- **Liver and Biliary Tract:** The liver diverticulum develops within the ventral embryonic mesentery and has the falciform ligament and the lesser omentum attached to its diaphragmatic and visceral surfaces, respectively. The gallbladder and biliary tree develop from the hepatic bud.
- **Pancreas:** Develops from two endodermal buds discussed later.

7.1 Development of the Spleen

The *spleen* develops from *mesoderm* within the *dorsal embryonic mesentery*. Attaching to the spleen are the *splenogastric* and *splenorenal ligaments*.

7.2 Development of the Pancreas

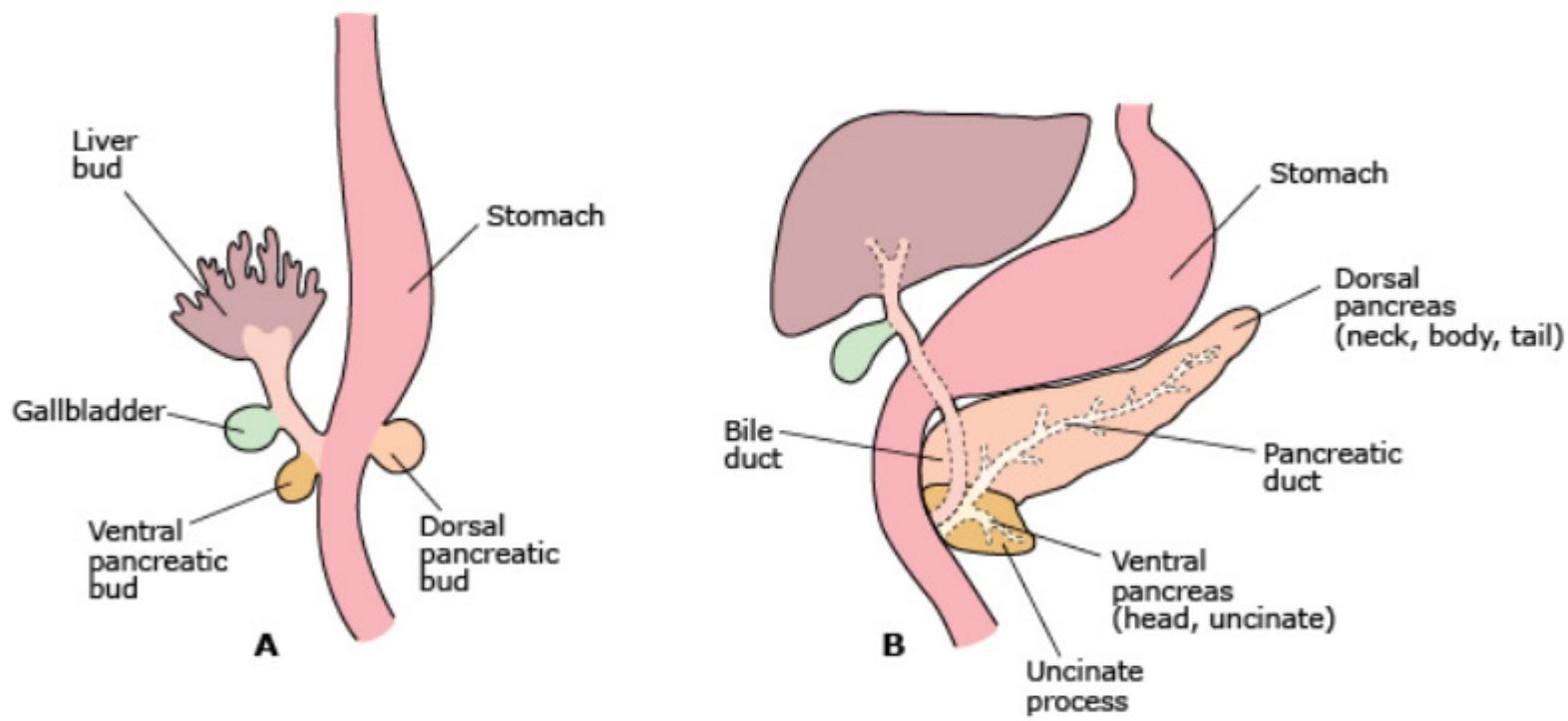

▲ **Figure 8–7.2A** Development of the Pancreas

The *pancreas* develops from *dorsal* and *ventral pancreatic buds* of foregut *endoderm*. These two buds arise from the dorsal and ventral sides of the duodenal region of the *foregut*, respectively.

- The *dorsal bud* develops within the dorsal embryonic mesentery and forms the *neck*, *body*, and *tail of the pancreas*.
- The *ventral bud* initially develops in the ventral embryonic mesentery, but rotates dorsally around the right side of the duodenum to join and fuse to the inferior aspect of the dorsal pancreatic bud. The *ventral bud* forms the *head* and *uncinate process of pancreas*.

Please visit us at www.Groupinsiders.com

© DeVry/Becker Educational Development Corp. All rights reserved.

Clinical Application

Annular Pancreas

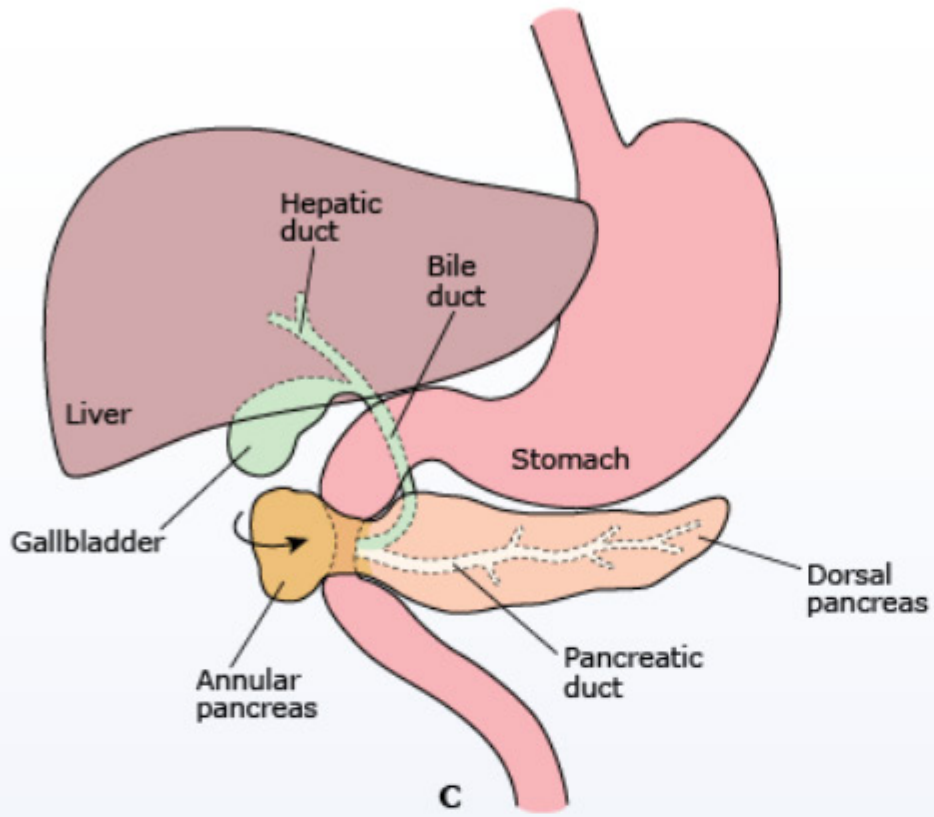

▲ **Figure 8–7.2B** Annular Pancreas

An *annular pancreas* occurs when the rotation of the ventral pancreatic bud splits and rotates around both sides of the duodenum and forms a ring or collar of pancreas around the duodenum.

- This malformation causes complete or partial duodenal obstruction (midgut).
- Patients may develop pancreatitis.
- More common in males.
- Associated with *polyhydramnios*.
- Have *bile-stained* projectile vomiting.

Please visit us at www.Groupinsiders.com

© DeVry/Becker Educational Development Corp. All rights reserved.

8 Midgut Development

Initially, the midgut forms as a cranial and caudal *U-shaped loop* that is suspended from the dorsal body wall by the dorsal embryonic mesentery. The midgut loop undergoes a rapid elongation.

- The midgut loop forms the distal duodenum through the proximal two thirds of the transverse colon.
- The midgut loop undergoes a *270-degree counterclockwise rotation* around the axis of the *superior mesenteric artery* during the herniation event. This results in the normal placement of the midgut viscera (Figure 8–6.0).
- In addition, because the abdominal space is not large enough for the rapid growth of the midgut, the midgut also *herniates* through the umbilical ring into the connecting stalk between weeks 6–10 to continue its development. The cranial loop returns first, and the caudal loop returns last.

Please visit us at www.Groupinsiders.com

© DeVry/Becker Educational Development Corp. All rights reserved.

9 Major Congenital Defects of the Gut Tube

9.1 Patent Vitelline Duct and Allantois

During development, the midgut and cloaca part of the hindgut each have a patent diverticulum (*vitelline duct* and *allantois*, respectively) that connect the gut tube out to the connecting stalk. In the latter half of pregnancy, both of these should obliterate and form a fibrous remnant.

- The *vitelline duct* temporarily connects the midgut to the connecting stalk. Two malformations can occur with the vitelline duct:
  - **Meckel (Ileal) Diverticulum:** Occurs when a short, proximal part of the vitelline duct persists, and the distal ends obliterate. This forms a blind pouch from the ileum, which may become infected and ulcerate when it contains ectopic gastric or pancreatic tissue. Surgically, these are described as being found in 2% of the population, 2 inches long, and 2 feet from the ileocecal junction.
  - **Vitelline Fistula:** Occurs when the vitelline duct remains patent over its entire length and, thus, forms a complete communication between the midgut and the umbilicus at birth. The fistulas are associated with leakage of gut tube discharge and meconium at the umbilical stump after birth.
- The *allantois* is an open connection between the *cloaca* of the hindgut and the umbilicus during fetal life. The cloaca is the site where the urinary bladder develops. If the allantois obliterates properly, it forms a fibrous remnant called the *urachus (median umbilical ligament)* that connects the apex of the bladder to the umbilical ring. Malformation of the closure of the allantois may result in a newborn leaking urine at the umbilical stump.

9.2 Hypertrophic Pyloric Stenosis

Pyloric stenosis is one of the more common anomalies of the stomach. It occurs more often in females and results from a marked thickening and hypertrophy of the muscles of the pyloric region of the stomach. This results in severe narrowing of the pyloric canal and obstruction of the passage of food.

- Stomach becomes expanded and distended.
- Child will take a full feeding and, in a short time after feeding, will exhibit forceful, projectile vomiting.
- The vomitus is non-bile-stained because the obstruction is proximal to the bile duct.
- During fetal life, the fetus develops *polyhydramnios* due to the fact that it cannot properly ingest amniotic fluid.
- Best treatment is surgical.

Please visit us at www.Groupinsiders.com

© DeVry/Becker Educational Development Corp. All rights reserved.

9.3 Duodenal Stenosis and Atresia

Duodenal stenosis is a partial occlusion of the gut tube, usually resulting from incomplete recanalization of the lumen. *Duodenal atresia* is when the lumen is totally occluded.

- Most of these anomalies involve the distal half of the duodenum and are associated with *bile-stained* vomitus, *polyhydramnios*, and *enlarged stomach*.
- Duodenal atresia is often associated with other congenital anomalies.

9.4 Liver and Biliary System

- Congenital malformations of the liver are not common.
- *Biliary atresia* occurs with obliteration of the biliary ducts and being replaced by fibrous tissue. Soon after birth the infant has jaundice and clay-colored stools. Must be corrected for survival.

9.5 Omphalocele

Omphalocele is an anterior body wall defect resulting from failure of herniated abdominal contents to return through the umbilical ring.

- The basis for this defect is the failure of the midgut to return into the body cavity following its physiologic herniation during the sixth to tenth week.
- The herniated gut protrudes through the *umbilical ring* and is covered by a thin, *shiny sac* of amnion.
- Large omphaloceles can contain stomach, liver, and intestines.
- They are associated with other genetic cardiac and neural tube defects and have a high rate of mortality (25%).
- Is associated with elevated alpha-fetoprotein (AFP) during pregnancy.

9.6 Gastroschisis

Gastroschisis is an uncommon anterior body-wall defect resulting in a large amount of intestines and viscera herniated out of the body cavity at birth.

- The basis of this anomaly is a defect in the closure of the anterior body wall by the lateral body folds.
- Usually involves the *right lateral body wall fold* and massive amounts of gut protruding not through the umbilical ring, but to the *right of the umbilicus*.
- The gut is not enclosed in a sac and is exposed directly to the amniotic fluid during development.
- Is also associated with elevated alpha-fetoprotein (AFP) during pregnancy.
- Gastroschisis is not usually associated with other chromosome abnormalities or other severe defects, and survival rate is good.
- The gut has to be returned slowly to the abdominal cavity over time after birth.

Please visit us at www.Groupinsiders.com

© DeVry/Becker Educational Development Corp. All rights reserved.

9.7 Colonic Aganglionosis (Hirschsprung Disease)

Hirschsprung disease is the *absence of parasympathetic terminal ganglionic cells* in the myenteric and submucosal plexuses within the wall of the hindgut. Aganglionosis is due to the failure of *neural crest cells* to migrate into the hindgut during the fifth to seventh weeks.

- Results in the loss of peristalsis in the colon distal to the lesion.
- Most commonly affects the sigmoid colon and rectum.
- Infant will be unable to pass meconium.
- Proximal to the lesion the gut will be distended (megacolon).
- Often requires surgical correction.

▼ Table 8–9.7 Summary of Important Congenital Malformations of the Gastrointestinal System

Malformation	Clinical Features
Hypertrophic pyloric stenosis	• Thickening of the pylorus musculature • Projectile vomiting, non-bile-stained • Polyhydramnios
Annular pancreas	• Abnormal fusion of ventral and dorsal pancreatic buds, forming a constricting ring around the duodenum • Duodenal obstruction (bilious vomiting); presents shortly after birth • Polyhydramnios
Meckel diverticulum	• Persistent remnant of the vitelline duct • Forms an outpouching (diverticulum) in the ileum • Ulceration and bleeding • Fifty percent contain either gastric or pancreatic tissue when symptomatic
Malrotation of the midgut	• Normal 270-degree rotation is not completed • Cecum and appendix lie in upper abdomen • Associated with volvulus (twisting of intestine), causing an obstruction
Hirschsprung disease (congenital or toxic megacolon)	• Failure of neural crest cells to migrate to colon • No peristalsis • Constipation and abdominal distention in newborn • Bowel movement precipitated by digital rectal examination
Anal agenesis	• Lack of anal opening as a result of improper formation of the urorectal septum • May cause rectovesical (anus to bladder), rectovaginal, or rectourethral fistula

Please visit us at www.Groupinsiders.com

© DeVry/Becker Educational Development Corp. All rights reserved.

10 Adult Viscera of the Abdomen

10.1 Stomach

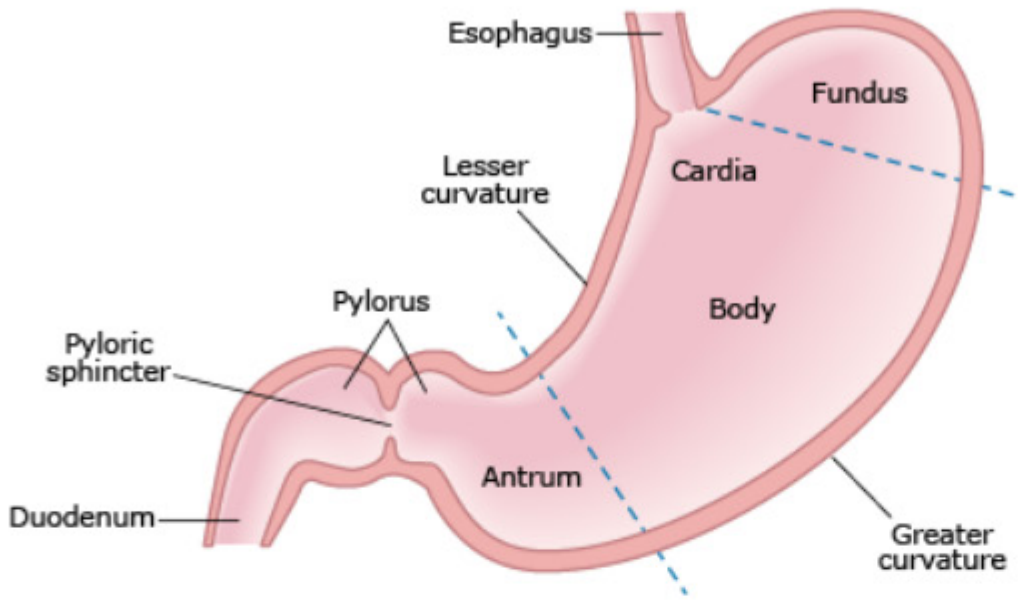

▲ **Figure 8–10.1** Stomach (Detail)

- The stomach is intraperitoneal, and the omental bursa is posterior to the body of the stomach.
- *Lesser curvature* forms the right border and is connected to the liver by the *lesser omentum* (hepatogastric).
- *Greater curvature* forms the left border with attachment of the *greater omentum*.
- Stomach is divided into the cardia, fundus, body, and pylorus.

Please visit us at www.Groupinsiders.com

© DeVry/Becker Educational Development Corp. All rights reserved.

10.2 Liver

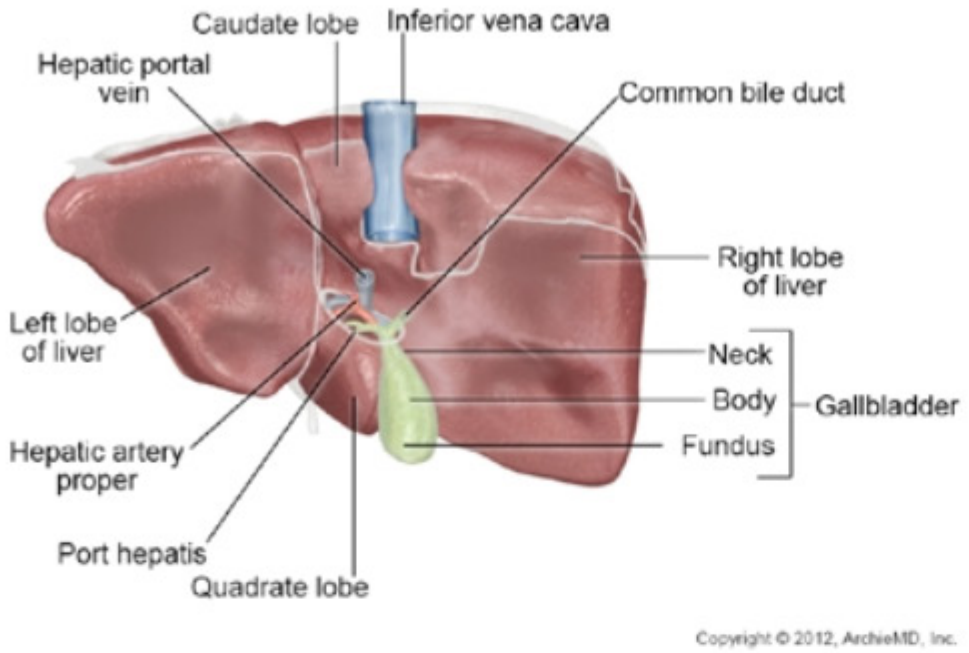

▲ **Figure 8–10.2** Liver—Visceral Surface

- The liver develops from foregut endoderm and occupies most of the right quadrant of the abdomen. It has two surfaces and four anatomic lobes.
- The *diaphragmatic surface* is superior and attached to the diaphragm and body wall by the *falciform ligament* (contains the *ligamentum teres* of the liver).
- The *visceral surface* is inferior and attached to the first part of the duodenum and lesser curvature of the stomach by the *lesser omentum* (hepatoduodenal and hepatogastric ligaments, respectively). The structures of the *portal triad (hepatic portal vein, proper hepatic artery, and common hepatic duct)* course through the *hepatoduodenal ligament* to enter the liver at the hilus or *porta hepatis* on the visceral surface.
- The liver is divided into four lobes: right, left, quadrate, and caudate. Functionally, the quadrate and most of the caudate lobes are part of the left lobe.
- The *hepatic portal vein* drains blood to the liver from the gut tub.
- *Hepatic veins* drain blood from the liver to the inferior vena cava.

Please visit us at www.Groupinsiders.com

© DeVry/Becker Educational Development Corp. All rights reserved.

10.3 Bile Duct System

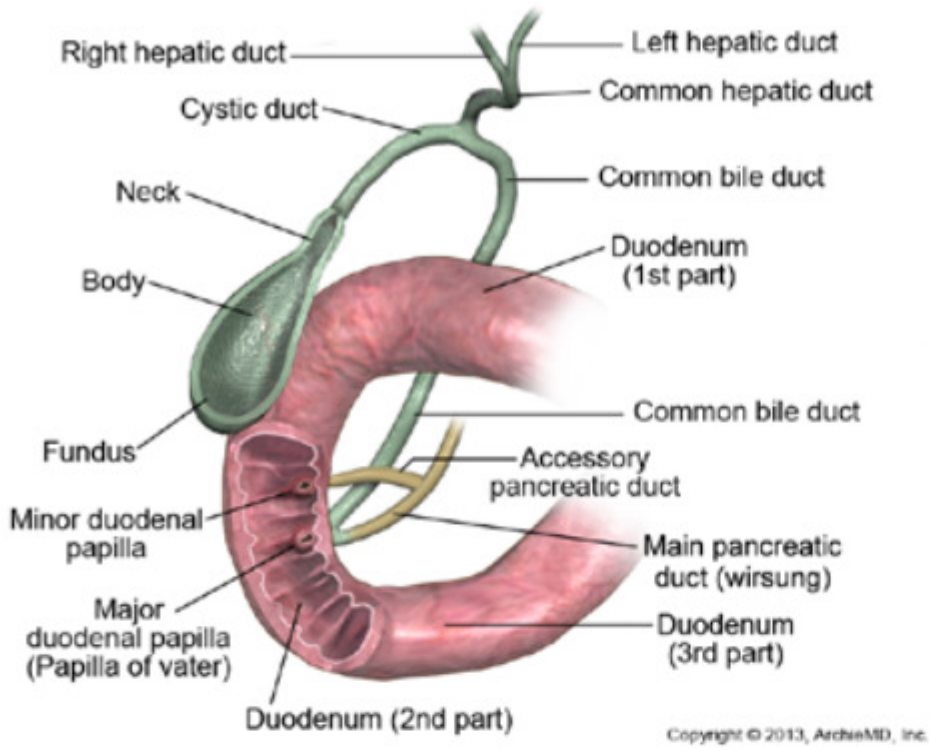

▲ **Figure 8–10.3** Bile Drainage

- The *right* and *left hepatic ducts* form at the porta hepatis of the liver and drain bile from each half of the liver.
- The right and left hepatic ducts fuse to form the *common hepatic duct* at the porta hepatis.
- The *cystic duct* drains the gallbladder and fuses with the common hepatic duct to form the *common bile duct*.
- The common bile duct courses in the *hepatoduodenal ligament* with the *proper hepatic artery and the hepatic portal vein*.
- The *common bile duct* descends posterior to the first part of the duodenum and runs through the head of the pancreas. In the pancreas, the common bile duct joins with the *main pancreatic duct* and drains into the second part of the duodenum at the ampulla of Vater.

Clinical Application

Pathology within the head of the pancreas (pancreatic carcinoma) can obstruct the common bile duct and pancreatic duct and result in jaundice.

Please visit us at www.Groupinsiders.com

© DeVry/Becker Educational Development Corp. All rights reserved.

10.4 Pancreas

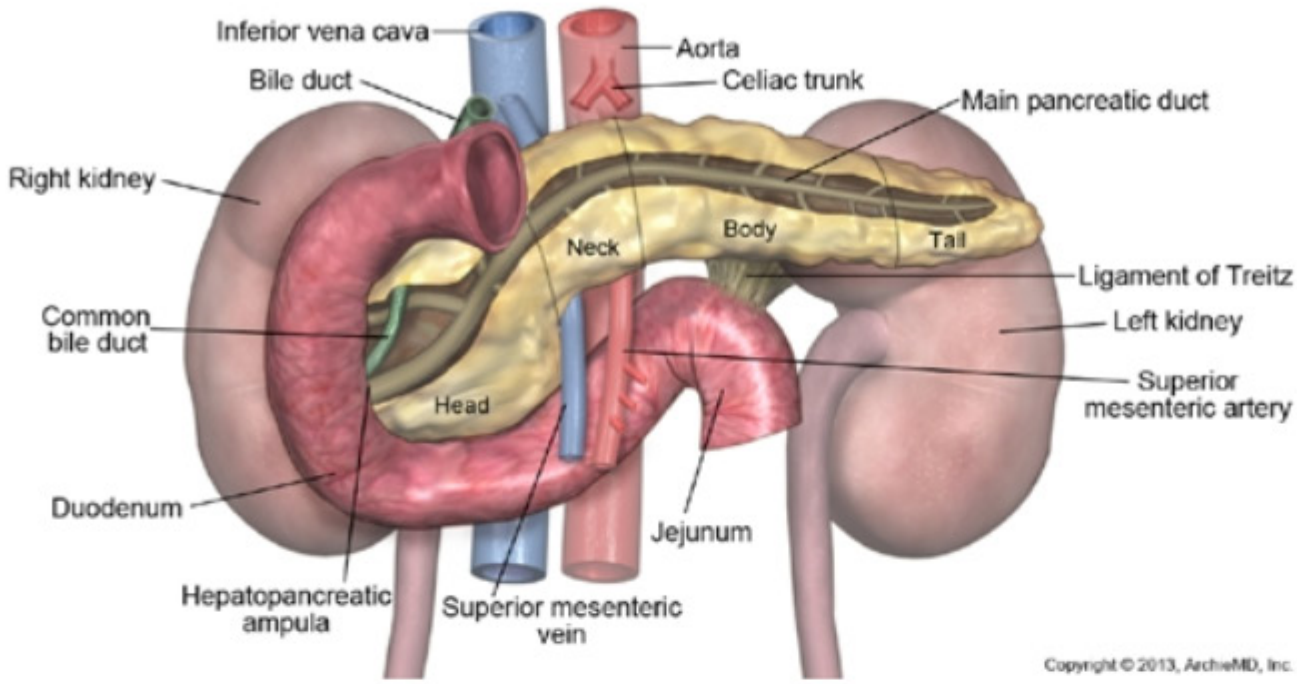

▲ **Figure 8–10.4** Pancreas

- The pancreas develops from two buds of foregut *endoderm*. Except for the tail, most of the pancreas is retroperitoneal and occupies a horizontal position across the dorsal body wall at the transpyloric plane (L1 level).
- The pancreas is divided into four parts:
  - **Head and uncinate process** are located within the concavity of the duodenum.
  - **Neck** is close to the midline and the formation of the hepatic portal vein is posterior.
  - **Body** crosses to the left anterior to the left kidney and adrenal gland.
  - **Tail** enters the *splenorenal ligament* with the splenic vessels at the hilum of the spleen.
- The *main pancreatic duct of Wirsung* travels through the neck and body of the pancreas to reach the head, where it is joined by the *common bile duct* to drain into the *second part of the duodenum at the ampulla of Vater*. Carcinoma in the head of the pancreas may compress the common bile duct and result in jaundice.

10.5 Spleen

The spleen lies in the upper left quadrant of the abdomen posterior to the midaxillary line and deep to ribs 9 to 11.

- The spleen develops from mesoderm and is intraperitoneal, with the splenorenal and splenogastric ligaments attached to its visceral surface.
- The visceral surface is related to the stomach, left kidney, and splenic flexure.
- The splenic vessels reach the hilus of the spleen via the splenorenal ligament.

Fracture of ribs 9–11 may lacerated the spleen on the left side.

Please visit us at www.Groupinsiders.com

© DeVry/Becker Educational Development Corp. All rights reserved.

10.6 Duodenum

The duodenum is the first segment of the small intestines. It is C-shaped and wraps itself around the head of the pancreas.

- The duodenum is divided into four numbered parts. The first part is intraperitoneal, but the rest are retroperitoneal.
- The *gastroduodenal vessels* and the *common bile duct* descend posterior to the first part of the duodenum (duodenal bulb) to reach the head of the pancreas.
- The common bile duct and the main pancreatic duct empty into the second part of the duodenum at the ampulla of Vater. The entrance of the bile duct into the duodenum is the landmark separating the foregut from the midgut.

10.7 Jejunum and Ileum

The jejunum and the ileum are the longest segments of the midgut. After the 270-degree rotation of the midgut, the jejunum occupies the upper left, and the ileum occupies the lower right aspect of the abdominal space. They are intraperitoneal organs and are attached to the mesentery proper.

- The jejunum begins at the duodenojejunal junction, located about 2 cm to the left of the midline at the L2 vertebral level.
- The duodenojejunal flexure is supported by the ligament of Treitz, which attaches to the right crus of the diaphragm. The ligament contains muscle tissue and connective tissue.
- The ligament of Treitz is used as a clinical dividing line between the upper and lower GI tract.
- The ileum empties into the ileocecal junction that is guarded by a muscular valve.

10.8 Large Intestines

The large colon consists of the cecum, ascending, transverse, descending, and the sigmoid colon.

- The transverse and sigmoid colon are intraperitoneal, being attached to the transverse mesocolon and sigmoid mesocolon, respectively. The ascending and descending colon are retroperitoneal.
- The large colon is characterized by three longitudinal bands of smooth muscle (teniae coli) that produce sacculations called haustra.

10.9 Rectum

The rectum and the anal canal are the terminal ends of the GI tract. The rectum begins at approximately at the S3 vertebral level and curves as it descends on the concavity of the sacrum to end at the anal canal as it passes through the pelvic diaphragm to enter the ischioanal fossa of the perineum.

Please visit us at www.Groupinsiders.com

© DeVry/Becker Educational Development Corp. All rights reserved.

10.10 Anal Canal

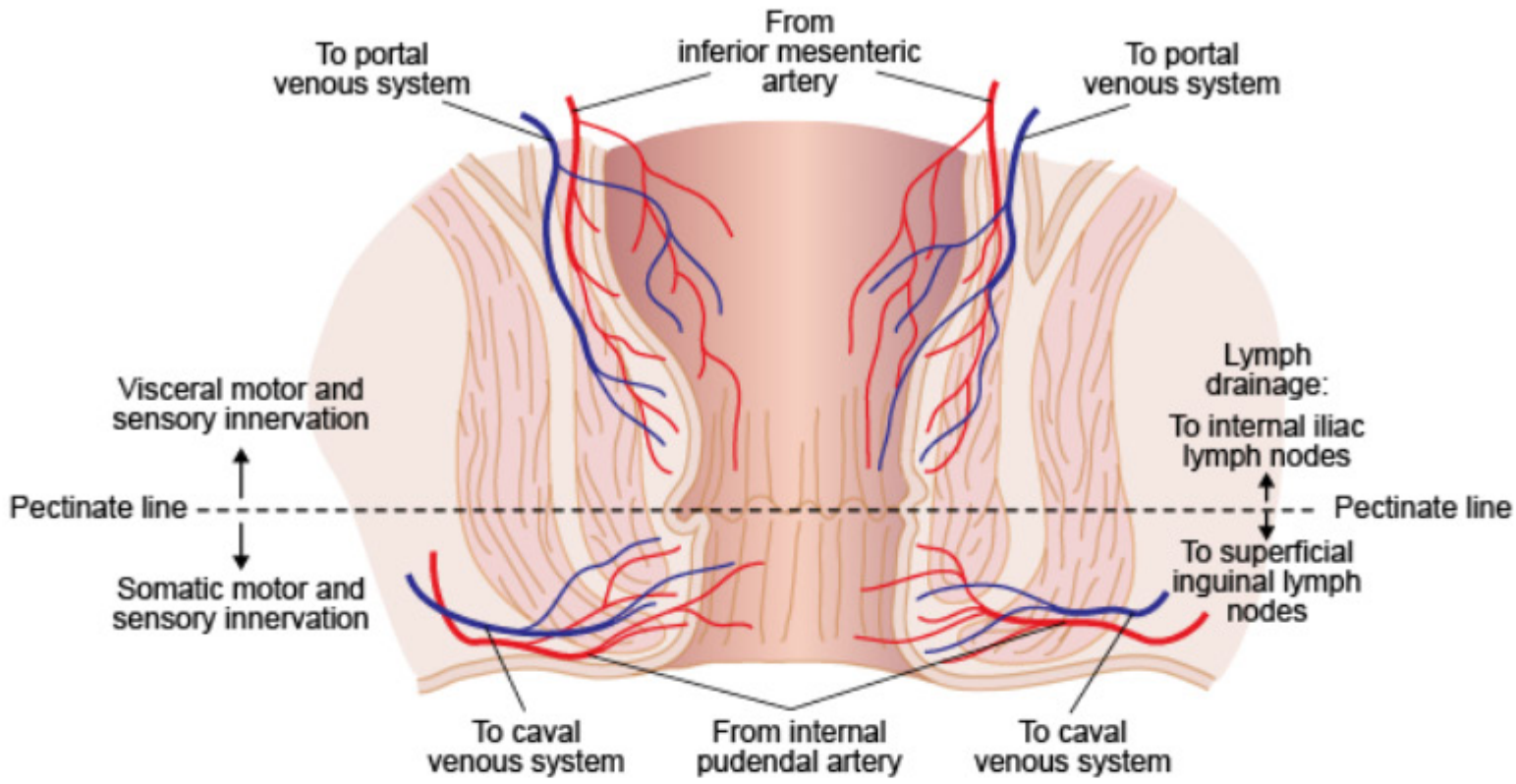

▲ **Figure 8–10.10** Anal Canal

The rectum is continuous with the anal canal at the pelvic diaphragm. There is a 90-degree posterior angle at the anorectal junction. The anal canal is divided into an upper portion and a lower portion by the *pectinate line*. The upper part of the anal canal is the distal end of the hindgut, and the lower portion is part of the anal triangle of the perineum. Characteristics of the anal canal above and below the pectinate line are shown in Figure 8–10.10.

- The *pectinate line* is a circular elevated ring of submucosal blood vessels at the midpoint of the canal.
- There are two muscular sphincters related to the wall of the anal canal:
  - **Internal Anal Sphincter:** Smooth muscle sphincter in wall of the canal that relaxes under parasympathetic control (pelvic splanchnics, S2, S3, and S4) and contracts under sympathetic control (lumbar splanchnics, L1–L2).
  - **External Anal Sphincter:** Circular skeletal muscle under voluntary control innervated by the pudendal nerve of the perineum.

Please visit us at www.Groupinsiders.com

© DeVry/Becker Educational Development Corp. All rights reserved.

11 Blood Supply to Abdomen

11.1 Abdominal Aorta

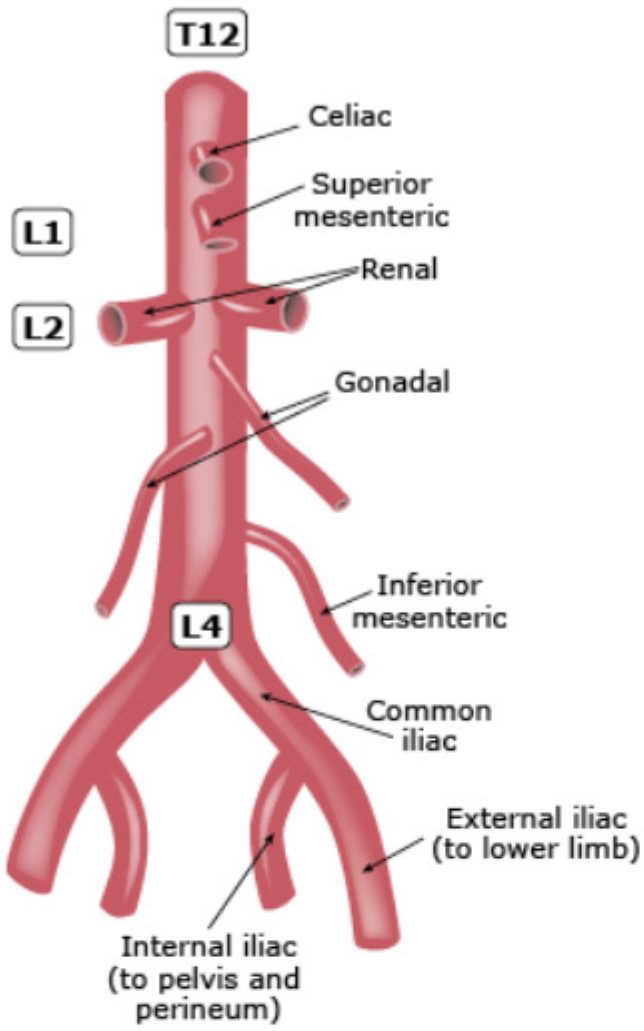

▲ **Figure 8–11.1** Aorta

The abdominal aorta passes through the aortic aperture between the right and left crura of the diaphragm at the T12 vertebra. The aorta descends on the lumbar vertebrae slightly to the left of the midline. At the L4 vertebrae, the aorta bifurcates into the right and left common iliac arteries.

The major branches of the abdominal aorta are shown and organized on Figure 8–11.1. The branches of the abdominal aorta are organized into three groups:

- Three unpaired visceral branches to the GI tract.
- Paired visceral branches.
- Paired and unpaired parietal branches.

Important Concept

Abdominal Aorta Branches

1. Visceral branches:
   - Unpaired
     - —Celiac (foregut)
     - —Superior mesentric (midgut)
     - —Inferior mesentric (hindgut)
   - Paired
     - —Middle suprarenals
     - —Renals
     - —Gonadals
2. Parietal branches
   - Unpaired
     - —Medial sacral
   - Paired
     - —Inferior phrenics
     - —Lumbars
     - —Comon iliac

Please visit us at www.Groupinsiders.com

© DeVry/Becker Educational Development Corp. All rights reserved.

11.2 Blood Supply to the Foregut, Midgut, and Hindgut

The gut tube receives its blood supply from three unpaired branches of the abdominal aorta: (1) celiac artery, (2) superior mesenteric artery, and (3) inferior mesenteric artery.

11.2.1 Celiac Artery

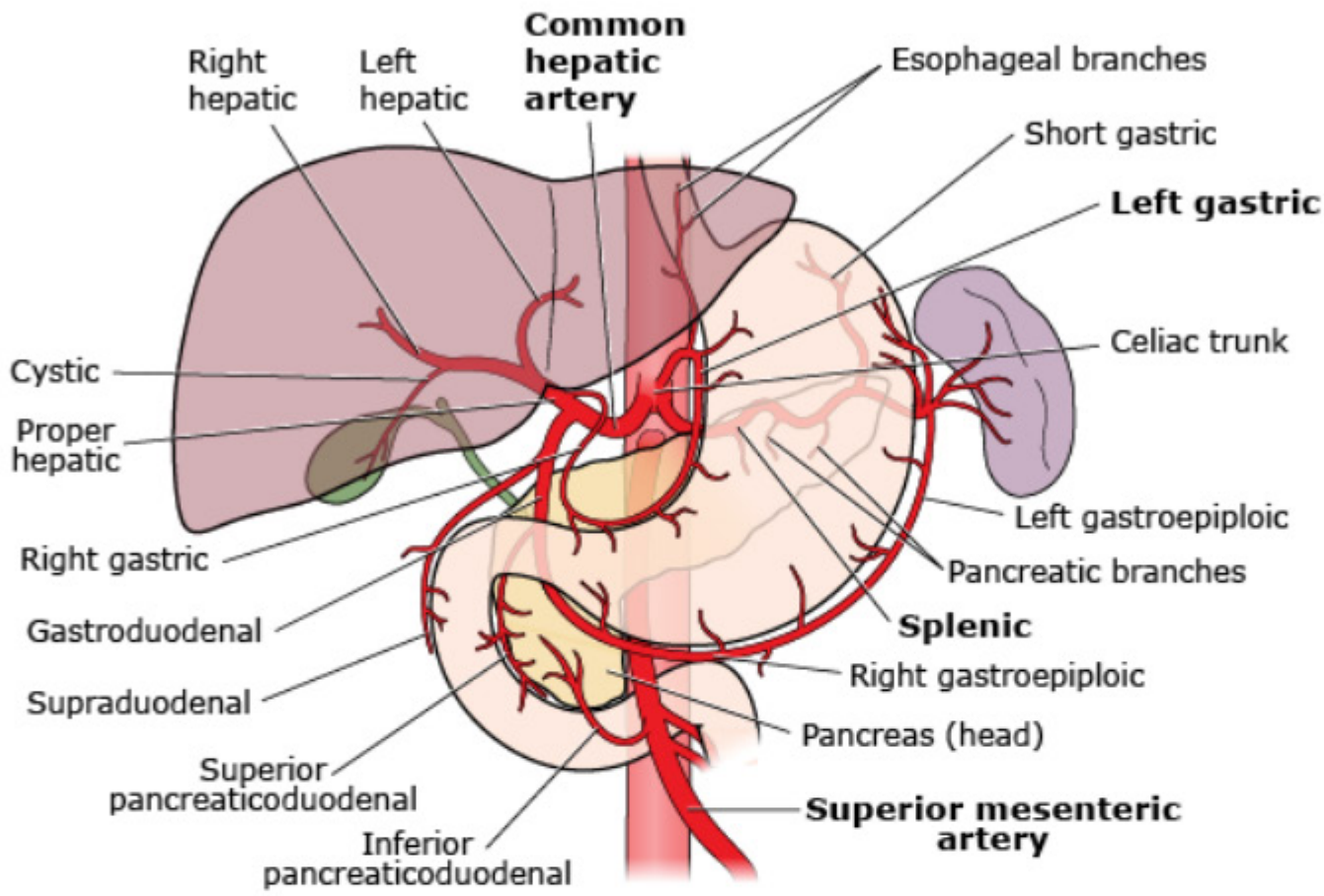

▲ **Figure 8–11.2A** Celiac Trunk

The celiac artery (or trunk) is the blood supply to the foregut structures. It arises from the ventral surface of the aorta at the level of the lower aspect of the T12 vertebra or the upper aspect of the L1 vertebra immediately below the diaphragmatic aperture. The celiac artery is located at the midline at the superior border of the pancreas. Within about 1 cm, the celiac artery divides into three branches: the left gastric, splenic and common hepatic arteries. All of these vessels begin in a retroperitoneal position, but later enter mesenteries.

Please visit us at www.Groupinsiders.com

© DeVry/Becker Educational Development Corp. All rights reserved.

The branches of the celiac artery include:

- The *left gastric artery* arches superiorly and to the left to course on and supply most of the *lesser curvature of the stomach*. It also has a small esophageal branch that supplies the abdominal part of the esophagus.
- The *splenic artery* is the largest and longest branch and runs to the left in a very tortuous course posterior to the body of the stomach along the upper border of the pancreas to reach the spleen. Distally, the splenic vessels enter the *splenorenal ligament* at the hilum of the spleen. The distributions of the splenic artery include:
  - Spleen
  - Several pancreatic branches to the neck, body, and tail of the pancreas
  - Short gastric arteries to the fundus of the stomach
  - The left gastroepiploic artery is a distal branch of the splenic artery. It courses on and supplies the left aspect of the greater curvature of the stomach and connects with the right gastroepiploic artery.
- The *common hepatic artery* travels a short distance to the right along the upper border of the pancreas and the first part of the duodenum, the duodenal bulb, where it divides into two branches:
  1. The *proper hepatic artery* ascends the hepatoduodenal ligament (with common bile duct and hepatic portal vein) to reach the porta hepatitis. At the porta, the proper hepatic artery divides into the *right and left hepatic arteries* that supply the liver. The right hepatic artery also gives rise to the *cystic artery*, supplying the gallbladder. A small and often insignificant right colic artery may be a branch of the proper hepatic artery.
  2. The *gastroduodenal artery* descends posterior to the duodenal bulb with the common bile duct to reach the head of the pancreas. *It supplies the duodenum and head of the pancreas via the superior pancreaticoduodenal arteries and the right aspect of the greater curvature of the stomach via the right gastroepiploic artery*.

Clinical Application

Note that two of the branches of the celiac system have posterior relationships with two parts of the foregut:

- **Splenic Artery:** Courses posterior to the body of the stomach and may hemorrhage with ulcerations of the posterior wall of the stomach.
- **Gastroduodenal Artery:** Descends posterior to the first part of the duodenum (bulb) and may hemorrhage with ulcerations of the duodenal bulb.

Please visit us at www.Groupinsiders.com

© DeVry/Becker Educational Development Corp. All rights reserved.

Please visit us at www.Groupinsiders.com

Clinical Application

The superior pancreaticoduodenal branches establish collateral arterial connections with inferior pancreaticoduodenal branches (branch of superior mesenteric artery) within the head of the pancreas. These collaterals establish very important collateralization between the celiac and superior mesenteric artery.

11.2.2 Superior Mesenteric Artery

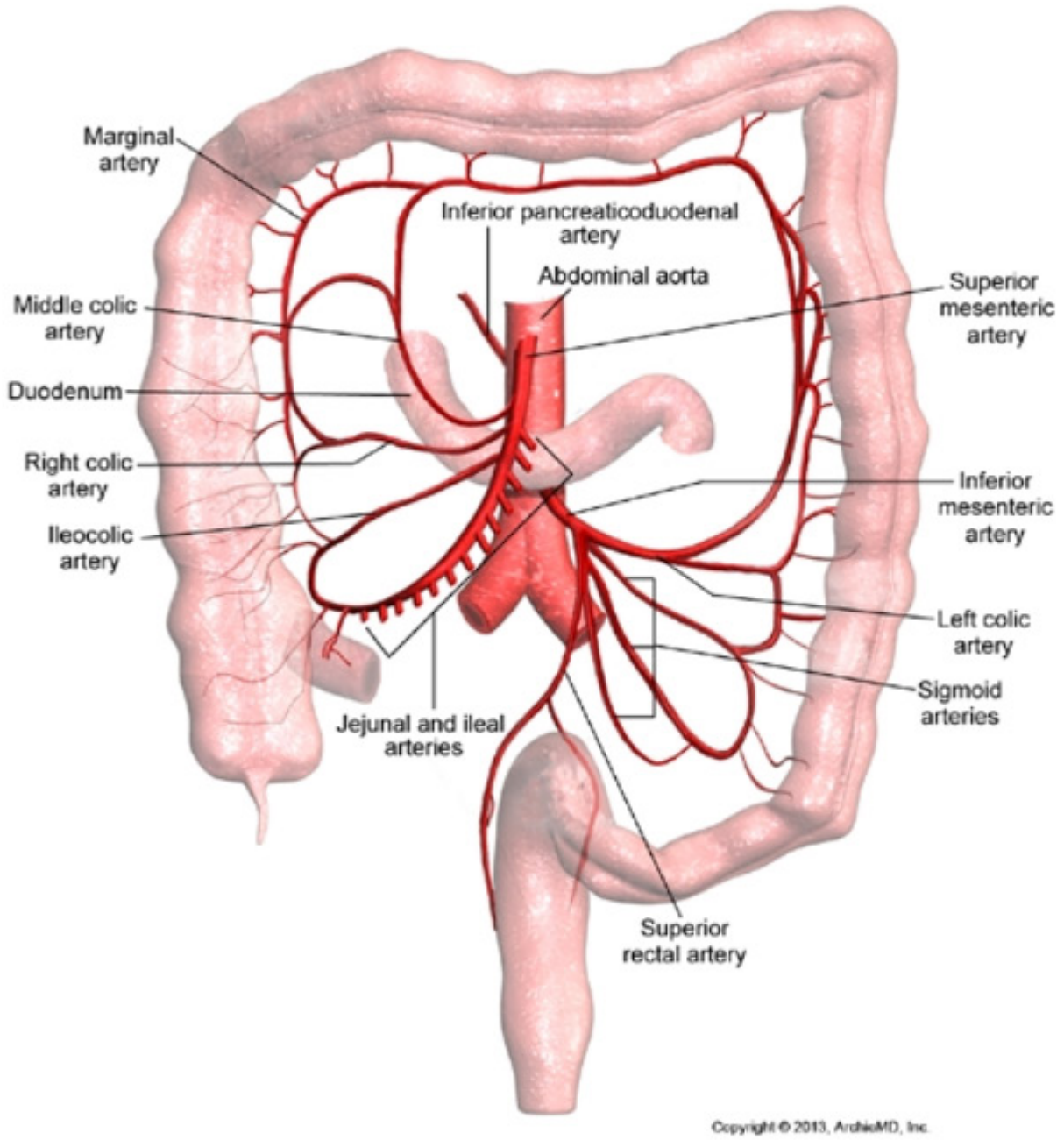

▲ **Figure 8–11.2B** Superior and Inferior Mesenteric Arteries

© DeVry/Becker Educational Development Corp. All rights reserved.

The *superior mesenteric artery* (SMA) supplies the *midgut structures*. The SMA branches from the ventral surface of the abdominal aorta at the level of the L1 vertebra. Its origin is very close to the celiac artery, and sometimes they have common origins from the aorta. The SMA arises from the aorta posterior to the neck of the pancreas and descends across the uncinate process of the head of the pancreas and anterior to the third part of the duodenum and the left renal vein to enter the root of the mesentery proper.

The branches of the SMA include:

- *Inferior pancreaticoduodenal branches* to the *head of the pancreas*. Note that the head of the pancreas has dual blood supply: pancreaticoduodenal branches from the celiac and SMA. These two sets of vessels provide an effective *collateralization* between the celiac artery and the SMA within the head of the pancreas, as discussed earlier.
- *Multiple intestinal branches* from the left side of the SMA supply the jejunum and ileum.
- *Ileocolic artery* supplies the distal ileum, cecum, and part of the ascending colon.
- *Right colic artery* supplies the ascending colon.
- *Middle colic artery* supplies the proximal two thirds of the transverse colon.

11.2.3 Inferior Mesenteric Artery

The *inferior mesenteric artery* (IMA) supplies the structures of the *hindgut*. The IMA arises from the left side of the abdominal aorta at the L3 vertebral level. The artery crosses the posterior abdominal wall posterior to the peritoneum to reach the hindgut.

The distributions of the IMA include:

- *Left colic artery* to the descending colon
- *Several sigmoidal arteries* to the sigmoid colon
- *Superior rectal artery* descends into the pelvic cavity and supplies the upper part of the rectum. The rectum also receives blood supply from the middle and inferior rectal branches of the internal iliac artery.

Clinical Application

The *marginal artery (of Drummond)* forms a collateral ring of vessels around the perimeter of the large colon that connects branches of the SMA and IMA. Note that the collaterals to the splenic flexure are the least effective of the entire gut tube, and the splenic flexure is the first part of the gut tube to become ischemic with decreasing blood flow.

Please visit us at www.Groupinsiders.com

© DeVry/Becker Educational Development Corp. All rights reserved.

12 Veins of the Abdomen

12.1 Inferior Vena Cava

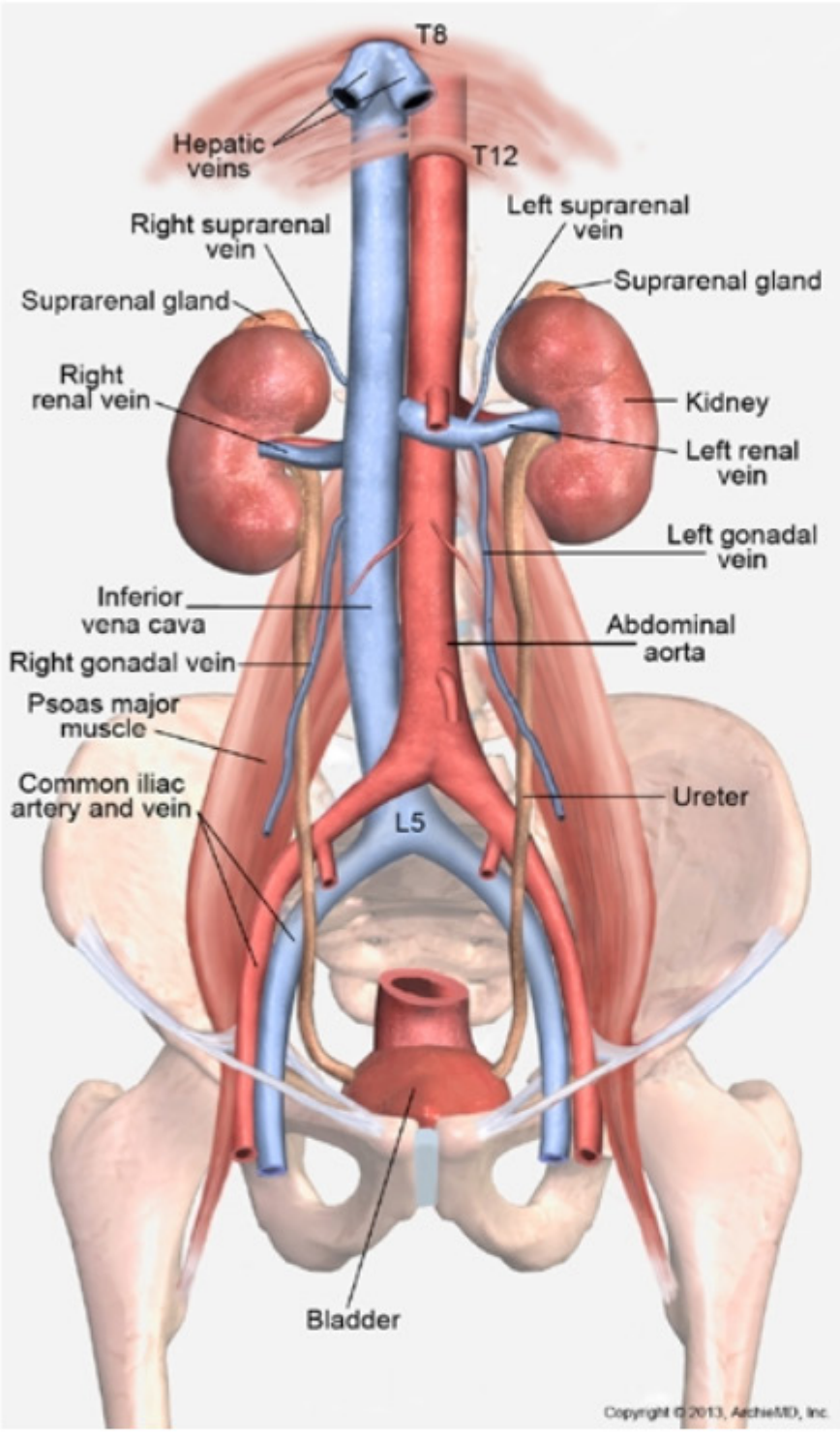

▲ **Figure 8–12.1** Inferior Vena Cava

The inferior vena cava (IVC) begins at the L5 vertebral level by the confluence of the two common iliac veins. It ascends on the right side of the vertebral bodies and the abdominal aorta and passes through the central tendon of the diaphragm at the *T8 vertebral level*. Thus, the inferior vena cava is longer than the abdomen within the abdomen.

- *The common iliac veins* return blood from the lower limbs, pelvis and perineum.
- The IVC receives venous drainages from the liver via *hepatic veins*.
- The IVC receives venous drainage from the kidneys via the two *renal veins* at the L2 vertebral level and the lumbar veins draining the posterior body wall.

Clinical Application

The left renal vein passes between the superior mesenteric artery and the aorta ("Nutcracker.") Aneurysm of the SMA can compress the left renal vein resulting in a variocele on the left scrotum.

Clinical Application

Left Varicocele

Left renal disease may produce left renal hypertension and cause blood to stagnate into the left testicular and pampiniform plexus of veins, and result in a left varicocele.

Please visit us at www.Groupinsiders.com

© DeVry/Becker Educational Development Corp. All rights reserved.

- The *left renal* vein with the third part of the duodenum courses between the superior mesenteric artery (anteriorly) and the abdominal aorta (posteriorly) to reach the IVC ("nutcracker").

Note: There is asymmetry in the venous tributaries to the IVC. On the right side, the IVC receives the right gonadal, suprarenal, and inferior phrenic veins. But on the left, these veins usually drain into the left renal vein.

12.2 Hepatic Portal Venous System

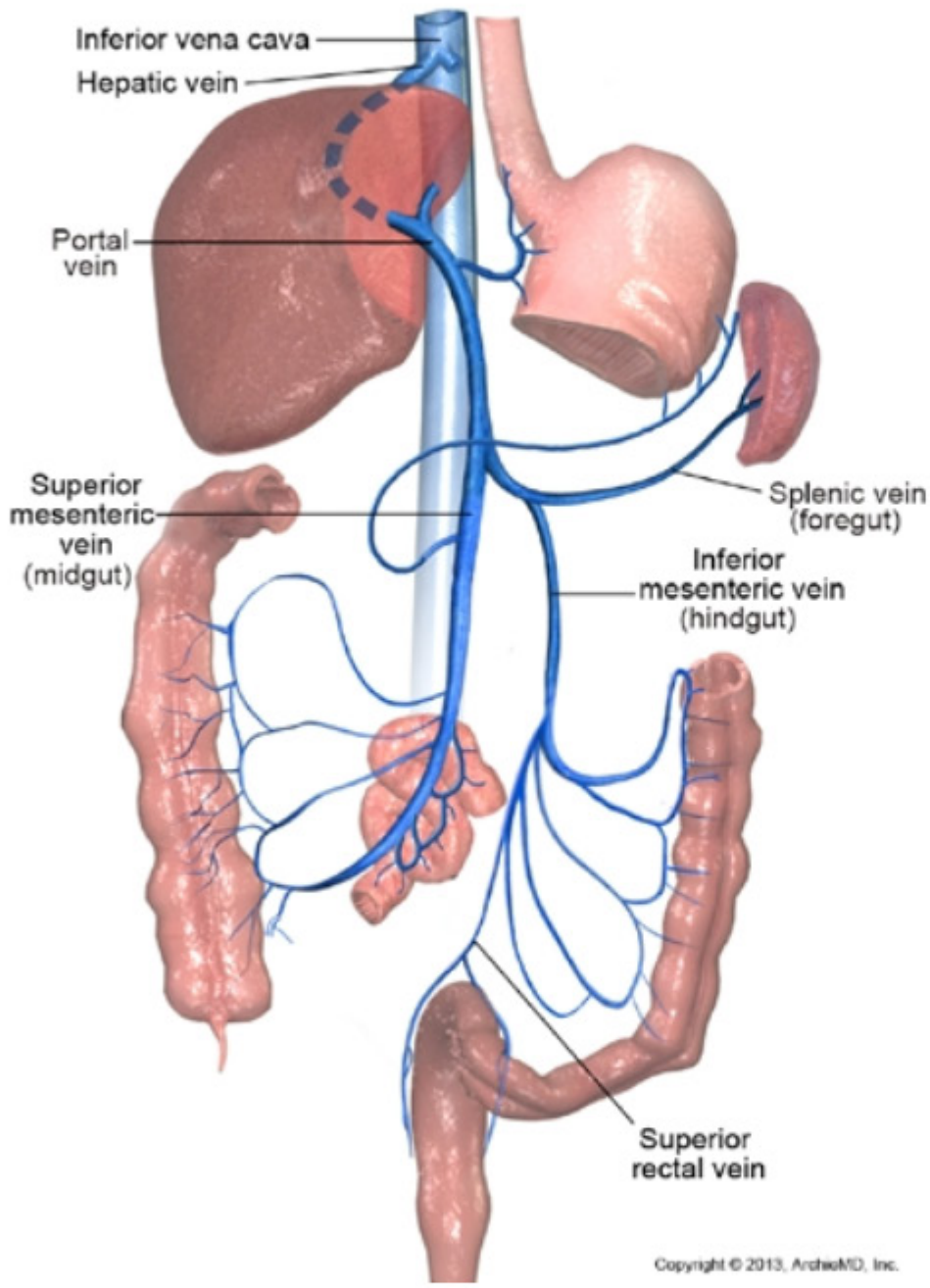

▲ **Figure 8–12.2** Portal Venous System

The *hepatic portal venous system* drains most of the blood from the gastrointestinal tract that was supplied by the celiac artery, the SMA, and the IMA. It brings absorbed nutrient products from the GI tract to the liver for metabolism. The blood flows through the sinusoids of the hepatic lobules and is collected by the *hepatic veins*, which return the blood to the inferior vena cava and to the right atrium.

- The *hepatic portal vein* forms posterior to the neck of the pancreas by the junction of the *splenic* and the *superior mesenteric veins*. There is no celiac vein, and the splenic vein drains most of the blood from the foregut.

Please visit us at www.Groupinsiders.com

© DeVry/Becker Educational Development Corp. All rights reserved.

- The inferior mesenteric vein usually drains into the splenic vein.
- The hepatic portal vein ascends posterior to the proper hepatic artery and the common bile duct within the *hepatoduodenal ligament to enter the liver at the portal hepatis*.

12.3 Portal-Caval Anastomoses

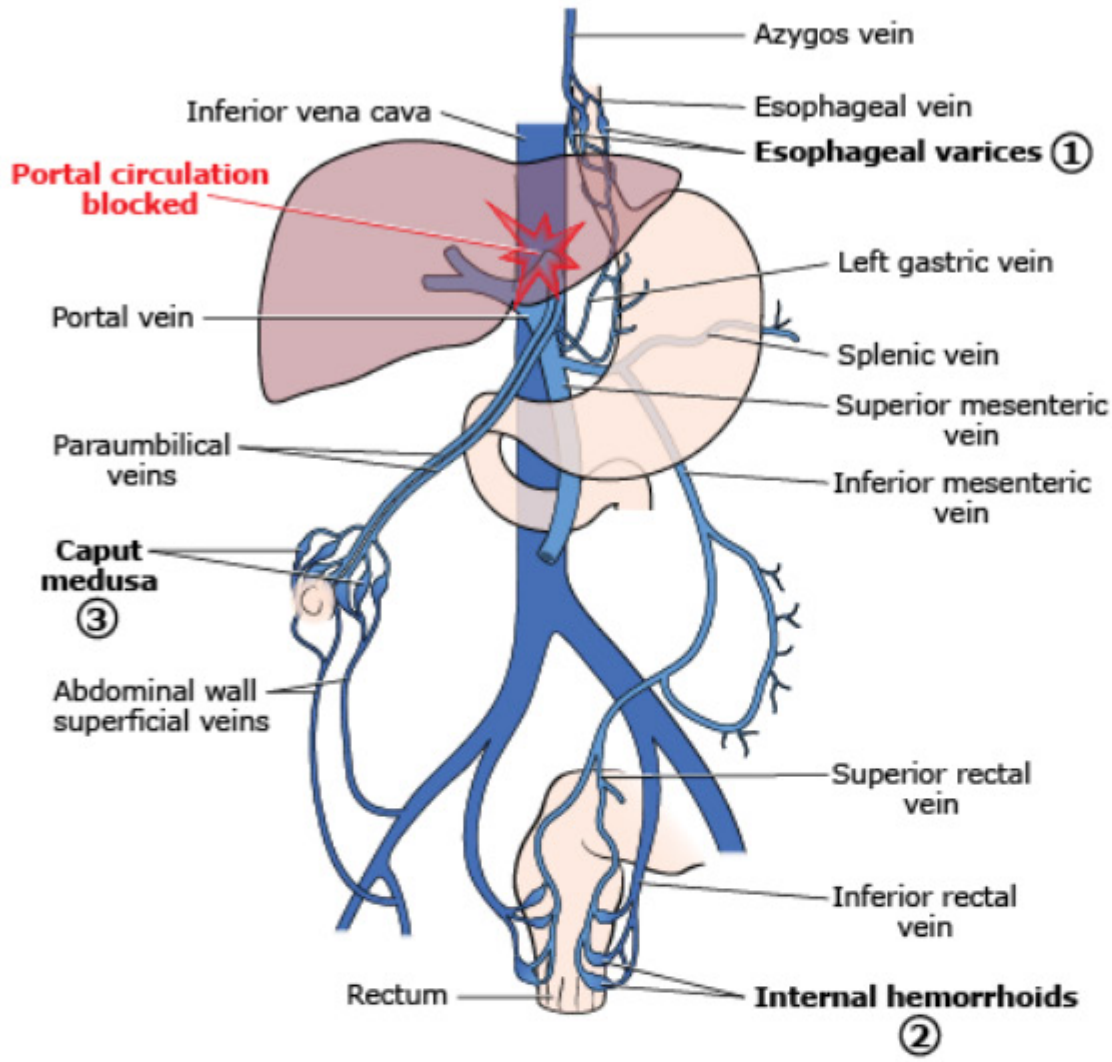

▲ **Figure 8–12.3** Portal-Caval Anastomoses

With the development of liver disease (tumors, cirrhosis, thrombosis), normal portal circulation is interrupted through the liver and backs up into and engorges the portal system, producing portal hypertension. Alternative return routes of blood to the heart have to develop over time. At three main sites, veins of the portal system collateralize with veins that drain into the caval system. These important portal-caval anastomoses are outlined in Table 8–12.3.

▼ **Table 8–12.3** Clinical Signs of Portal Hypertension

Site of Anastomosis	Clinical Sign	Veins Involved in Portal ↔ Inferior Venal Caval Anastomosis
Esophagus (site 1)	Esophageal varices	Left gastric vein ⟷ azygos vein
Rectum (site 2)	Anorectal varices (Internal hemorrhoids)	Superior rectal vein ⟷ middle and inferior rectal veins
Umbilicus (site 3)	Caput medusa	Paraumbilibal vein ⟷ superficial and inferior epigastric veins

Please visit us at www.Groupinsiders.com

© DeVry/Becker Educational Development Corp. All rights reserved.

13 Development of the Urinary System

13.1 Development of the Kidneys

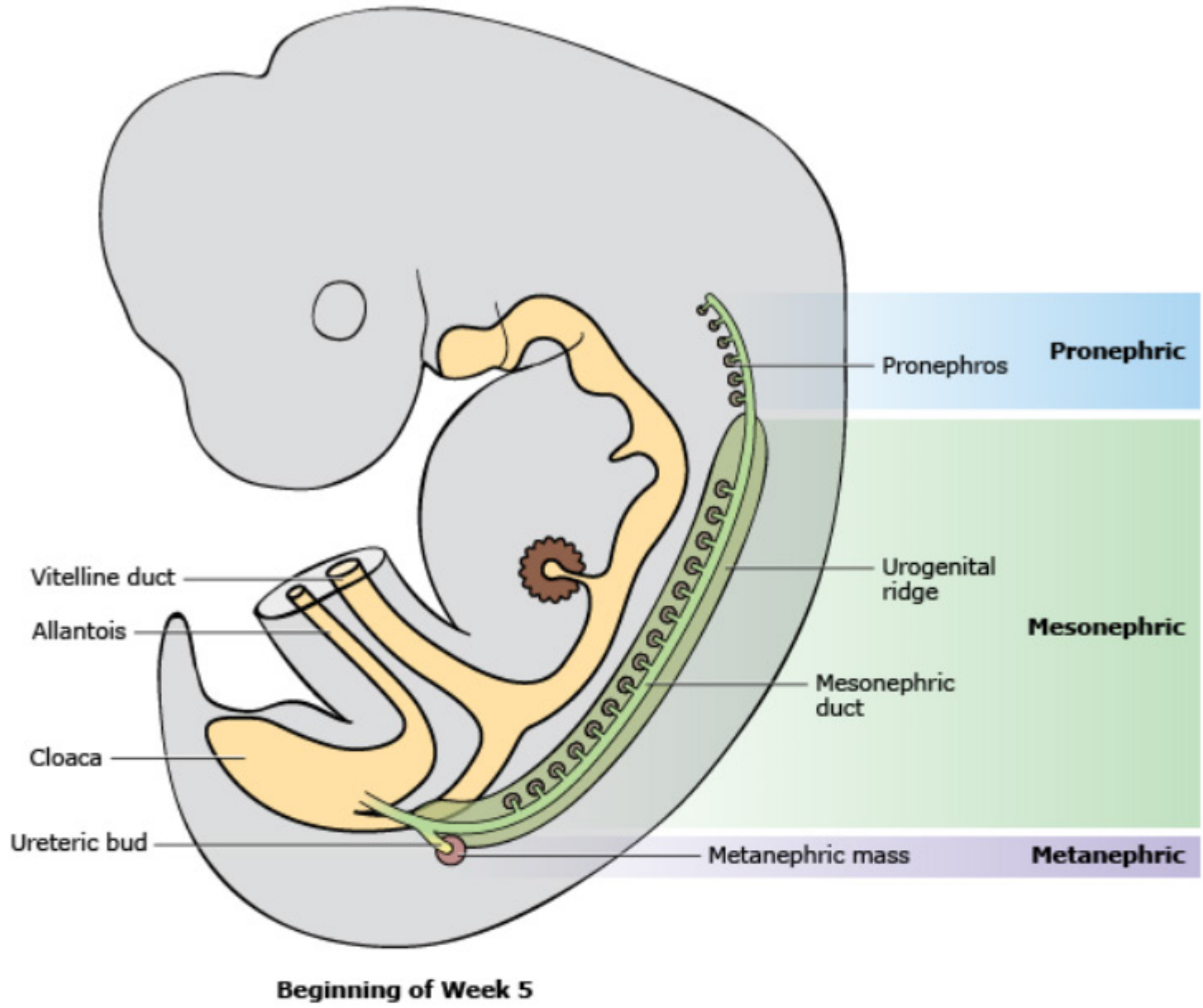

▲ **Figure 8–13.1A** Renal Development

Kidneys develop from the *intermediate mesoderm* of the *urogenital ridge*. The human kidney develops in three successive stages between the 4th and the 10th weeks.

- **Pronephros:** This first kidney develops at the cranial end of the urogenital ridge and quickly regresses. It never functions in humans.
- **Mesonephros:** This is the second kidney that forms in the late fourth week and has a filtration function until the later part of the first trimester, when the permanent kidney develops. This kidney develops a mesonephric duct that drains into the cloaca of the hindgut. When the mesonephros regresses, the mesonephric duct is retained in the male, contributing to the male genital tract. The duct completely regresses in the female after a short period.

Please visit us at www.Groupinsiders.com

© DeVry/Becker Educational Development Corp. All rights reserved.

- **Metanephros:** This forms the final kidney and becomes functional about the 10th week. This kidney develops from two mesoderm sources:
  1. The *ureteric bud* is an outgrowth from the mesonephric duct near the cloaca. It will be the primordium of the ureter, renal pelvis, minor and major calices and the collecting tubules. All of these drain urine from the kidneys.
  2. The *metanephric mass* (or blastema) is mesoderm that forms a cap over the ureteric bud. It will form the nephron of the kidney within the cortex and medulla.

Note: The ureteric bud and metanephric mass are both required for renal development.

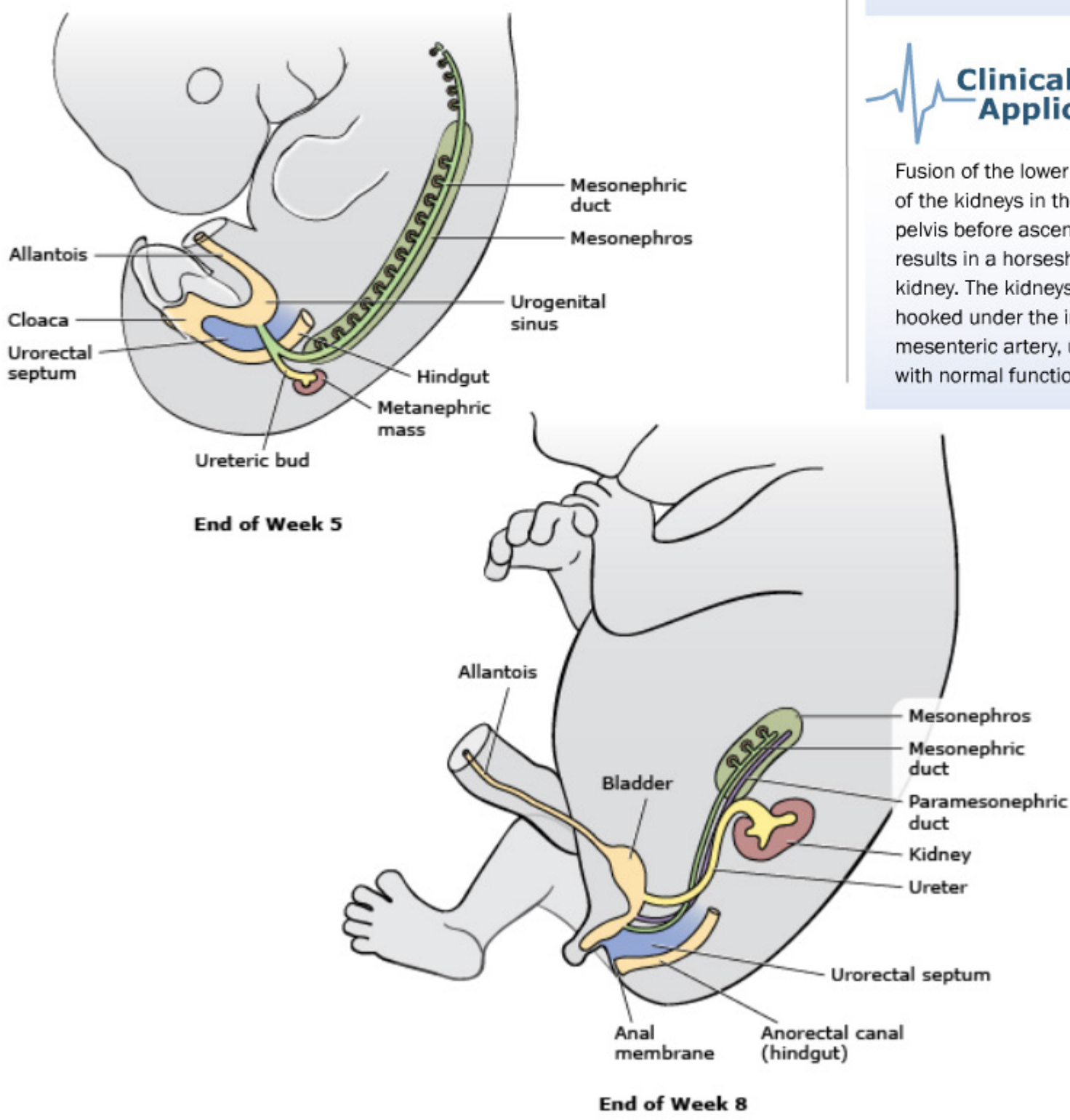

▲ **Figure 8–13.1B** Metanephric Kidney

Clinical Application

Renal Agenesis

Failure of the ureteric bud or the metanephric mass to develop results in failure of the kidney to develop on that side. Bilateral renal agenesis is fatal and is associated with oligohydramnios and Potter sequence: pulmonary hypoplasia, limb defects and facial deformities.

Clinical Application

Fusion of the lower poles of the kidneys in the pelvis before ascension results in a horseshoe kidney. The kidneys are hooked under the inferior mesenteric artery, usually with normal function.

Please visit us at www.Groupinsiders.com

© DeVry/Becker Educational Development Corp. All rights reserved.

13.2 Development of Urinary Bladder and Urethra

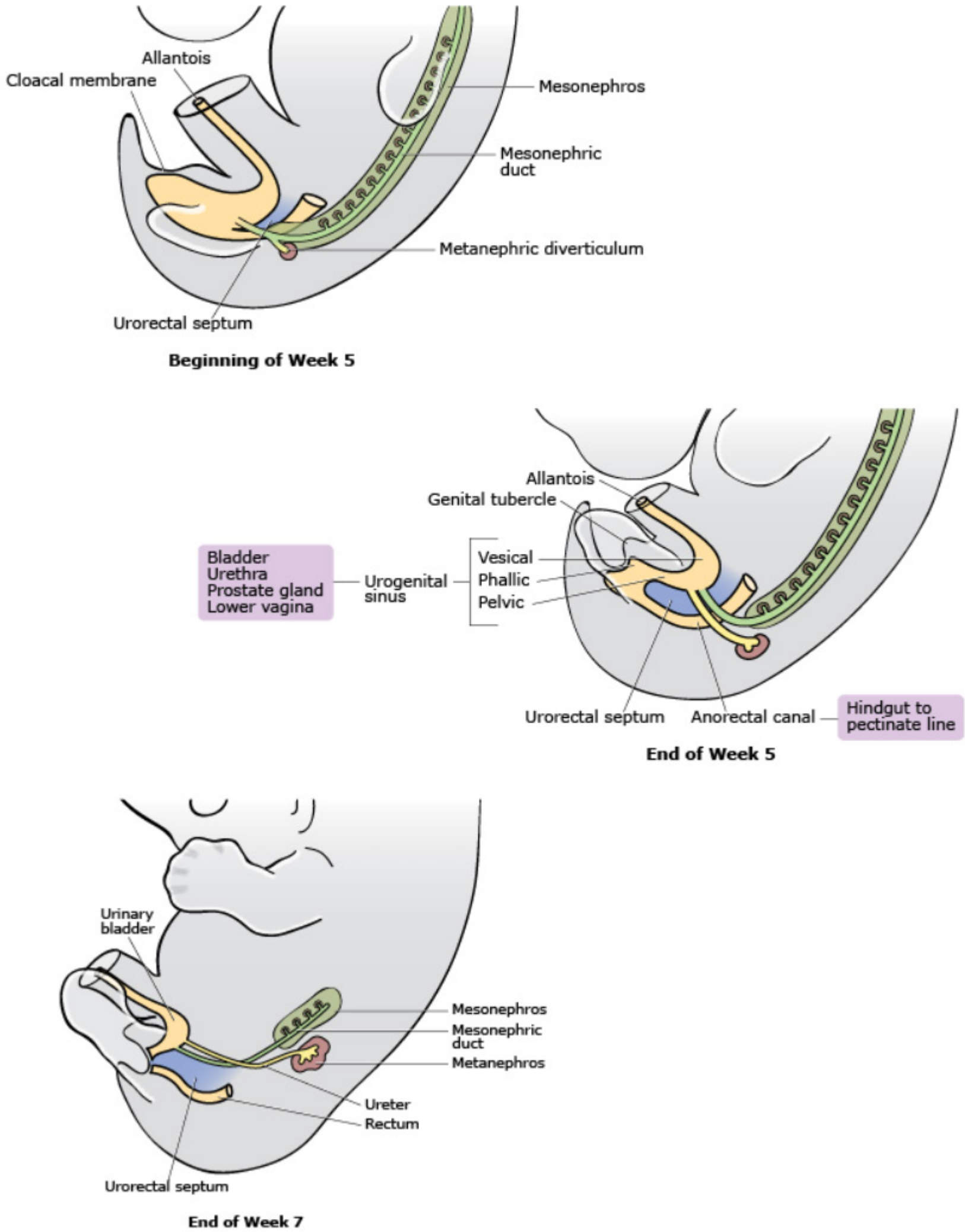

▲ **Figure 8–13.2A** Development of Hindgut and Urinary Bladder

Please visit us at www.Groupinsiders.com

© DeVry/Becker Educational Development Corp. All rights reserved.

The *urinary bladder* and *urethra* develop following the septation of the cloaca of the hindgut by a column of mesoderm growing from the dorsal body wall called the *urorectal septum*. By the seventh week, the cloaca has been divided by the septum into an anterior (ventral) portion called the urogenital sinus and a posterior (dorsal) portion called the *anorectal canal*.

- The *anorectal canal* forms the hindgut distally to the pectinate line of the anal canal.
- The *urogenital sinus* is subdivided into:
  - The *cranial or vesical part*, which forms most of the *urinary bladder*. This part is connected to the *allantois*, which will later become a fibrous cord connected to the bladder called the *urachus*.
  - The middle or pelvic part, which forms all of the urethra in the female and most of the male urethra (prostatic and membranous parts).
  - The caudal or phallic part contributes to external genitalia of male and female.

Clinical Application

Urachal Anomalies

If the urachus does not close completely, remnants may dilate, fill with fluid, and give rise to a *urachal cyst*. Rarely, the complete urachus may stay completely open and form a *urachal fistula*, with urine leaking out at the umbilicus.

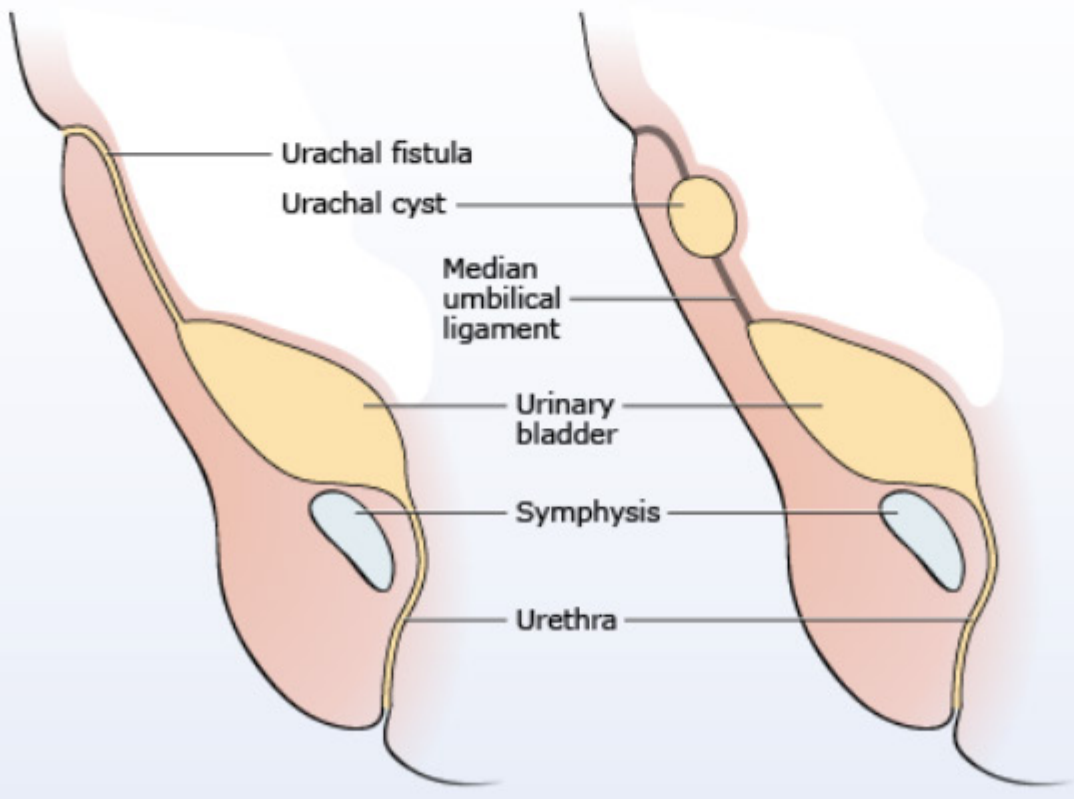

▲ **Figure 8–13.2B** Urachal Cyst

(continued on next page)

Please visit us at www.Groupinsiders.com

© DeVry/Becker Educational Development Corp. All rights reserved.

Clinical Application *(continued)*

Imperforate Anus

Imperforate anus occurs more commonly in males and results mainly from abnormal development of the urorectal septum and the anal membrane. There is incomplete separation of the urogenital sinus and the anus.

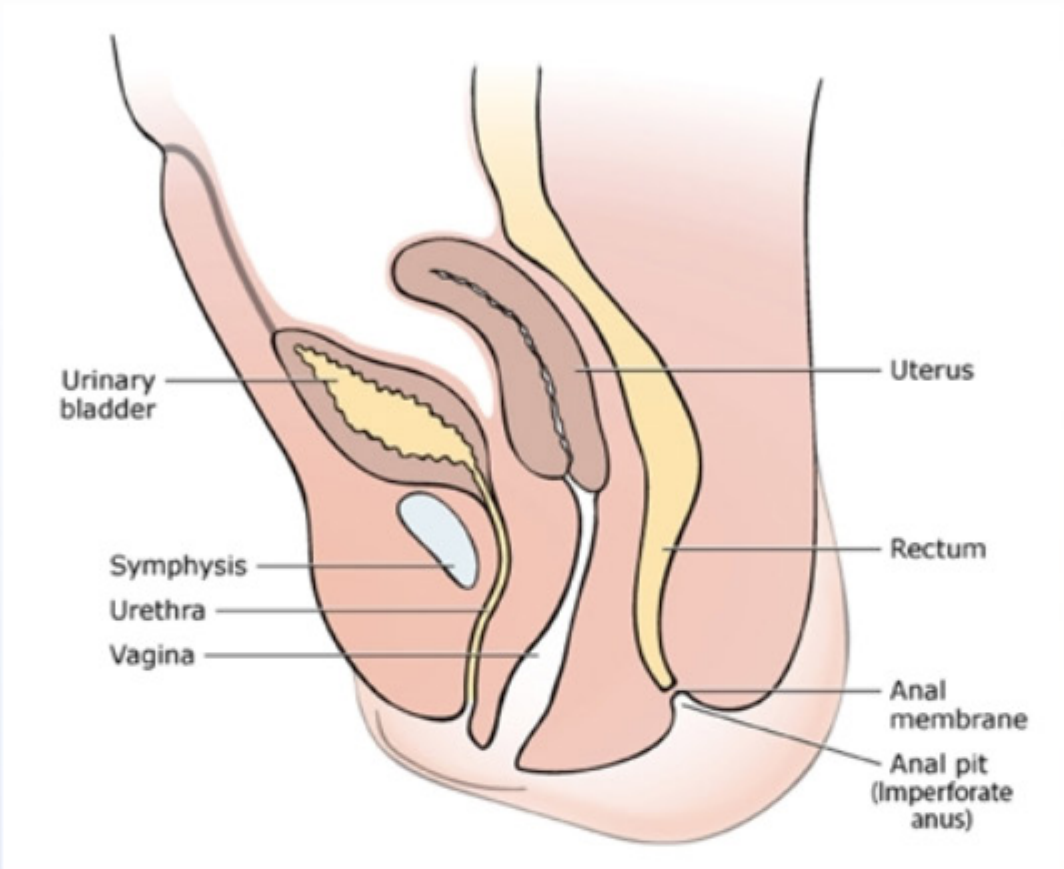

▲ **Figure 8–13.2C** Imperforate Anus

Please visit us at www.Groupinsiders.com

© DeVry/Becker Educational Development Corp. All rights reserved.

14 Posterior Abdominal Wall

14.1 Adult Kidneys and Ureters

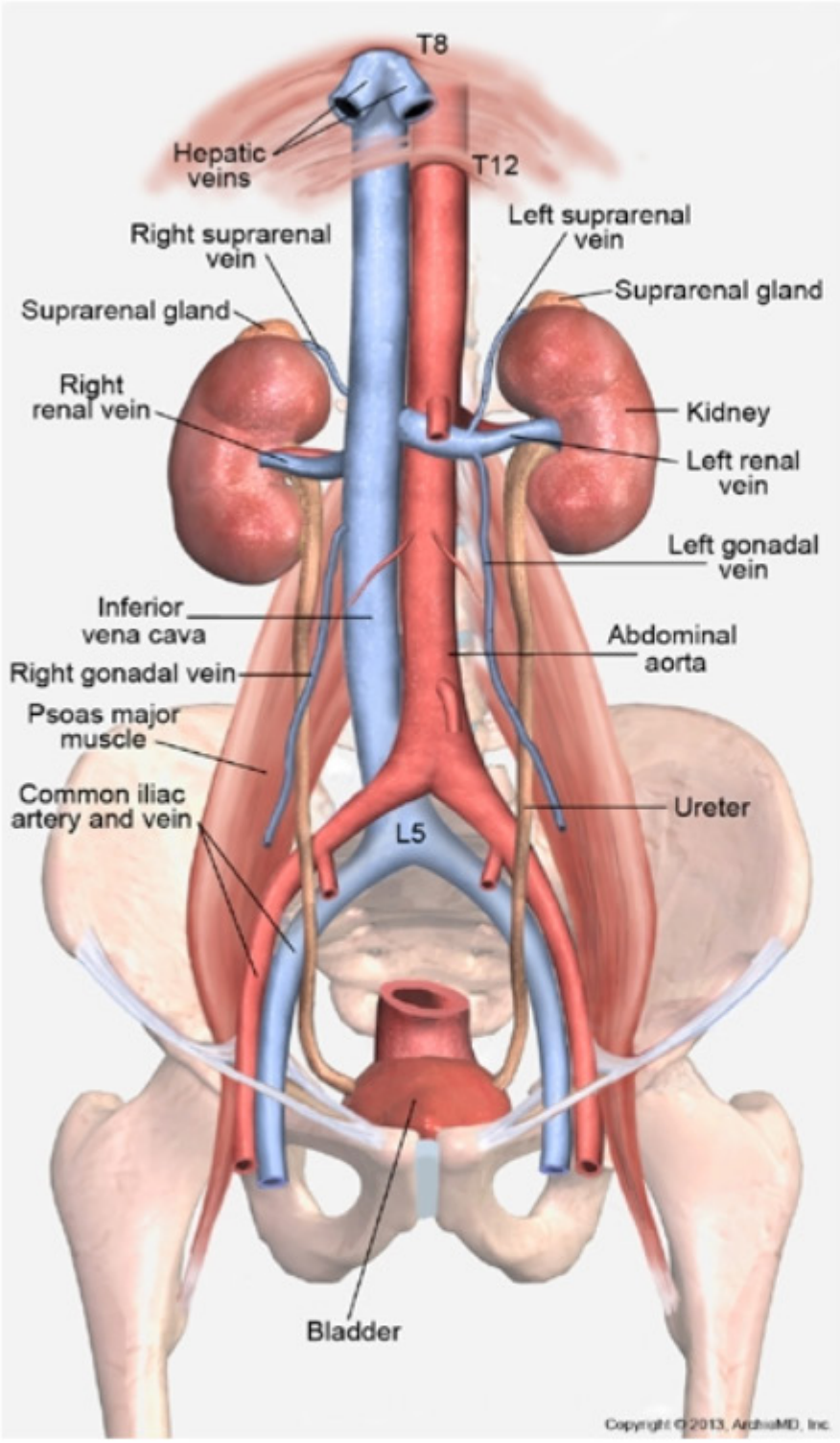

▲ **Figure 8–14.1** Kidneys and Ureter

The kidneys are retroperitoneal and are embedded in renal fascia and fat on the posterior abdominal wall. They usually extend between T12 and L3, with the right kidney being slightly lower.

- The hilum is on the medial aspect, and is where the ureters and renal vessels and nerves enter or leave the kidney at the L2 vertebral level.
- The kidneys are in contact with the *diaphragm*, *psoas major*, and *quadratus lumborum muscles*. The psoas major muscle is medial, and the quadratus lumborum muscle is posterior.

Please visit us at www.Groupinsiders.com

© DeVry/Becker Educational Development Corp. All rights reserved.

The *ureters* are retroperitoneal and descend on the ventral surface of the psoas major muscle on the posterior abdominal wall. They cross the pelvic brim at the bifurcation of the common iliac vessels and course on the lateral wall of the pelvic cavity to reach the urinary bladder.

Clinical Application

Renal Calculi

Renal calculi (kidney stones) are usually found at one of three locations:

1. Where the ureter leaves the kidney at the *renal pelvis*.
2. Where the ureter crosses the bifurcation of the common iliac artery at the *pelvic brim*.
3. Where the ureter penetrates the wall of the *urinary bladder*.

Clinical Application

Double Ureter

Double ureter occurs when there is a splitting of the ureteric bud or when two ureter buds are formed.

Please visit us at www.Groupinsiders.com

© DeVry/Becker Educational Development Corp. All rights reserved.

15 Radiology Images

ISM/Phototake, Inc.

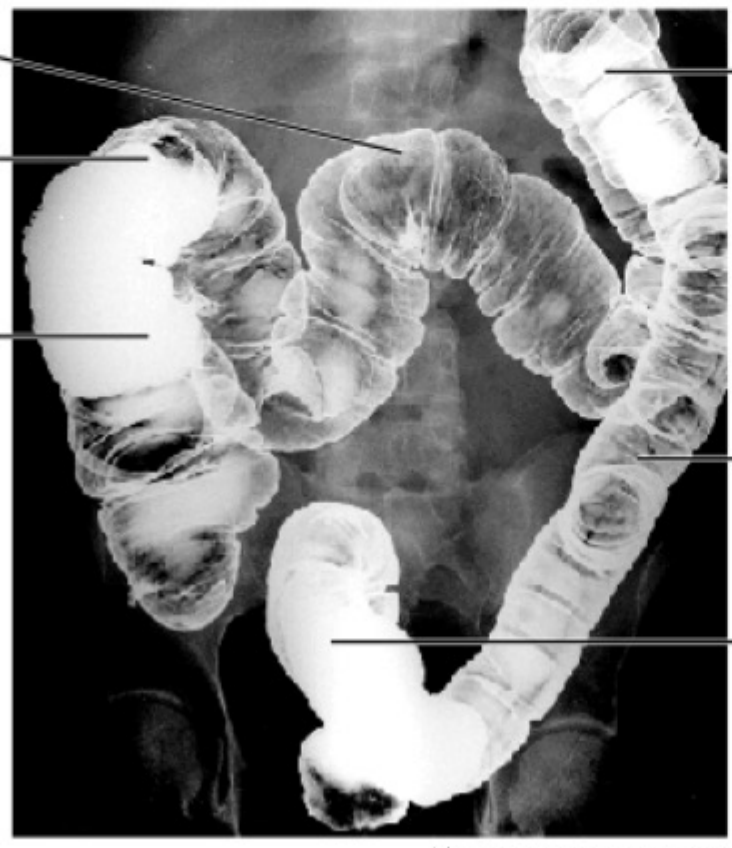

Medical Body Scans/Science Source

▲ **Figure 8–15.0A** Upper and Lower GI

Please visit us at www.Groupinsiders.com

© DeVry/Becker Educational Development Corp. All rights reserved.

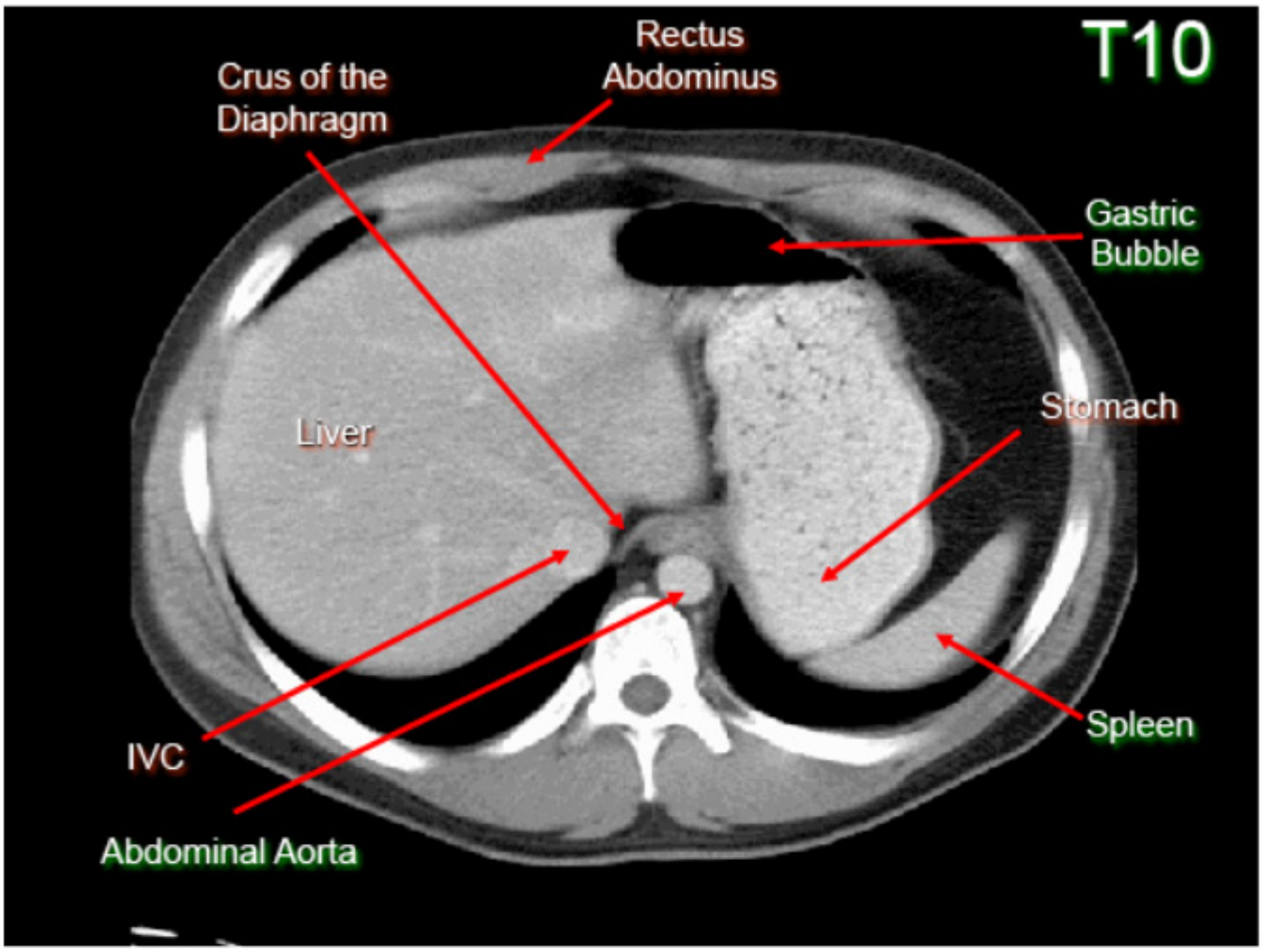

▲ **Figure 8–15.0B** Abdomen CT

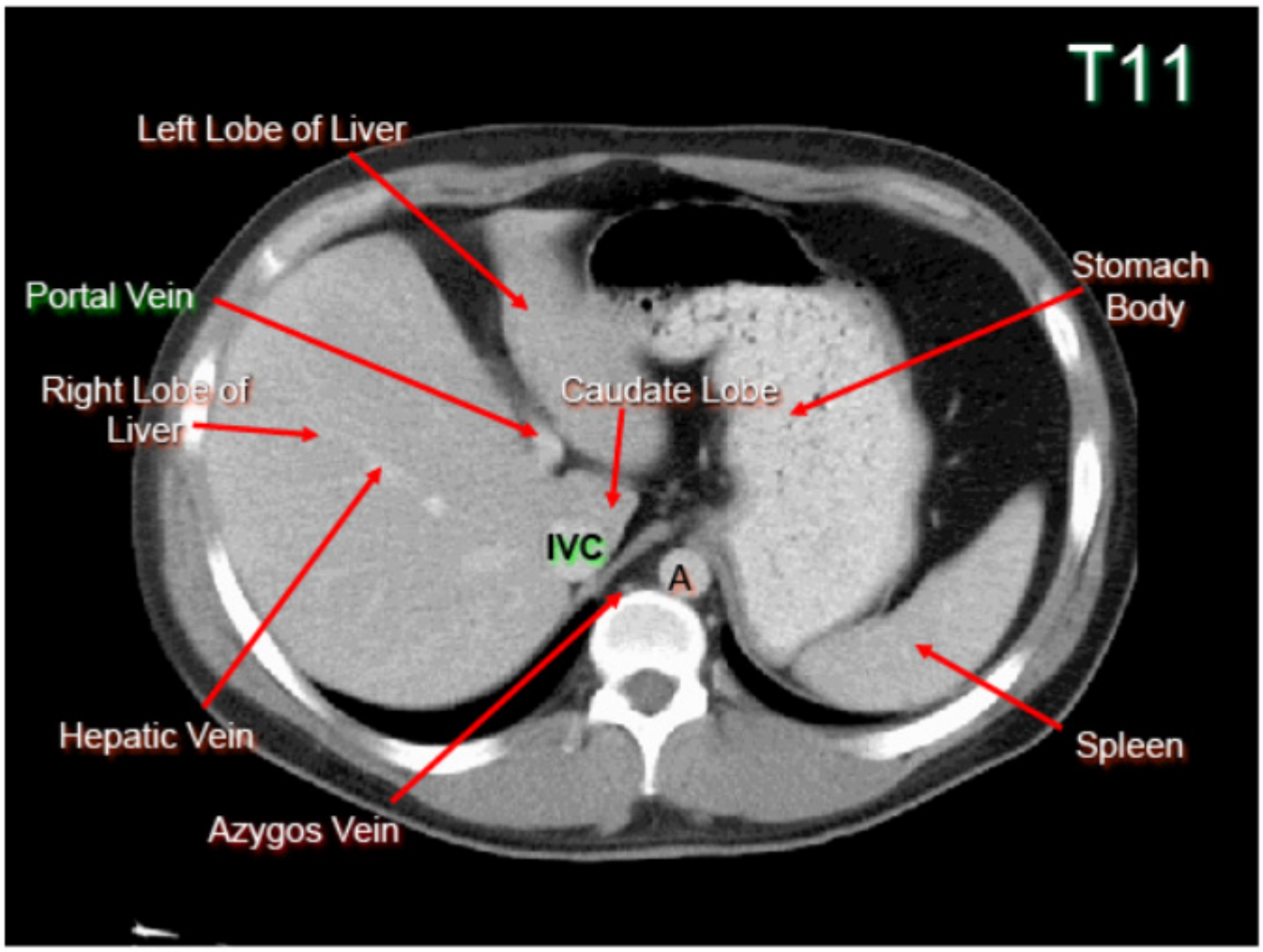

▲ **Figure 8–15.0C** Abdomen CT

Please visit us at www.Groupinsiders.com

© DeVry/Becker Educational Development Corp. All rights reserved.

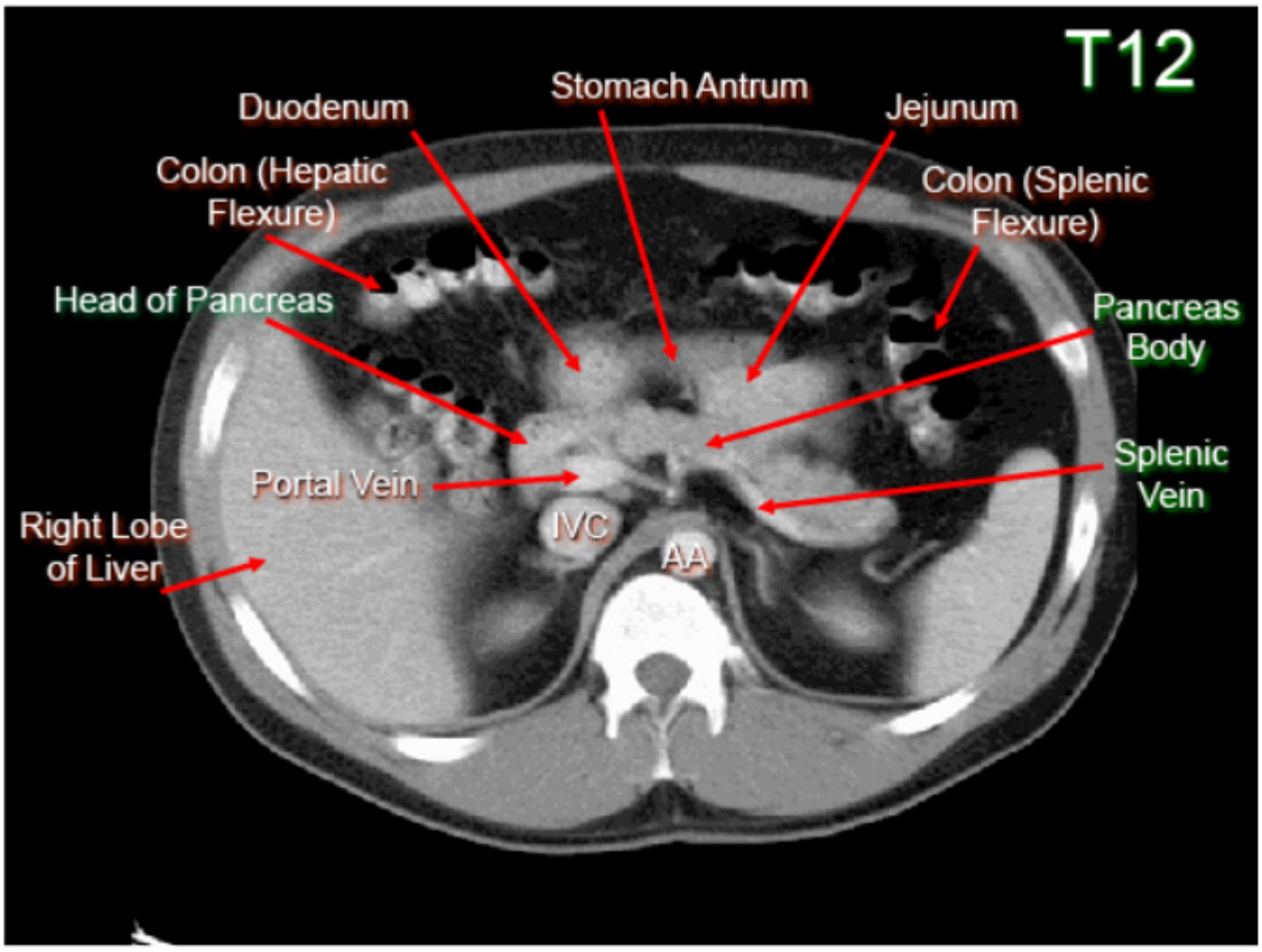

▲ **Figure 8–15.0D** Abdomen CT

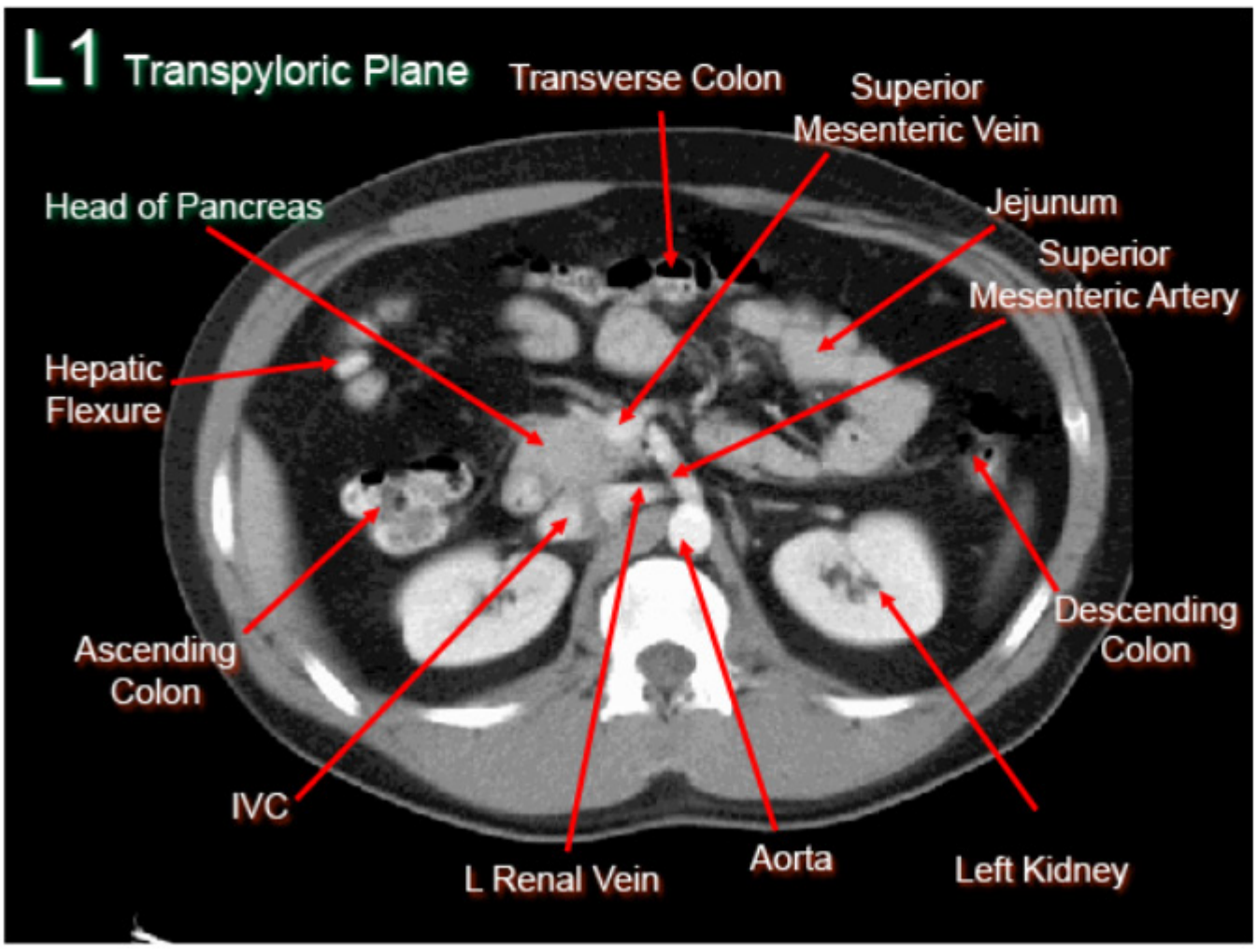

▲ **Figure 8–15.0E** Abdomen CT

Please visit us at www.Groupinsiders.com

© DeVry/Becker Educational Development Corp. All rights reserved.

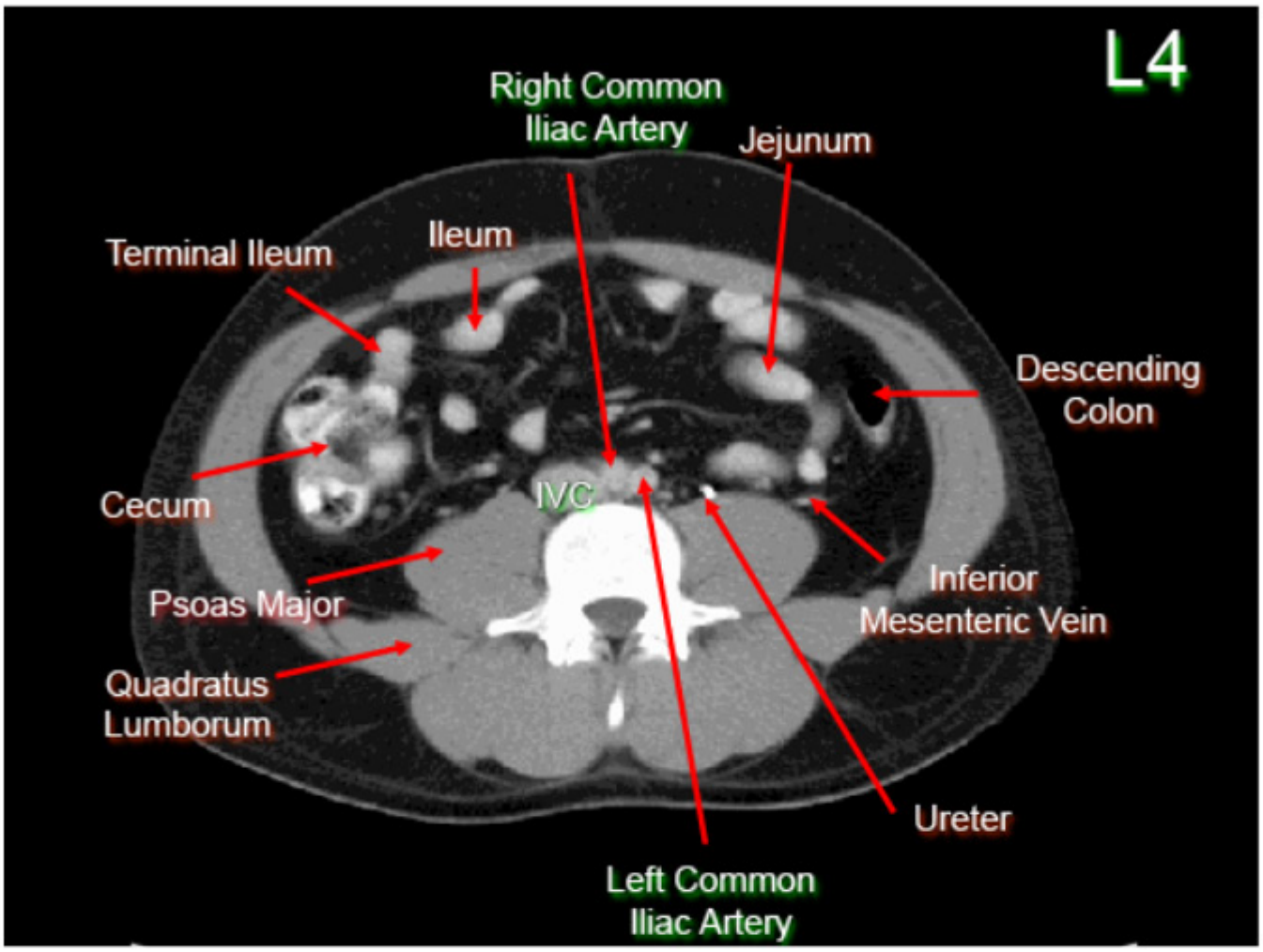

▲ **Figure 8–15.0F** Abdomen CT

Please visit us at www.Groupinsiders.com

© DeVry/Becker Educational Development Corp. All rights reserved.

1 Muscular Diaphragms of the Pelvis and Perineum

There are two important skeletal muscle diaphragms associated with the pelvis and perineum: the *pelvic diaphragm* and the *urogenital diaphragm*. Both of these diaphragms provide important support mechanisms for the pelvis and perineum, and are innervated by the pudendal nerve and branches of the sacral plexus.

1.1 Pelvic Diaphragm

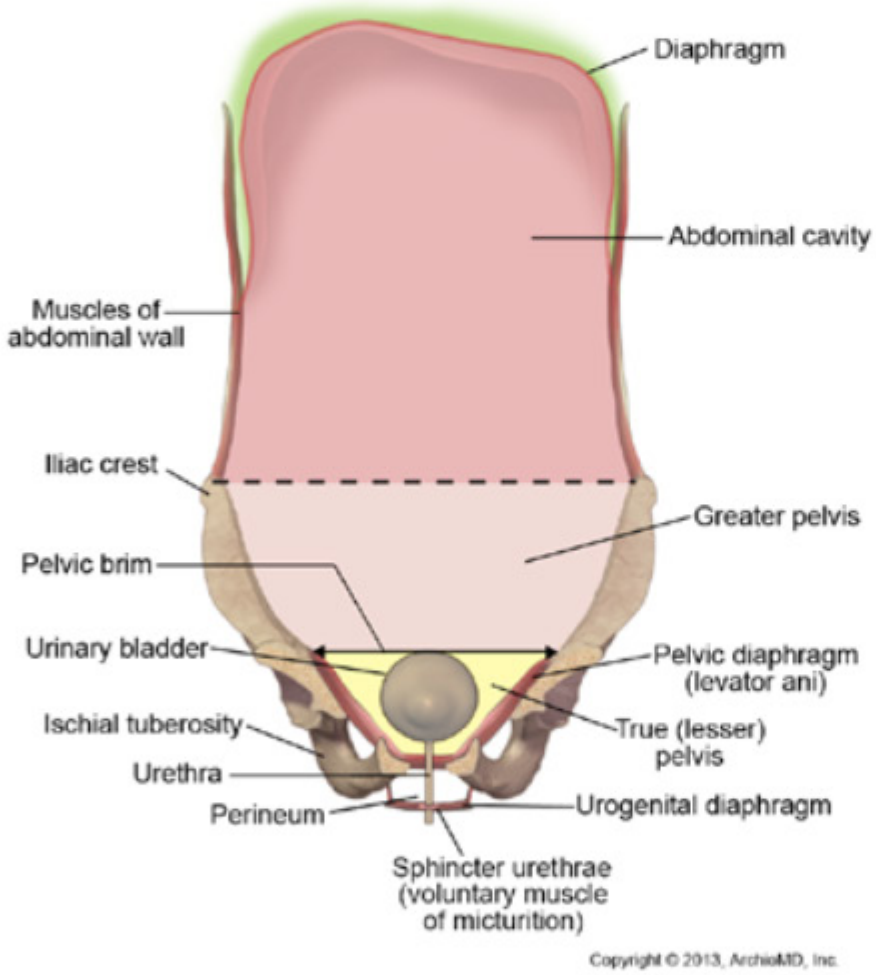

▲ **Figure 9–1.1A** Pelvic and Urogenital Diaphragms

The *pelvic diaphragm* (PD) is a funnel-shaped skeletal muscle that forms *the floor of the pelvis* and is a very important support mechanism for all of the pelvic viscera, especially in the female.

- The perineum is inferior to the pelvic diaphragm, and the pelvic cavity is superior to the pelvic diaphragm.
- The PD has apertures for passage between the pelvis and the perineum for parts of the GI tract (anorectal junction) posteriorly and parts of the genitourinary system (urethrae and vagina) anteriorly.

USMLE® Key Concepts

For Step 1, you must be able to:

- Identify the structure and function of the two muscular diaphragms of the pelvis and perineum.
- Describe the source of innervation and blood supply to the perineum.
- Differentiate male and female pelvic viscera as seen on a midsagittal section.
- Explain the routes of extravasation of urine from the urethra following trauma to the male perineum.

Important Concept

The puborectalis part of the pelvic diaphragm is responsible for rectal continence and the sphincter urethrae part of the urogenital diaphragm is responsible for urinary continence.

Please visit us at www.Groupinsiders.com

© DeVry/Becker Educational Development Corp. All rights reserved.

- The PD receives somatic innervation from the *pudendal nerve* (S2, S3, S4).
- The diaphragm is formed by two muscles: *coccygeus* and *levator ani*. The levator ani forms the majority of the diaphragm.
  - The *puborectalis* part of the levator ani is particularly significant. It forms a muscular sling around the junction of the rectum and anal canal at the pelvic diaphragm that prevents leakage of rectal contents and is important for *rectal continence*. Voluntary relaxation of this muscle allows emptying of the rectum.

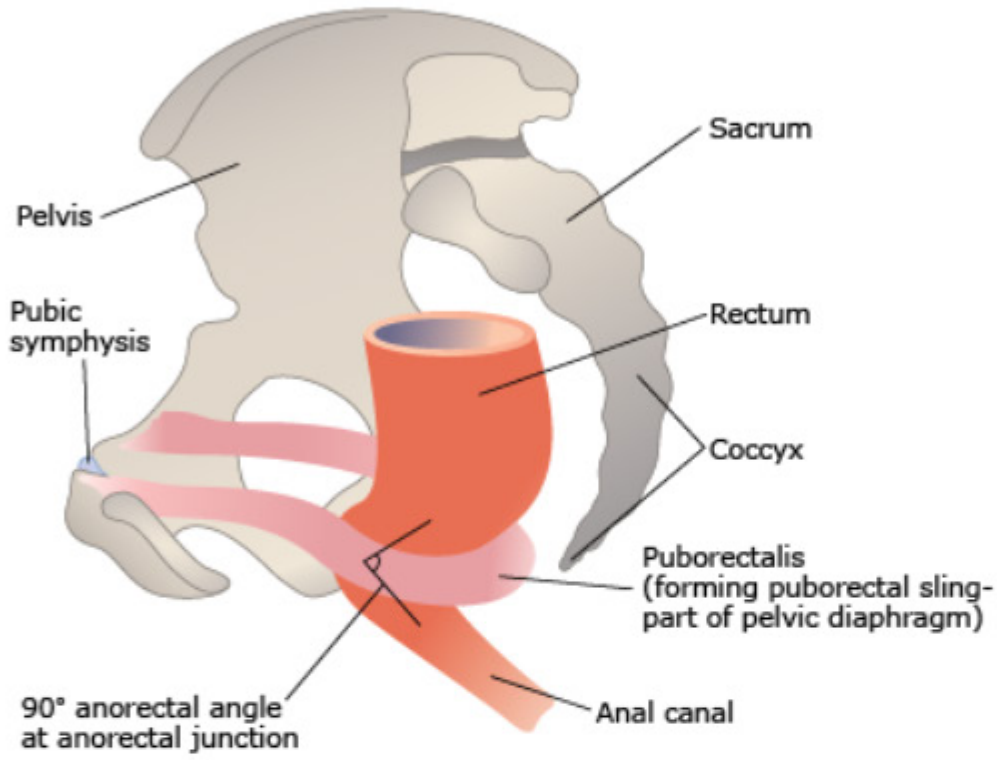

▲ **Figure 9–1.1B** Puborectalis Muscle

Please visit us at www.Groupinsiders.com

© DeVry/Becker Educational Development Corp. All rights reserved.

1.2 Urogenital Diaphragm

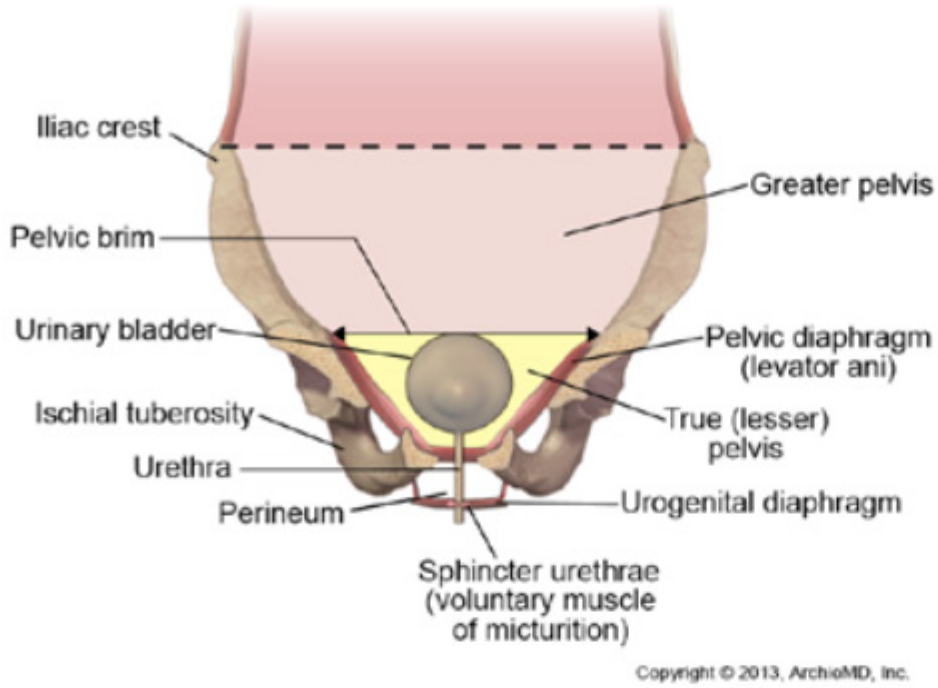

▲ **Figure 9–1.2** Urogenital Diaphragm

The *urogenital diaphragm* (UG) is also skeletal muscle that forms a horizontal muscular diaphragm stretched between the two ischiopubic rami, creating the deep perineal pouch of the perineum. It forms a muscular platform to which the external genitalia are attached and suspended from its inferior surface.

- Forms the deep perineal space of the perineum.
- The UG diaphragm provides passage of the urethra in males and females and the vagina in the female.
- The UG diaphragm is innervated by the *pudendal nerve*.
- The diaphragm is formed by two muscles: the deep transverse perineus muscle and the *sphincter urethrae muscle*.
  - The *sphincter urethrae* (external urethral sphincter) forms a *voluntary muscle of micturition* surrounding the urethra that prevents leakage of urine and is important in *urinary continence.* The sphincter urethrae muscle is innervated by the pudendal nerve.

Important Concept

The support of pelvic viscera is provided by the urogenital and pelvic diaphragms, transverse cervical and uterosacral ligaments, and the perineal body.

Please visit us at www.Groupinsiders.com

© DeVry/Becker Educational Development Corp. All rights reserved.

1.3 Male and Female Pelvic Cavities

The pelvic basin or cavity is surrounded by a ring of bone formed by the *hip bone* and the *sacrum*. The hip bone consists of three fused bones: ilium, ischium, and pubis.

The *true pelvic cavity* is located below the terminal line (pelvic brim) and houses most of the viscera of the male and female genital tract, bladder, and rectum. The perineum is located below the pelvic floor and houses the external genitalia and anal canal.

The major structures and their relationships of the male and female pelvic cavities are shown in Figures 9–1.3A and 9–1.3B.

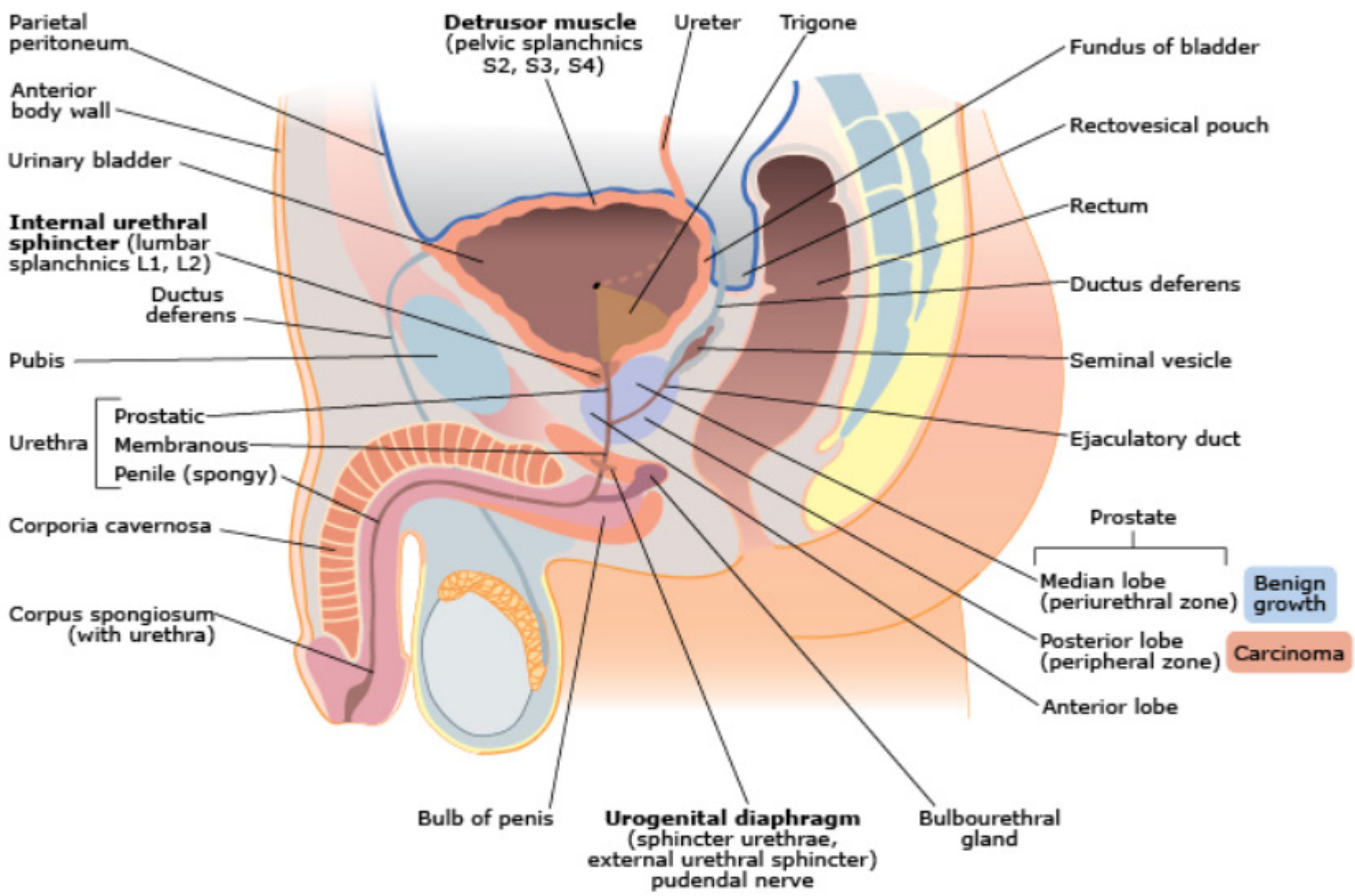

▲ **Figure 9–1.3A** Male Pelvis

Please visit us at www.Groupinsiders.com

© DeVry/Becker Educational Development Corp. All rights reserved.

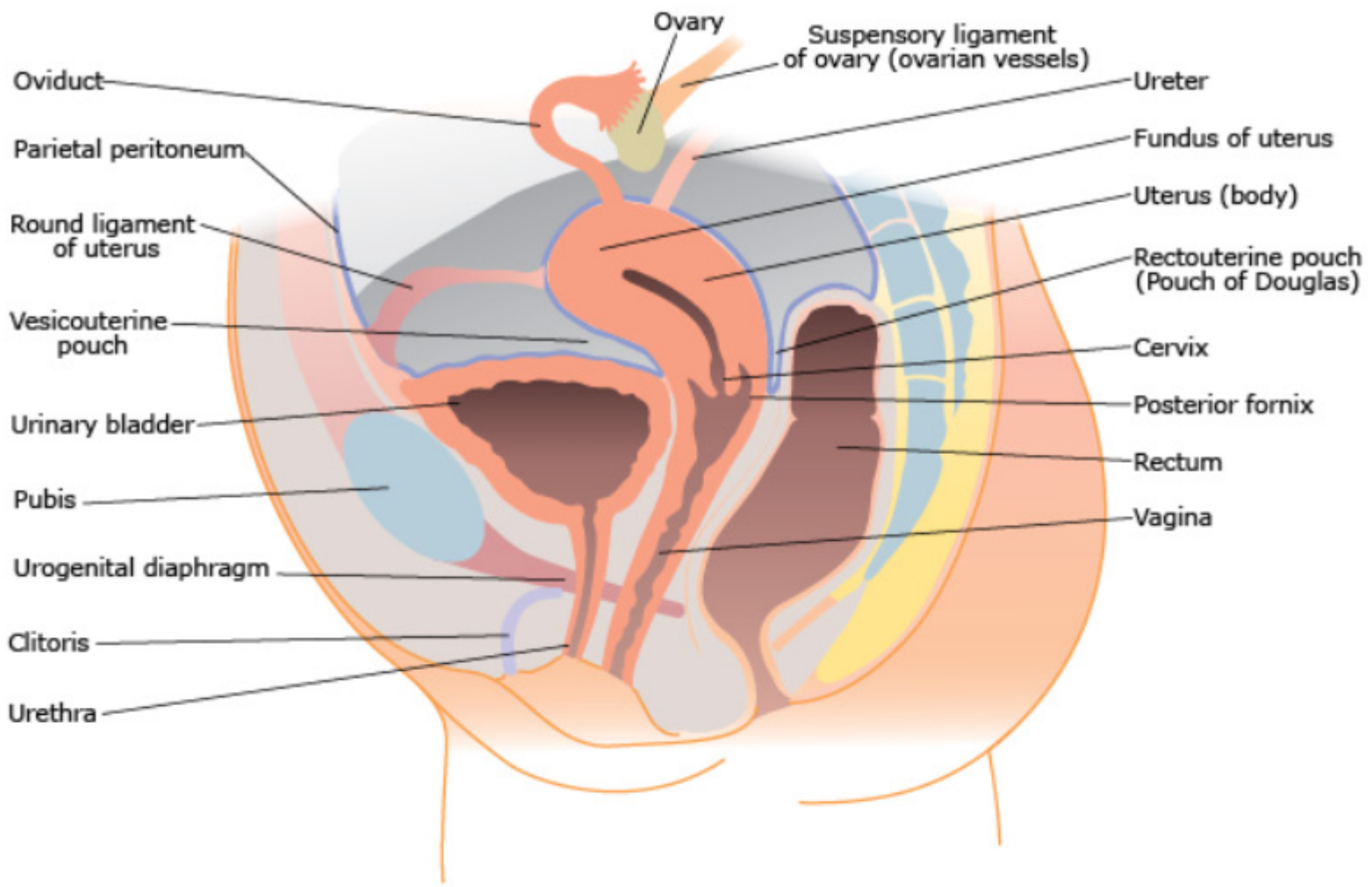

▲ **Figure 9–1.3B** Female Pelvis

Important Concept

The ureter passes inferior to the uterine artery in the floor of the pelvis and medial to the suspensory ligament of the ovary at the pelvic brim. At both locations, the ureter has to be protected during surgical procedures.

Please visit us at www.Groupinsiders.com

© DeVry/Becker Educational Development Corp. All rights reserved.

2 Perineum

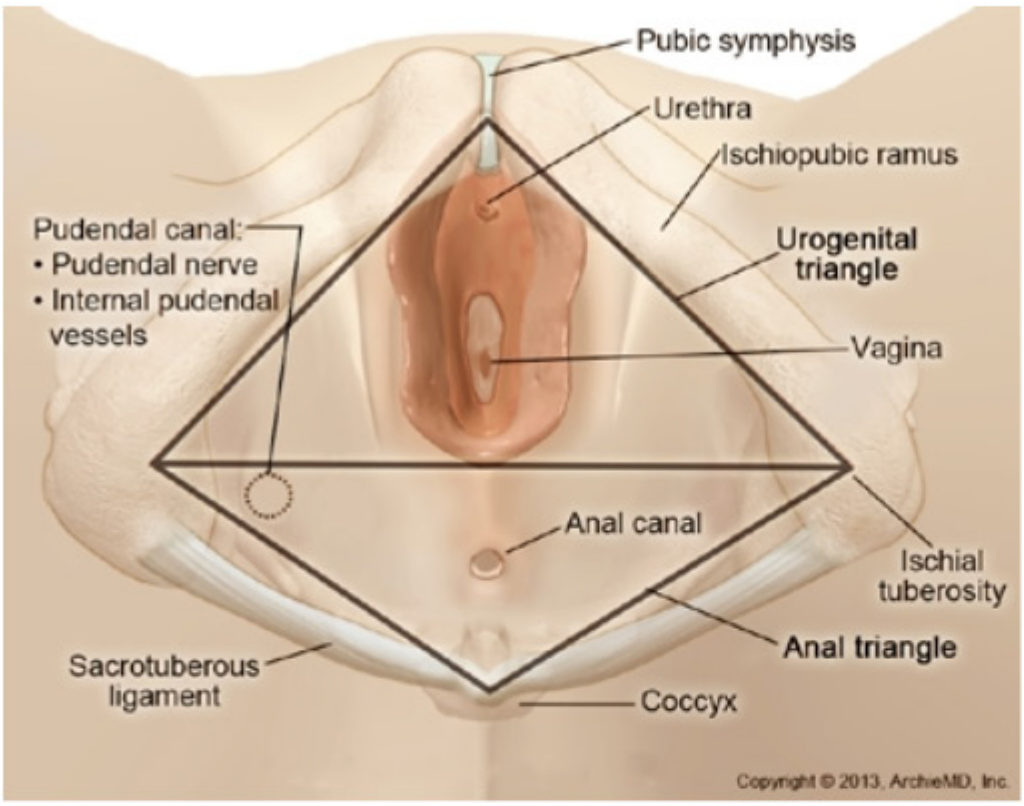

▲ **Figure 9–2.0A** Boundaries of the Perineum

The *perineum* is the outlet of the pelvis located inferior to the pelvic diaphragm and between the two thighs. It contains structures related to the external genitalia anteriorly and the lower half of the anal canal and anus posteriorly. Anteriorly, it serves as a passage of the urethra and parts of the male and female genital tracts; posteriorly, it is the anal canal.

- The perineum is divided into two triangles by an imaginary line drawn between the tibial tuberosities: *anal* and *urogenital triangles*.
- The *pudendal nerve (S2, S3, and S4)* contributes to the motor innervation to all skeletal muscles of the perineum and to the sensory innervation from most of the perineum.
- The *internal pudendal artery* provides the blood supply to the tissues of the perineum, including erectile tissue.
- These nerves and vessels cross *dorsal to the ischial spine* (site of pudendal block) and through the lesser sciatic foramen to enter the perineum.

Please visit us at www.Groupinsiders.com

© DeVry/Becker Educational Development Corp. All rights reserved.

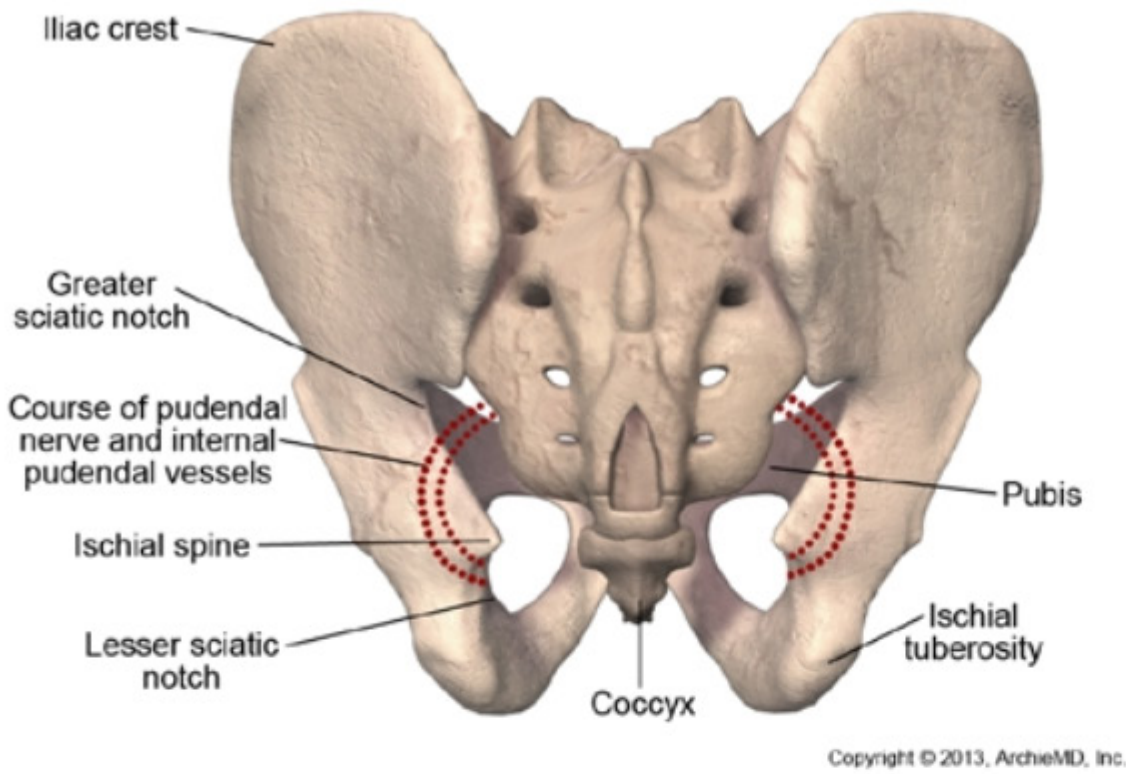

▲ **Figure 9–2.0B** Course of Pudendal Nerve and Vessels

- *Lymphatic drainage* from the perineum is mainly to the superficial inguinal nodes except for the testes, which drain through the spermatic cord up to the aortic (lumbar) nodes of the posterior abdominal wall.

2.1 Anal Triangle

- The distal half of the anal canal inferior to the pectinate line to the anal opening is part of the perineum.
- Surrounding the anal canal is a fat-filled area called the *ischioanal fossa*. In the lateral wall of the fossa is the *pudendal canal* that transmits the pudendal nerve and internal pudendal vessels into the perineum.
- Autonomic innervation is provided by the *parasympathetic pelvic splanchnic nerves (S2, S3, and S4)* and the *sympathetic lumbar splanchnic nerves (L1–L2)*.

Please visit us at www.Groupinsiders.com

© DeVry/Becker Educational Development Corp. All rights reserved.

2.2 Urogenital Triangle

Female

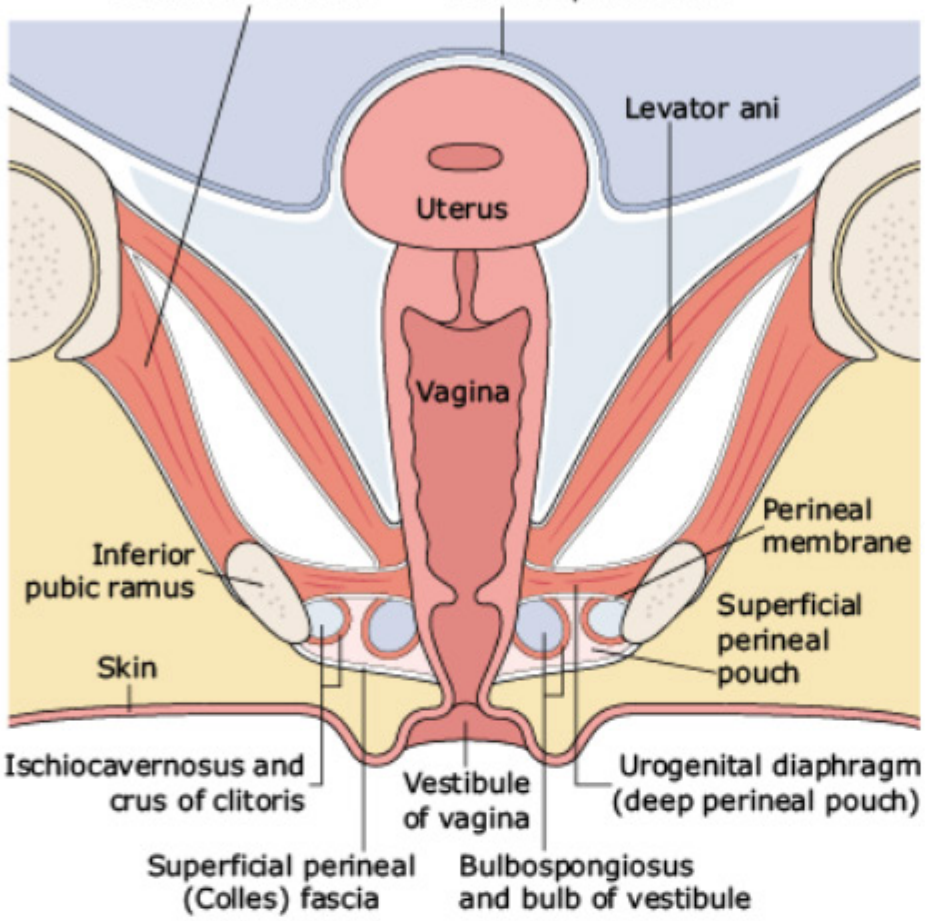

Male

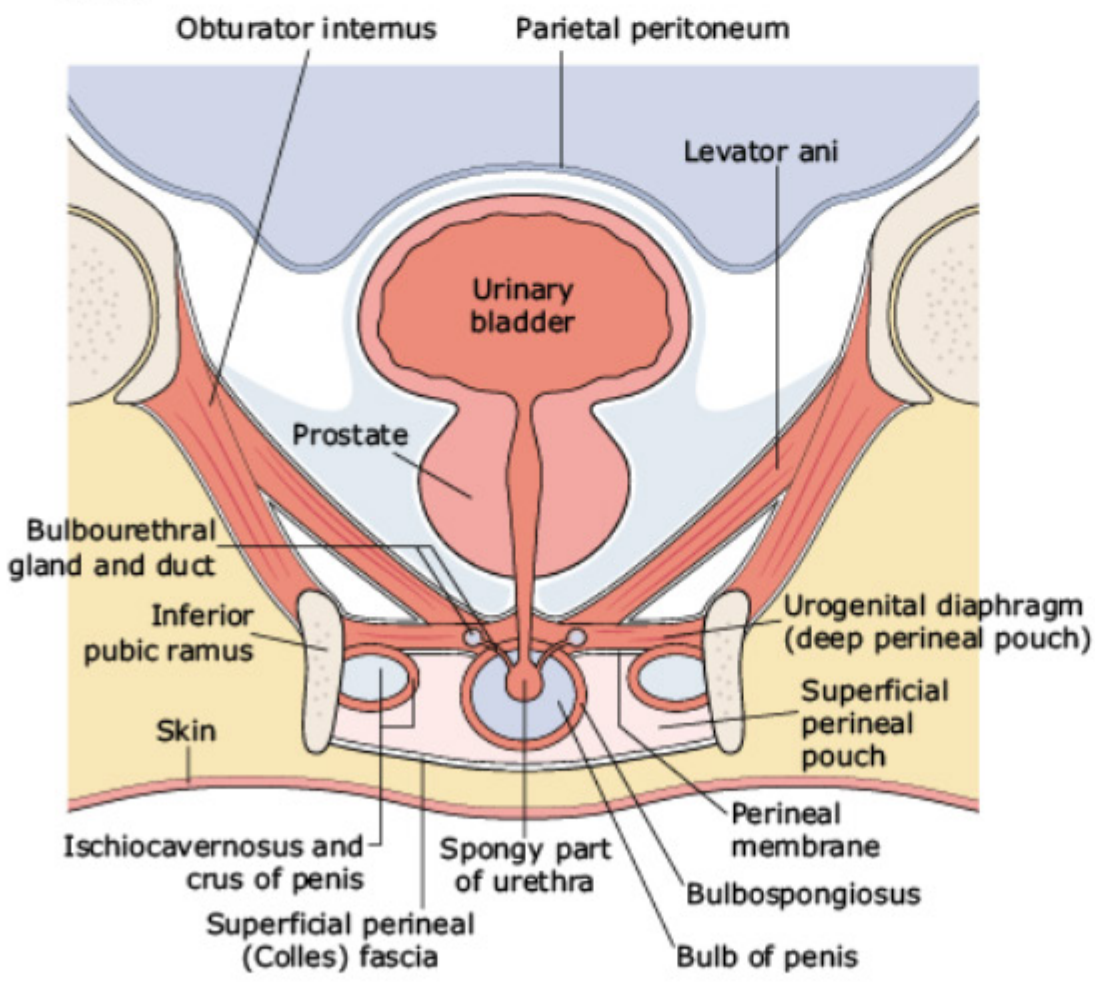

▲ **Figure 9–2.2A** Spaces and Structures of the Perineum

Please visit us at www.Groupinsiders.com

© DeVry/Becker Educational Development Corp. All rights reserved.

- The *urogenital triangle* is the anterior part of the perineum that houses external genitalia and associated muscles and vessels.
- The triangle is divided into two spaces, or pouches:
  1. The *superficial perineal pouch* is located between two fascial layers (Colles fascia and superficial perineal fascia) and houses structures related to the external genitalia:
     - Crura of clitoris and penis
     - Root structures of the genitalia: Corpora cavernosa, corpora spongiosum (male only); bulb of penis; bulb of vestibule (female)
     - Skeletal muscles: Bulbospongiosus and ischiocavernosus muscles help maintain erection in male and female. Bulbospongiosus muscle also helps to empty the urethra in the male during micturition and ejaculation
     - Greater vestibular (Bartholin) gland in the female
  2. The *deep perineal pouch* is formed by the urogenital diaphragm and its fascia:
     - Sphincter urethrae muscle (voluntary muscle of micturition)
     - Deep transverse perineus muscle
     - Bulbourethral gland (Cowper gland) in the male

Note: A summary of congenital anomalies of the reproductive system is in Table 9–2.2:

Clinical Application

Extravasation of Urine

The common site for rupture of the urethra in the male, accompanied with extravasation of urine, is at the bulb of the penis. This injury usually follows from severe trauma to the perineum that ruptures the bulb of the penis and the urethra. Urine leaks out into the superficial perineal space and can pass into the subcutaneous tissue of the scrotum, penis, and superiorly deep to the anterior body wall. Because of attachment of Colles fascia to the inguinal ligament, urine does not pass into the thigh.

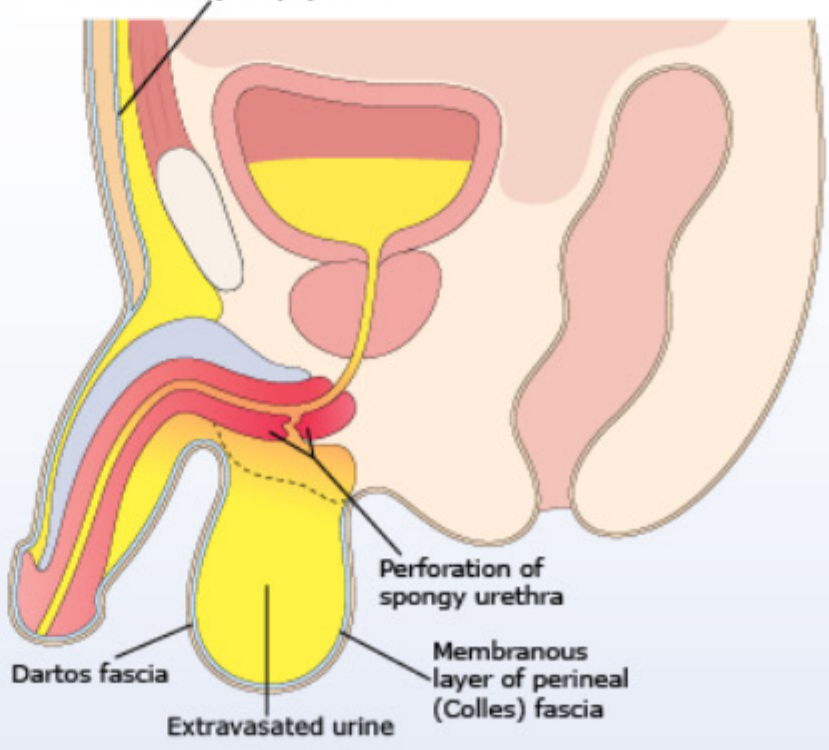

▲ **Figure 9–2.2B** Extravasation of Urine

Please visit us at www.Groupinsiders.com

© DeVry/Becker Educational Development Corp. All rights reserved.

▼Table 9–2.2 Congenital Malformations of Pelvis and Perineum

Malformation	Clinical Features
Hypospadias	• Urethra opens on the *ventral* side of the penis • Spongy urethra does not form properly or the *urogenital folds* do not fuse • Paucity of hormone receptors or too little hormone produced from the testes may play a role • More common than epispadias
Epispadias	• Urethra opens on the *dorsum* of the penis • Associated with exstrophy of the bladder
Undescended testis (cryptorchidism)	• Most are of unknown cause • May be unilateral or bilateral • Most testes descend before one year of life • If testes remain undescended, *sterility or testicular cancer* can result
Congenital inguinal hernia (indirect hernia)	• A communication is formed between the *tunica vaginalis* (adjacent to the testis) and the peritoneal cavity • A loop of intestine may herniate into the opening and become entrapped, resulting in obstruction • May be associated with undescended testis
Double uterus	• The cause is failure of the *paramesonephric ducts* to fuse • The condition may appear in two forms: Uterus divided internally by a thin septum or a division of only the superior part of the uterus (bicornuate uterus)
Double ureter	• Splitting of ureteric bud or two ureteric buds

Please visit us at www.Groupinsiders.com

© DeVry/Becker Educational Development Corp. All rights reserved.

Chapters 8–9 Review Questions

1. During a prenatal checkup of an eight-months-pregnant woman, the physician notes that AFP levels are elevated. An ultrasound is ordered and shows that the small intestines of the fetus are herniated into the amniotic cavity and bathed by amniotic fluid. This condition is due to a congenital defect of which of the following?

   A. Midgut herniation
   B. Septation of hindgut
   C. Lateral body folds
   D. Amnion
   E. Migration of neural crest cells

2. During the physical examination of a hernia in a 40-year-old male, the physician notices that the herniation is located above the inguinal ligament and medial to the inferior epigastric artery. What type of hernia is identified by the physician?

   A. Umbilical
   B. Direct
   C. Femoral
   D. Indirect
   E. Anterior body wall

3. During development of the GI tract, the ventral embryonic mesentery fails to develop properly. Which of the following abdominal ligaments would be expected to be affected?

   A. Hepatoduodenal
   B. Gastrosplenic
   C. Splenorenal
   D. Greater omentum
   E. Sigmoid mesocolon

Please visit us at www.Groupinsiders.com

© DeVry/Becker Educational Development Corp. All rights reserved.

Review Questions Chapters 8–9

4. A 55-year-old man who has alcoholic cirrhosis is brought to the emergency department because he has been vomiting blood for two hours. He has a two-month history of abdominal distention, dilated veins over the anterior abdominal wall, and internal hemorrhoids. Which one of the following veins of the hepatic portal venous system is directly connected to the branches that are likely to be feeding blood to the area of the hematemesis?

A. Inferior rectal vein
B. Left gastric vein
C. Paraumbilical veins
D. Superior rectal vein
E. Hepatic vein

5. In a patient with generalized atherosclerosis, an acute blockage occurs at the origin of the superior mesenteric artery. Which of the following abdominal structures would lose most of its blood supply?

A. Duodenum
B. Spleen
C. Pancreas
D. Ileum
E. Descending colon

6. A 6-year-old boy presents with a large intra-abdominal mass in the midline just superior to the symphysis pubis. During surgery, a fluid-filled mass is found attached between the umbilicus and the apex of the bladder. Which of the following is the most likely diagnosis?

A. Urachal cyst
B. Omphalocele
C. Gastroschisis
D. Meckel fistula
E. Hydrocele

Please visit us at www.Groupinsiders.com

© DeVry/Becker Educational Development Corp. All rights reserved.

Chapters 8–9 Review Questions

7. A 68-year-old man complains of severe, painful urination. A CT scan and biopsy reveals an enlarged and cancerous prostate gland. Subsequently, he undergoes radiation therapy and a prostatectomy. Postoperatively, he suffers from urinary incontinence due to paralysis of the external urethral sphincter. Which nerve must have been injured during the operation?

A. Pelvic splanchnics
B. Lumbar splanchnics
C. Pudendal
D. Superior gluteal
E. Lumbar part of the sympathetic chain

8. A 65-year-old male with a history of heavy smoking and hypercholesterolemia is diagnosed with severe, systemic atherosclerosis affecting many of the arteries of his body. While his history is being taken, he complains of impotence. Occlusion of which of the following arteries may have resulted in his condition?

A. External iliac
B. Inferior epigastric
C. Femoral
D. Internal pudendal
E. Obturator

Please visit us at www.Groupinsiders.com

© DeVry/Becker Educational Development Corp. All rights reserved.

Review Answers Chapters 8–9

1. The correct answer is C. The anterior body wall defect described is gastroschisis, which results from an incomplete closure of the anterior body wall folds, more commonly on the right side. The herniated gut occurs to the side of the umbilical ring and is not enclosed in a covering of amnion.

2. The correct answer is B. An inguinal hernia that is located medial to the inferior epigastric artery and superior to the inguinal ligament is a direct inguinal hernia. The gut herniates through the weak area of the posterior wall of the inguinal canal and does not pass through the deep inguinal ring.

3. The correct answer is A. The liver develops from endoderm within the ventral embryonic mesentery. The two ligaments that attach to the liver, the falciform ligament and the lesser omentum (formed by the hepatogastric and hepatoduodenal ligaments), develop from the ventral embryonic mesentery.

4. The correct answer is B. With the development of hepatic disease that blocks the flow of hepatic portal venous blood through the liver, several sites of portal-caval anastomosis develop to reroute blood flow to the heart. The esophageal bleeding in this individual is due to anastomosis between the left gastric vein (portal system) and the azygos vein (caval system).

5. The correct answer is D. The superior mesenteric artery is the sole supply of the ileum. The other parts of the GI tract listed are not directly or indirectly supplied by the superior mesenteric artery.

6. The correct answer is A. The patient presents with a patent urachus. This congenital defect results from failure of the allantois to close completely. Fluid-filled cysts can form anywhere along the course of the urachus between the bladder and the umbilicus.

7. The correct answer is C. During surgery for prostate carcinoma, the pudendal nerve was accidently damaged. The pudendal nerve innervates the five skeletal muscles within the perineum including the urogenital diaphragm, which contains the voluntary muscle of micturition, the external urethral sphincter.

8. The correct answer is D. The blood supply to the perineum including the blood flow to erectile tissue is provided by the internal pudendal artery, a branch of the internal iliac artery.

Please visit us at www.Groupinsiders.com

© DeVry/Becker Educational Development Corp. All rights reserved.

1 Overview

The upper limb provides a wide range of movement, especially for placement of the hand. The shoulder (pectoral) girdle (scapula and clavicle) contributes to a significant range of movement of the upper limb. The clavicle connects the shoulder girdle to the sternum and serves as a strut to hold the upper limb away from the trunk.

2 Development of Limbs

Following gastrulation, mesoderm differentiates into three regions: (a) a medial paraxial mesoderm on either side of the midline adjacent to the developing neural tube; (b) a central intermediate mesoderm; and (c) the lateral mesoderm.

By the end of the third week, the *paraxial mesoderm* becomes organized and begins to form a series of blocks of mesoderm called *somites*. Somites develop in a craniocaudal sequence and eventually form about 35 somites. The first pair of somites forms on about Day 20.

The somites differentiate into the following parts:

- *Sclerotome*: Forms bones and cartilage of the vertebral column.
- *Dermatome*: Forms dermis and subcutaneous tissues of the skin.
- *Myotome*: Contributes to muscles of trunk and limbs. The mesoderm of the ventral aspect of the myotome migrates into the limb buds and condenses to form the musculature of the limbs.

USMLE® Key Concepts

For Step 1, you must be able to:

- Describe the formation of the brachial plexus and the major nerves derived from the plexus.
- Explain the spinal cord segmentation of the major nerves and how the segmentation relates to the innervation pattern of the upper limb.
- Describe the muscular compartments, blood supply, and neurovascular relationships of the upper limb.
- Identify the nerves providing sensory innervation to the hand and forearm.
- Describe the major nerve lesions of the upper limb and how they relate to motor and sensory deficits of the limb.

Please visit us at www.Groupinsiders.com

© DeVry/Becker Educational Development Corp. All rights reserved.

3 Brachial Plexus

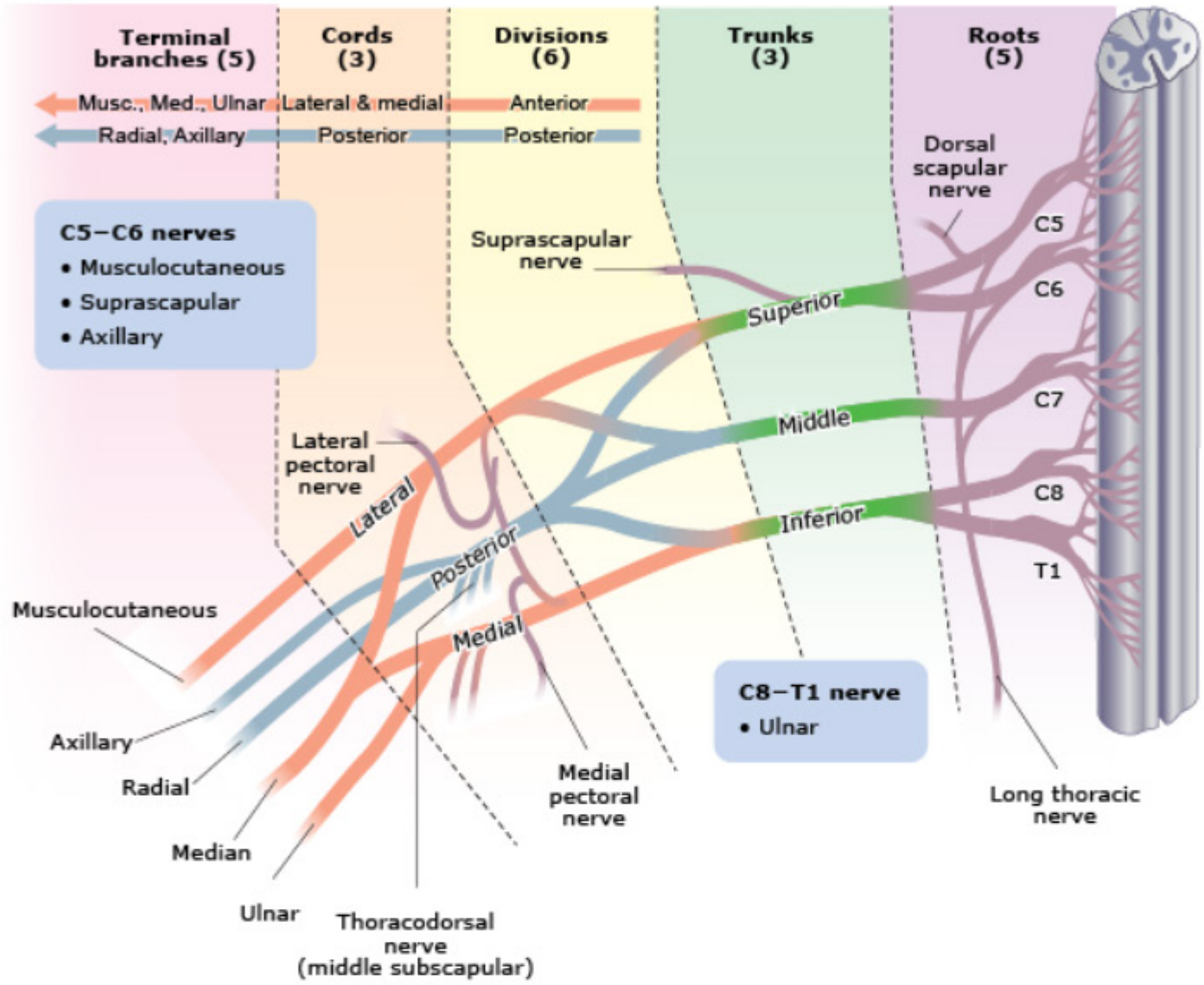

▲ **Figure 10–3.0** Brachial Plexus

The *brachial plexus* is the extensive network of nerves that provides the motor and sensory functions for the upper limb. The plexus is formed by the nerve fibers of the *anterior (ventral) rami of C5–T1 spinal nerves*.

The formation of the plexus begins in the posterior triangle of the neck and descends through the axilla and distributes throughout the limb. The proximal-to-distal plan of the brachial plexus consists of five successive stages: *root, trunks, divisions, cords, and terminal branches*. The plexus is divided into a supraclavicular part located above the clavicle in the neck (roots and trunks) and an infraclavicular part located below the clavicle in the axilla (cords and their branches).

The primary nerve branches of the brachial plexus and their segmentation are the:

- Musculocutaneous: C5, C6, (C7)
- Median: (C5), C6–T1
- Ulnar: C8, T1
- Radial: C5–8, (T1)
- Axillary: C5, C6
- Long thoracic: C5, C6, C7
- Suprascapular: C5, C6
- Thoracodorsal: C7, C8

Important Concept

Anterior division fibers of the brachial plexus supply anterior compartment muscles, and posterior division fibers supply posterior compartment muscles of the upper limb.

Please visit us at www.Groupinsiders.com

© DeVry/Becker Educational Development Corp. All rights reserved.

The motor distributions of the major branches of the brachial plexus are shown in Tables 10–3.0A and 10–3.0B.

▼ Table 10–3.0A Major Motor Innervations by the Five Terminal Nerves

Terminal Nerve	Muscles Innervated	Primary Actions
Musculocutaneous nerve C5–C6	**Anterior compartment muscles** of the arm	Flex elbow Supination (biceps brachii)
Median nerve C5–T1	**A. Forearm** • **Muscles of anterior compartment** (except 1½ muscles innervated by ulnar nerve: flexor carpi ulnaris and the ulnar half of the flexor digitorum profundus)	Flex wrist and all digits Pronation
	B. Hand • **Thenar compartment:** Opponens pollicis • **Central compartment** Lumbricals: To second and third digits	Opposition of thumb Flex metacarpophalangeal (MP) and extend interphalangeal (PIP and DIP) joints of digits 2 and 3
Ulnar nerve C8–T1	**A. Forearm** **Anterior Compartment:** 1[½] muscles not innervated by the median nerve	Flex wrist (weak) and digits 4 and 5
	B. Hand • Hypothenar compartment • Central compartment —Interossei muscles: Palmar and Dorsal • Lumbricals: Digits 4 and 5 • Adductor pollicis	Dorsal—Abduct digits 2–5 (DAB) Palmar—Adduct digits 2–5 (PAD) Assist lumbricals in MP flexion and IP extension of digits 2–5 Flex MP and extend PIP and DIP joints of digits 4 and 5 Adduct the thumb
Axillary nerve C5–C6	Deltoid Teres minor	Abduct shoulder—15°–110° Lateral rotation of shoulder
Radial nerve C5–T1	**Muscles of posterior compartment** of the arm and forearm	Extend MP, wrist, and elbow Supination (supinator muscle)

Please visit us at www.Groupinsiders.com

© DeVry/Becker Educational Development Corp. All rights reserved.

▼ **Table 10–3.0B** Additional Major Nerves of the Brachial Plexus

Nerve	Muscles or Skin Innervated
Long thoracic nerve	Serratus anterior (rotate scapular superiorly and hold scapula against rib cage)
Suprascapular nerve C5, 6	Supraspinatus—abduct shoulder 0–15° Infraspinatus—laterally rotate humerus
Lateral pectoral nerve	Pectoralis major (adduct and flex humerus)
Medial pectoral nerve	Pectoralis major and minor
Upper subscapular nerve	Subscapularis (medial rotate humerus)
Middle subscapular (thoracodorsal) nerve C(6), 7, 8	Latissimus dorsi (adduct, medial rotate and extend humerus)
Lower subscapular nerve	Subscapularis and teres major

3.1 Segmentation of Nerve Fibers in Brachial Plexus

There is a proximal-to-distal segmental gradient in the distribution of the fibers in the brachial plexus to the muscles of the upper limb:

- Proximal shoulder and arm muscles: C5–C6 fibers
- Distal arm and proximal forearm muscles: C6–C7
- Distal forearm muscles: C7–C8
- Hand muscles: C8–T1

4 Cutaneous Nerves of the Forearm and Hand

The sensory innervation of the forearm and hand is shown in Figure 10–4.0.

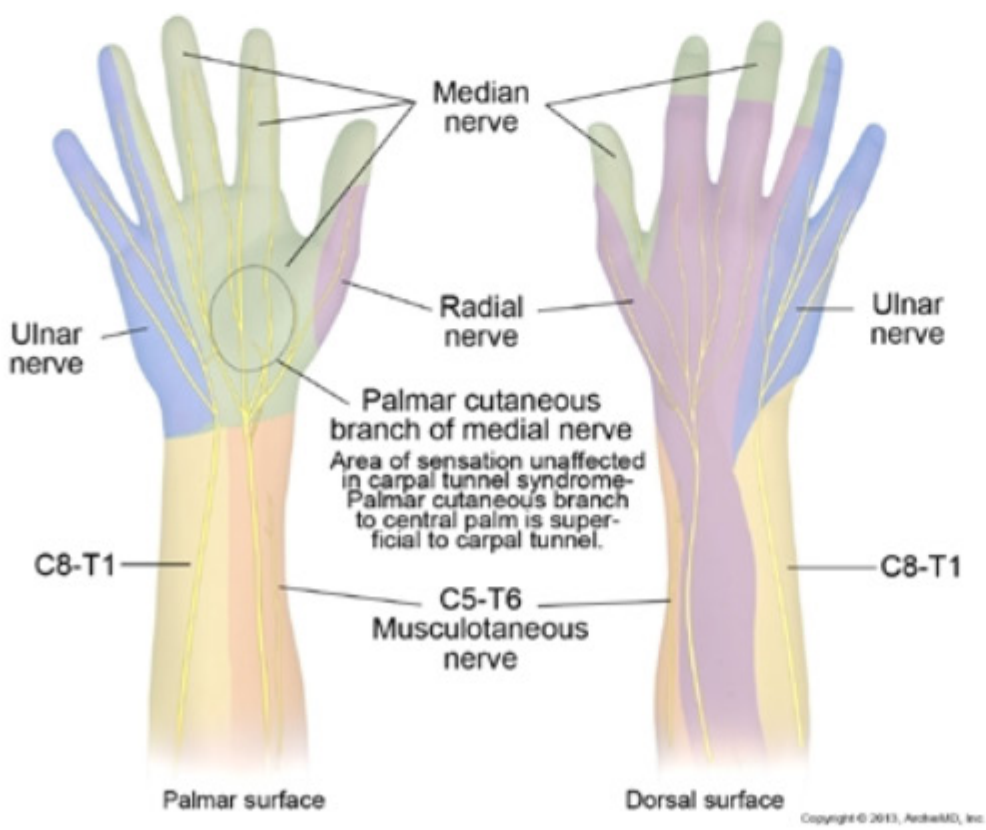

◀ **Figure 10–4.0** Sensory Innervation of the Hand

Please visit us at www.Groupinsiders.com

© DeVry/Becker Educational Development Corp. All rights reserved.

5 Lesions of the Upper Limb and Brachial Plexus

Points to consider when evaluating a nerve lesion:

- Note any sensory deficits, because sensory deficits usually precede muscle weakness.
- When motor functions are lost on one side of an articulation, the opposing antagonist muscles will, at rest, pull the limb in the position opposite of the loss function. For example, if flexors are lost on one side of an articulation, the opposite intact extensors pulls the limb into extension.
- Some motor deficits will become apparent when the limb is at rest, and other deficits occur when the patient moves the limb.
- When nerves run long courses in a limb (median, ulnar, or radial), test the most distal motor and sensory functions first. This gives a good overall view of the integrity of the nerve.

5.1 Axillary Nerve (C5–C6)

Common lesion sites are (1) fracture of the surgical neck of the humerus and (2) inferior dislocation of the shoulder joint.

- Axillary nerve innervates the deltoid and teres minor muscles.
- Loss of horizontal abduction (15–110 degrees) of the arm at the shoulder joint due to paralysis of the deltoid.
- Atrophy of the deltoid muscle and loss of the rounded contour of the shoulder.
- Sensory loss of skin overlying the cap of the shoulder.

5.2 Musculocutaneous Nerve (C5–C6)

Damaged in trauma to the axilla or muscle compression in the upper arm.

- Severe weakness of elbow flexion and weakness in supination.
- Sensory loss of lateral side of the forearm between elbow and base of thumb.

5.3 Suprascapular Nerve (C5–C6)

Injury due to entrapment as the nerve crosses the superior border of the scapula in the scapular notch.

- The suprascapular nerve innervates the supraspinatus and infraspinatus muscles.
- Weakness in initiating the first 15 degrees of shoulder abduction due to loss of the supraspinatus muscle. This deficit can be compensated by other muscles.
- Some weakness of external (lateral) rotation of the shoulder due to loss of the infraspinatus muscle.
- *No sensory loss*.

Please visit us at www.Groupinsiders.com

© DeVry/Becker Educational Development Corp. All rights reserved.

5.4 Long Thoracic Nerve (C5, C6, C7)

Damaged as the nerve passes on the superficial surface of the serratus anterior muscle by trauma to the lateral chest wall or following mastectomy when the nerve may be accidently cut at the lateral aspect of the mammary gland.

- Weakness in rotating the scapula upward, resulting in difficulty in abducting the arm vertically above the horizon and raising the hand above the head.
- Weakness in holding the scapula tightly against the dorsal chest wall. Sign is a *winged scapula*.
- *No sensory losses* with a long thoracic nerve lesion.

5.5 Thoracodorsal Nerve (C6, C7, C8)

Injuries occur with trauma or surgical approaches to the lateral chest wall.

- Injury affects the latissimus dorsi muscle.
- Weakened adduction, extension, and medial rotation of the shoulder.
- Lesion of thoracodorsal nerve significantly affects extension of the shoulder.

The *radial*, *median*, and *ulnar* nerves or their branches course the length of the upper limb. These nerves can be damaged at various sites along the limb, resulting in different motor and sensory deficits, as described below.

5.6 Radial Nerve (C5–C8, T1)

Injury in the axilla: Compression of radial nerve at the armpit after using crutches or Saturday night palsy.

An injury to the radial nerve in the axilla is proximal to the origin of the nerves supplying the triceps brachii. There is paralysis of the triceps and the dorsal forearm muscles that extend the wrist, thumb, MP joints, and the supinator muscle.

- Loss of extension of elbow, wrist, and MP joints.
- Distal sign is *wrist drop* with a poor grip.
- Absence of the triceps reflex; *weakened supination* with the forearm slightly pronated. The pronator muscles of the anterior forearm are innervated by the median nerve and are functional.
- Sensory loss from skin on the dorsum of the forearm and of the radial side of the hand (first dorsal web space).

Injury at midshaft of humerus: Lesion resulting from a
(1) midshaft fracture of the humerus at the radial groove;
(2) lateral elbow trauma at the lateral epicondyle; or
(3) dislocation of the head of radius.

- Loss of extension of wrist and MP joints.
- *Elbow extension is sparred* in lesions of radial nerve distal to the armpit because the nerves to the triceps arise proximal to the radial groove.
- *Wrist drop* is the distal sign. Inability to extend wrist indicates a lesion at or proximal to the elbow.
- Sensory loss from extensor surface of forearm and dorsum of thumb.

Please visit us at www.Groupinsiders.com

© DeVry/Becker Educational Development Corp. All rights reserved.

Laceration at wrist

- Only sensory loss on dorsum of thumb.
- No motor deficits with wrist lesions. Remember there are no intrinsic compartment muscles of the dorsum of the hand.

5.7 Median Nerve (C5–T1)

Injury at elbow: Lesions of median nerve at the elbow can result from supracondylar fracture of the humerus or muscle compression of the median nerve in the cubital fossa.

- Lesions at the elbow or above result in global loss of all median nerve functions in the forearm and hand. Arm muscles are not affected.
- Flexion and abduction of wrist are much weakened, but not totally lost because of the ulnar innervated flexor carpi ulnaris and the medial two tendons of the flexor digitorum profundus. There is ulnar deviation of the wrist.
- Loss of pronation.
- When attempting to make a fist (flex all five digits), there is inability to flex digits 1–3, but digits 4–5 can be flexed using the medial half of the flexor digitorum profundus (innervated by ulnar nerve). Sign is a *hand of benediction*.
- Loss of thenar compartment muscles of the hand results in weakness of opposition of the thumb: sign of *ape hand* (thumb is pulled into the plane of the palm at rest by the intact adductor pollicis, with the ulnar innervated).
- Atrophy of the thenar muscles and a flattening of the thenar compartment.
- Weakness of lateral two lumbrical muscles.
- Sensory loss over the palmar surface of the lateral hand and the lateral 3½ digits.

Note: The *hand of benediction* and *ape hand* are both seen in a lesion at the elbow or above.

Lesion at wrist: Laceration; carpal tunnel syndrome (the wrist is the most common lesion site for a median nerve lesion.)

- The forearm motor functions of the forearm are spared (described above) with an elbow lesion. There is normal pronation, wrist flexion, and digital flexion.
- In the hand there is weakness of the thenar muscles, with *ape hand* at rest, as described previously.
- *Note:* With a wrist lesion there is no *hand of benediction*, as described previously.
- Thenar muscles atrophy and flatten over time.
- Weakness of the lateral two lumbricals.
- Sensory deficit will be mostly on the palmar side of the lateral 3½ digits. The skin on the palm is spared in a carpal tunnel lesion because the cutaneous branch of the median nerve to the palm arises in the distal forearm and enters the palm by passing superficial to the carpal tunnel.

Please visit us at www.Groupinsiders.com

© DeVry/Becker Educational Development Corp. All rights reserved.

5.8 Ulnar Nerve (C8–T1)

Damage of the ulnar nerve can occur (1) on the medial side of the elbow (trauma to the medial epicondyle); (2) as a result of wrist laceration or compression; or (3) with fracture of hook of the hamate.

Lesions at any of these locations produce similar signs because most of the ulnar motor and sensory functions are dedicated to intrinsic functions of the hand.

- Motor loss of the medial two lumbricals, dorsal, and palmar interossei, adductor pollicis, and hypothenar compartment muscles.
- Loss of *abduction and adduction of digits 2–5* (due to the loss of the dorsal and palmar interossei muscles, respectively).
- Weakness of *IP extension of digits 2–5,* but with limited weakness of IP extension for digits 2 and 3 (lumbricals for these two digits are innervated by median nerve and are unaffected).
- Weakness of IP extension of digits 2–5 causes clawing or flexion due to the pull of the intact long flexors of the flexor forearm muscles, and results in a position of the hand called *claw hand*. Note that clawing is less pronounced in digits 2 and 3 because these two lumbrical muscles are innervated by the median nerve and are functional. Hyperextension of the MP joints of digits 2–5.
- Strongly abducted thumb (loss of the *adductor pollicis*); other movements of the thumb are intact.
- Weakness, atrophy, and flattening of hypothenar compartment muscles.
- Sensory loss from the dorsal and palmar surfaces of the medial 1½ digits of the hand.
- *Note:* With an ulnar nerve lesion at the elbow, there is weakness of the flexor carpi ulnaris and the medial half of the flexor digitorum profundus in addition to the above deficits. Results in:
  - Minimal weakness in wrist flexion with *radial deviation* (loss of the flexor carpi ulnaris).
  - Radial deviation upon wrist flexion is one of the *main differences* observed between elbow and wrist lesion sites.
  - Clawing is greater with a wrist lesion of the ulnar nerve because of the loss of the medial two heads of the flexor digitorum profundus.

5.9 Proximal Lesions of the Brachial Plexus

Proximal lesions at the roots and trunks are some of the more common sites for brachial plexus lesions. Injury can be caused by penetration wounds, trauma, stretching, or disease.

Memory Aid

A—Axillary nerve damaged at surgical neck

R—Radial nerve damaged at midshaft of humerus

M—Median nerve damaged with supracondylar break of humerus

Please visit us at www.Groupinsiders.com

© DeVry/Becker Educational Development Corp. All rights reserved.

5.9.1 Upper Brachial Plexus Lesion

Upper brachial plexus lesion, or *Erb-Duchenne syndrome* (waiter's tip), involves damage to the *C5 and C6 fibers of the superior trunk*. The injury usually results from falls on the shoulder in which the head and shoulder are acutely separated, which can stretch or tear the upper brachial plexus in the posterior triangle region of the neck. This trauma can also occur during birth when the nerves are stretched.

- Damage to the C5–C6 fibers significantly affects the *musculocutaneous*, *suprascapular*, and *axillary nerves* as well as the proximal muscles at the shoulder and arm.
- The upper limb is strongly *adducted at the shoulder* due to the loss of the abduction functions of the *suprascapular* and *axillary nerves*. The unopposed pectoralis major and latissimus dorsi muscles pull the limb in adduction.
- Damage to the *musculocutaneous nerves* (loss of the anterior arm muscles) results in *extension of the elbow* with *pronation of the forearm*.
- Clinical appearance: The limb hangs by the side (tightly adducted shoulder by the unopposed adductors of the shoulder) with extended elbow and pronated forearm (loss of musculocutaneous nerve). The sign is the *waiter's tip position*.
- Sensory loss is on the lateral border of the forearm.

5.9.2 Lower Brachial Plexus Lesion

Lower brachial plexus lesions *(Klumpke palsy)* are not as common as those on the upper brachial plexus. This trauma occurs when the upper limb is suddenly pulled upward and away from the body. Damage to the lower brachial plexus can also occur during delivery or with a thoracic outlet syndrome. The injury involves damage to the *C8 and T1 fibers of the inferior trunk* in the posterior triangle of the neck. The distal muscles of the limb innervated by C8 and T1 nerves are the ones mainly involved.

- C8 and T1 lesions primarily affect the intrinsic muscles of the hand innervated by the ulnar nerve (interossei and medial two lumbricals) and some of the muscles innervated by C8 and T1 fibers of the median nerve (thenar compartment).
- Patient presents with a combined claw hand and some degree of ape hand.
- Similar to an ulnar nerve lesion; in addition, there is some weakness of the thenar muscles.
- Sensory loss of the medial border of the forearm and the medial 1½ digits.

Please visit us at www.Groupinsiders.com

© DeVry/Becker Educational Development Corp. All rights reserved.

A summary of the major lesions to the brachial plexus is shown in Table 10–5.9.

▼Table 10–5.9 Lesions of the Brachial Plexus and Its Branches

Disorder	Lesion	Cause	Clinical Features
Erb-Duchenne palsy	Upper brachial plexus (C5 and C6)	Separation of head and shoulder (such as trauma, during delivery)	*"Waiter's tip"* position (shoulder medial rotated and extended and adducted; forearm pronated)
Klumpke palsy	Lower brachial plexus (C8–T1)	Upper limb pulled upward (trauma and during delivery)	Claw hand from ulnar nerve involvement; ape hand with median nerve involvement; asociated with Horner syndrome
Claw hand	Ulnar nerve	Medial elbow and wrist trauma	Weak finger abduction and adduction; medial hand numbness; clawing of digits 2–5
Radial nerve palsy	Radial nerve	Fraction of midhumerus at radical groove; trauma to lateral elbow	Wrist drop; inability to extend wrist; loss of sensation from dorsum of thumb
Carpal tunnel syndrome	Median nerve	Repetitive wrist motion (swelling within the flexor retinaculum compresses the median nerve)	Wrist flexion elicits pain; wrist extension relieves pain; symptons worse at night. Ape hand; loss of sensation on the lateral 3½ digits
Winged scapula	Long thoracic nerve	Surgery (mastectomy) and trauma to lateral chest	Serratus anterior paralysis; medial scapula protudes if patient pushes against a wall
Surgical neck fracture of the humerus	Axillary nerve	A fall landing on the shoulder	Loss of innervation to deltoid; palpable depression under acromion; sensory loss of skin over deltoid

Please visit us at www.Groupinsiders.com

© DeVry/Becker Educational Development Corp. All rights reserved.

6 Blood Supply to the Upper Limb

The arterial blood supply to the upper limb is provided by the *subclavian artery*. The left subclavian artery is a direct branch of the arch of the aorta, and the right subclavian artery is a branch of the brachiocephalic artery. The subclavian arteries arch into the root of the neck and turn inferiorly across the first rib, where the name changes to the *axillary artery* at the lower border of the first rib.

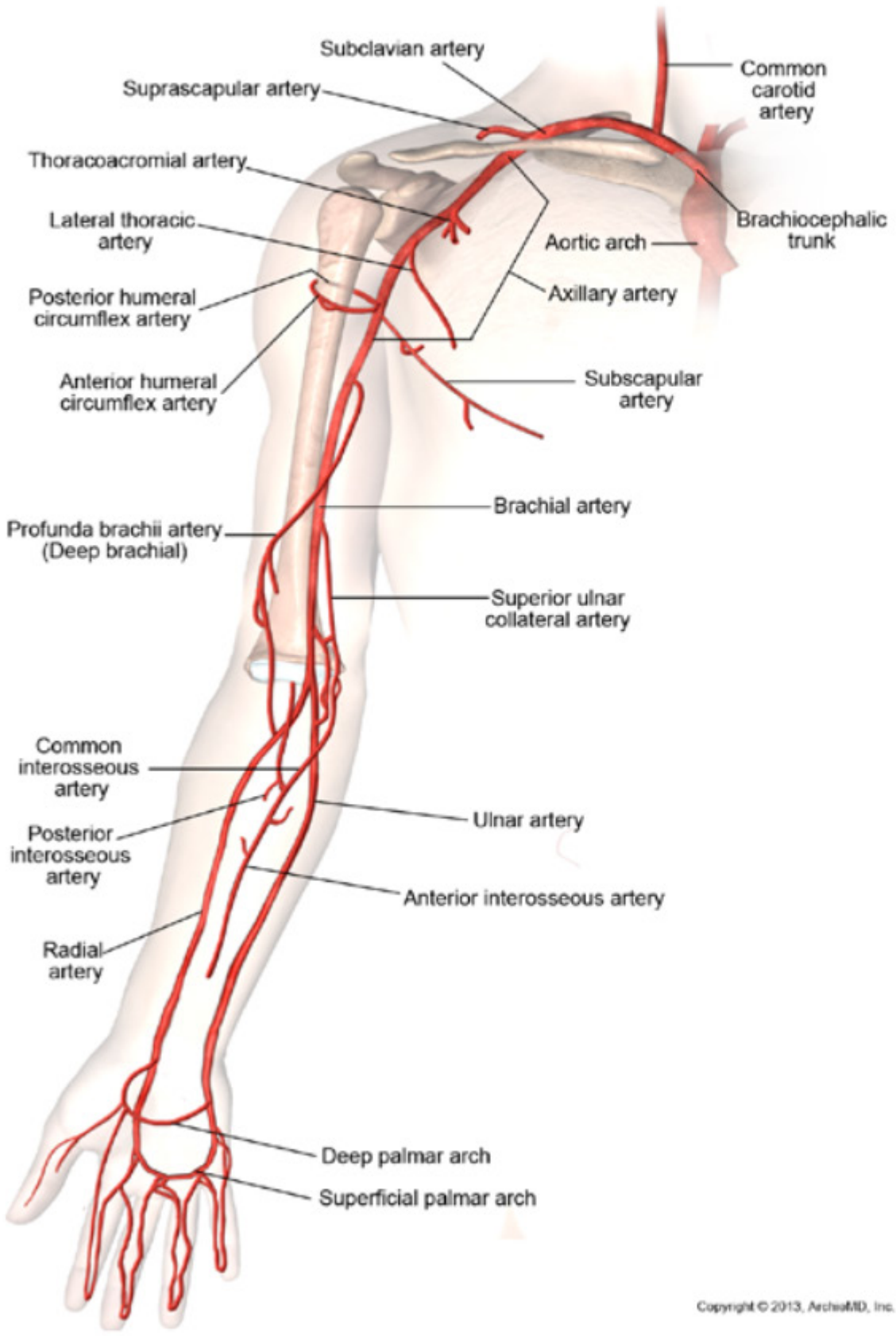

▲ **Figure 10–6.0** Blood Supply of Upper Limb

Please visit us at www.Groupinsiders.com

© DeVry/Becker Educational Development Corp. All rights reserved.

The sequence of vascular segments supplying the upper limb is the *axillary artery, brachial artery, radial and ulnar arteries, and the superficial and deep palmar arterial arches of the hand*.

6.1 Axillary Artery

The *axillary artery* extends from the *lower border of the first rib* to the *lower border of the teres major muscle*, where the name changes to the brachial artery to the arm. The axillary artery is the first vascular segment of the upper limb. There are six branches of the axillary artery in the axilla. The three important clinical arterial branches are the:

- **Posterior Humeral Circumflex Artery:** Encircles the surgical neck of the humerus with the *axillary nerve*, where they both are commonly damaged.
- **Subscapular Artery:** Contributes to the collateral circulation around the scapular and shoulder area by connecting with the *suprascapular branch* of the subclavian artery on the dorsal surface of the scapula.
- **Lateral Thoracic Artery:** Courses at the lateral chest wall on the surface of the serratus anterior muscle with the *long thoracic* nerve, where they can be commonly damaged.

6.2 Brachial Artery

The *brachial artery* is the continuation of the axillary artery inferior to the lower border of the teres major muscle. The brachial artery supplies the arm and continues into the cubital fossa, where it divides into the radial and ulnar arteries.

- One major branch of the brachial artery is the *profunda (deep) brachial artery*, which courses posterior to the midshaft of the humerus in the radial groove with the *radial nerve*, where they can commonly be damaged.

6.3 Radial and Ulnar Arteries

The radial and ulnar arteries descend the respective sides of the forearm and supply the muscle compartments of the forearm.

- In the hand, the radial and ulnar arteries form two vascular arches that supply the compartments and tissues of the hand:
  - **Superficial Palmar Arterial Arch:** Formed mainly by the ulnar artery.
  - **Deep Palmar Arterial Arch:** Formed mainly by the radial artery.

Please visit us at www.Groupinsiders.com

© DeVry/Becker Educational Development Corp. All rights reserved.

7 Rotator Cuff Muscles of the Shoulder Joint

The shoulder (glenohumeral) joint provides a highly mobile and freely movable articulation for the upper limb. To gain this mobility, strength and stability of the joint are sacrificed.

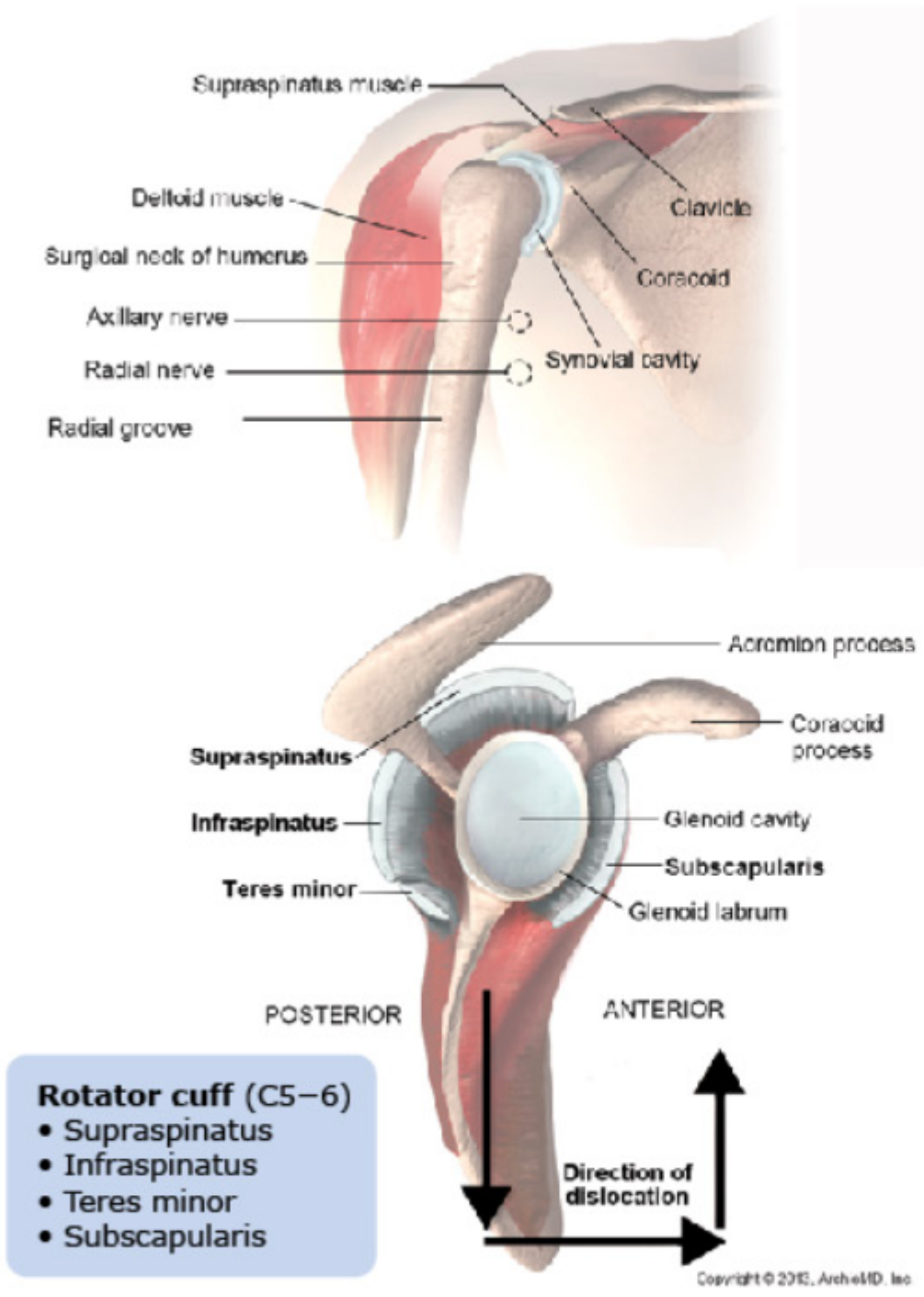

▲ **Figure 10–7.0** Shoulder and Rotator Cuff

The *rotator cuff* (SITS) consists of *four muscles (supraspinatus, infraspinatus, subscapularis, and teres minor)*. These muscles form a musculotendinous cuff, which provides strength, support, and stability to the articular capsule of the shoulder joint. The SITS muscles hold the head of the humerus in the glenoid cavity of the scapula. These four rotator cuff muscles primarily support the anterior, superior, and posterior aspects of the joint, leaving the inferior part of the joint the weakest.

The supraspinatus muscle is the most commonly damaged muscle of the rotator cuff.

Clinical Application

Shoulder Dislocation

Trauma or a fall with an outstretched hand can result in a dislocation of the humerus at the shoulder joint. The dislocation of the head of the humerus initially occurs inferiorly, where the cuff is the weakest. The humerus is then pulled anteriorly and superiorly by other muscles. The *axillary nerve* at the surgical neck of the humerus is the first to be damaged, followed by the *radial nerve*.

Please visit us at www.Groupinsiders.com

© DeVry/Becker Educational Development Corp. All rights reserved.

8 Carpal Tunnel

The carpal tunnel is the fibro-osseous passageway formed by ligaments and carpal bones on the ventral side of the wrist.

- The *anterior boundary* is formed by the *flexor retinaculum*, and the *posterior boundary* is formed primarily by the *lunate carpal bone* of the proximal row of carpal bones.
- Coursing through the tunnel are the *median nerve* immediately deep to the lateral aspect of the flexor retinaculum and nine flexor tendons of the flexor compartment of the forearm (*four flexor digitorum superficialis tendons, four flexor digitorum profundus tendons* and the tendon of the *flexor pollicis longus*).
- There are no other nerve structures or any vascular structures in the tunnel.

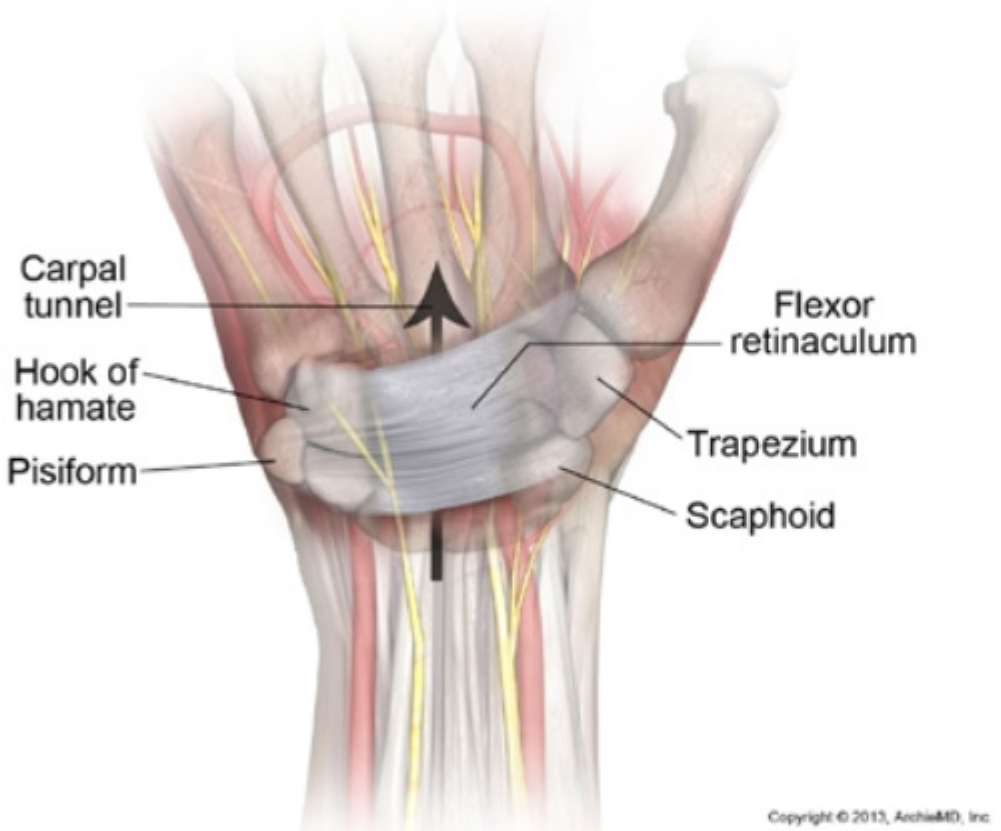

▲ **Figure 10–8.0A** Carpal Tunnel and Ventral Side of Wrist

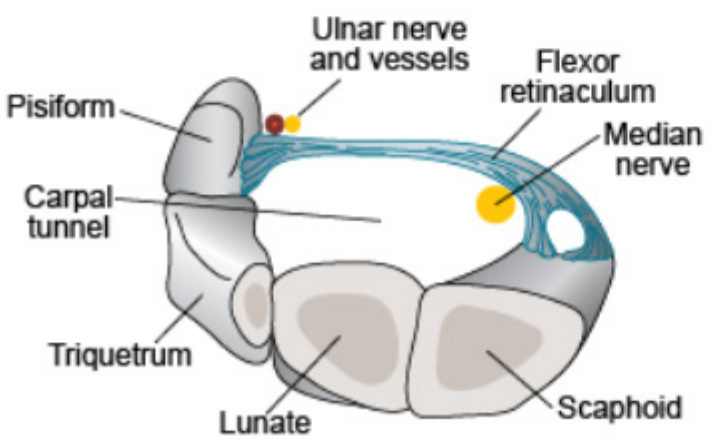

▲ **Figure 10–8.0B** Carpal Tunnel: Detailed View

Clinical Application

Carpal Tunnel Syndrome

Carpal tunnel syndrome results from pathology that reduces the space of the carpal tunnel (inflammation or thickening of the flexor retinaculum, arthritis, or inflammation of tendon sheaths).

- Compresses the median nerve with weakness in opposition of the thumb and some degree of *ape hand*.
- Compression of the long digital flexor tendons.
- Atrophy and flattening of the thenar muscles.
- Sensory loss and tingling on the lateral 3½ digits. Sensory loss on the lateral side of the central palm is not affected because the cutaneous branch of the median nerve supplying the lateral side of the palm does not course through the carpal tunnel, but runs superficial to the flexor retinaculum.

Please visit us at www.Groupinsiders.com

© DeVry/Becker Educational Development Corp. All rights reserved.

9 Radiology Images

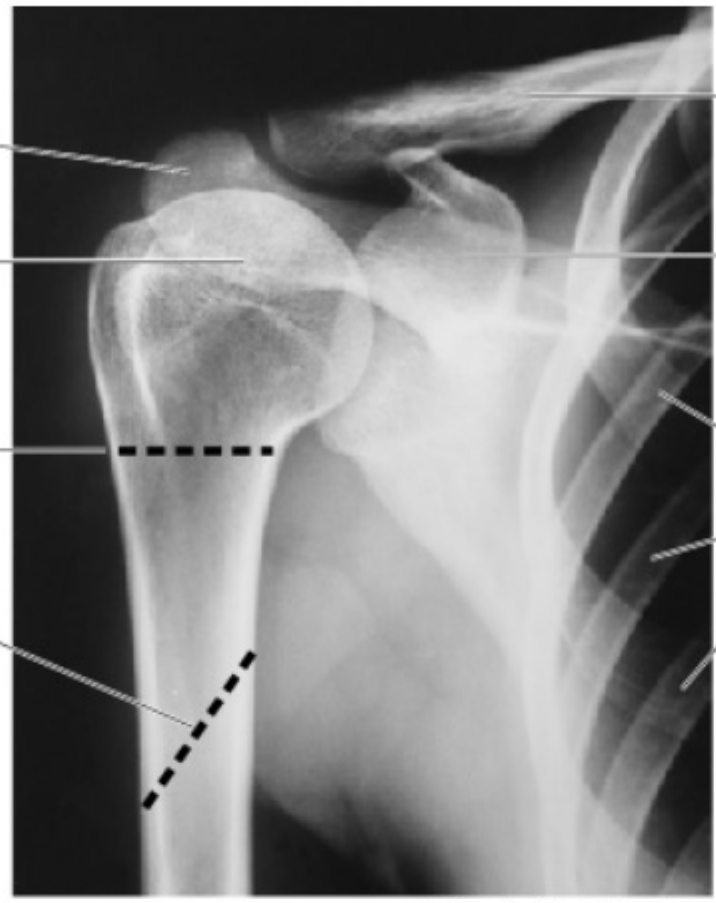

Biophoto Associates/Science Source

Charles McRae/Visuals Unlimited, Inc.

▲ **Figure 10–9.0A** Shoulder and Elbow

Please visit us at www.Groupinsiders.com

© DeVry/Becker Educational Development Corp. All rights reserved.

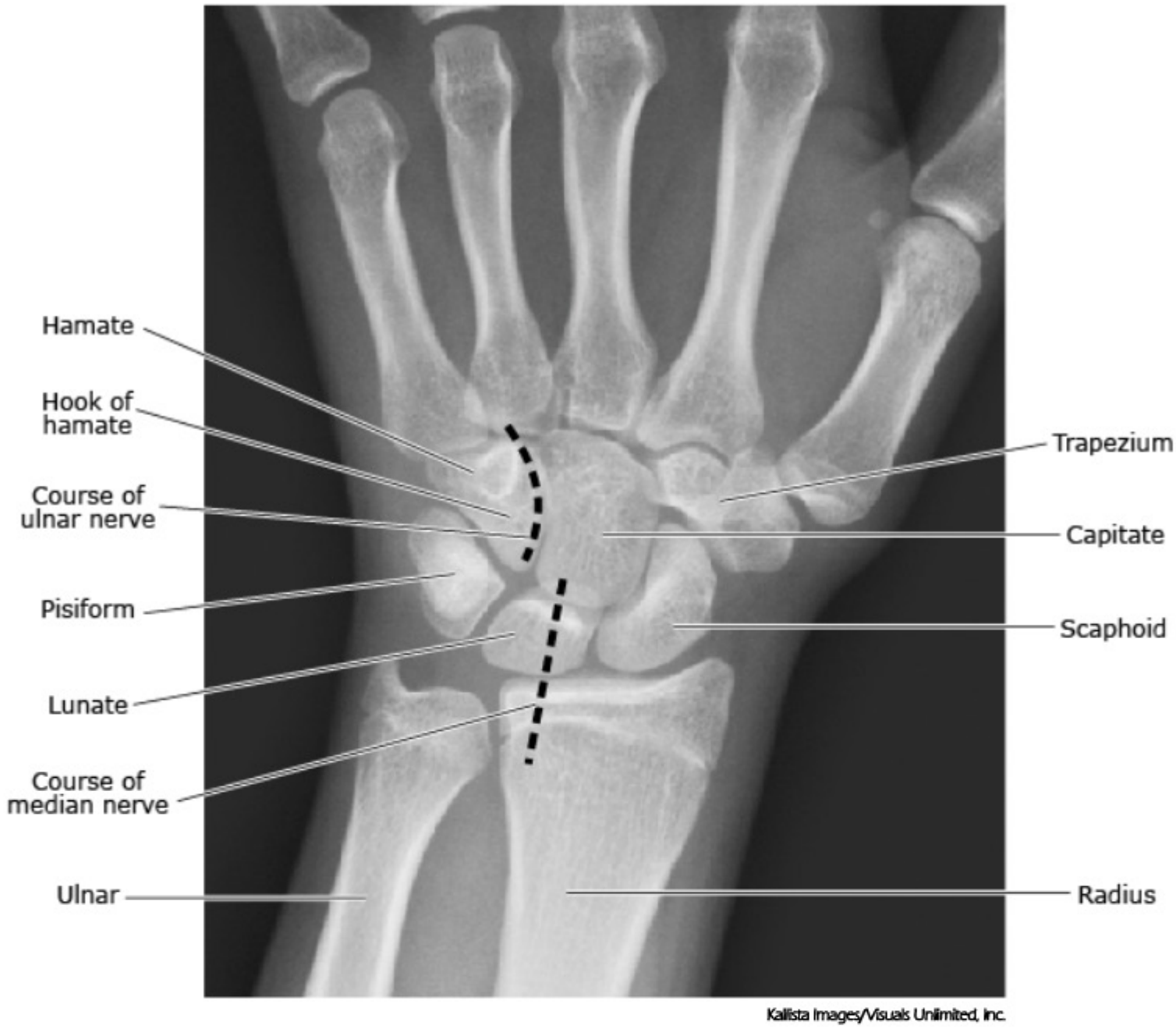

▲ **Figure 10–9.0B** Wrist and Hand

Please visit us at www.Groupinsiders.com

© DeVry/Becker Educational Development Corp. All rights reserved.

1 Overview

The lower limb is specialized for walking, locomotion, and supporting body weight, whereby the upper limb functions more in mobility and freedom of movement. The lower limb articulates with the pelvic girdle, which forms a solid ring of bone that is stronger and less mobile than the shoulder girdle.

2 Lumbosacral Plexus

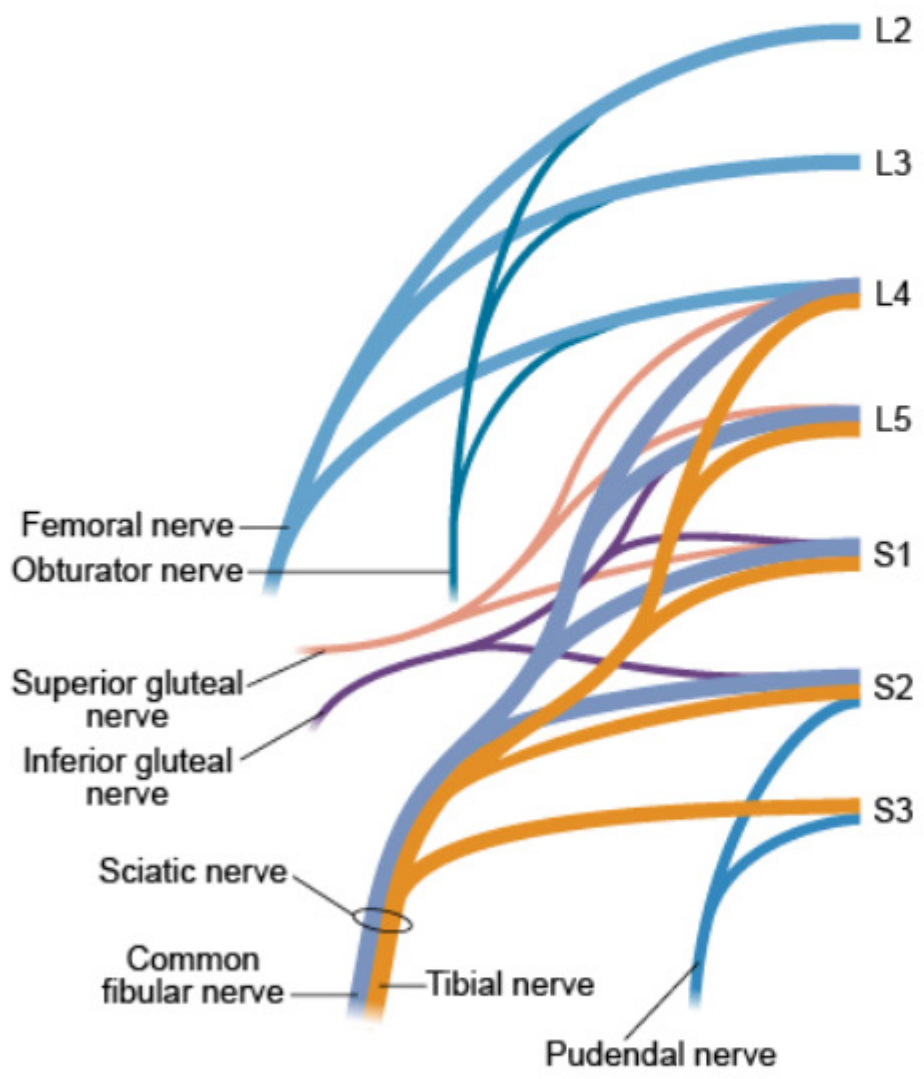

▲ **Figure 11–2.0** Lumbosacral Plexus

The *lumbosacral plexus* provides the network of nerves supplying the motor and sensory innervations for the lower limb. The plexus is formed by *the anterior (ventral) rami of spinal nerve from L2–S3*. The plexus forms on the posterior wall of the lower abdomen (lumbar plexus) and on the lateral wall of the pelvic cavity (sacral plexus).

USMLE® Key Concepts

For Step 1, you must be able to:

- List the major names of nerve branches of the lumbosacral plexus.
- Identify the muscular compartments, blood supply, and neurovascular relationships of the lower limb.
- Describe the sensory innervation of the foot.
- List the major nerve lesions of the lower limb and how they relate to motor and sensory deficits.
- Describe the structure and the ligaments of the knee joint.

Please visit us at www.Groupinsiders.com

© DeVry/Becker Educational Development Corp. All rights reserved.

The major nerves of the lumbosacral plexus and their segmentations are the:

- **Femoral Nerve:** Posterior division fibers of L2, L3, and L4.
- **Obturator Nerve:** Anterior division fibers of L2, L3, and L4.
- **Tibial Nerve:** Anterior division fibers of L4–S3.
- **Common Fibular Nerve:** Posterior division fibers of L4–S2.
- **Superior Gluteal Nerve:** Posterior division fibers of L4–S1.
- **Inferior Gluteal Nerve:** Posterior division fibers of L5–S2.

Note: The *sciatic nerve* is formed by the tibial and common fibular nerves combined in a common connective tissue sheath. The sciatic nerve descends through the gluteal region deep to the gluteus maximus and enters the posterior compartment of the thigh, where it divides into the tibial and common fibular nerves.

The motor distributions of the major branches of the lumbosacral plexus are shown in Tables 11–2.0A and 11–2.0B.

▼Table 11–2.0A Terminal Nerves of Lumbosacral Plexus

Terminal Nerve	Origin	Muscles Innervated	Primary Actions
Femoral nerve	L2–L4	*Anterior compartment* of thigh (quadriceps femoris, sartorius, pectineus)	Knee extension
Obturator nerve	L2–L4	*Medial compartment* of thigh (gracilis, adductor longus, adductor brevis, anterior portion of adductor magnus)	Adduct thigh Medially rotate thigh
Tibial nerve	L4–S3	*Posterior compartment* of thigh (semimembranosus, semitendinosus, long head of biceps femoris, posterior portion of adductor magnus)	Knee flexion Extend thigh
		Posterior compartment of leg (gastrocnemius, soleus, flexor digitorum longus, flexor hallucis longus, tibialis posterior)	Plantar flex foot (S1–S2) Flex digits Inversion
		Plantar muscles of foot	
Common fibular nerve	L4–S2	Short head of biceps femoris	Flex knee
Superficial fibular nerve	L4–L5, S1	*Lateral compartment of leg* (fibularis longus, fibularis brevis)	Eversion
Deep fibular nerve	L4–L5, S1–S2	*Anterior compartment of leg* (tibialis anterior, extensor hallucis, extensor digitorum, fibularis tertius)	Dorsiflex foot (L4–L5) Extend digits Inversion

▼Table 11–2.0B Additional Major Nerves of Lumbosacral Plexus

Nerve	Origin	Muscles or Skin Innervated	Primary Actions
Superior gluteal nerve	L4–S1	Gluteus medius, gluteus minimus, tensor fasciae	Stabilize pelvis Abduct hip
Inferior gluteal nerve	L5–S2	Gluteus maximus	Extension of hip Lateral rotation of thigh

Please visit us at www.Groupinsiders.com

© DeVry/Becker Educational Development Corp. All rights reserved.

3 Segmentation of Nerve Fibers in Lumbosacral Plexus

There is a proximal-to-distal gradient in the distribution of the segmental nerve fibers within the lumbosacral plexus to muscles of the upper limb, as shown in Table 11–3.1.

▼ **Table 11–3.1** Segmental Innervaton to Lower Limb

Anterior Muscles of Limb	Posterior Muscles of Limb
Hip: L2–L3	**Hip: L4–L5**
Knee: L3–L4	**Knee: L5–S1**
Ankle: L4–L5	**Ankle: S1 –S2**

4 Cutaneous Innervation of the Foot and Lower Leg

The sensory innervation of the lower leg and foot is shown in Figure 11-4.0.

▲ **Figure 11–4.0** Sensory Innervation of Foot

Please visit us at www.Groupinsiders.com

© DeVry/Becker Educational Development Corp. All rights reserved.

5 Nerve Lesions of the Lower Limb

5.1 Femoral Nerve (L2, L3, L4)

- Severe weakness in extension of the knee due to loss of quadriceps muscle.
- Some weakness in flexion of the hip.
- Sensory loss on anterior surface of the thigh.
- Sensory loss on medial leg and medial side of ankle (provided by the saphenous nerve).

5.2 Obturator Nerve (L2, L3, L4)

The obturator nerve is commonly damaged in the lateral wall of the pelvis. The adductor groups of muscles are involved in groin strains when the muscles are stretched, usually in sport injuries.

- Severe loss of adduction of the hip joint (loss of adductor compartment).
- Small area of sensory loss on medial side of thigh.

5.3 Inferior Gluteal Nerve (L5, S1, S2)

- Significant weakness in extension of the thigh.
- Weakness in lateral rotation of the thigh with loss of gluteus maximus muscle.
- Difficulty in walking up stairs or an incline and standing from a sitting position.
- No sensory loss.

5.4 Superior Gluteal Nerve (L4, L5, S1)

- Weakness in hip abduction and being unable to stabilize the pelvis during walking.
- Lesion results in a positive *Trendelenburg sign*, which is indicated when the pelvis falls and droops on the side where the foot is raised off the floor during walking. The patient presents with a waddling gait.
- *Note:* The weakness results from paralysis of the gluteus medius and minimus muscle on the side opposite the raised foot.
- No sensory loss.

5.5 Sciatic Nerve

Sciatic nerve injuries occur in the gluteal region and result from posterior dislocation of the head of the femur, herniated lumbar disks, or a poorly directed intramuscular injection.

- If complete, the sciatic nerve lesion would damage the tibial and common fibular nerves, resulting in loss of all functions of lower limb except those supplied by the femoral and obturator nerves.
- Herniation of the lower lumbar disk produces radiating pain into the leg and foot *(sciatica)*.
- Sensory loss on posterior aspect of the thigh, leg, and sole of the foot.

Important Concept

Posterior location of the hip can damage the sciatic nerve. A total lesion of the sciatic nerve would eliminate all nerve function in the lower limb except for the areas supplied by the femoral and obturator nerves.

Please visit us at www.Groupinsiders.com

© DeVry/Becker Educational Development Corp. All rights reserved.

5.6 Tibial Nerve (L4–S3)

The tibial nerve supplies muscles of the posterior thigh, posterior leg, and intrinsic foot compartments. At the medial side of the ankle, the tibial nerve enters the sole of the foot by passing posterior to the medial malleolus (the nerve can be compressed at the medial malleolus), where it divides into the *lateral and medial plantar nerves*.

- With lesions of the tibial nerve in the gluteal region, there is motor weakness in *knee flexion and plantar flexion*.
- With lesions at the knee, there is only weakness in plantar flexion.
- Sensory loss occurs on the posterior thigh, leg, and sole of the foot.

5.7 Common Fibular Nerve (L4, L5, S1, S2)

The common fibular nerve is the most frequently *lesioned nerve* in the lower limb, usually injured where it crosses the lateral side of the knee at the neck of the fibula, and piriformis compression.

- The nerve enters the leg and divides into the *deep* and *superficial fibular nerve distal to the neck of the fibula*.
- Lesion at the neck of the fibula results in loss of dorsiflexion *(foot drop)* and loss of eversion of the foot.
- Sensory loss on all of the dorsum of the foot and lateral side of the leg.

5.8 Deep Fibular Nerve (L4, L5, S1, S2)

- Courses in the anterior compartment of the leg with the anterior tibial artery.
- Weakened inversion.
- Loss of extension of the toes.
- Loss of dorsiflexion (L4–L5) *(foot drop)*.
- Loss of sensation from skin between the first and second toes.

5.9 Superficial Fibular Nerve (L4, L5, S1)

- Courses in the lateral compartment of the leg.
- Loss of eversion of the foot.
- Loss of sensation from most of the dorsum of foot except area supplied by deep fibular nerve (first web space).

The common fibular nerve crosses the lateral side of the neck of the fibula, where it is the most frequently damaged nerve of the lower limb. The individual will lose both the anterior and lateral compartments of the leg, resulting in foot drop and loss of eversion.

Compression of the common fibular nerve by the piriformis muscle can occur in the gluteal regions.

Please visit us at www.Groupinsiders.com

© DeVry/Becker Educational Development Corp. All rights reserved.

6 Blood Supply to the Lower Limb

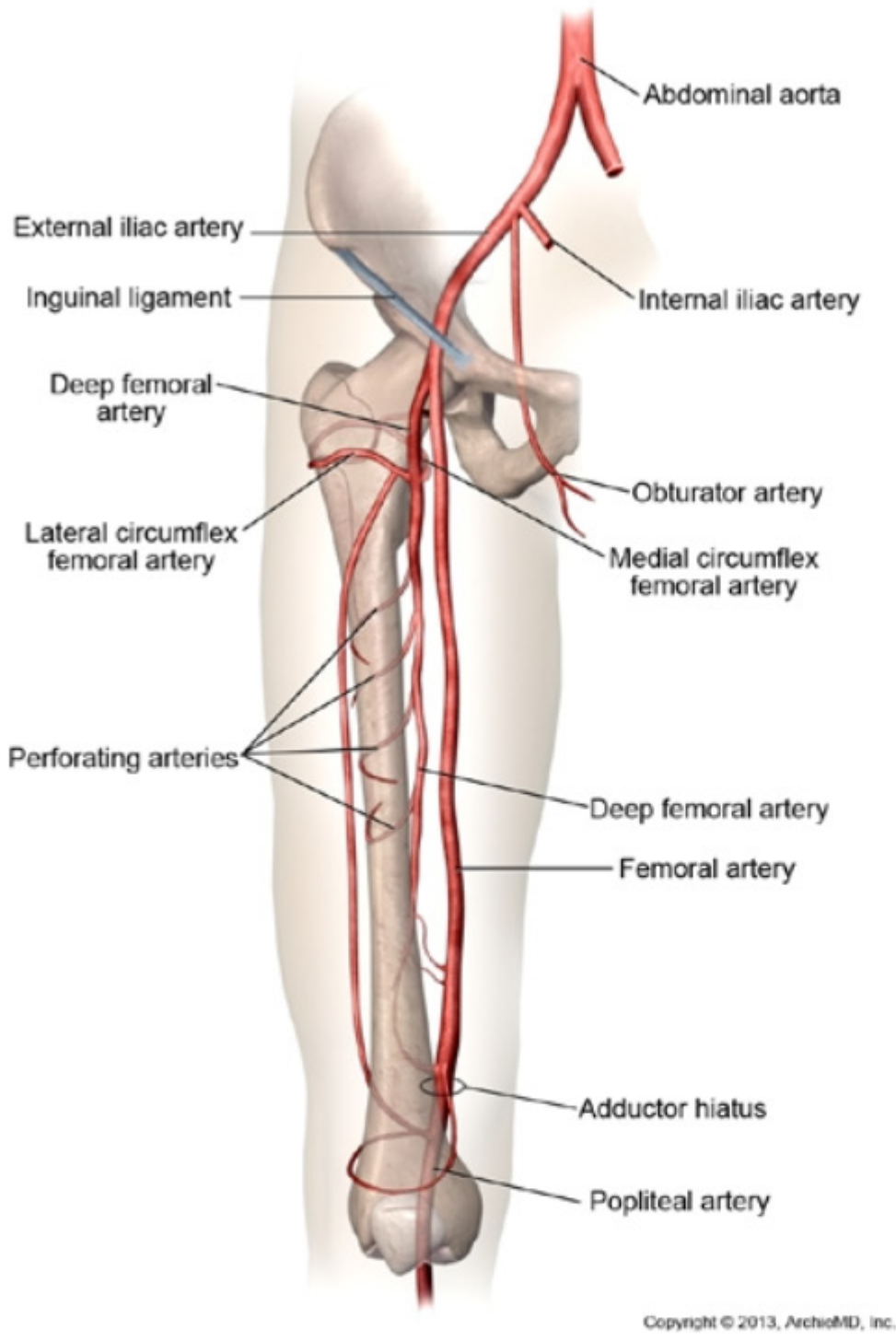

▲ **Figure 11–6.0** Blood Supply to Lower Limb

The common iliac artery bifurcates at the sacroiliac junction into the internal and external iliac arteries.

- The internal iliac artery gives rise to the *obturator artery*, which supplies the medial compartment of the thigh.
- The external iliac artery continues on the pelvic brim and passes deep to the inguinal ligament to become the *femoral artery*.
- The femoral artery enters the femoral triangle of the anterior compartment of the thigh within the femoral sheath between the femoral vein medially and the femoral nerve laterally.
- The femoral artery supplies many muscular arteries in the thigh. Its major branch in the thigh is the profunda femoris artery.

Please visit us at www.Groupinsiders.com

© DeVry/Becker Educational Development Corp. All rights reserved.

6.1 Profunda (Deep) Femoris Artery

- *Medial circumflex femoral artery* provides the main supply of blood to the *head of the femur*. Vascular insufficiency leads to *vascular necrosis of the head of the femur*.
- *Lateral circumflex artery* contributes to blood supply to muscles on the lateral thigh.
- Provides several perforating arteries to the posterior compartment muscles of the thigh.

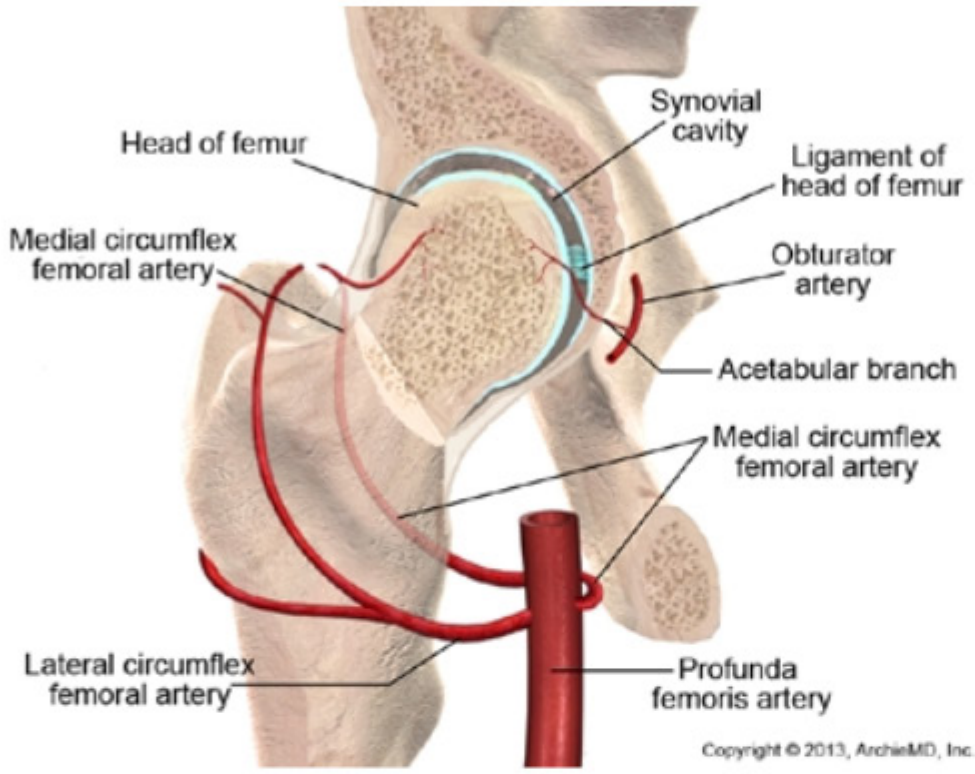

▲ **Figure 11–6.1** Blood Supply to Hip

The primary blood supply to the head of the femur is from the medial femoral circumflex artery. Vascular disease of this vessel can lead to avascular necrosis of the head of the femur.

Please visit us at www.Groupinsiders.com

© DeVry/Becker Educational Development Corp. All rights reserved.

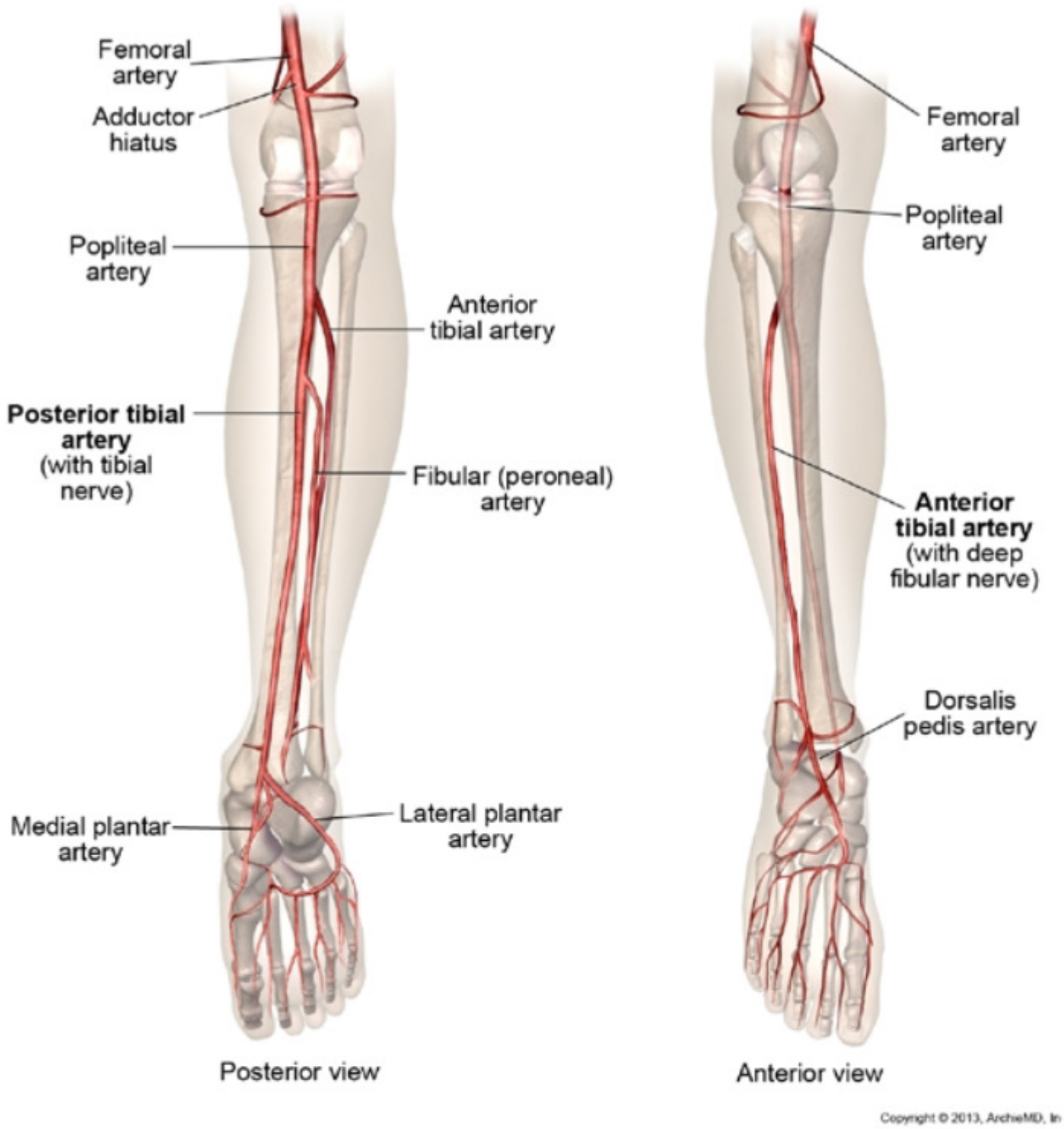

▲ **Figure 11–6.2** Blood Supply to Lower Limb

6.2 Popliteal Artery

In the distal thigh, the femoral artery enters the popliteal fossa by passing through the adductor hiatus. In the fossa, the femoral artery becomes the *popliteal artery*. The popliteal artery supplies the knee joint, and, at the lower border of the popliteus muscle, the popliteal artery divides into the anterior and posterior tibial arteries.

- **Anterior Tibial Artery:** The anterior tibial artery supplies muscles of the anterior compartment of the leg and courses with the deep fibular nerve.
  - Distally, the anterior tibial artery crosses the dorsal surface of the ankle, where it becomes the dorsalis pedis artery lateral to the extensor halluces longus. Dorsalis pedis pulse can be felt as the artery is compressed against the dorsal surface of the tarsal bones.

Please visit us at www.Groupinsiders.com

© DeVry/Becker Educational Development Corp. All rights reserved.

- **Posterior Tibial Artery:** The posterior tibial artery supplies muscles of the lateral and posterior compartments of the thigh. In the posterior compartment, the posterior tibial artery courses with the tibial nerve. The artery passes *posterior to the medial malleolus* with the tibial nerve and divides into the *medial and lateral plantar arteries* that supply the intrinsic compartments in the sole of the foot.

Clinical Application

Femoral Head Necrosis

The medial circumflex femoral artery is the primary blood supply to the head of the femur. Fractures or vascular pathology that reduce this blood flow result in *avascular necrosis of the head of the femur*.

Compartment Syndromes

Hemorrhage into the compartments of the limbs due to injury or fractures results in increased compartmental pressures and compression of the nerves and vascular structures, producing acute pain. Surgical relief is usually required.

- **Anterior Compartment:** Weakness of dorsiflexion and extension of the toes; severe pain with passive plantar flexion and eversion of the foot.
- **Posterior Compartment:** Weakness of plantar flexion; severe pain with passive dorsiflexion.

Please visit us at www.Groupinsiders.com

© DeVry/Becker Educational Development Corp. All rights reserved.

7 Knee Joint

The knee joint is the articulation between the two condyles of the femur and the two condyles of the tibia and also the joint between the patella and the femur. The knee joint provides critical mechanisms for standing, walking, locomotion, and weight bearing, and is damaged frequently because it depends on muscle and ligaments for most of its support.

- Primary actions are flexion and extension with some rotation.
- Support and stabilization of the joint are provided by surrounding muscles and ligaments.

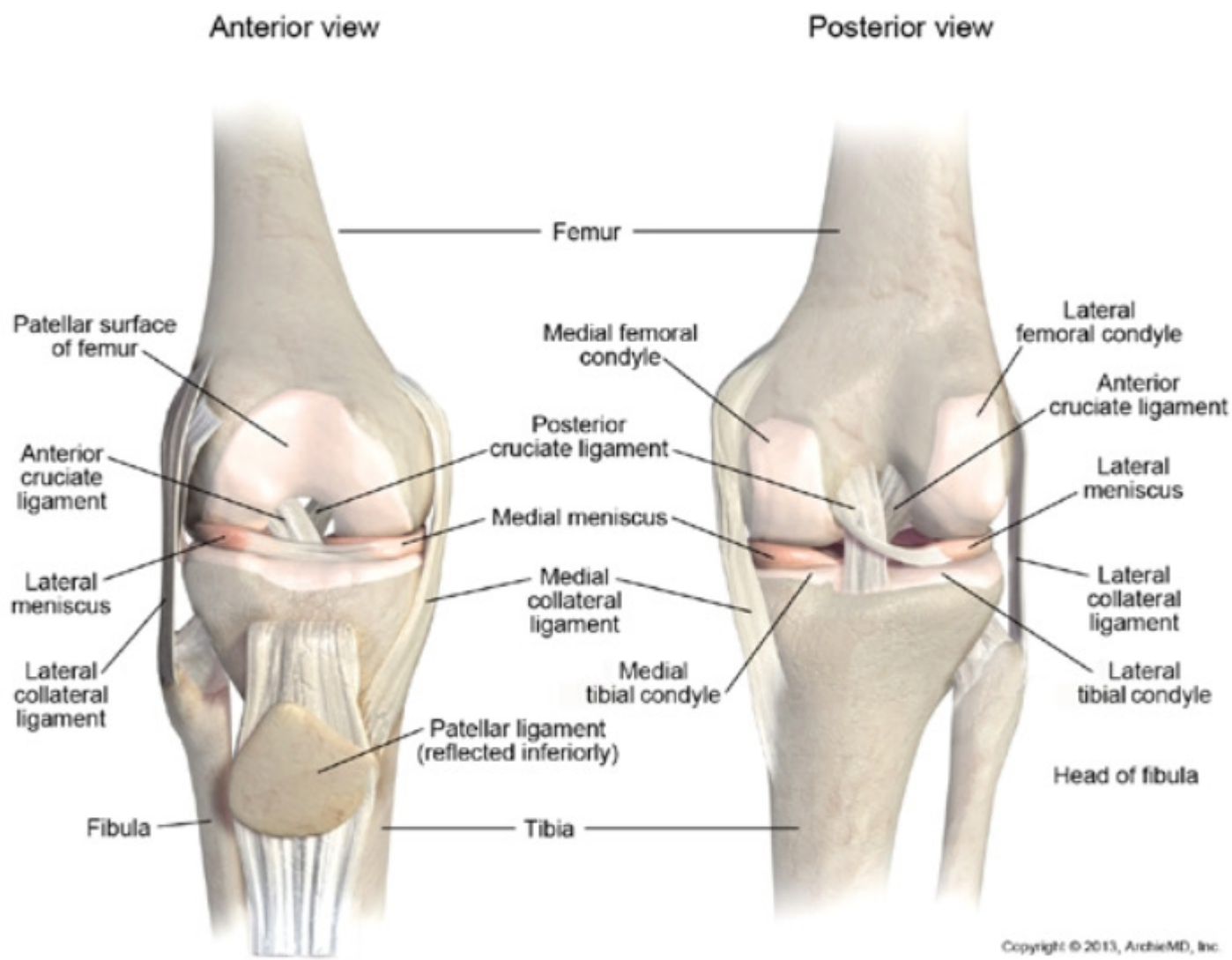

▲ **Figure 11–7.0** Knee Joint

7.1 Support Structures of the Knee Joint

7.1.1 Muscles

The tendons of the quadriceps muscles of the anterior compartment of the thigh with the patella ligament cross the joint ventrally and provide anterior support. The hamstring muscles of the posterior compartment of the thigh cross the joint dorsally and provide posterior support.

Please visit us at www.Groupinsiders.com

© DeVry/Becker Educational Development Corp. All rights reserved.

7.1.2 Major Capsular Ligaments

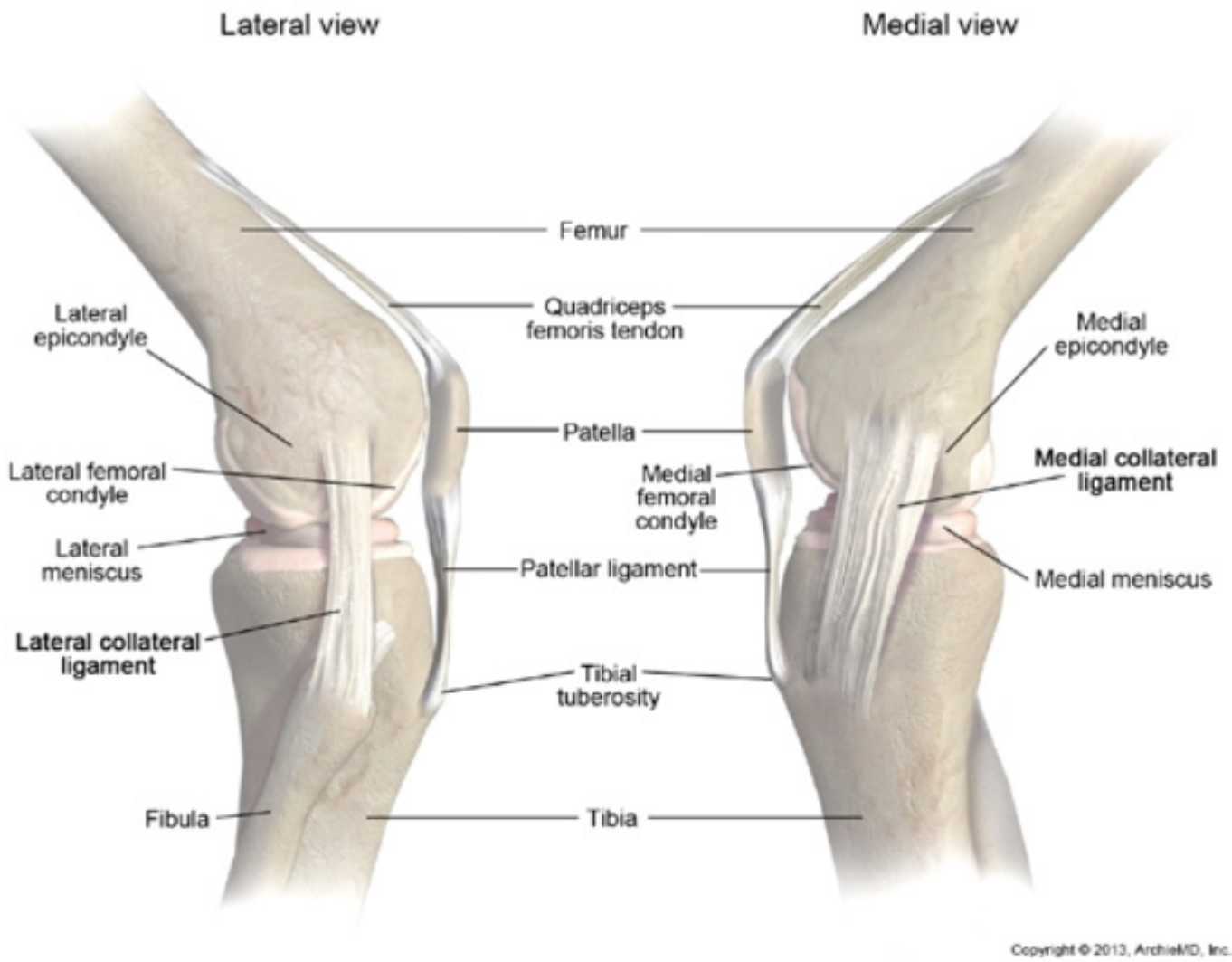

▲ **Figure 11–7.1A** Collateral Ligaments

1. **Lateral (Fibular) Collateral Ligament**
   - Supports the lateral aspect of the knee joint and is very strong and not commonly injured.
   - Attaches above to the lateral femoral epicondyle and below to the fibular head.
   - Resists *medial* (adduction) displacement of the tibia under the femur.
   - Not attached to the lateral meniscus.
   - Becomes tight with extension of knee.
2. **Medial (Tibial) Collateral Ligament**
   - Supports the medial aspect of the knee joint and is very important in stabilizing the knee.
   - Attaches above to the medial femoral epicondyle and below to the tibial condyle.
   - Resists *lateral* (abduction) displacement of the tibia under the femur. Is firmly attached to the medial meniscus, and the two are often damaged concurrently.
   - Becomes tight with extension of knee.
3. **Patella Ligament**
   - Attaches the patella to the tibial tuberosity and provides the insertion of the quadriceps muscles.

Clinical Application

The tibial and fibular collateral ligaments are most taut during extension of the knee. The tibial collateral ligament is the most commonly damaged ligament of the knee, often following lateral blows to the knee.

Please visit us at www.Groupinsiders.com

© DeVry/Becker Educational Development Corp. All rights reserved.

7.1.3 Intracapsular Ligaments

1. Anterior Cruciate Ligament (ACL)

- Arises from the anterior intercondylar margin of the tibia and passes upward to insert on the medial side of the lateral condyle of the femur (see Figure 11–7.0 and Figure 11–7.1B).
- Resists *anterior movement* of the tibia under the femur.
- Is tightest when the knee is extended and limits hyperextension of the knee.
- Injury to the ACL is often associated with damage to the tibial collateral ligament and the medial meniscus.
- Is weaker than the posterior cruciate ligament and is more frequently damaged.

2. Posterior Cruciate Ligament (PCL)

- Attaches to the posterior intercondylar margin of the tibia and passes upward to insert on the lateral side of the medial condyle of the femur (see Figure 11–7.0 and Figure 11–7.1B).
- Resists *posterior movement* of the tibia under the femur.
- Is tightest when the knee is flexed and limits flexion.
- Is stronger than the ACL.

Clinical Application

The ACL is most taut with the extended knee and resists hyperextension. It is weaker and more often damaged than the PCL and prevents anterior displacement of the tibia under the femur.

The PCL is most taut with the knee flexed and resists excessive flexion. It prevents posterior displacement of the tibia under the femur.

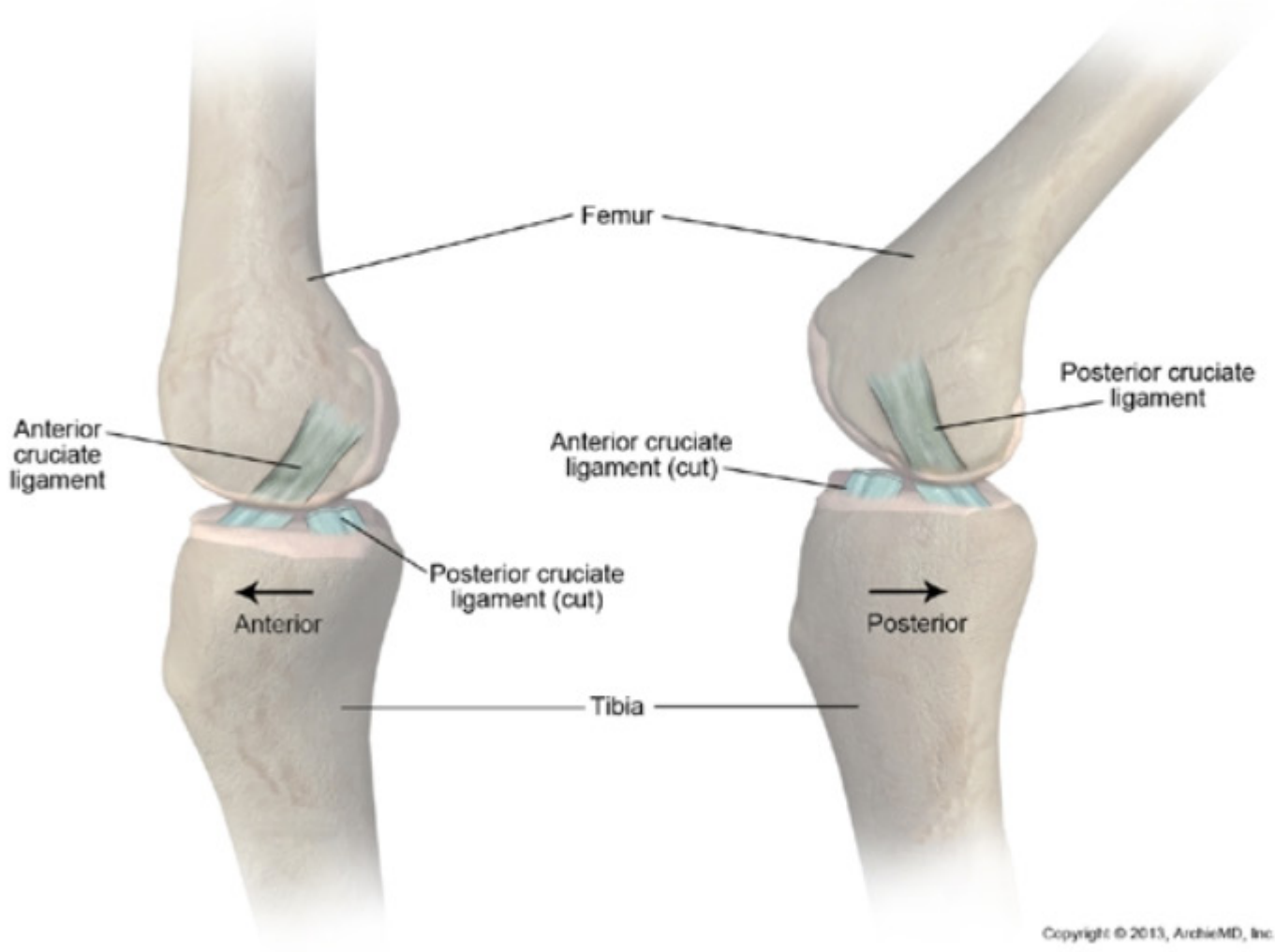

▲ **Figure 11–7.1B** Cruciate Ligaments

Please visit us at www.Groupinsiders.com

© DeVry/Becker Educational Development Corp. All rights reserved.

7.1.4 Menisci

The *menisci* are wedges of fibrocartilage that rest on the medial and lateral tibial plateaus. They facilitate the articulation of the opposing condyles.

Lateral Meniscus

- Is almost circular.
- Is not fused to the lateral collateral ligament and floats more freely in the joint.

Medial Meniscus

- Is shaped like the letter C.
- Is firmly attached to the tibial collateral ligament and is more frequently damaged than the lateral meniscus.

Clinical Application

Menisci

Tears and displacements of the menisci are some of the more common injuries to the knee. The *medial meniscus* is injured more frequently than the lateral meniscus because the medial meniscus is firmly attached to the medial collateral ligament.

Drawer Sign

The drawer sign is used to determine the integrity of the ACL and PCL.

- The *anterior drawer sign* is the excessive forward movement of the tibia on the femur resulting from a tear of the ACL.
- The *posterior drawer sign* is the excessive posterior movement of the tibia on the femur resulting from a tear of the PCL.

Unhappy Triad

The *unhappy triad injury* occurs when the foot is firmly attached to the ground and there is a blow to the knee from the lateral side. The injury typically involves rupture of the *tibial collateral ligament*, the *ACL,* and the *medial lemniscus*.

Ankle Sprain

Ankle sprains usually occur with an inversion injury that stretches the ligaments on the lateral aspect of the ankle. The *anterior talofibular ligament* is most often damaged.

Please visit us at www.Groupinsiders.com

© DeVry/Becker Educational Development Corp. All rights reserved.

Review Questions Chapters 10–11

1. A 70-year-old female is admitted to the hospital after falling at her home. Her right lower limb is laterally rotated and radiographic examination reveals a fracture of the femoral neck. Which artery is at most risk for damage?

A. Deep femoral
B. Medial circumflex femoral
C. Femoral
D. Upper perforating
E. Lateral circumflex femoral

2. A decreased pulse in the dorsalis pedis artery could result from damage to an artery in which of the following locations?

A. Posterior to the medial malleolus
B. Posterior to the lateral malleolus
C. Anterior compartment of the leg
D. Deep to the gastrocnemius and soleus muscles
E. Neck of the fibula

3. An 18-year-old man was involved in a head-on automobile collision; during the crash, his flexed knee hit the dashboard of the car. The physical exam shows that he has a major instability of the tibia at the knee joint where the tibia freely moves posteriorly underneath the femur. Which of the following structures was most likely damaged?

A. Posterior cruciate ligament
B. Anterior cruciate ligament
C. Medial meniscus
D. Medial collateral ligament
E. Posterior capsule of the joint

4. A baseball pitcher was admitted to the emergency room with a traumatic axillary artery aneurism. During surgery the first part of the axillary had to be ligated, but distal blood flow to the upper limb is possible because of collateralization between which of the following vessels?

A. Anterior and posterior humeral circumflex arteries
B. Posterior humeral circumflex and deep femoral arteries
C. Lateral thoracic and subscapular arteries
D. Posterior humeral circumflex and subscapular arteries
E. Suprascapular and subscapular arteries

5. A 10-year-old boy falls on his outstretched hand. The physical exam shows that there is weakness in flexion of the distal phalanx of digits 4 and 5. Damage to which of the following carpal bones of the wrist could result in damage to the nerve that caused this motor deficit?

A. Trapezium
B. Capitate
C. Hamate
D. Lunate
E. Scaphoid

Please visit us at www.Groupinsiders.com

© DeVry/Becker Educational Development Corp. All rights reserved.

Chapters 10–11 Review Questions

6. An 8-year-old boy falls from a tree and damages the axilla on one side. He is able to extend the wrist and pronation of the forearm is normal, but flexion of the elbow and supination are significantly weakened. Where did the damage most likely occur?

A. Posterior division fibers of brachial plexus
B. Musculocutaneous nerve
C. Lateral and medial cords of brachial plexus
D. Radial nerve at lateral elbow
E. Posterior cord of brachial plexus

7. A patient presents with a very deep knife wound to the posterior surface of the arm three to four inches below the spine of the scapular. What structures may have been damaged?

A. Posterior cord and axillary artery
B. Radial nerve and deep brachial artery
C. Radial nerve and axillary nerve
D. Posterior circumflex humeral artery and axillary nerve
E. Axillary nerve and posterior circumflex humeral artery

8. A 10-year-old girl receives a superficial cut on the ventral surface of the radial side of her palm and requires sutures. A few days later, she returns to her physician complaining of diminishing hand function. Which of the following movements most likely would have been affected?

A. Flexion of the distal phalanx of digit 4
B. Extension of the distal phalanx of digits 4–5
C. Abduction of digits 2–5
D. Opposition of the thumb
E. Flexion of the MP joint of digits 3–4

9. A 16-year-old high school football player sustains a strong hit on the lateral surface of the knee that results in damage to a nerve at the neck of the fibula. Which of the following functions would be expected to be diminished in the player?

A. Sensory loss on the lateral side of the sole of the foot
B. Weakness of the gastrocnemius muscle
C. Sensory loss on the medial side of the ankle
D. Weakness of the tibialis anterior muscle
E. Weakness in plantar flexion of the foot

10. A 25-year-old man is admitted to the emergency room after experiencing a sharp pain in his leg after being kicked in his back during a soccer game. The physical exam indicates that plantar flexion is weakened on the affected side. Herniation of which of the following disks could be a cause of the injury?

A. L3 disk
B. L4 disk
C. L5 disk
D. S3 disk
E. S4 disk

Please visit us at www.Groupinsiders.com

© DeVry/Becker Educational Development Corp. All rights reserved.

Review Answers Chapters 10–11

1. The correct answer is B. The head and neck of the femur receive their primary blood supply from the medical circumflex femoral artery. The artery is a branch of the deep femoral artery and courses along the neck to reach the head of the femur.

2. The correct answer is C. The dorsalis pedis artery is the distal continuation of the anterior tibial artery. The anterior tibial artery courses in the anterior compartment of the leg where it can be damaged and result in a decreased pulse of the dorsalis pedis artery.

3. The correct answer is A. The anterior and posterior cruciate ligaments are responsible for preventing the tibia from moving anteriorly or posteriorly, respectively, underneath the femur. During the drawer test, a freely movable tibia in the posterior direction indicates a tear of the posterior cruciate ligament.

4. The correct answer is E. The scapular anastomosis occurs around the dorsal surface of the scapula and forms a collateralization between the suprascapular branch of the subclavian artery with the subscapular branch of the axillary artery.

5. The correct answer is C. The weakness of flexion of the distal phalanx of digits 4 and 5 is due to a deficit of the flexor digitorum profundus, which inserts on the distal phalanx. The ulnar nerve innervates the flexor digitorum muscle inserting on these digits. The ulnar nerve is often damaged with dislocation of the hamate bone.

6. The correct answer is B. Flexion of the elbow and part of supination are functions of the muscles in the anterior compartment of the arm. These muscles are innervated by the C5–C6 fibers of the musculocutaneous nerve.

7. The correct answer is B. A deep laceration on the posterior surface of the arm would cut through the triceps muscle and could possibly cut the radial nerve and the deep brachial artery in the radial groove on the posterior surface of the midshaft of the humerus.

8. The correct answer is D. A superficial cut on the radial side of the palm can lacerate the motor branch of the median nerve that crosses the hand and innervates the thenar group of muscles. One of the essential muscles of the thenar compartment is the opponens pollicis, which is responsible for opposition of the thumb.

9. The correct answer is D. The nerve damaged at the lateral aspect of the knee was the common fibular nerve. The nerve is often damaged with trauma to the lateral knee. Distal to the neck of the femur, the common fibular nerve divides into the deep fibular nerve (supplies muscles in the anterior compartment of the leg including the tibialis anterior muscle) and the superficial fibular nerve (supplies muscle in the lateral compartment of the leg). The superficial and deep fibular nerves provide sensory innervation to the dorsum of the foot.

10. The correct answer is C. Plantar flexion is a function of muscles in the posterior compartment of the leg and is innervated primarily by S1 and S2 fibers of the tibial nerve. The S1 fibers would be compressed by an L5 disk herniation.

Please visit us at www.Groupinsiders.com

© DeVry/Becker Educational Development Corp. All rights reserved.

1 Head and Neck Development

1.1 Pharyngeal Apparatus

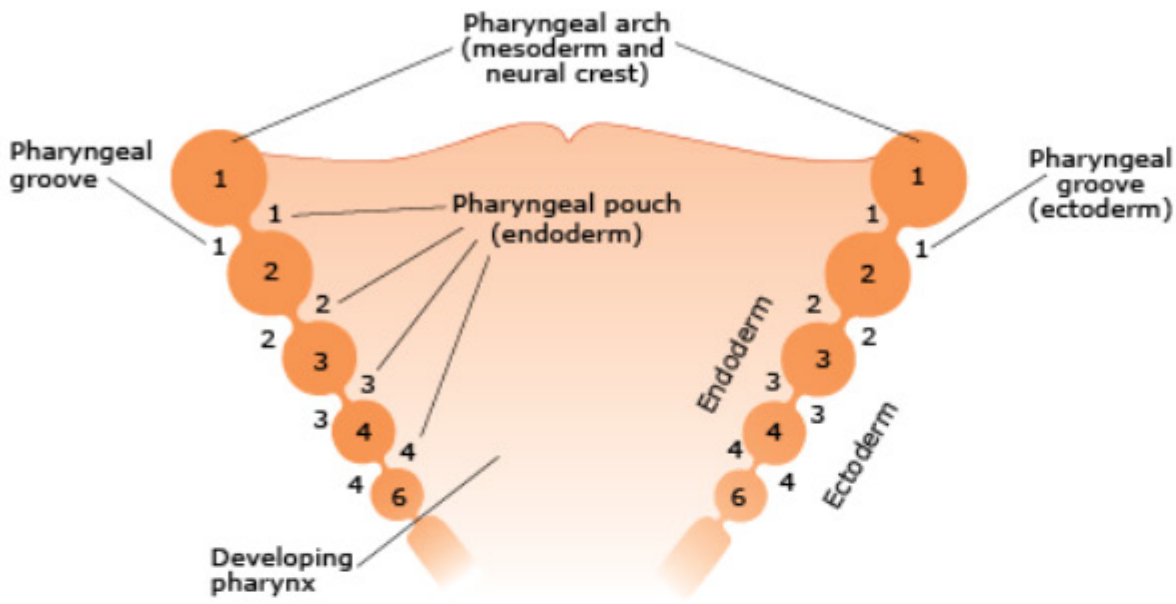

▲ **Figure 12–1.1A** Pharyngeal Apparatus: Frontal Section of Pharynx

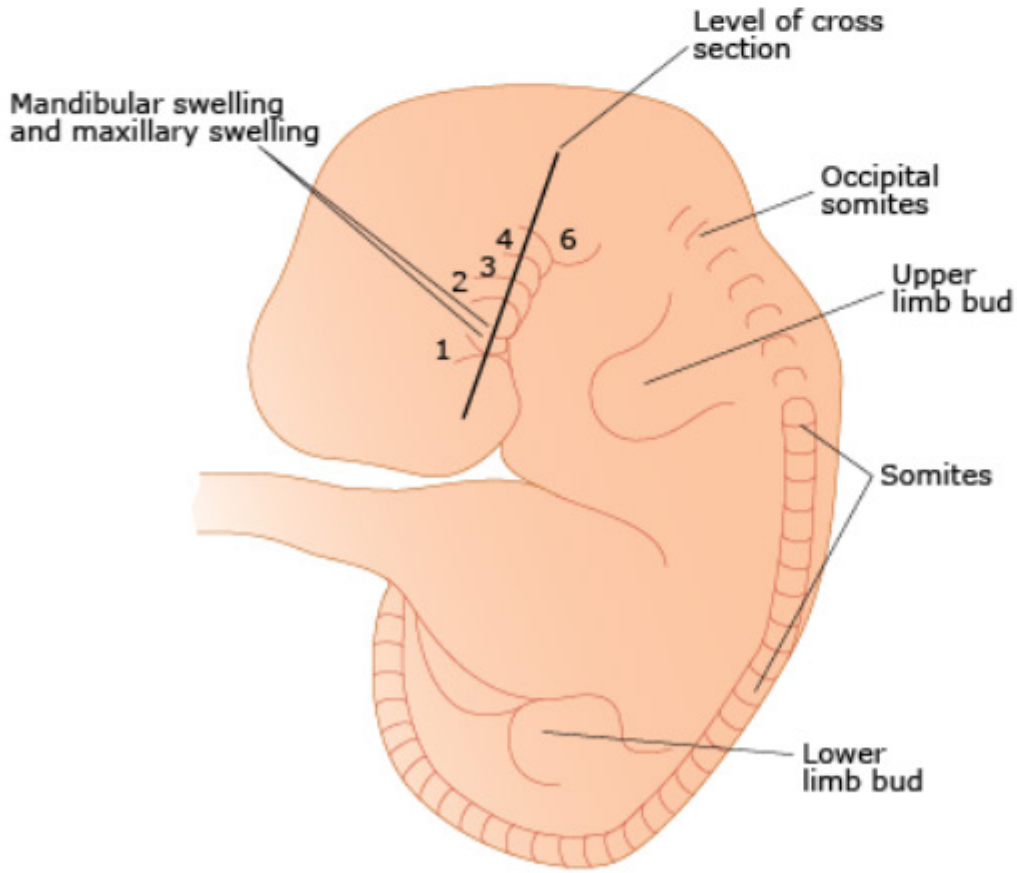

▲ **Figure 12–1.1B** Pharyngeal Apparatus

USMLE® Key Concepts

For Step 1, you must be able to:

- Identify the pharyngeal arches, pouches, and clefts, and their derivatives during development of the head and neck.
- Explain the development of the thyroid gland.
- Describe the mechanism of cleft lip and cleft palate.
- Identify the arrangement of meninges in the cranial cavity and the formation of dural venous sinuses.
- Explain intracranial venous flow and drainage of blood from the cranium.
- Describe the cavernous dural venous sinus and the cranial nerves involved in cavernous sinus thrombosis.

Please visit us at www.Groupinsiders.com

© DeVry/Becker Educational Development Corp. All rights reserved.

The *pharyngeal apparatus* is responsible for the development of most of the structures of the head and neck, and is formed by *pharyngeal arches*, *pharyngeal pouches*, and *pharyngeal grooves* (clefts). These structures develop during the fourth week at the lateral aspect of the developing pharynx.

- *Pharyngeal arches* (1, 2, 3, 4, 6) are composed of *mesoderm* and *neural crest* cells. The mesoderm of the arches forms *muscles* and *arteries* (aortic arches), and the neural crest cells contribute to the development of *bone* and *connective tissue*. Developing with each pharyngeal arch is a cranial nerve. The structures that develop from the arches are shown in Table 12–1.1A. Originally, there is a fifth pharyngeal arch, but it develops and regresses quickly, and does not form any structures.

▼Table 12–1.1A Structures Derived From Pharyngeal Components

Arch	Nerve	Muscles (Mesoderm)	Skeletal Structures (Neural Crest)	Aortic Arches (Mesoderm)
First (mandibular)	Mandibular nerve (CN V)	*Muscles of mastication:* • Masseter • Temporalis • Lateral pterygoid • Medial pterygoid Mylohyoid and anterior belly of digastric Tensor tympani Tensor veli palatini	Malleus Incus Mandible Maxilla	
Second (hyoid)	Facial (CN VII)	*Muscles of facial expression* Stapedius Stylohyoid Posterior belly of digastric	Stapes Styloid process Lesser horn of hyoid Upper body of hyoid bone	
Third	Glossopharyngeal (CN IX)	Stylopharyngeus	Greater horn of hyoid Lower part of body of hyoid bone	Right and left common carotid arteries Right and left internal carotid arteries
Fourth	Superior laryngeal branch of vagus (CN X)	Cricothyroid Levator veli palatini (soft palate) Pharyngeal muscles (5)	Thyroid cartilage	Right subclavian artery (right arch) Arch of aorta (left arch)
Sixth	Recurrent laryngeal branch of vagus (CN X)	Laryngeal muscles Striated muscles of esophagus	Laryngeal cartilages	Right and left pulmonary arteries Ductus arteriosus (left 6th arch)

The seven **muscles of the orbit** innervated by CN III, IV, and VI and the **muscles of the tongue** (XII) develop from mesoderm of upper occipital somites (somitomeres).

Please visit us at www.Groupinsiders.com

© DeVry/Becker Educational Development Corp. All rights reserved.

- *Pharyngeal pouches* (1, 2, 3, 4) are formed by four evaginations of *endoderm* lining the lateral wall of the developing pharynx. Structures that develop from the pouches are organized in Table 12–1.1B and Figure 12–1.1C.

▼Table 12–1.1B Adult Structures Derived From the Fetal Pharyngeal Pouches

Pouch	Adult Derivatives
1	Epithelial lining of auditory tube and middle ear cavity
2	Epithelial lining of crypts of palatine tonsil
3	Inferior parathyroid (IP) gland Thymus (T)
4	Superior parathyroid (SP) gland Ultimobranchial body (UB)*

*Neural crest cells migrate into the ultimobranchial body to form parafollicular (C) cells of the thyroid.

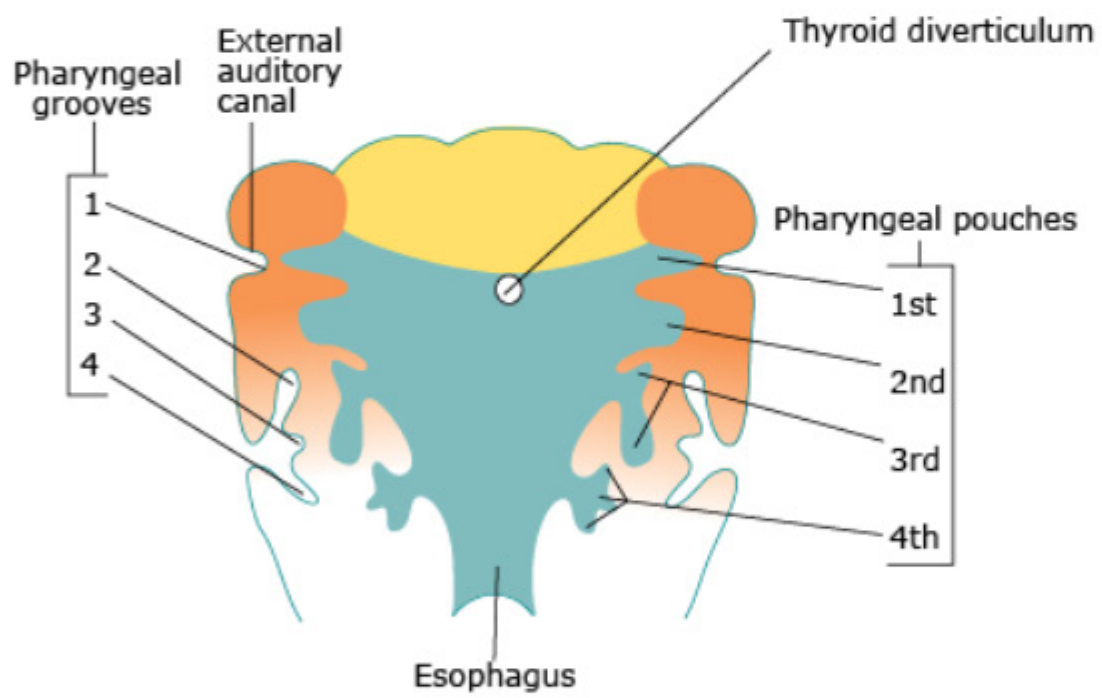

▲Figure 12–1.1C Frontal Section of Pharynx

- *Pharyngeal grooves* (1, 2, 3, 4) are formed by four invaginations of ectoderm. The derivatives of the grooves are shown in Figure 12–1.1C.

Please visit us at www.Groupinsiders.com

© DeVry/Becker Educational Development Corp. All rights reserved.

1.2 Development of the Thyroid Gland

The *thyroid gland* develops (Figure 12–1.2) from *a median endodermal thickening in the floor of the developing pharynx* (*not* endoderm of the pouches). The endoderm bud forms a *thyroid diverticulum* at a site called the *foramen cecum* in the floor of the pharynx. The thyroid diverticulum descends inferiorly via the *thyroglossal duct* in the anterior midline of the neck to the area where the thyroid gland envelops the upper tracheal rings. The thyroglossal duct later degenerates. Ectopic thyroid gland tissue can be located anywhere along the route of the thyroglossal duct.

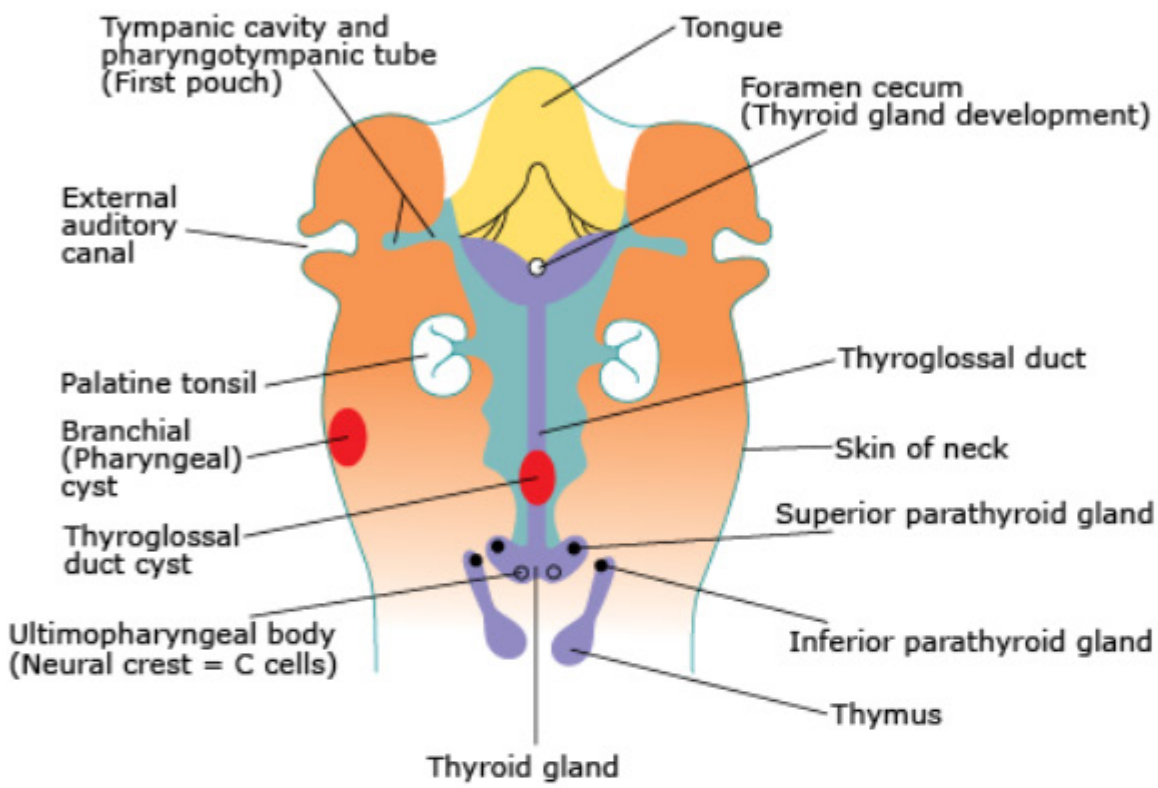

▲ **Figure 12–1.2** Pharyngeal Apparatus

Please visit us at www.Groupinsiders.com

© DeVry/Becker Educational Development Corp. All rights reserved.

Clinical Application

First Arch Syndrome

First arch syndrome consists of a group of various facial anomalies resulting from abnormal development of the first pharyngeal arch. The anomalies involve the eyes, ears, mandible, and palate, and are due to the failure of the migration of neural crest cells into the arch during the fourth week. Treacher Collins syndrome and Pierre Robin syndrome are examples.

DiGeorge Syndrome

DiGeorge syndrome is caused by the failure of pharyngeal pouches 3 and 4 to differentiate due to a failure of proper neural crest cell migration. Infants are born without a thymus and parathyroid glands with various types of facial anomalies resembling first arch syndrome. The newborns are immune deficient.

Cervical Cysts

Fluid-filled *cervical cysts* can occur at several locations on the neck:

- **Branchial (Pharyngeal) Cysts:** These cysts are remnants of parts of the second or third pharyngeal grooves (clefts) that did not close completely and later became fluid-filled cysts. They are typically located at the *lateral neck* along the *anterior border of the sternocleidomastoid muscle*.

  A branchial cyst may develop into a *fistula* and form a patent opening from the external surface of the neck to the pharyngeal region internally.

- **Thyroglossal Duct Cysts:** These are fluid-filled cysts that can occur anywhere along the course of the thyroglossal duct and are remnants of parts of the thyroglossal duct that did not atrophy. These cysts are located at the *anterior midline* of the *neck*.

Please visit us at www.Groupinsiders.com

© DeVry/Becker Educational Development Corp. All rights reserved.

1.3 Development of the Tongue

The gross anatomy and the development of the tongue are divided into two main parts: an anterior two-thirds and a posterior one-third part, which explains the innervation of the different parts of the tongue.

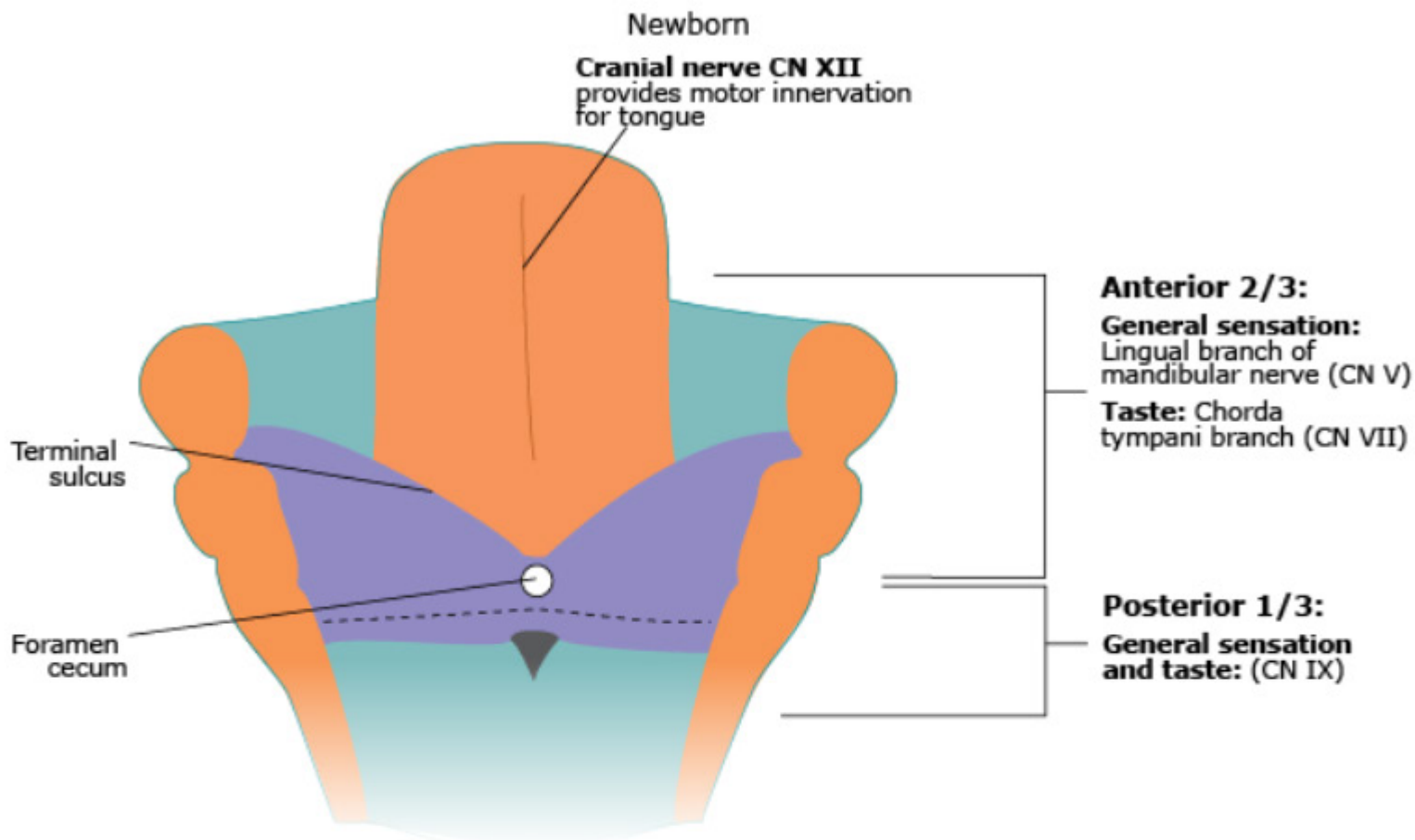

▲ **Figure 12–1.3** Tongue Development

- The *anterior two thirds* of the tongue develops primarily from the mesoderm of the first pharyngeal arch and secondarily from the second pharyngeal arch. Thus, the innervation of the anterior two thirds of the tongue is provided from two sources: (1) *General sensory innervation* from the mucosa of the tongue is from the *lingual branch of the mandibular nerve* (the nerve of the first arch) and (2) *taste* from the anterior thirds mucosa is provided by the *chorda tympani branch of the facial nerve*.
- The *posterior one third* of the tongue develops primarily from the mesoderm of the third pharyngeal arch. The *glossopharyngeal nerve* (the nerve of the third pharyngeal arch) provides both the *general sensation* and *taste functions* for the posterior one third of the tongue.

Most of the skeletal muscles of the tongue develop from mesoderm that migrated from the upper *occipital somites* and are innervated by the *hypoglossal nerve*.

Please visit us at www.Groupinsiders.com

© DeVry/Becker Educational Development Corp. All rights reserved.

1.4 Development of the Face and Palate

1.4.1 Face

The face develops from *five prominences* formed primarily by the *mesoderm* and *neural crest cells* of the *first pharyngeal arch*. There are *two maxillary* and *two mandibular prominences* and a single *frontonasal prominence*.

▼Table 12–1.4 Structures Contributing to Formation of the Face

Prominence	Structural Formed
Frontonasal[1]	Forehead, bridge of nose, and medial and lateral nasal prominences
Maxillary	Cheeks, lateral portion of upper lip
Medial nasal prominence	Philtrum of upper lip and intermaxillary segment
Lateral nasal prominence	Alae of nose
Mandibular	Lower lip and lower face

[1]The frontonasal prominence is a single unpaired structure; the other prominences are paired.

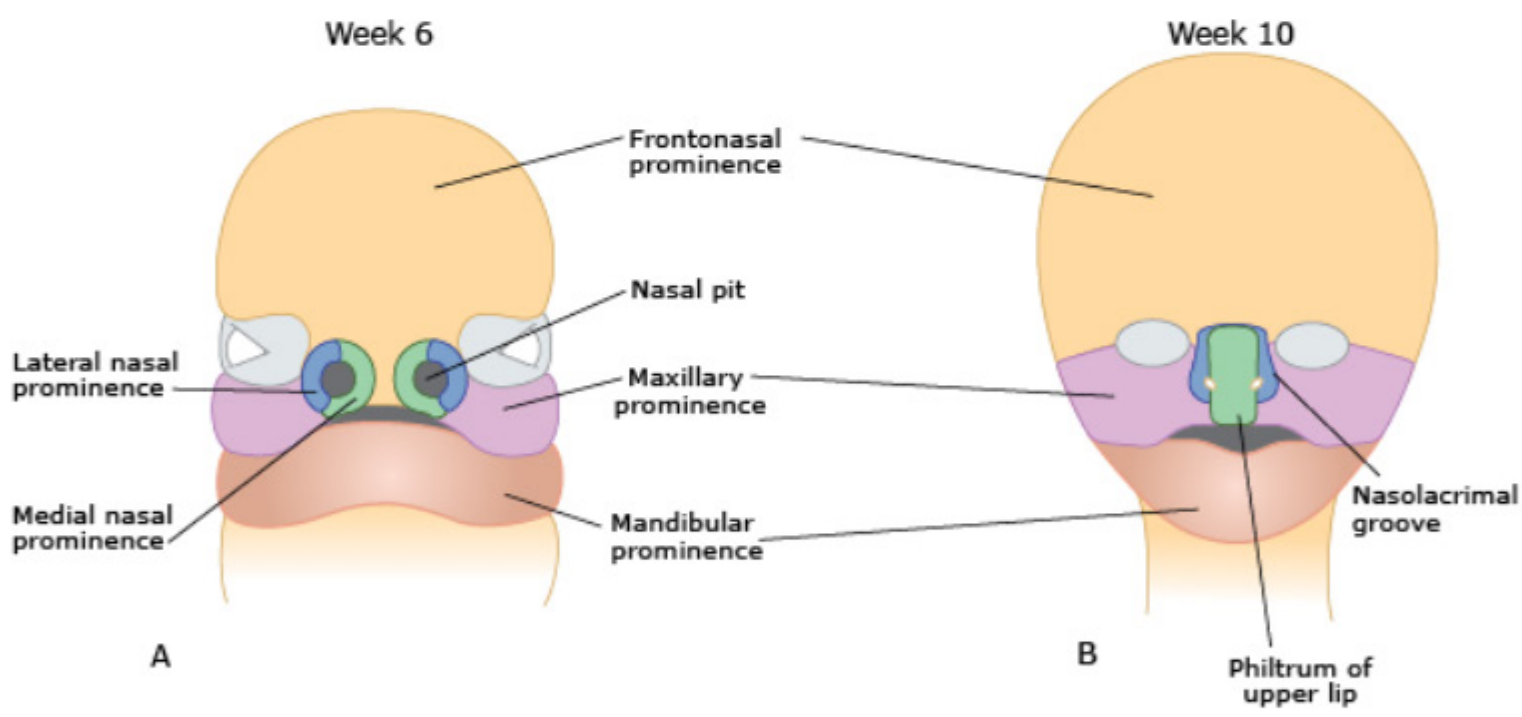

▲Figure 12–1.4A Development of Face

- *The mandibular prominences* fuse in the midline to form the lower face and lower lip. *The frontonasal prominence* forms the forehead and upper face above the orbits.
- *The medial* and *lateral nasal prominences* develop from the ventrolateral parts of the frontonasal prominence.
- The lateral nasal prominences form the ala of the nose.
- *Medial nasal prominences* fuse in the midline to form the *philtrum* of the *upper lip* and the *intermaxillary segment*.
- *Maxillary prominences* migrate medially and fuse with the *medial nasal prominences* to form the upper lip and the secondary palate.

Please visit us at www.Groupinsiders.com

© DeVry/Becker Educational Development Corp. All rights reserved.

1.4.2 Hard Palate

The hard palate develops by the fusion of the *intermaxillary segment (primary palate formed by the medial nasal prominences)* with the *palatine shelves (secondary palate formed from the maxillary prominences)*, and also by the fusion of the palatine shelves with each other at the midline of the hard palate.

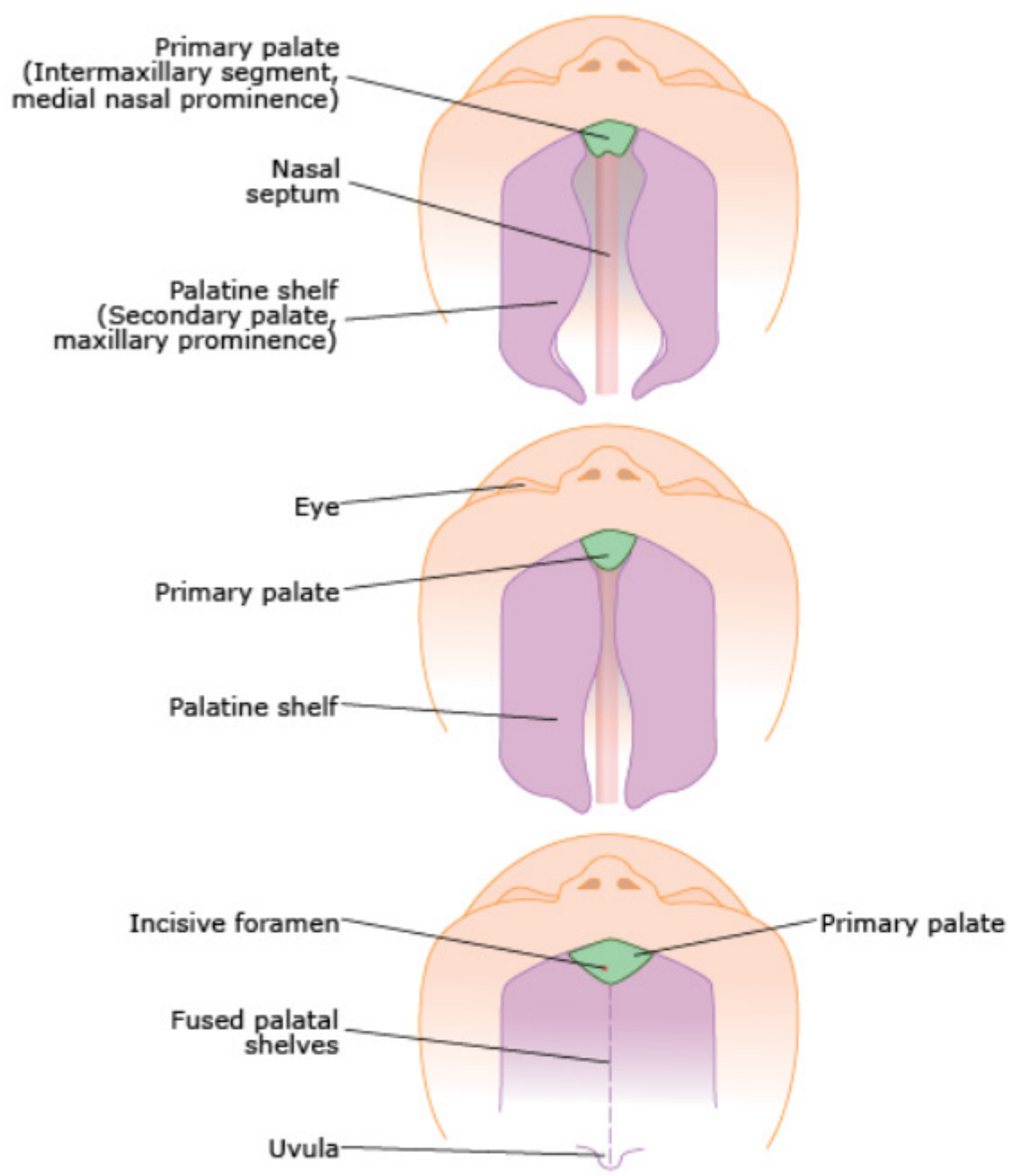

▲ **Figure 12–1.4B** Development of Hard Palate

Cleft Lip

Results from the failure of the *maxillary prominences* to fuse with the *medial nasal prominences*; can be unilateral or bilateral.

Cleft Palate

Cleft palate is caused by the failure of the *palatine shelves* to fuse with each other at the midline or failure of the palatine shelves to fuse with the *primary palate* or both. A cleft palate may also include a cleft lip.

Please visit us at www.Groupinsiders.com

© DeVry/Becker Educational Development Corp. All rights reserved.

2 Blood Vessels of the Head and Neck

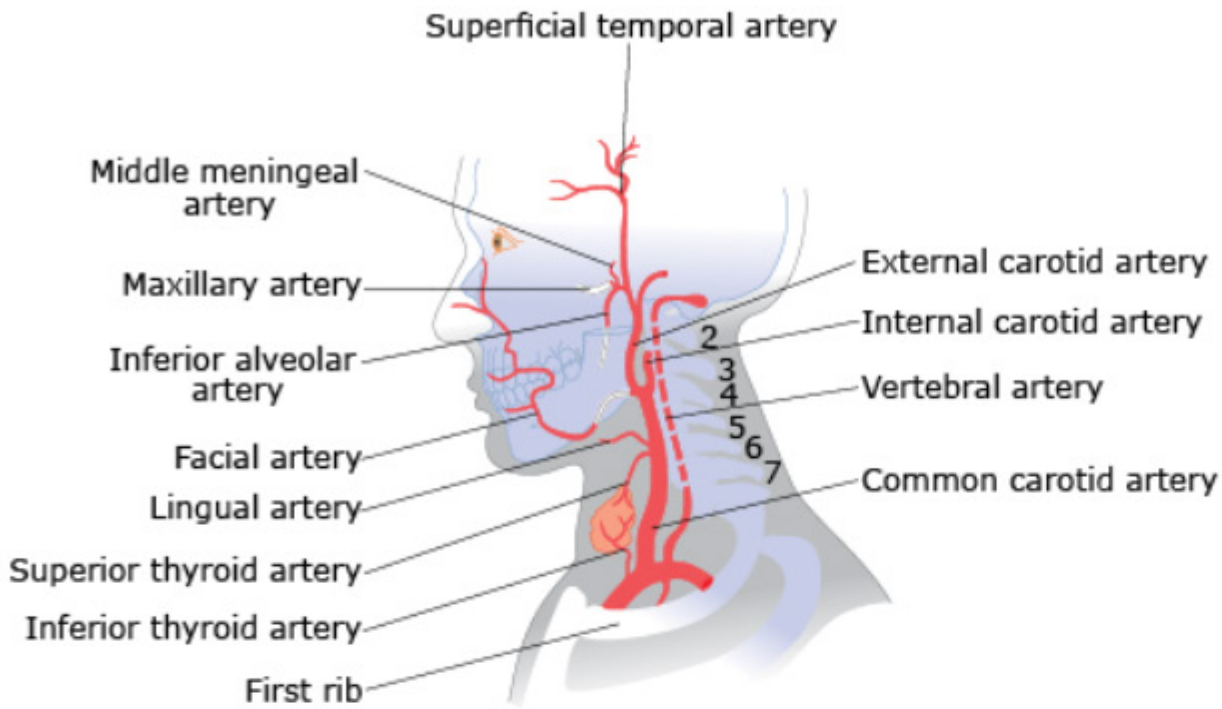

▲ **Figure 12–2.1** Blood Supply to Head and Neck

2.1 Subclavian Artery

The *right subclavian artery* is a branch of the brachiocephalic trunk, and the *left subclavian artery* is a branch of the aortic arch. The major branches of the subclavian arteries are the:

- **Vertebral Artery:** One of two blood supplies to the brain and brainstem.
- **Thyrocervical Trunk:** Supplies thyroid gland and structures at shoulder.
- **Suprascapular Artery:** Forms a collateral circulation around the scapula with the subscapular branch of the axillary artery.
- **Internal Thoracic Artery:** Supplies the anterior chest wall.

2.2 Common Carotid Artery

The common carotid artery ascends the carotid sheath in the neck and divides into the *internal* and *external* carotid arteries at the level of the upper border of the thyroid cartilage. The internal carotid artery remains in the carotid sheath and ascends to the base of the skull. The external carotid artery leaves the carotid sheath for its distribution of eight branches.

- **Internal Carotid Artery:** Second major blood supply to brain.
- **External Carotid Artery:** Major branches include:
  - **a. Superior Thyroid:** Supplies thyroid gland.
  - **b. Lingual Artery:** Supplies floor of mouth and tongue.
  - **c. Facial Artery:** Supplies superficial face.
  - **d. Maxillary Artery:** Provides blood supply to the deep face, including the middle meningeal artery, which passes through foramen spinosum to supply the dura mater in the cranial cavity.

Important Concept

The vertebral and internal carotid arteries provide intracranial blood supply to the brain.

Laceration of the middle meningeal branch of the maxillary artery in the cranial cavity results in epidural hematoma.

Please visit us at www.Groupinsiders.com

© DeVry/Becker Educational Development Corp. All rights reserved.

3 Foramina in the Skull

The foramina of the skull and the major structures that pass through them are shown in Figures 12–3.0A and 12–3.0B.

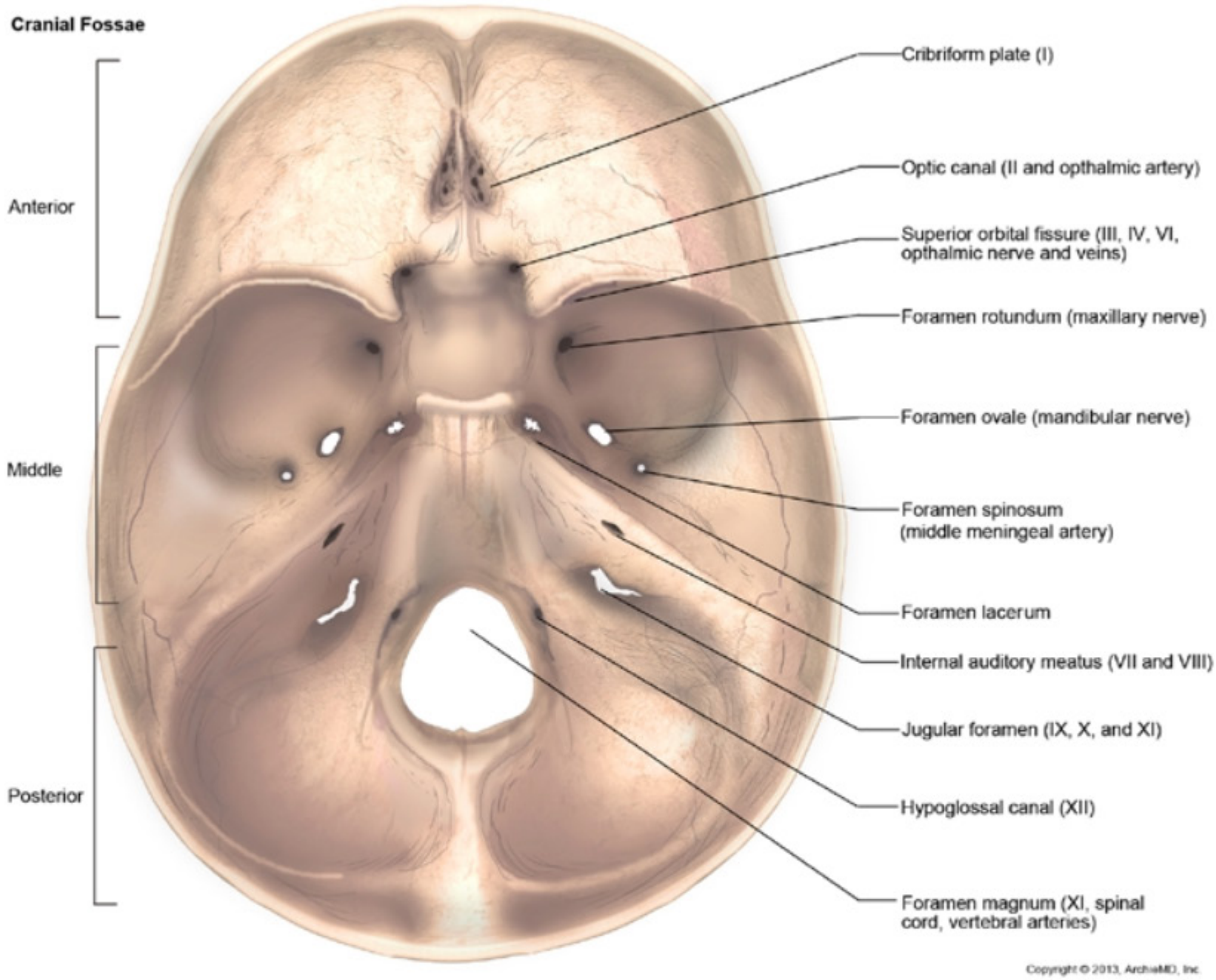

▲ **Figure 12–3.0A** Cranial Cavity

Please visit us at www.Groupinsiders.com

© DeVry/Becker Educational Development Corp. All rights reserved.

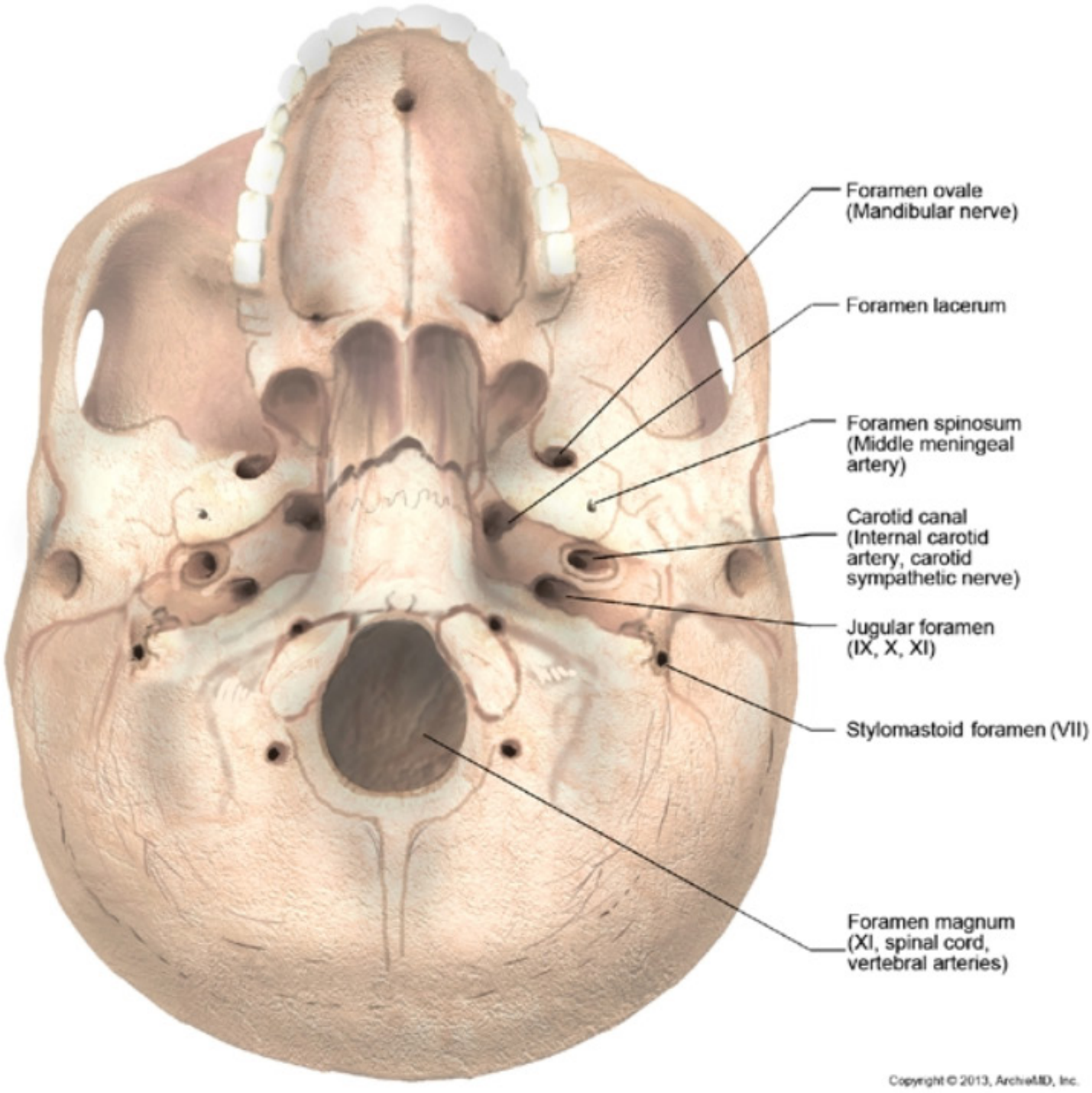

▲ **Figure 12–3.0B** Base of Skull

Please visit us at www.Groupinsiders.com

© DeVry/Becker Educational Development Corp. All rights reserved.

4 Meninges of the Brain

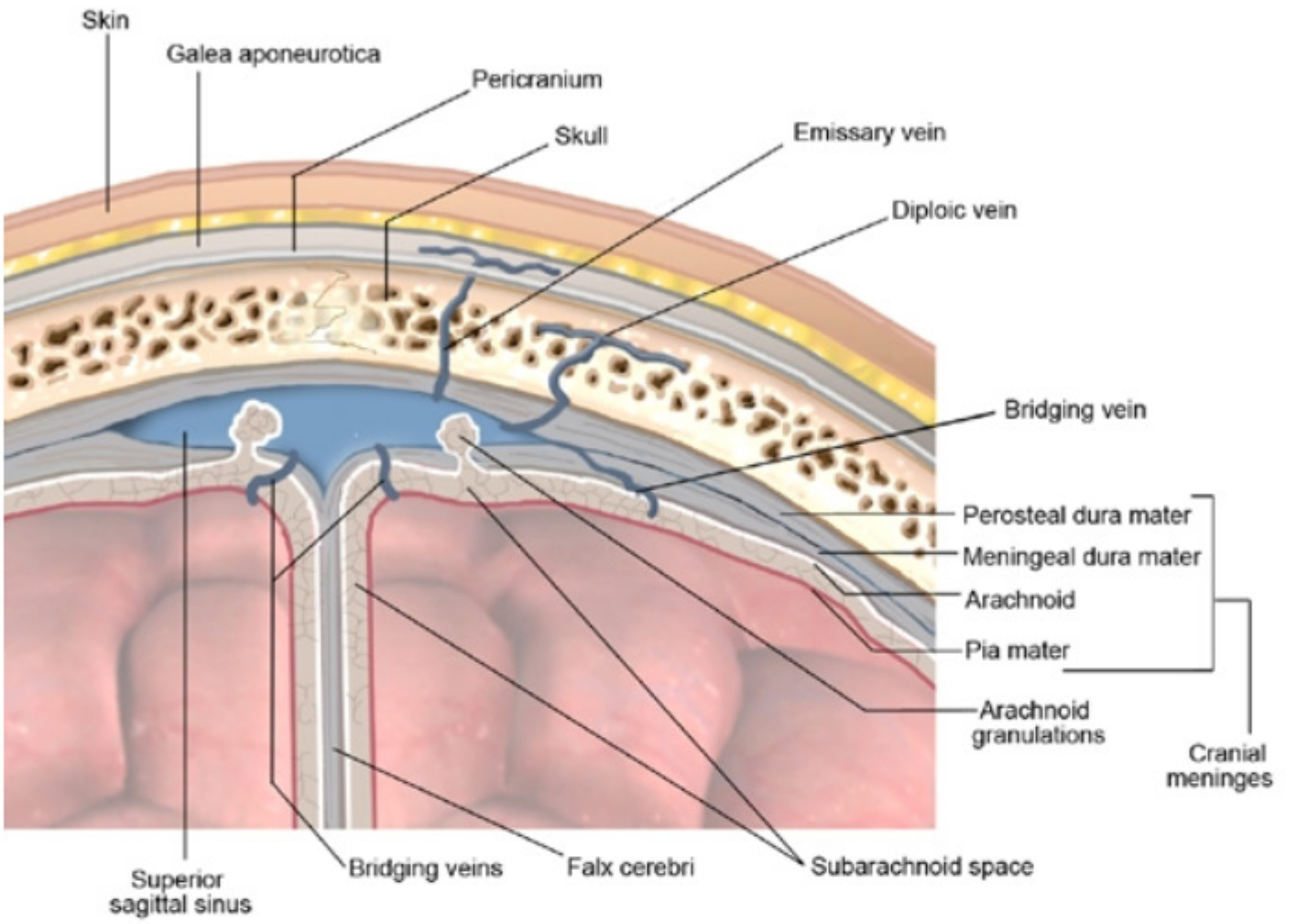

▲ **Figure 12–4.0** Frontal Section of Cranial Cavity

The brain is covered by three layers of *meninges (pia mater, arachnoid, and dura mater)*, which help to protect the CNS.

- The *pia mater* of the brain is the thin, innermost delicate covering that is tightly applied to the brain surface. It follows the contours of the brain and encloses the blood vessels on its surface.
- The *arachnoid layer* is the spider-like, transparent middle meningeal layer that is opposed to the inner surface of the dura mater by the pressure in the subarachnoid space. The arachnoid is located between the dura mater and the pia mater in the subarachnoid space, which is filled with cerebrospinal fluid (CSF). Tufts of arachnoid (*arachnoid granulations*) project into the superior sagittal dural venous sinus to allow cerebrospinal fluid to return to the systemic circulation.
- The *dura mater* is the strong, double-layered membrane that forms the outermost meningeal layer. The cranial dura mater consists of two layers: *meningeal dura* and *periosteal dura*. The two layers of dura mater are fused together for most of their extent, but at certain points the layers separate and form the dural venous sinuses. The dura mater receives extensive sensory innervation by branches of the three divisions of CN V.

Please visit us at www.Groupinsiders.com

© DeVry/Becker Educational Development Corp. All rights reserved.

- The *periosteal layer of dura* is the outer layer of dura that is opposed to the inner surface of the bones of the skull and serves as the periosteum.
- The *meningeal layer of dura* is the inner membrane that forms the true dura mater. This layer is continuous with the spinal dural through the foramen magnum. When the meningeal layer separates from the periosteal layer to form the dural venous sinuses, the meningeal layer forms several internal foldings or duplications that subdivide the cranial fault into smaller compartments: *falx cerebri, tentorium cerebella*, and *diaphragma sellae*.

4.1 Meningeal Spaces Related to Intracranial Hemorrhages

Intracranial hemorrhages can occur in several meningeal spaces and are summarized below.

- *Epidural space* is a potential space located between the inner surface of the bones of the skull and the periosteal layer of dura mater. The epidural space contains distributions of the middle meningeal artery that can tear and produce *epidural hematomas*.
- *Subdural space* is a potential space located between the arachnoid layer and the meningeal layer of dura mater. This space is crossed by the bridging veins that can tear and cause *subdural hematomas*.
- *Subarachnoid space* is located between the pia mater and the arachnoid, and contains the cerebrospinal fluid. The central nervous system is surrounded by the subarachnoid space and is bathed by the cerebrospinal fluid (CSF) that protects and nourishes the nervous system. *Subarachnoid hematomas* can result from berry aneurysms.

Please visit us at www.Groupinsiders.com

© DeVry/Becker Educational Development Corp. All rights reserved.

5 Dural Venous Sinuses

Dural venous sinuses are endothelial-lined, vein-like spaces formed when the periosteal and meningeal layers of the dura mater separate at various sites within the cranial cavity. Most of the sinuses are found within the two largest duplications of dura (falx cerebri and tentorium cerebelli) formed by the infoldings of the meningeal layer of dura.

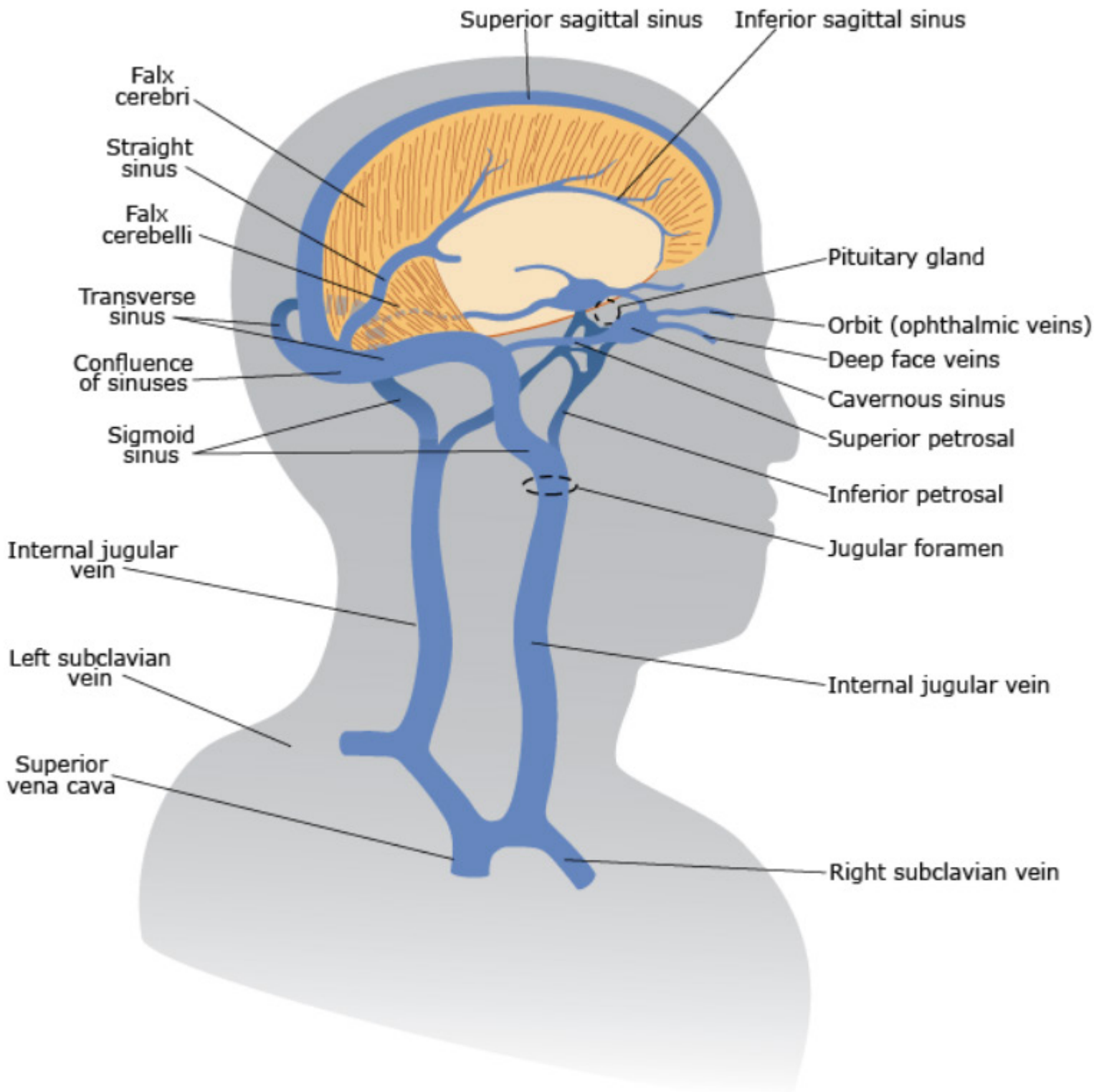

▲ **Figure 12–5.0** Dural Venous Sinuses

The dural venous sinuses receive venous drainage from intracranial tissues and drainage of cerebrospinal fluid via the arachnoid granulations. All of this venous flow ultimately drains through the sinuses into the *internal jugular vein* at the jugular foramen.

Please visit us at www.Groupinsiders.com

© DeVry/Becker Educational Development Corp. All rights reserved.

The major structures draining into the sinuses are the:

- **Bridging Veins:** Formed by veins draining the cerebrum and cerebellum. These veins cross the subarachnoid and subdural spaces to drain into the sinuses.
- **Emissary Veins:** Drain through the flat bones of the skull and connect extracranial veins with the intracranial dural sinuses.
- **Meningeal Veins:** Drain the meninges.
- **Arachnoid Granulations:** Drain CSF from the subarachnoid space into the dural sinuses.

The major dural venous sinuses are the:

- Superior sagittal sinus
- Inferior sagittal sinus
- Straight sinus
- Confluence of the sinuses
- Transverse sinus
- Sigmoid sinus
- Cavernous sinus
- Superior and Inferior petrosal sinuses

5.1 Cavernous Sinus

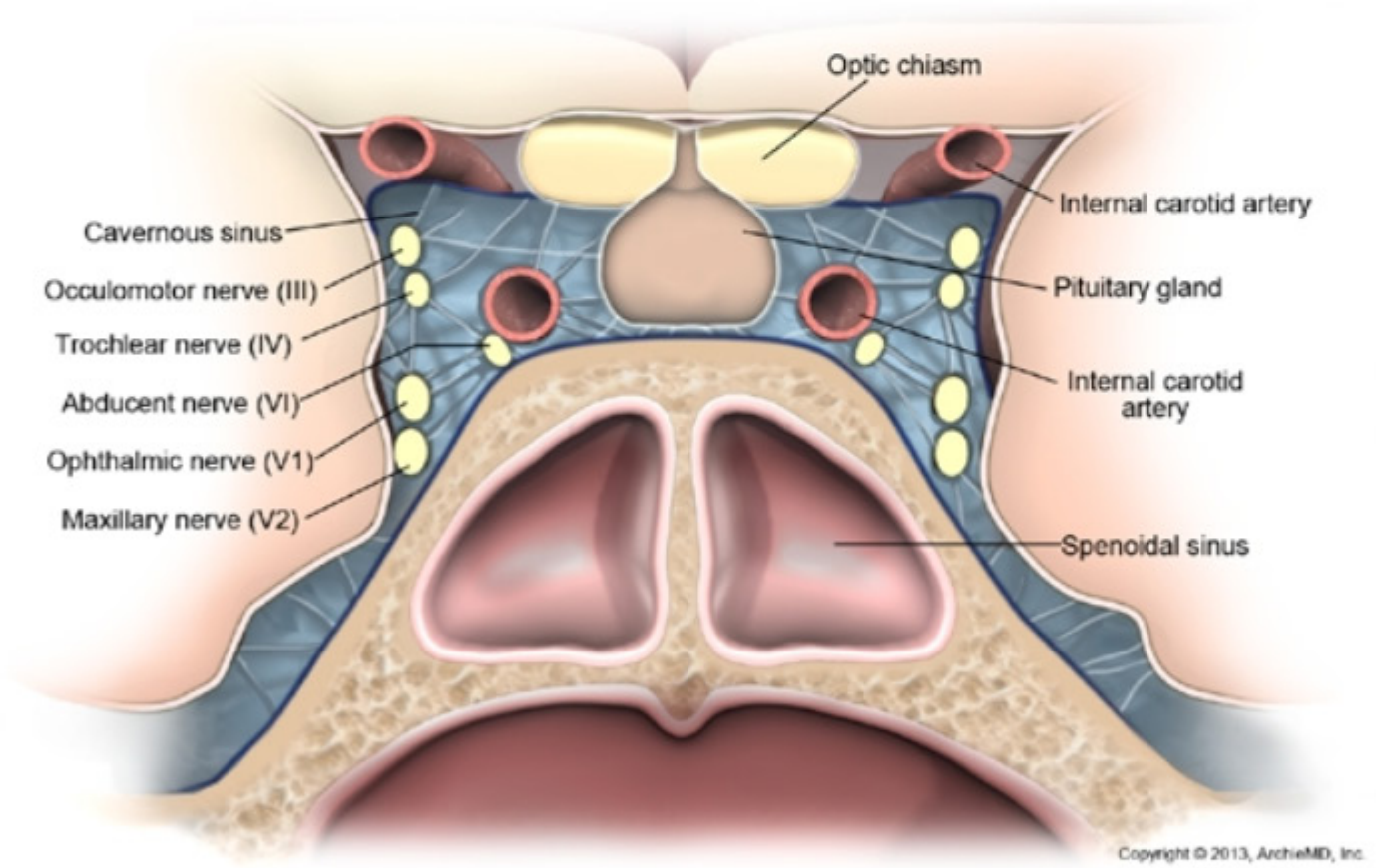

▲ **Figure 12–5.1** Cavernous Sinus

The *cavernous sinuses* are clinically important because of their relationship to cranial nerves and involvement with infections. The cavernous sinuses are found on either side of the body of the sphenoid bone between the meningeal and periosteal layers of dura mater.

Please visit us at www.Groupinsiders.com

© DeVry/Becker Educational Development Corp. All rights reserved.

- The sinuses receive venous flow from the *deep veins of the face* and the *ophthalmic veins* (drain the orbit via the superior orbital fissure).
- Venous flow drains posteriorly from the cavernous sinus via the superior petrosal and inferior petrosal sinuses into either the transverse sinus or the junction of the sigmoid sinus with the internal jugular vein.
- The cavernous sinus' clinical importance derives from the four cranial nerves located in its lateral wall *(III, IV, ophthalmic, and maxillary divisions of V)* and one *cranial nerve (VI)*, plus the *internal carotid artery* located centrally in the sinus.

Clinical Application

Cavernous Sinus Thrombosis

Thrombi can form within the cavernous sinus as a result of bacterial infection. Infections can spread from the skin of the face via veins draining through the orbit into the sinus or from infections that spread through veins draining the deep face.

- Thrombi block blood flow with swelling and increased pressure in the sinus.
- Pressure in the sinus can damage the three *ocular cranial nerves* (III, IV, and VI).
- Cranial nerve VI is affected first, producing internal strabismus and diplopia. Later, all three of the ocular nerves will be affected, with total paralysis of all six ocular muscles and the levator palpebrae muscle (ptosis).
- Sensory deficits occur on the areas of the face supplied by the *ophthalmic* and *maxillary nerves*.

Please visit us at www.Groupinsiders.com

© DeVry/Becker Educational Development Corp. All rights reserved.

Chapter 12 Review Questions

1. A 12-year-old boy presents with a smooth, fluid-filled swelling on the lateral surface of his neck that has enlarged slowly over the last few weeks. The physician notices that it is without pain or inflammation and remains stationary when the boy moves his neck or swallows. Which of the following is the most likely cause of the swelling?

A. Remnant of the first pharyngeal cleft
B. Lateral cyst of the larynx
C. Fluid collecting in the thyroglossal cyst
D. Remnant of the second pharyngeal cleft
E. Swollen lymph nodes along the carotid sheath

2. A newborn male has a noticeably small mandible. A CT scan and physical exam reveal hypoplasia of the mandible, a cleft palate, and defects of position of the eyes and ears. Abnormal development of which of the following structures will most likely produce these findings?

A. First pharyngeal arch
B. Second pharyngeal arch
C. Sixth pharyngeal arch
D. Fourth pharyngeal pouch
E. Fifth pharyngeal pouch

Please visit us at www.Groupinsiders.com

© DeVry/Becker Educational Development Corp. All rights reserved.

Review Questions Chapter 12

3. A 10-year-old female develops a cavernous sinus infection following a severe skin infection on the skin of her cheek. The female has an elevated temperature and diplopia. Which of the following is the most likely route for the spread of bacteria to the cavernous sinus?

A. Foramen ovale
B. Ophthalmic vein
C. Jugular foramen
D. Maxillary vein
E. Superior sagittal sinus

4. A newborn presents with a cleft lip but with normal development of the hard palate. Which of the following facial primordia failed to fuse and resulted in the cleft?

A. Medial and lateral nasal prominences
B. Mandibular and the medial nasal prominences
C. Maxillary and mandibular prominences
D. Mandibular and the frontonasal prominences
E. Maxillary and medial nasal prominences

5. A patient presents with a progressive degeneration of the motor fibers that innervate the muscles that close the eyelids. Which additional muscle may also show weakness with the progressive nerve lesion?

A. Stapedius
B. Stylopharyngeus
C. Masseter
D. Laryngeal muscles
E. Uvula

Please visit us at www.Groupinsiders.com

© DeVry/Becker Educational Development Corp. All rights reserved.

Chapter 12 Review Questions

6. A CT scan indicates a tumor compressing the jugular foramen. Which of the following functions would the physician expect to remain normal?

A. Movements of the vocal folds
B. Elevating the corner of the mouth
C. Swallowing reflex
D. Turning head from side to side
E. Sensory innervation of laryngeal mucosa

7. A newborn presents with facial and cardiovascular anomalies and undergoes genetic analysis, which shows a defect of chromosome 22. The defect is identified as DiGeorge syndrome with absence of thymus. Which of the following structures is primarily affected?

A. First pharyngeal arch
B. Sixth pharyngeal arch
C. First pharyngeal cleft (groove)
D. Second pharyngeal pouch
E. Third pharyngeal pouch

Please visit us at www.Groupinsiders.com

© DeVry/Becker Educational Development Corp. All rights reserved.

Review Answers Chapter 12

1. The correct answer is D. A painless cyst located on the lateral side of the neck would be typical of a pharyngeal cleft that did not close completely and, later in life, filled with fluid. These usually are located along the margin of the sternocleidomastoid muscle.

2. The correct answer is A. The severe facial deformities described in this individual represent failure of neural crest cells to migrate into the first pharyngeal arch, which is responsible for much of facial structure development.

3. The correct answer is B. The bacterial infection from the cheek was carried by veins into the orbit, where they were picked up by the ophthalmic veins. The ophthalmic veins leave the orbit through the superior orbital fissure and drain into the cavernous sinus.

4. The correct answer is E. The upper lip is formed by the fusion of the medial nasal prominence (forms the philtrum of the upper lip) and the maxillary prominence (forms the lateral part of the upper lip).

5. The correct answer is A. The muscles that close the eye are part of the group of facial expression muscles that are innervated by the seventh cranial nerve. This group of muscles develops from the mesoderm of the second pharyngeal arch, which is involved in the muscle degeneration described in the question. Of the muscles listed, the stapedius is the only one that also develops from the second pharyngeal arch.

6. The correct answer is B. The tumor at the jugular foramen would compress cranial nerves IX, X, and XI that pass through the foramen. All functions listed are provided by these nerves, except the muscles that move the mouth are innervated by the seventh cranial nerve.

7. The correct answer is E. The endoderm lining the third pharyngeal pouch gives rise to the inferior parathyroid glands and the thymus. The third and fourth pharyngeal pouches are involved in DiGeorge syndrome.

Please visit us at www.Groupinsiders.com

© DeVry/Becker Educational Development Corp. All rights reserved.

Unit 3

Neuroscience

Please visit us at www.Groupinsiders.com

Please visit us at www.Groupinsiders.com

CHAPTER 13 Introduction and Embryology of the Nervous System

1 Overview of the Nervous System

1.1 Organization of the Nervous System

The nervous system is divided structurally into the *central nervous system* (CNS) and the *peripheral nervous system* (PNS). The CNS integrates information between peripheral and central systems, and maintains overall control of the nervous system. The PNS transfers sensory and motor signals to and from the CNS.

1.1.1 The Peripheral Nervous System

The *peripheral nervous system* consists of 12 pairs of cranial nerves, 31 pairs of spinal nerves, ganglia, and autonomic nerves.

- **Cranial nerves:** Twelve pairs of cranial nerves attach to different parts of the CNS in the cranial cavity to supply motor and sensory innervation for structures in the head and autonomic innervation to viscera in the neck, thorax, and foregut and midgut of the abdomen.
- **Spinal nerves:** There are 31 pairs of spinal nerves that attach to the 31 spinal cord segments and supply motor and sensory innervation for the trunk and limbs.
- **Ganglia:** Ganglia are an organized collection of neuronal cell bodies in the PNS that are associated with spinal nerves and some of the cranial nerves. The ganglia of the PNS develop from neural crest cells. There are two types of ganglia: *sensory* and *motor*.
  - *Sensory ganglia* contain cell bodies of pseudounipolar (or unipolar) sensory neurons. These are the primary afferent neurons of the typical sensory pathway.
  - *Motor (autonomic) ganglia* contain cell bodies of postganglionic motor neurons of the autonomic nervous system (ANS).

1.1.2 The Central Nervous System

- The *central nervous system* consists of brain structures in the cranial cavity and spinal cord, and parts of the autonomic nervous system. The CNS is arranged into two parts:
  1. **Gray matter:** Consists primarily of neuronal cell bodies, dendrites, and glial cells.
  2. **White matter:** Consists of glial cells and axons that are organized into long tracts, peduncles, fasciculi, or lemnisci.

  Note: In the CNS, an organized collection of neuronal cell bodies is referred to as a *nucleus*.

USMLE® Key Concepts

For Step 1, you must be able to:

- Explain the basic organization and divisions of the nervous system.
- Describe the early development of the nervous system (neurulation) and the role of neuroectoderm and neural crest cells in development.
- Identify the primary and secondary vesicles of the neural tube and their adult derivatives.
- Describe the major defects of nervous system development.
- Explain the sympathetic pathway of the ANS to the head and identify the lesions resulting in Horner syndrome.

Please visit us at www.Groupinsiders.com

© DeVry/Becker Educational Development Corp. All rights reserved.

1.2 Functional Classification of the Nervous System

- The nervous system can also be divided functionally into *somatic* and *visceral nervous systems*:
  - *Somatic pathways* primarily mediate somatic functions at the conscious level: (1) innervation of skeletal muscles and (2) conscious sensations from peripheral receptors in skin, muscles, tendons, and joint capsules.
  - In contrast, *visceral pathways* of the ANS primarily mediate involuntary motor (to smooth and cardiac muscle and glands) and sensory innervation of visceral structures.
- Both the somatic and visceral systems use *efferent (motor)* and *afferent (sensory) neurons*.

Please visit us at www.Groupinsiders.com

© DeVry/Becker Educational Development Corp. All rights reserved.

2 Embryology of the Nervous System

The development of the nervous system is complex. Its development from *ectoderm* begins in the third week, immediately following gastrulation, and continues for some time after birth.

2.1 Neurulation and Formation of the Neural Tube

Neurulation (Figure 13–2.1A) is the process involved in the formation of the neural plate (neuroectoderm), closure of the neural tube, and early development of the nervous system. The following is a brief outline of major neurulation events:

- The *notochord* induces the dorsal midline surface ectoderm to form the *neural plate* (neuroectoderm). The notochord develops from epiblast cells and forms a central axial rod in the midline of the embryonic disk.
- The neural plate is the dorsal midline thickening of neuroectoderm that marks the beginning of the nervous system.
- The neural plate invaginates to form the *neural groove*—day 20–21.
- Lateral margins of the neural plate and groove form thickened areas called *neural folds*.
- *Neural crest cells* arise within the margins of the neural folds.
- Neural folds rotate across the dorsal midline to begin closure of the neural groove and formation of the *neural tube*. The central area of the neural groove is the first part to close—this begins on day 21–22.
- *Cranial* and *caudal neuropores* are the last parts of the neural tube to close—days 25 and 27, respectively.
- The ventral part of the neural tube forms the *basal plate* that develops motor neurons.
- The dorsal part of the neural tube forms the *alar plate* that develops sensory neurons.

Important Concept

Body wall defects such as neural tube defect, gastrochisis and omphalocele may result in elevation of α-fetoprotein (AFP) levels.

Please visit us at www.Groupinsiders.com

© DeVry/Becker Educational Development Corp. All rights reserved.

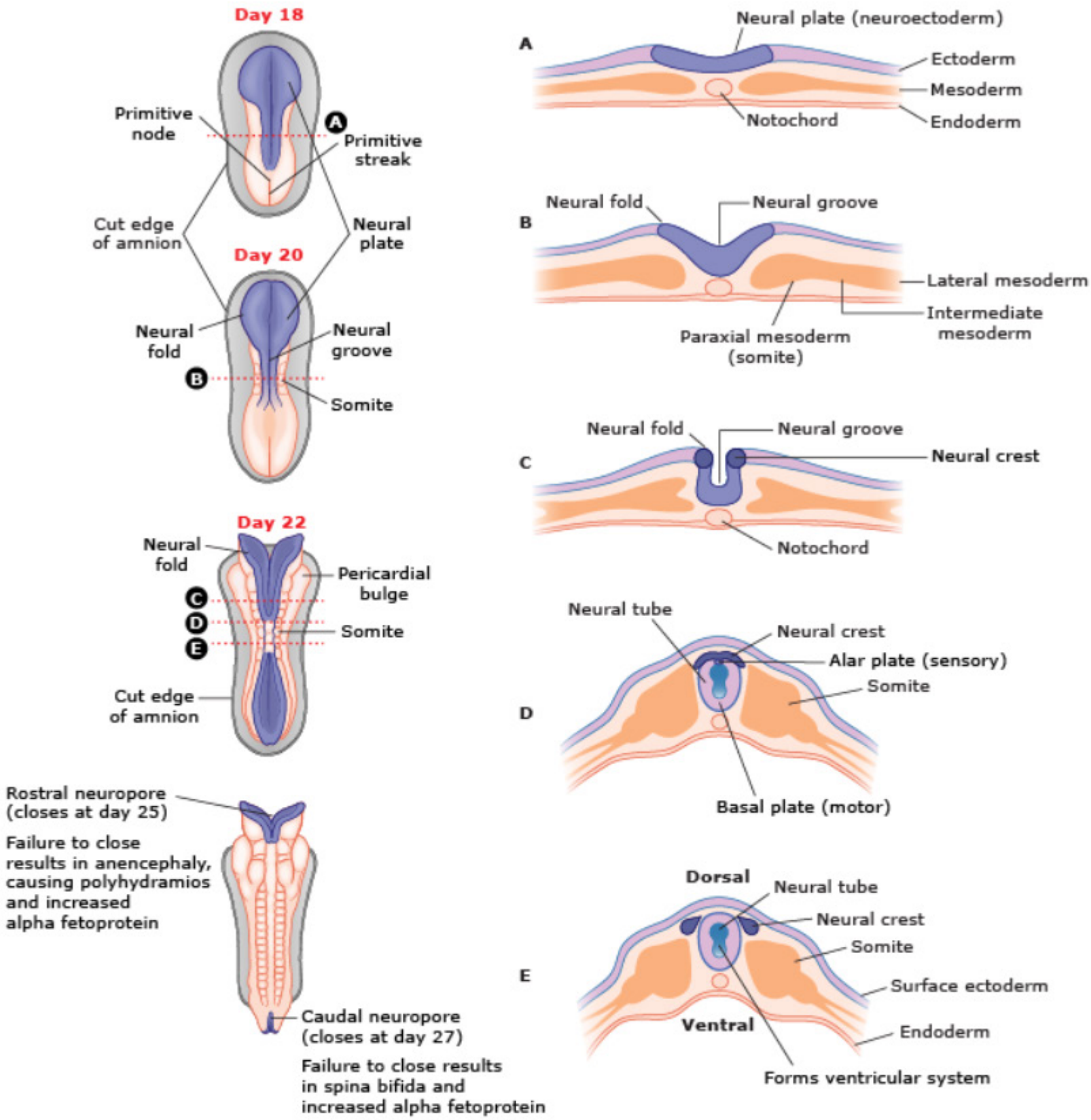

▲ **Figure 13–2.1A** Nervous System Development

Please visit us at www.Groupinsiders.com

© DeVry/Becker Educational Development Corp. All rights reserved.

2.1.1 Primary and Secondary Brain Vesicles

- In the fifth week, following closure of the cranial and caudal neuropores, the cranial end of the closed neural tube forms three dilations called *primary vesicles*:
  1. **Prosencephalon,** or forebrain;
  2. **Mesencephalon,** or midbrain; and
  3. **Rhombencephalon,** or hindbrain.
- The primary vesicles then divide into *five secondary vesicles*. The secondary vesicles and their adult derivatives are shown in Figure 13–2.1B and Table 13–2.1A.

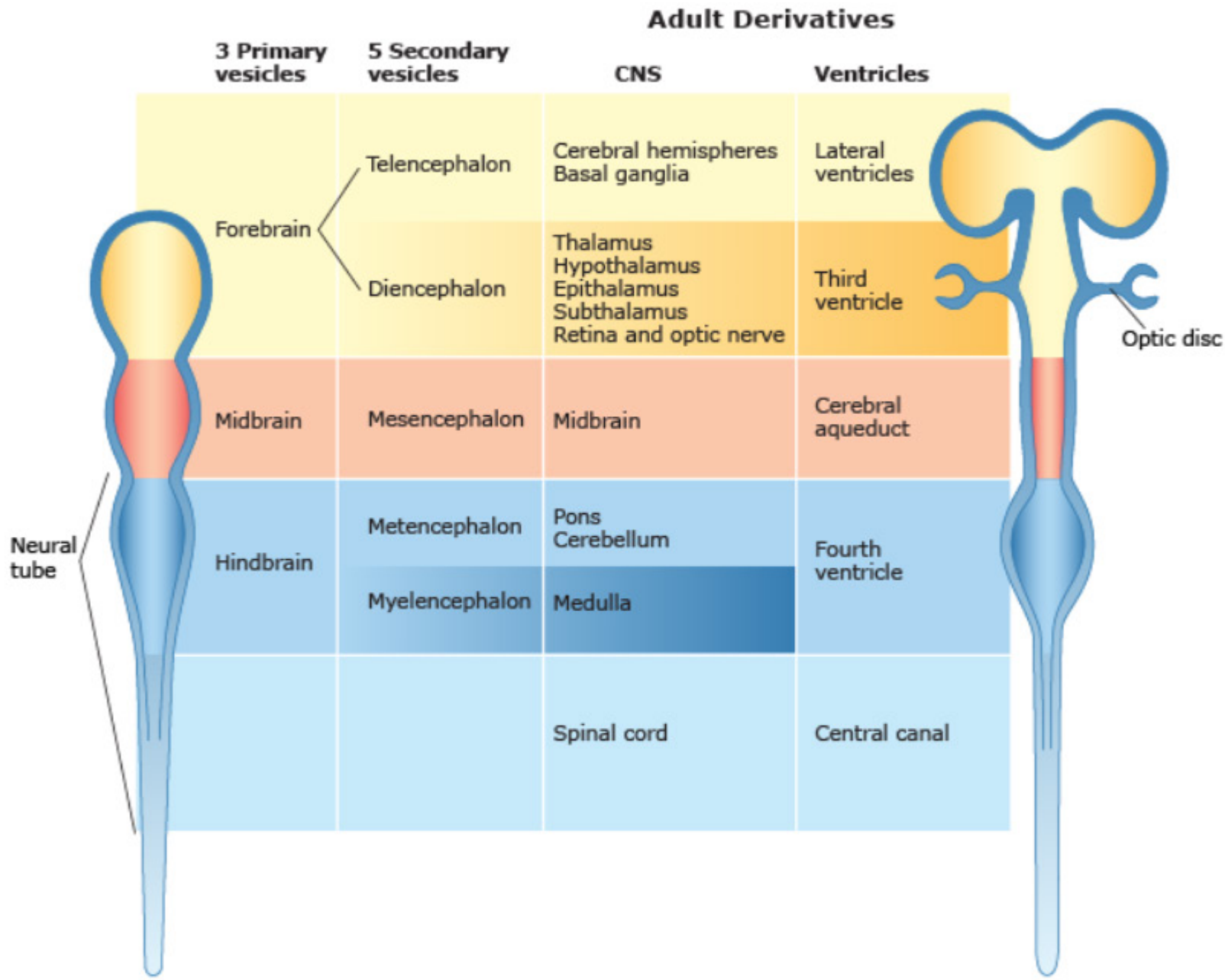

▲ **Figure 13–2.1B** Brain Vesicles and Adult Derivatives

Please visit us at www.Groupinsiders.com

© DeVry/Becker Educational Development Corp. All rights reserved.

▼ **Table 13–2.1A** Secondary Brain Vesicle Derivatives

Vesicles	Structures	Neural Canal Remnant
Telencephalon	Cerebral hemispheres, most of basal ganglia	Lateral ventricles
Diencephalon	Thalamus, hypothalamus, subthalamus, epithalamus (pineal gland), retina, and optic nerve	Third ventricle
Mesencephalon	Midbrain	Cerebral aqueduct
Metencephalon	Pons, cerebellum	Fourth ventricle
Myelencephalon	Medulla	Fourth ventricle
	Spinal cord	Central canal

The adult derivatives from the ectoderm germ layer are shown below.

▼ **Table 13–2.1B** Derivatives of Ectoderm Germ Layer

Ectoderm	
Surface ectoderm	Epidermis Hair Nails Inner ear, external ear Enamel of teeth Lens of eye Anterior pituitary (Rathke pouch) Parotid gland Anal canal below pectinate line Mammary gland
Neuroectoderm	Neural tube: • Central nervous system • Retina and optic nerve—CNS tract (diencephalon) • Pineal gland • Neurohypophysis • Astrocytes • Oligodendrocytes (CNS myelin; CN II—multiple sclerosis)
Neural crest	Adrenal medulla Ganglia: • Sensory—pseudounipolar neurons • Autonomic—postganglionic neurons Pigment cells Schwann cells (PNS myelin—Guillain-Barré) Meninges (Pia and arachnoid mater) Pharyngeal arch cartilage Odontoblasts Parafollicular (C) cells Aorticopulmonary septum Endocardial cushions

Important Concept

Two types of neurons in PNS ganglia formed by neural crest:

1. Unipolar (sensory)
2. Postganglionic (motor)

Two myelin forming cells:

1. Oligodendrocytes (CNS)
2. Schwann cells (PNS)

Please visit us at www.Groupinsiders.com

© DeVry/Becker Educational Development Corp. All rights reserved.

2.2 Developmental Defects of the Nervous System

▼ Table 13–2.2 Congenital Defects of the Nervous System

Condition	Clinical Features
Spina bifida	• Improper closure of posterior neuropore • Several forms: **A.** *Spina bifida occulta* (mildest form): Failure of vertebrae to close around spinal cord (tufts of hair often evident). No ↑ AFP **B.** *Spinal meningocele* (spina bifida cystica): Meninges extend out of defective spinal canal. ↑ AFP **C.** *Meningomyelocele*: Meninges and spinal cord extend out of spinal canal. ↑ AFP **D.** *Myeloschisis* (most severe form): Neural tissue is visible externally. ↑ AFP
Anencephaly	• Failure of brain and cranium to develop • Caused by lack of closure of anterior neuropore • Associated with increased maternal α-fetoprotein (AFP) and polyhydramnios • Severe cranial nerve defects
Hydrocephaly	• Accumulation of cerebrospinal fluid (CSF) in ventricles and subarachnoid space • Caused by congenital blockage of cerebral aqueducts • Increased head circumference in neonates
Dandy-Walker malformation	• Dilation of fourth ventricle leading to hypoplasia of cerebellum • Failure of foramina of Luschka and Magendie to open
Arnold-Chiari malformation Type II	• Herniation of the *cerebellar vermis* through the foramen magnum • Hydrocephaly • Myelomeningocele and syringomyelia • Newborn
Fetal alcohol syndrome	• *Most common cause of intellectual disability* • *Cardiac septal defects* • Facial malformations including widely spaced eyes and long philtrum • Growth retardation

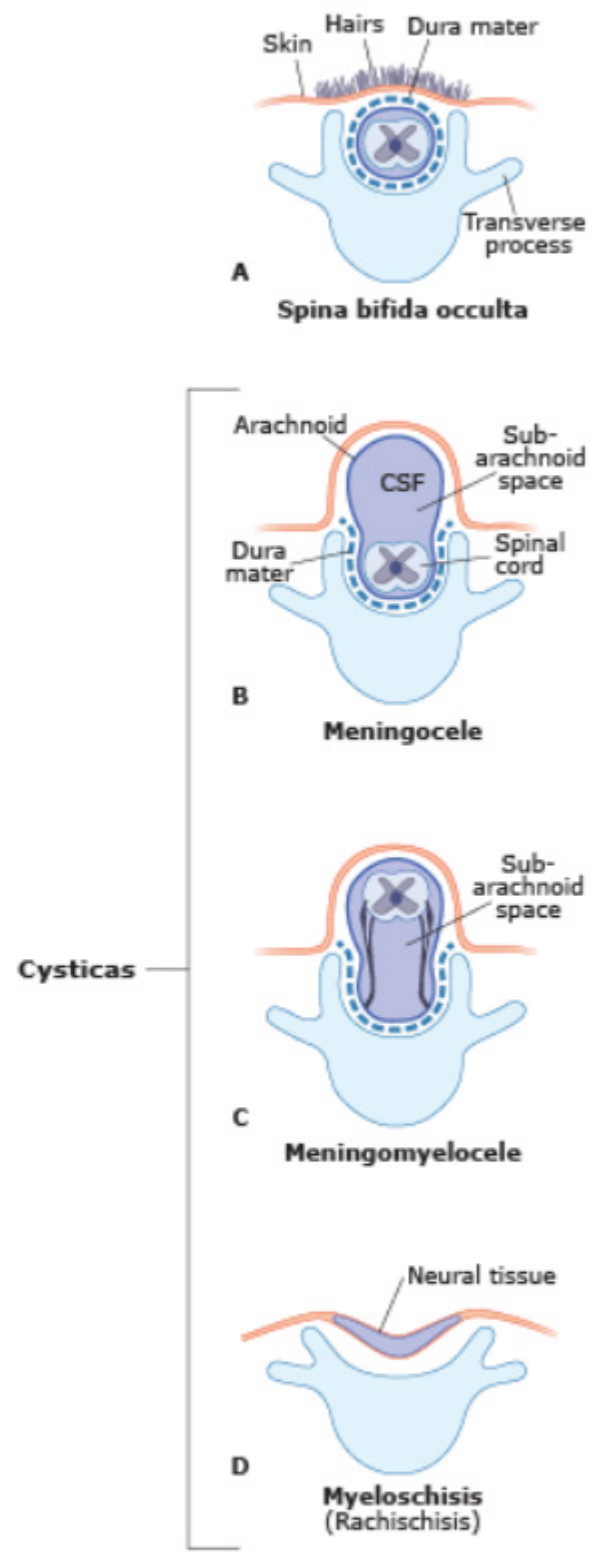

▲ Figure 13–2.2 Spina Bifida

Please visit us at www.Groupinsiders.com

© DeVry/Becker Educational Development Corp. All rights reserved.

3 Review of the Autonomic Nervous System

3.1 Sympathetic

Clinical Application

A Pancoast tumor on the apex of the lung or thoracic outlet syndrome may cause Horner syndrome.

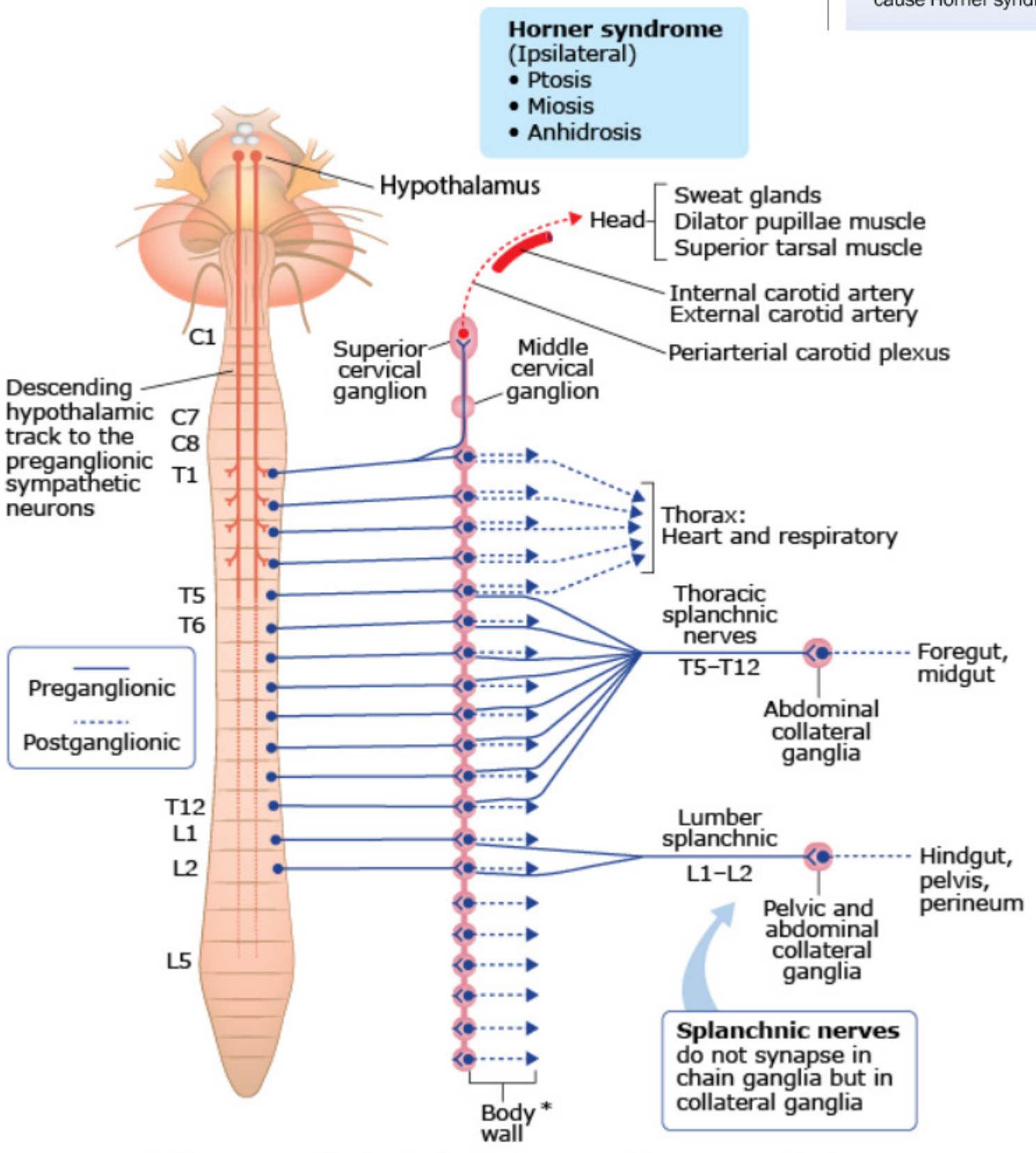

* The **preganglionics** derive from T1–L2. The **postganglionics** leave sympathetic chain in all 31 gray rami to rejoin spinal nerves for distribution to body wall and limbs.

▲ **Figure 13–3.1** Sympathetic Pathways

Please visit us at www.Groupinsiders.com

© DeVry/Becker Educational Development Corp. All rights reserved.

1 Cellular Elements of the Nervous System

The two primary cell types in the nervous system are *glial* (or support) cells and *neurons*.

1.1 Glial Cells (Neuroglia)

Glial cells are non-neuronal cells in the CNS and PNS that develop from the neural tube or neural crest cells, respectively. Glial cells are essential for neuronal function. Unlike neurons, glial cells are mitotically active and undergo cell division throughout life, especially in response to disease and trauma. There are up to 10 times more glial cells than neurons. Glial neoplasms account for the most common type of primary tumors in the CNS.

The following are the major types of glial cells. The first four types are found in the CNS, and the fifth one (Schwann cell) is found in the PNS:

1. **Astrocytes:** Astrocytes are large, star-shaped cells that are the most numerous of the glial cells. Astrocytes can be considered the workhorse of the glial cells. Their functions include:
   - Removal of certain neurotransmitters (GABA and glutamate) when released from the synapse.
   - Maintain ionic homeostasis in the extracellular environment around the neurons by the removal of K+ ions.
   - Form perivascular end-feet that contribute to the blood-brain barrier.
   - Form scar tissue in response to damage in the CNS.
2. **Oligodendrocytes:** Oligodendrocytes are responsible for the *myelination of CNS axons*. The processes of oligodendrocytes myelinate multiple CNS axons (up to 30–60 axons).
3. **Ependymal Cells:** Ependymal cells line the central canal of the spinal cord and ventricles of the brain, and form the choroid plexus, which produces most of the cerebrospinal fluid.
4. **Microglia:** Microglia arise from monocytes that migrate to a site of injury and phagocytize and remove debris of nerve tissues.
5. **Schwann Cells:** Schwann cells are the glial supporting cells found in the PNS and are derivatives of neural crest cells. Schwann cells are responsible for *myelination of axons in the PNS*. In contrast to oligodendrocytes, Schwann cells myelinate only one internodal segment of one axon. In addition, they are also critical for regeneration of damaged axons in the PNS.
   - *Nodes of Ranvier* are the insulated interruptions between segments of myelinated axons in the PNS that are found along the length of the axons. The action potential traveling along the axon jumps from one node of Ranvier to another to increase speed of conduction (saltatory conduction).

USMLE® Key Concepts

For Step 1, you must be able to:

- Identify the different types of neurons and glial cells and their functions in either the central or peripheral nervous systems.
- Describe the cells responsible for myelination of central and peripheral axons.
- Define the two major types of neuronal axon transports and their roles in both the normal function of cells and in pathology.
- Explain the process of axon regeneration in the peripheral nervous system.

Please visit us at www.Groupinsiders.com

© DeVry/Becker Educational Development Corp. All rights reserved.

▼ **Table 14–1.1** Major Demyelinating Diseases of the Nervous System

Disease	Etiology	Clinical Manifestation
Multiple sclerosis (MS): most common demyelinating disease in CNS	Unknown; more common in women with 3rd or 4th decade onset; *oligodendrocyte damage*	Multiple focal areas of demyelination; variable course in time; motor and sensory deficits; internuclear ophthalmoplegia (MLF); vertigo; blindness
Guillain-Barré syndrome: most common demyelinating disease in PNS	Postviral autoimmune reaction involving PNS; *Schwann cell damage*	Muscle weakness and paralysis *ascending upward* from the lower extremities
Huntington disease	Chromosome 4	Degeneration of *caudate nucleus*; onset at 30 to 40 years of age; athetoid movements; muscular deterioration; dementia
Amyotrophic lateral sclerosis (ALS, Lou Gehrig disease)	Autosomal dominant in 5% of cases	*Both upper and lower motor neuron signs*; loss of lateral corticospinal tracts and anterior motor neurons leading to muscle atrophy

1.2 Neurons

Neurons are the functional cells of the CNS and PNS that are responsible for the transfer of information and production of neurotransmitters. Neurons have lost their ability to undergo cell division and cannot reproduce themselves. Chemical transmission across the synapse utilizing neurotransmitters is the primary mechanism of communication between neurons.

1.2.1 Classification of Neurons

Neurons are classified according to their morphological structure and the number of processes. The three basic types of neurons are:

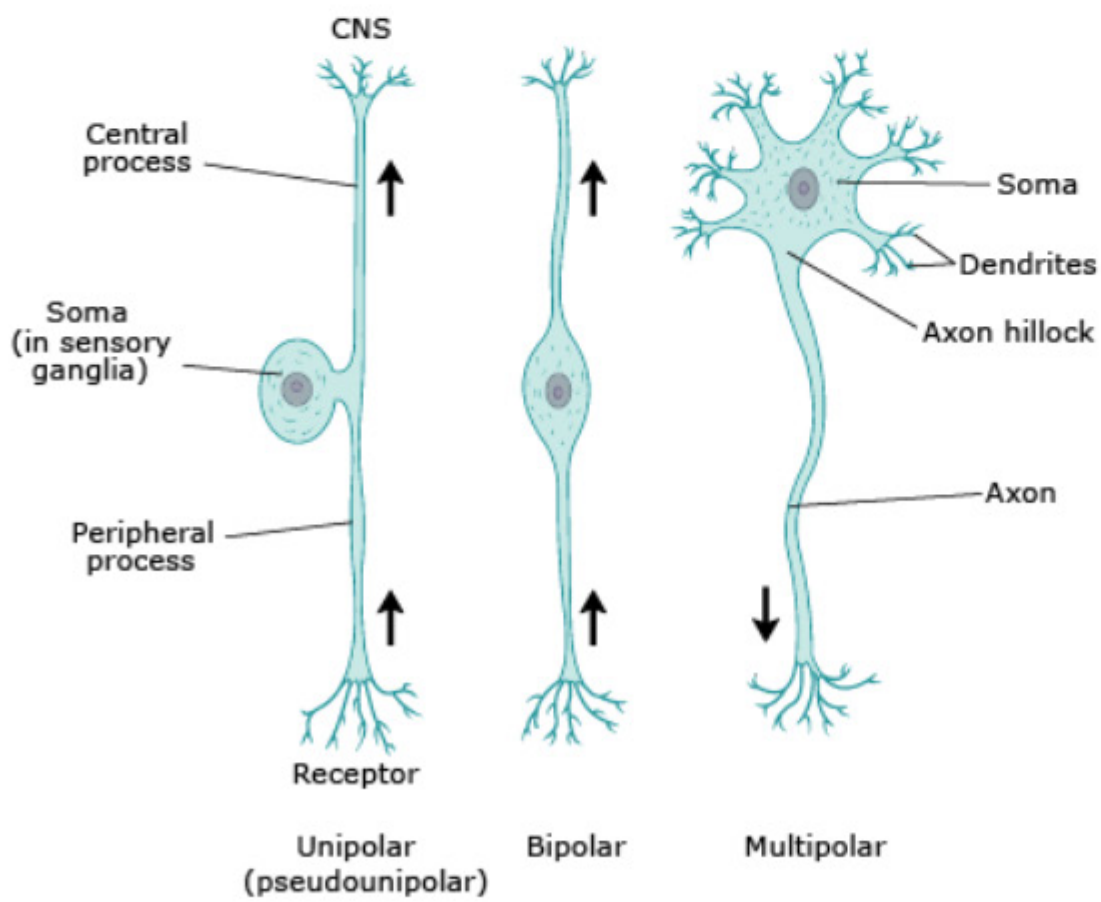

▲ **Figure 14–1.2** Classification of Neurons

Please visit us at www.Groupinsiders.com

© DeVry/Becker Educational Development Corp. All rights reserved.

1. Unipolar or Pseudounipolar Neurons

- Are sensory neurons of the PNS.
- Have cell bodies located in sensory ganglia within the PNS.
- Have a single fiber that extends from the cell body and divides into a *peripheral* and a *central process*. The peripheral process extends distally through the spinal nerve system and receives information from sensory receptors. The central process continues through the dorsal root of the spinal nerve and enters the CNS.

2. Bipolar Neurons

These are sensory neurons found in limited areas of the nervous system:

- The retina (CN II).
- Sensory ganglia of the vestibulocochlear nerve (CN VIII).
- The olfactory epithelium (CN I).

3. Multipolar Neurons

- Are the most common and numerous neurons of the CNS and PNS.
- Consist of multiple dendrites, cell body (soma), and a single axon.

1.3 Neuron Cell Structure

The multipolar neurons demonstrate the classic cell structure of the neuron.

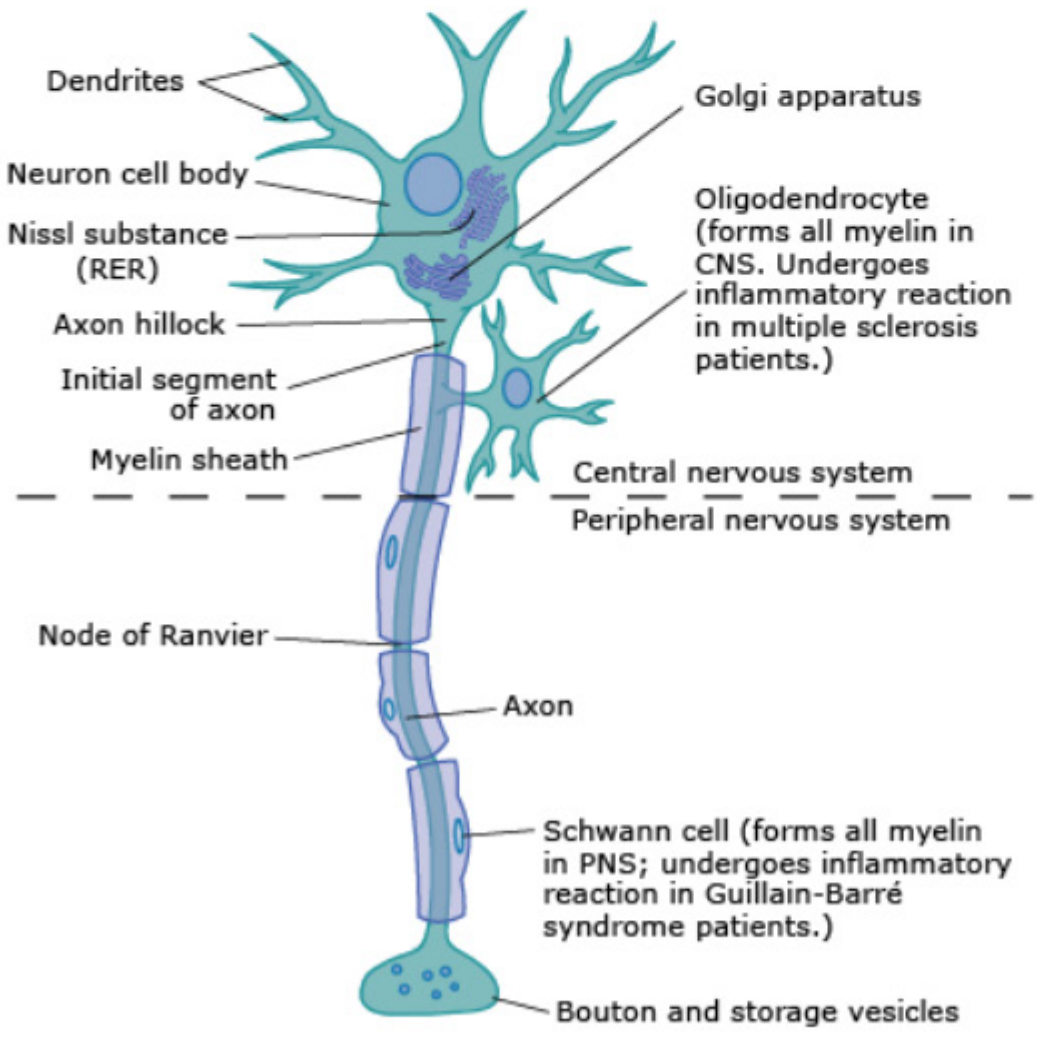

▲ **Figure 14–1.3** Multipolar Neuron

Please visit us at www.Groupinsiders.com

© DeVry/Becker Educational Development Corp. All rights reserved.

1.3.1 Dendrites

- Are multiple, tapered, and branched processes that extend from the cell body.
- Make synaptic contact with other neurons and transmit information toward the cell body.
- Increase surface area of the cell membrane.

1.3.2 Cell Body (Soma or Perikaryon)

- Contains a large central nucleus and nucleolus.
- Cytoplasm contains typical organelles: Mitochondria, Golgi apparatus, rough endoplasmic reticulum (Nissl substance), and cytoskeleton (neurofilaments, microfilaments, and microtubules).

1.3.3 Axons

- Form a single, long process extending from the cell body.
- Arise from axon hillock.
- Are uniform in diameter with collateral branches.
- Cytoplasm does not contain Nissl substance or Golgi apparatus.
- End distally in terminal dilations called a *bouton* containing storage vesicles for neurotransmitters.

Please visit us at www.Groupinsiders.com

© DeVry/Becker Educational Development Corp. All rights reserved.

2 Axon Transport

- Axon transport is an active process of transporting intracellular material (secretory products, proteins, organelles, membranes, and pathological agents) through the axon. Axon transport from the cell body to the bouton is called *anterograde transport*, and transport from the terminal bouton back to the cell body is referred to as *retrograde transport*. Both directions of transport utilize *microtubules* (Figure 14–2.0).
- *Anterograde transport* is responsible for the movement of neurotransmitters, proteins, organelles, and membranes produced in the cell body toward the terminal bouton. *Fast anterograde transport* (100–400 mm/day) utilizes microtubules and is mediated by *kinesin*. Slow anterograde transport (1–2 mm/day) does not utilize microtubules.
- *Retrograde transport* is slower (50–100 mm/day) than anterograde transport and is responsible for movement of intracellular elements and debris from the distal end of the axon back toward the cell body. Retrograde transport also utilizes microtubules but is mediated by *dynein*. Note that retrograde axonal transport is also involved in the transport of pathological agents such as herpes, polio, rabies viruses, and tetanus toxin from the axon terminals toward the cell bodies.

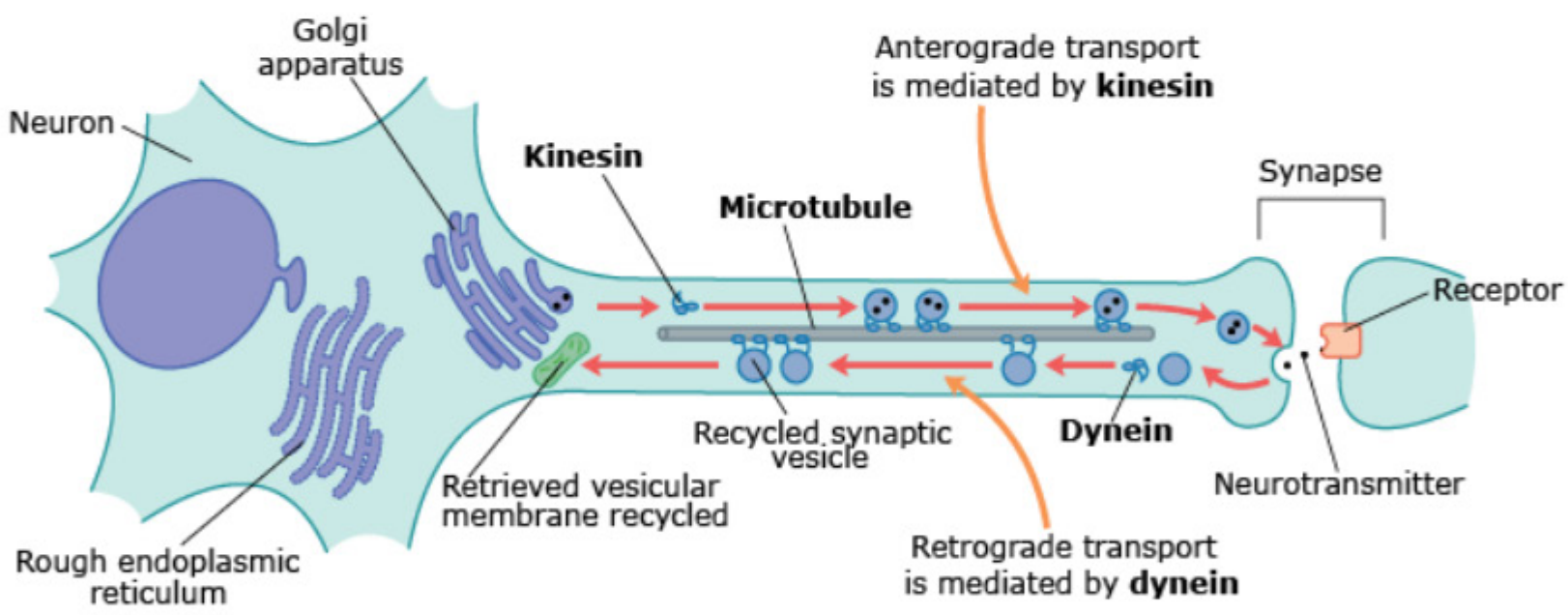

▲ **Figure 14–2.0** Axon Transport

Please visit us at www.Groupinsiders.com

© DeVry/Becker Educational Development Corp. All rights reserved.

▼Table 14–2.0 Nervous System Tumors in Adults and Children

Tumor	Presentation	Significant Features
Metastatic neoplasms	Headache, focal defects, formation of discrete nodules in brain	Nearly half of all intracranial neoplasm; usually blood-borne; commonly from lung, breast, gastrointestinal, thyroid, kidney, genitourinary, or melanoma
Glioblastoma multiforme (grade IV astrocytoma)	Cerebral hemisphere tumor, irregular mass with necrotic center surrounded by edema seen on CT	*Most common primary intracranial neoplasm*; poor prognosis; neural tube origin; *pseudopalisading* arrangement of cells
Meningioma	Slow growing, originates in arachnoid cells, follows sinuses; does not invade brain	*Second most common primary CNS tumor*; usually occurs in women; resettable; neural crest origin
Schwannoma	Tinnitus and hearing loss, ataxic gait, increased intracranial pressure, hydrocephalus, benign	*Third most common primary intracranial tumor*; neural crest origin; usually occurs in the cerebellopontine angle and involves CN VIII
Craniopharyngioma	Endocrine abnormalities, papilledema, *bitemporal hemianopsia* due to compression of optic chiasm	Enlarged sella turcica; *most common supratentorial brain tumor in children; ectodermal origin (Rathke pouch)*
Oligodendroglioma	Slow-growing frontal lobe tumor	Rare; clearing of the cytoplasm around the nuclei *(perinuclear halo)* gives tumor cells a *"fried egg" appearance*
Medulloblastoma	Cerebellar mass, may compress the fourth ventricle *(noncommunicating hydrocephalus)*, ataxic gait, projectile vomiting	*Most common malignant primary brain tumor of childhood*; neural tube origin
Ependymoma	May compress the fourth ventricle *(noncommunicating hydrocephalus)*	Neural tube origin; *perivascular rosettes* (circular arrangement of tumor cells around a central vessel)

Please visit us at www.Groupinsiders.com

© DeVry/Becker Educational Development Corp. All rights reserved.

3 Regeneration of Axons

Nerve cells are not mitotically active and cannot divide and reproduce themselves. Thus, when destroyed by disease or trauma, they cannot be replaced. However, the axons of neurons can regenerate and regain function if the cell body remains intact, but this ability to regenerate axon function is limited to the PNS. CNS axons do not regenerate.

3.1 Wallerian or Anterograde Degeneration

When an axon in the CNS or PNS is damaged or cut, the axon distal to the lesion undergoes wallerian (anterograde) degeneration (Figure 14–3.1).

- In the PNS, the axon distal to the lesion degenerates quickly and is removed in two to three weeks. It is critical that the Schwann cell that forms the myelin sheath around the axon remains intact and does not degenerate. The Schwann cells form scaffolding in which the new axon grows.
- In the CNS, the degeneration and removal of the axon distal to the lesion takes a longer time, up to several months. The oligodendrocytes of the CNS do not support axon regeneration, and astrocytes replace the damaged CNS axon with scar tissue.

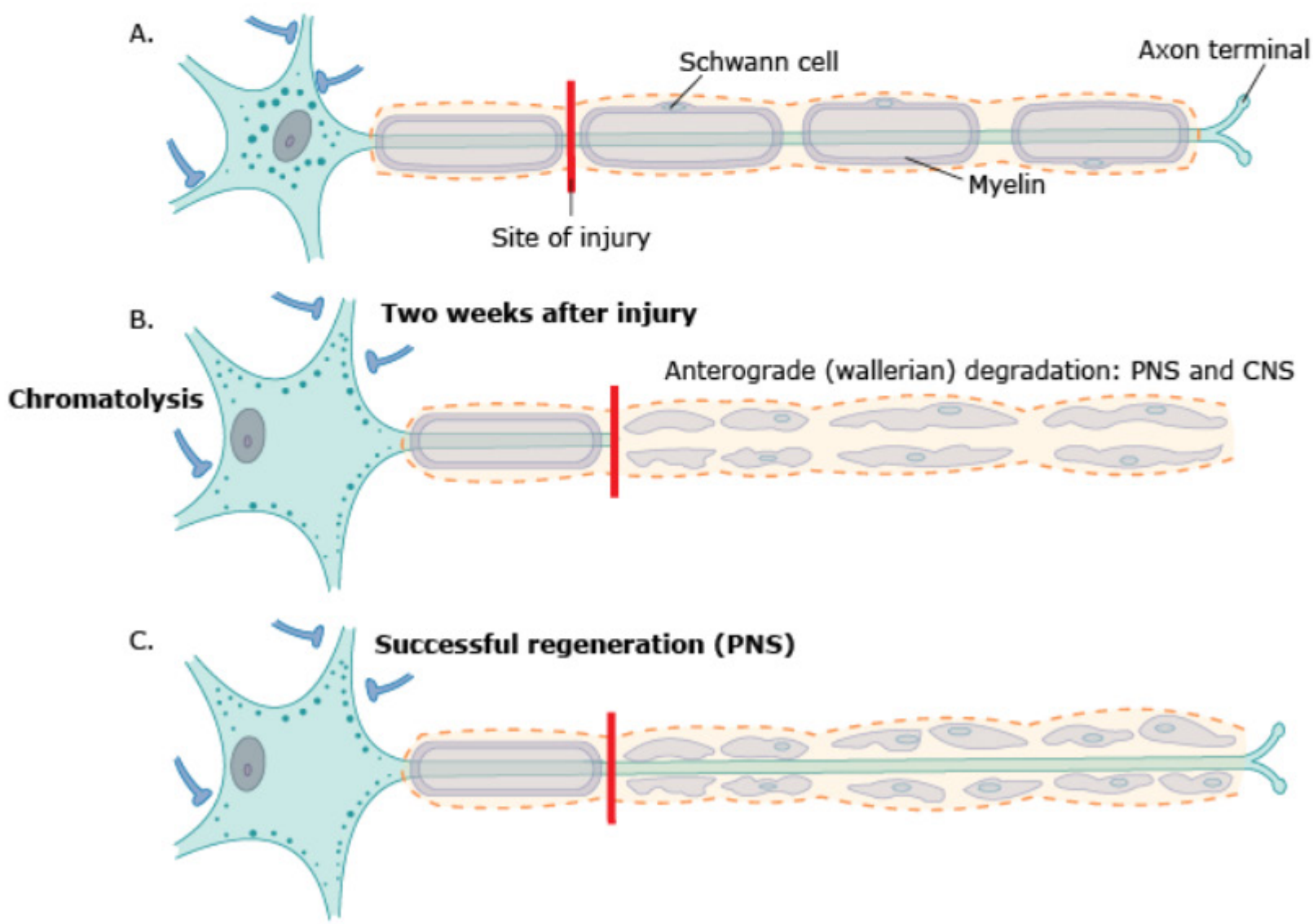

▲ **Figure 14–3.1** Neuron Regeneration

Please visit us at www.Groupinsiders.com

© DeVry/Becker Educational Development Corp. All rights reserved.

3.2 Chromatolysis

Chromatolysis occurs in the cell body of the damaged axon and prepares the cell to regenerate a new axon. Within several days of the cut axon, the cell body swells, there is dispersion of Nissl substance, and the nucleus moves to the periphery.

3.3 Axon Regeneration in the PNS

If the Schwann cells in the PNS are intact, they proliferate and form a myelin sleeve for the new axon sprout to follow. The axon sprout grows about 1–3 mm/day. If the growth of the new axon is hindered, a neuroma forms at the site where regeneration was blocked.

Please visit us at www.Groupinsiders.com

© DeVry/Becker Educational Development Corp. All rights reserved.

Meninges and Circulation of Cerebrospinal Fluid

1 Dural Venous Sinuses

Dural venous sinuses are endothelial-lined, vein-like spaces formed when the periosteal and meningeal layers of the dura mater separate at various sites within the cranial cavity. Most of the sinuses are found within the two largest duplications of dura (falx cerebri and tentorium cerebelli) formed by the infoldings of the meningeal layer of dura.

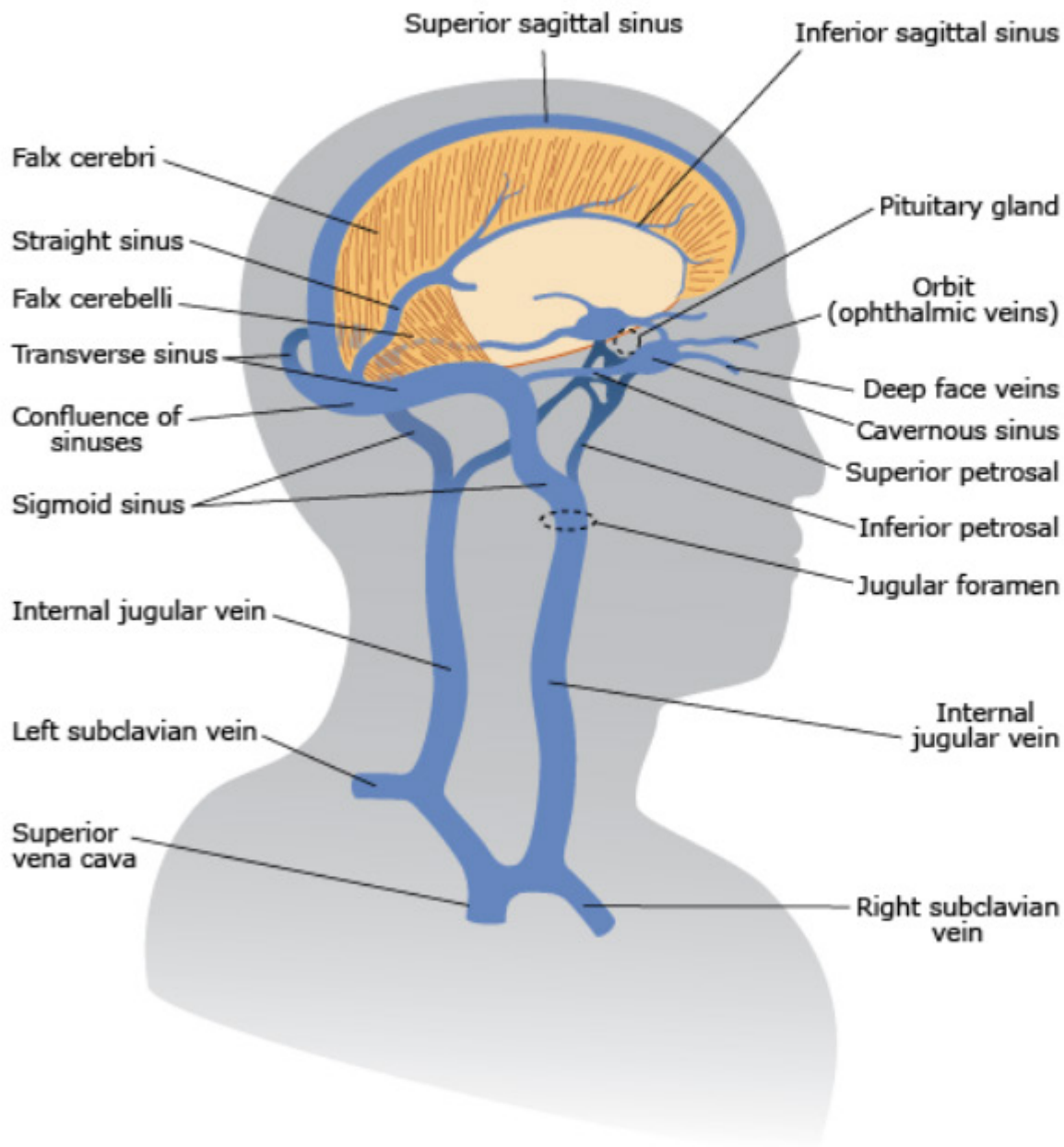

▲ **Figure 15-1.0** Dural Venous Sinuses

USMLE® Key Concepts

For Step 1, you must be able to:

- Describe the ventricular system and the route of circulation of cerebrospinal fluid (CSF).
- Identify where CSF is produced and where it is absorbed back into the systemic circulation.
- Distinguish between the different types of hydrocephalus.

Please visit us at www.Groupinsiders.com

© DeVry/Becker Educational Development Corp. All rights reserved.

The dural venous sinuses receive venous drainage from intracranial tissues and drainage of cerebrospinal fluid via the arachnoid granulations. All of this venous flow ultimately drains through the sinuses into the *internal jugular vein* at the jugular foramen. The major structures draining into the sinuses are the:

- *Bridging veins,* formed by veins draining the cerebrum and cerebellum. These veins cross the subarachnoid and subdural spaces to drain into the sinuses.
- *Emissary veins,* which drain through the flat bones of the skull and connect extracranial veins with the intracranial dural sinuses.
- *Meningeal veins,* which drain the meninges.
- *Arachnoid granulations,* which drain CSF from the subarachnoid space into the dural sinuses.

The major dural venous sinuses are:

- Superior sagittal sinus
- Inferior sagittal sinus
- Straight sinus
- Confluence of the sinuses
- Transverse sinus
- Sigmoid sinus
- Cavernous sinus
- Superior and inferior petrosal sinuses

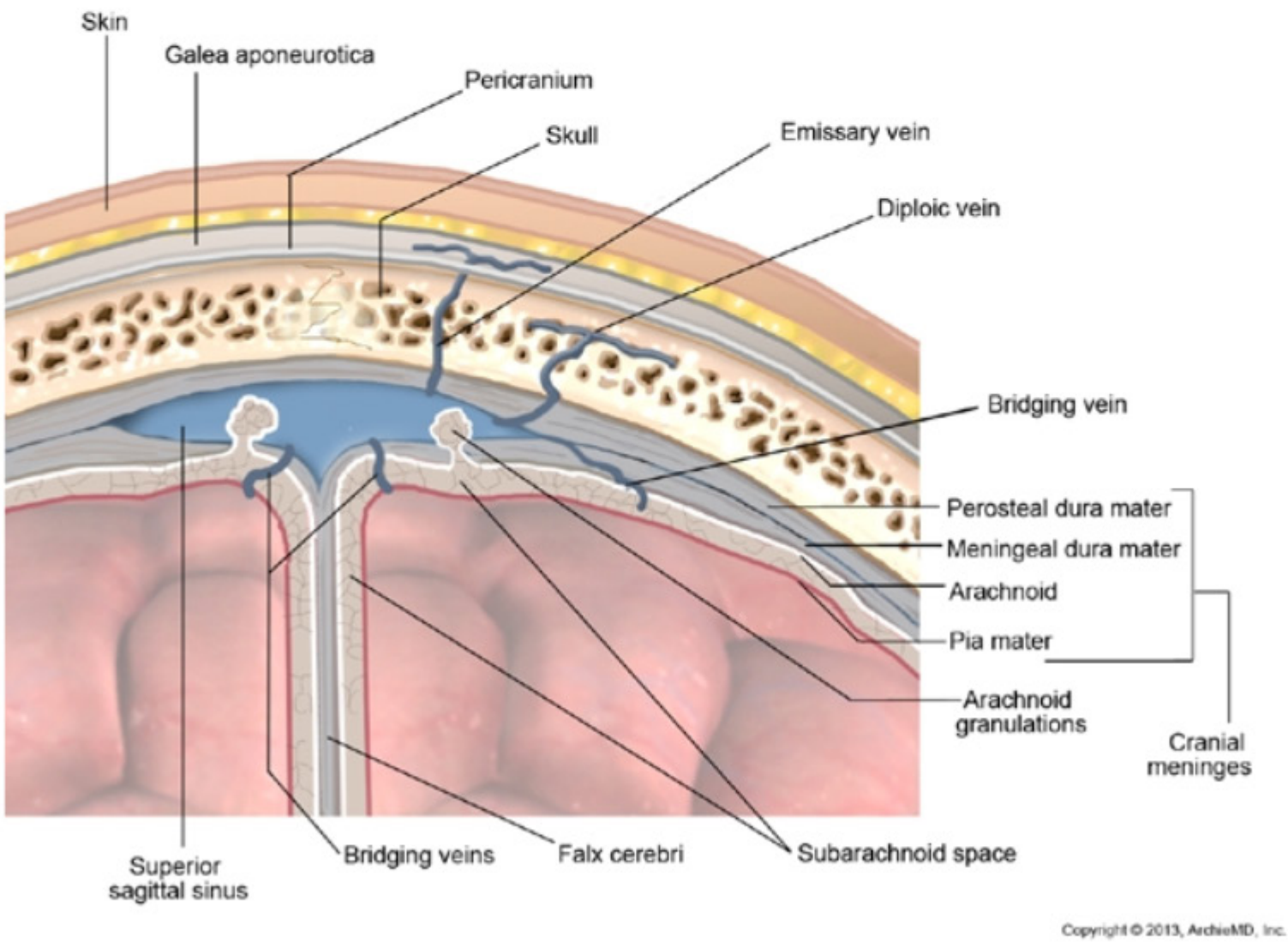

▲ **Figure 15-1.1** Cranial Meninges

Please visit us at www.Groupinsiders.com

© DeVry/Becker Educational Development Corp. All rights reserved.

2 Cerebrospinal Fluid

Cerebrospinal fluid (CSF) is a clear fluid that circulates in the subarachnoid space and ventricles. Bathing the CNS, it provides support and protection from trauma as well as nutrition. It also removes waste products. CSF has a pH of 7.33, with a lower concentration of protein, glucose, calcium, and potassium than serum. Sodium concentrations in CSF are equal to those in serum, while the concentrations of chloride and magnesium are higher.

Most of the volume of CSF (70%) is produced by the *choroid plexus* at a rate of about 500 mL per day, although the total average volume at one time is 90 to 150 mL. Choroid plexus is found in the lateral, third, and fourth ventricles. From the ventricles, CSF enters and circulates in the subarachnoid space. From the subarachnoid space, CSF is absorbed back into the systemic circulation (superior sagittal sinus) via the *arachnoid granulations*. The CSF volume is replaced from three to four times a day.

Important Concept

CSF is produced by choroid plexuses (mostly in lateral, third and fourth ventricles).

CSF is absorbed back into systemic circulation at the arachnoid granulations.

Please visit us at www.Groupinsiders.com

© DeVry/Becker Educational Development Corp. All rights reserved.

3 Ventricular System of the Brain

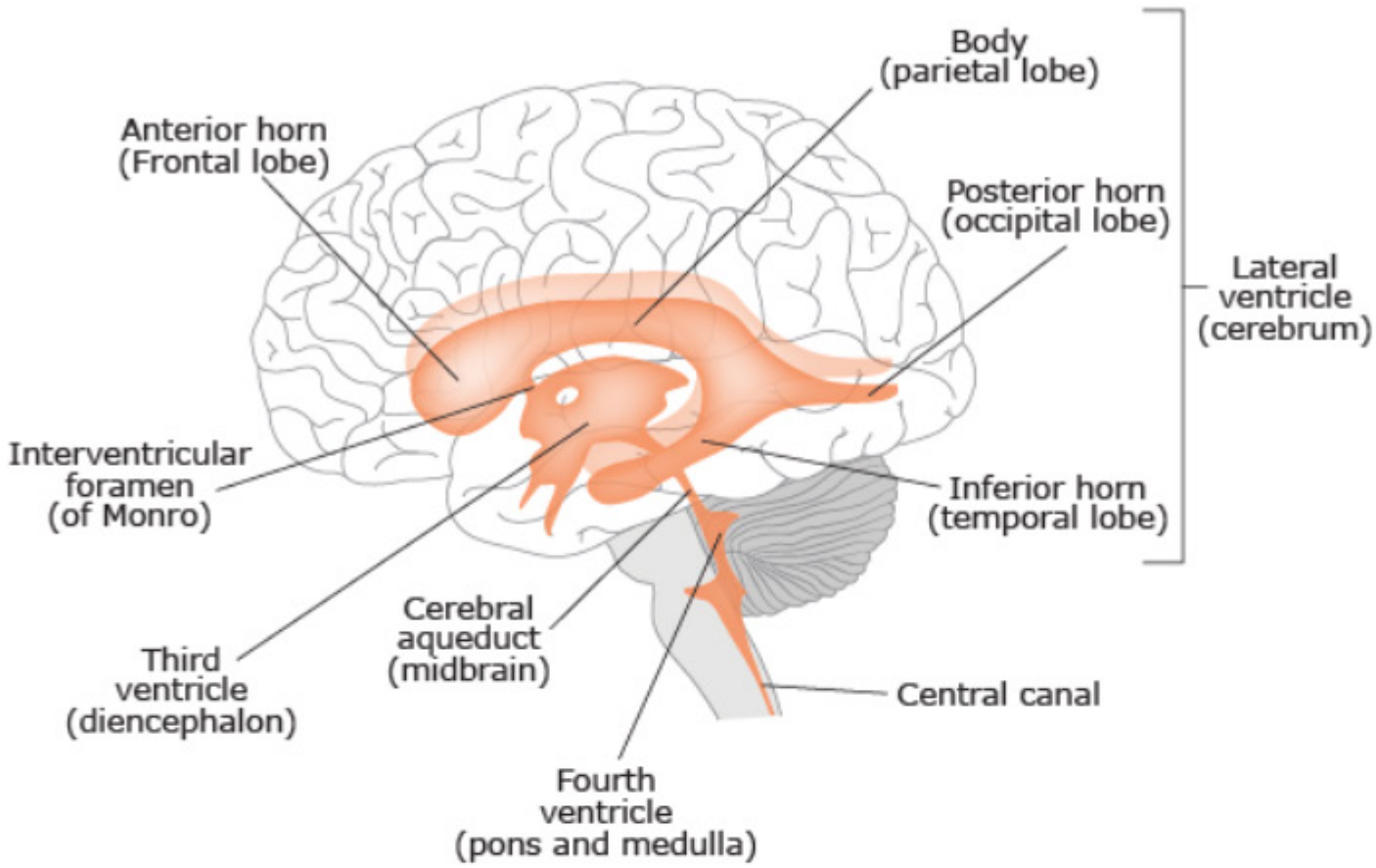

▲ **Figure 15–3.0A** Ventricles of CNS

Please visit us at www.Groupinsiders.com

© DeVry/Becker Educational Development Corp. All rights reserved.

Within the brain, there are four ependymal-lined cavities referred to as cerebral ventricles (Figure 15–3.0A). The four ventricles communicate with each other and the subarachnoid space, allowing for the circulation of cerebrospinal fluid (CSF). CSF circulation follows the circulation route described below (Figure 15–3.0B):

1. There are *two lateral ventricles* located in the right and left cerebral hemispheres. The lateral ventricles are divided into horns that project into all four lobes of the cerebrum. The anterior horn is located in the frontal lobe, the posterior horn is located in the occipital lobe, the inferior horn is located in the temporal lobe, and the body of the lateral ventricles is located in the parietal lobe.
2. The *interventricular foramen* (of Monro) is a narrow passageway that connects each lateral ventricle with the third ventricle.
3. The *third ventricle* is the expanded, single area that lies in the midline between the two thalamic regions of the diencephalon.
4. The *cerebral aqueduct* (of Sylvius) continues from the third ventricle into the midbrain, connecting the third ventricle with the fourth ventricle. It is the narrowest part of the CSF circulation and a common site of hydrocephalus.
5. The *fourth ventricle* is single and located within the lower two-thirds of the brainstem. Its floor is formed by the pons and upper medulla and its roof is formed by the cerebellum.
6. Two lateral *foramina of Luschka* and a median *foramen of Magendie* connect the fourth ventricle with the *subarachnoid space*.
7. The *central canal* extends from the fourth ventricle into the entire length of the spinal cord.
8. CSF circulates within the *subarachnoid space* and returns to the systemic circulation via the arachnoid granulations located in the superior sagittal venous sinus.

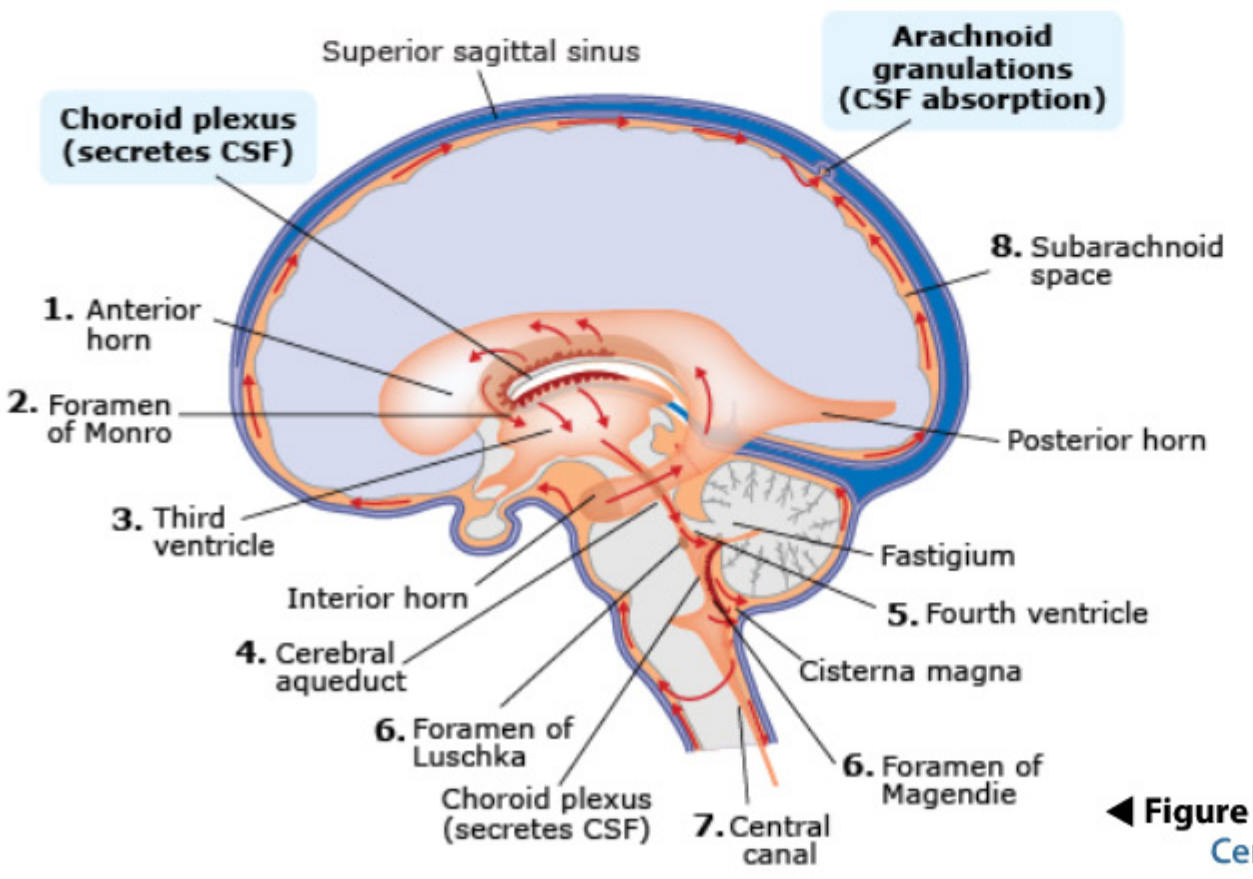

◀ **Figure 15–3.0B** Circulation of Cerebrospinal Fluid

Please visit us at www.Groupinsiders.com

© DeVry/Becker Educational Development Corp. All rights reserved.

Clinical Application

Hydrocephalus

Hydrocephalus is an excessive accumulation of CSF volume in the ventricles or subarachnoid space that results in dilation of the ventricles, increased pressure, and damage to nerve tissue. Some of the major types of hydrocephalus are listed below.

▼ **Table 15–3.0** Major Types of Hydrocephalus

Type of Hydrocephalus	Description
Noncommunicating	*Obstruction of flow within ventricles*; most commonly occurs at narrow points, e.g., foramen of Monro, cerebral aqueduct, and openings of fourth ventricle.
Communicating	*Impaired CSF reabsorption* in arachnoid granulations or oversecretion of CSF by choroid plexus.
Normal pressure (chronic)	CSF is not absorbed by arachnoid villi (a form of communicating hydrocephalus). CSF pressure is usually normal. Ventricles are chronically dilated. Produces *triad* of *dementia, apraxic (magnetic) gait,* and *urinary incontinence*. Peritoneal shunt.

Please visit us at www.Groupinsiders.com

© DeVry/Becker Educational Development Corp. All rights reserved.

Chapters 13–15 Review Questions

1. A 35-year-old male presents with headaches for several months. His cerebrospinal fluid pressures (CSF) were increased and radiology scans were normal. The physician determined that the elevated pressures were the result of poor absorption of CSF. Which of the following would be the site of lesion?

   A. Cerebral aqueduct
   B. Monro foramen
   C. Foramen of Luschka
   D. Foramen of Magendie
   E. Arachnoid granulations

2. During development, the neural crest cells fail to develop properly from the neural tube. Which of the following most likely would be affected?

   A. Decreased number of preganglionic autonomic nervous system neurons
   B. Somatic motor neurons
   C. Myelination of central nervous system axons
   D. Sensory neurons in sensory ganglia
   E. Development of the adenohypophysis

3. A small child fell through a glass door and cut the ulnar nerve on the medial aspect of the arm. Which of the following plays an essential role in proper regeneration of the axons of the ulnar nerve?

   A. Schwann cells
   B. Oligodendrocytes
   C. Wallerian degeneration
   D. Astrocytes
   E. Microglia

4. During pregnancy, a fetus is identified as having noncommunicating hydrocephalus with enlargement of the lateral, third, and fourth ventricles. In which of the following is the obstruction of CSF flow most likely located?

   A. Cerebral aqueduct
   B. Foramen of Magendie
   C. Monro foramen
   D. Diencephalon
   E. Midbrain

5. During development, the metencephalon does not form completely, resulting in significant defects in the central nervous system. Which of the following would you expect to be absent or poorly developed?

   A. Midbrain
   B. Basal ganglia
   C. Cerebral hemispheres
   D. Cerebellum
   E. Hypothalamus

6. During pregnancy, laboratory tests and ultrasound indicate that the fetus has a neural tube defect with increased levels of alpha-fetoprotein and polyhydramnios. The congenital defect would more likely be:

   A. Spina bifida occulta
   B. Dandy-Walker malformation
   C. Spina bifida meningomyelocele
   D. Arnold-Chiari malformation
   E. Anencephaly

Please visit us at www.Groupinsiders.com

© DeVry/Becker Educational Development Corp. All rights reserved.

Review Answers Chapters 13–15

1. The correct answer is E. The patient demonstrates a communicating type of hydrocephalus resulting from decreased absorption of CSF back into the systemic circulation. CSF is absorbed from the subarachnoid space into the superior sagittal dural venous sinus via the arachnoid granulations (villi).

2. The correct answer is D. Neural crest cells develop from the neuroectoderm of the neural tube and contribute to development of a number of systems. Neural crest cells contribute to the peripheral nervous system and form Schwann cells and the neurons with cell bodies in peripheral ganglia. Sensory ganglia contain the unipolar sensory neurons that bring sensory information into the central nervous system.

3. The correct answer is A. When an axon is damaged in either the CNS or PNS, the fiber distal to the injury will undergo wallerian degeneration with breakdown and removal of the axon. The Schwann cells are critical for PNS axon regeneration by forming a sleeve for the growth of the new axon. Oligodendrocytes of the CNS will not support CNS axon regeneration.

4. The correct answer is B. With enlargement of all three ventricles, the obstruction is in one of the foramina of the fourth ventricle (Luschka or Magendie) that transport CSF into the subarachnoid space.

5. The correct answer is D. After closure of the neural tube on days 27–28, the neural tube forms three primary vesicles and then five secondary vesicles: telencephalon, diencephalon, mesencephalon, metencephalon, and metencephalon. The metencephalon forms the pons of the brainstem and the cerebellum.

6. The correct answer is E. The failure of the neural tube to close will result in elevated levels of alpha-fetoprotein that pass through the body-wall defect into the amnion. Failure of the rostral (cranial) neuropore to close will result in anencephaly and severe cranial defects in which the fetus cannot swallow amniotic fluid and develops polyhydramnios.

Please visit us at www.Groupinsiders.com

© DeVry/Becker Educational Development Corp. All rights reserved.

1 General Structure of the Spinal Cord

The spinal cord is the inferior part of the CNS that occupies the upper two thirds of the vertebral column. Highly organized, it is involved in processing sensory, motor, autonomic, and reflex innervation for the trunk and limbs. The cord receives sensory input from the trunk and limbs, and contains all of the lower motor neurons supplying the muscles of the trunk and limbs. The distal end of the spinal cord tapers to form the conus medullaris, which terminates at the L1 or L2 vertebral level in the adult or around L3 or L4 in the newborn.

The spinal cord develops segmentally from the caudal end of the neural tube and is divided into 31 segments: 8 cervical, 12 thoracic, 5 lumbar, 5 sacral, and *1 coccygeal*. Each of these segments provides attachment for *31 pairs of spinal nerves* of the same name and number.

- **Cervical Spinal Nerves (C1–C8):** Contribute to the *cervical plexus* (C1–C4) and the *brachial plexus* (C5–T1), which provide motor and sensory innervation for the anterolateral neck and upper limb, respectively.
- **Thoracic Spinal Nerves (T1–T12):** Form intercostal nerves and the subcostal nerve that innervate the body wall of the anterior and lateral trunk.
- **Lumbar Spinal Nerves (L1–L5):** Contribute to the lumbar and sacral plexuses that innervate the lower limb and lower trunk.
- **Sacral Spinal Nerves (S1–S5):** Contribute to the sacral plexus for innervation of the lower limb.
- **One Coccygeal Nerve:** Provides minimal sensory innervation.

USMLE® Key Concepts

For Step 1, you must be able to:

- Define the structure, distribution, and function of a typical spinal nerve.
- Describe gray matter and white matter of the cord and understand their role in spinal cord lesions.
- Identify the three major long tract systems, their functions, pathways, and how lesions of these long tracts present with spinal cord damage.
- Differentiate between upper and lower motor neuron lesions.
- Describe the neural circuitry of reflex contraction of muscles and how reflex testing assists in identifying types of nerve lesions.
- Explain the major types of cord lesions and their characteristics and mechanisms.

Please visit us at www.Groupinsiders.com

© DeVry/Becker Educational Development Corp. All rights reserved.

2 Typical Spinal Nerve

The structure and distribution of a typical spinal nerve is shown below:

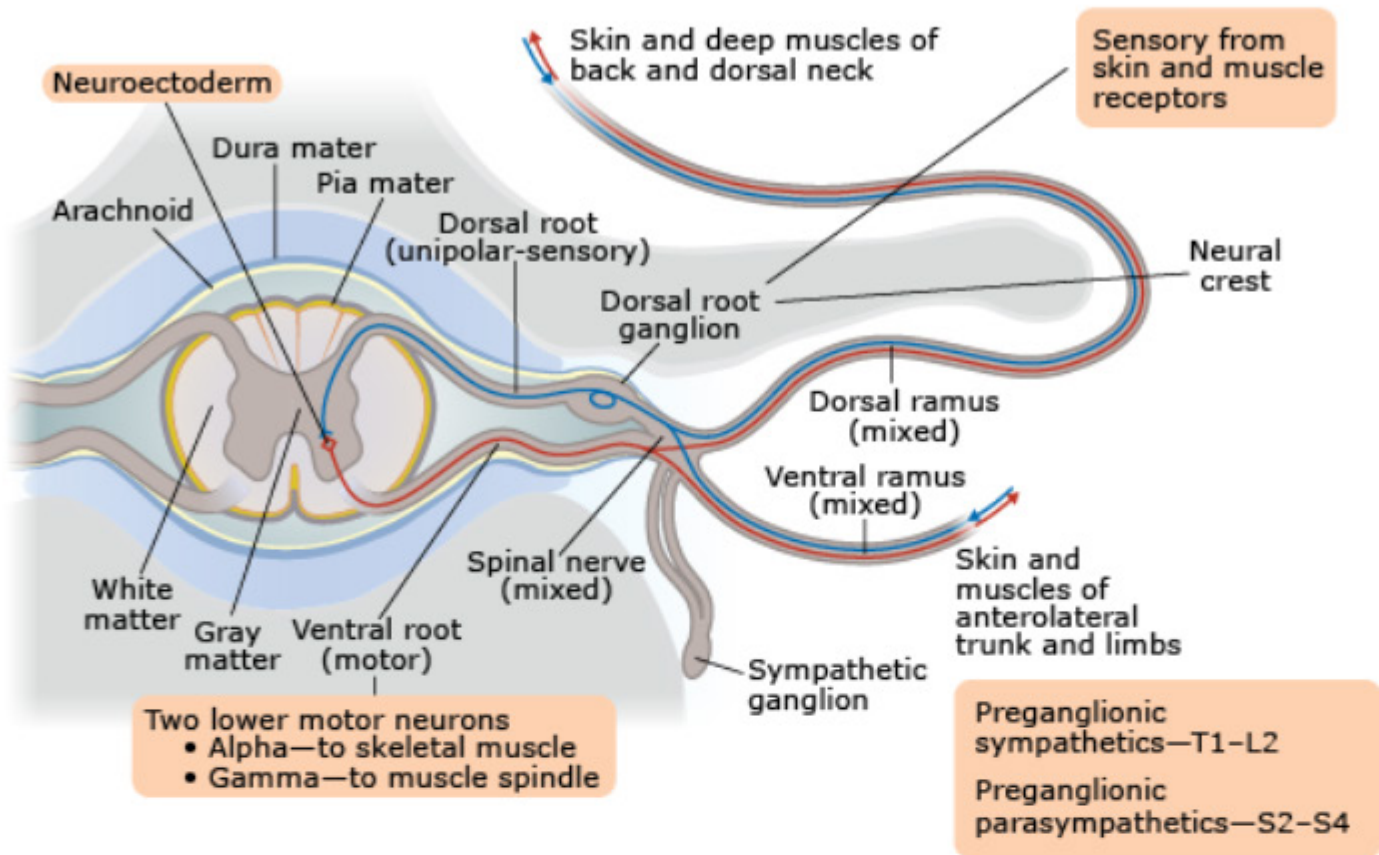

▲ **Figure 16–2.0** Spinal Nerve Distribution

- **Dorsal Root:** The *dorsal roots* of spinal nerves attach to the dorsal entry zone of the cord and transmit *afferent* (sensory) information from peripheral sensory receptors to the spinal cord. Each dorsal root contains a *dorsal root ganglion* that houses the cell bodies of the sensory neurons coursing in the dorsal root (pseudounipolar or unipolar neurons). The unipolar neurons have a single process extending from the cell body that divides into central and peripheral processes.
  - The *peripheral processes* of the unipolar neurons extend peripherally through the spinal nerve complex and receive information from sensory receptors.
  - The *central processes* of the unipolar neurons pass through the dorsal root of the spinal nerve and enter the spinal cord for connections in the CNS. The central processes at the dorsal root entry zone are organized into *medial* (epicritic and proprioceptive fibers) and *lateral* (protopathic) divisions. Medial division fibers (1a, 1b, and A-beta) are larger and heavily myelinated. Lateral division fibers are smaller and thinly myelinated (A-delta) or unmyelinated (C) fibers (discussed on next page).

Please visit us at www.Groupinsiders.com

© DeVry/Becker Educational Development Corp. All rights reserved.

- **Ventral Root:** The *ventral roots* attach to the ventral surface of the cord and distribute *motor (efferent) innervation*, somatic and visceral, from the CNS to the periphery. The cell bodies of these motor neurons are located within the gray matter of the spinal cord. The ventral roots contain alpha and gamma lower motor neurons (LMN) and also contain preganglionic neurons in certain ventral roots.
- **Spinal Nerve:** The dorsal and ventral roots merge immediately distal to the dorsal root ganglion to form the *spinal nerve* at the intervertebral foramen. Spinal nerves are mixed nerves carrying motor and sensory fibers.
- **Rami:** External to the intervertebral foramen, the spinal nerve immediately divides into dorsal and ventral *rami* that distribute motor and sensory neurons throughout the PNS:
  - *Dorsal rami* (31) provide segmental motor, sensory, and autonomic innervations for the back (dorsum) and posterior neck: Skin, intrinsic deep muscles, and the joints of the vertebral column.
  - *Ventral rami* (31) provide motor, sensory, and autonomic innervations for the skin and muscles of the anterior and lateral trunk and limbs. Many of the ventral rami fuse with each other to form peripheral nerve plexuses (brachial, cervical, and lumbosacral). Other ventral rami (T1–T12) remain single and form intercostal and subcostal nerves.
- The spinal nerves are connected to the sympathetic chain via *white and gray rami communicans*.

Please visit us at www.Groupinsiders.com

© DeVry/Becker Educational Development Corp. All rights reserved.

3 Internal Structure of the Spinal Cord

In a transverse section of a spinal cord segment, the spinal cord is organized into two mantles, or layers (Figures 16–3.0A and 16–3.0B): *white matter* and *gray matter*.

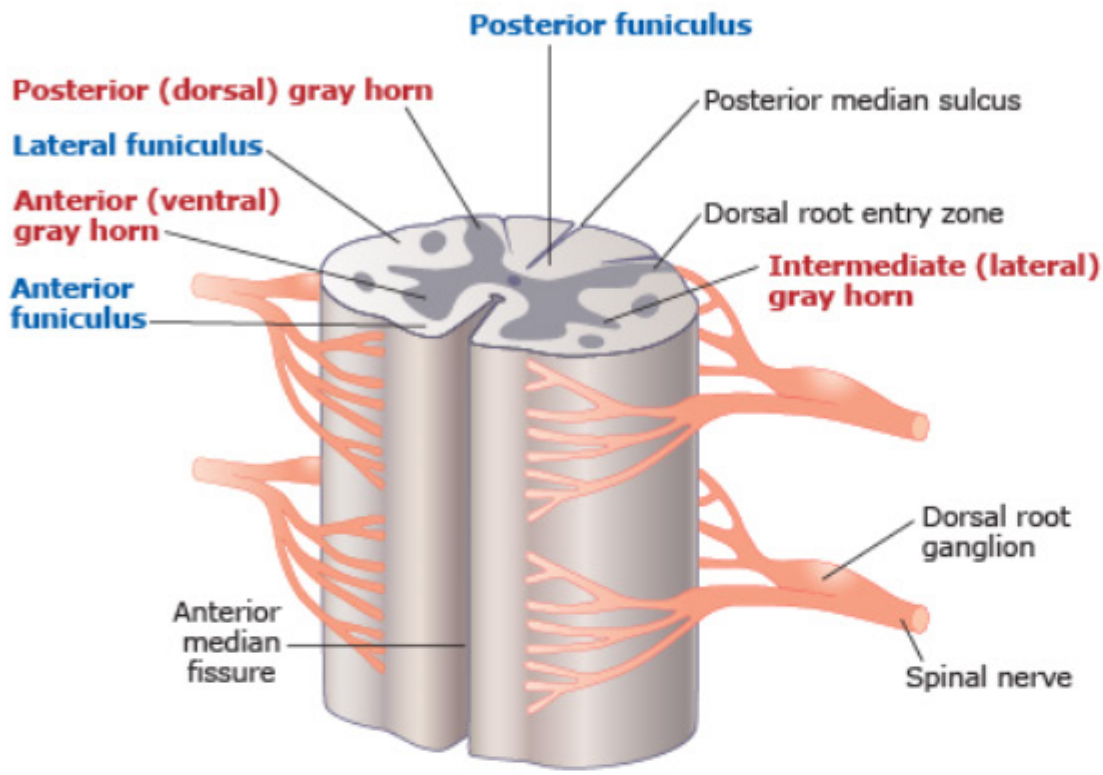

White matter
- Myelinated long tracts
- Few glial cells
- Divided into:
  - —Posterior funiculus
  - —Lateral funiculus
  - —Anterior funiculus

Gray matter
- Nuclei, dendrites, many glial cells
- Divided into:
  - —Dorsal horn—sensory
  - —Ventral horn—lower motor neurons: alpha and gamma
  - —Intermediate (lateral) horn (T1-L2)—Preganglionic sympathetic

Lesions of long tracts
result in motor/sensory deficits at and **below** the lesion, contralateral or ipsilateral

Lesions of gray matter
result in ipsilateral motor/sensory deficits **at the level** of the lesion

▲ **Figure 16–3.0A** Organization of the Spinal Cord

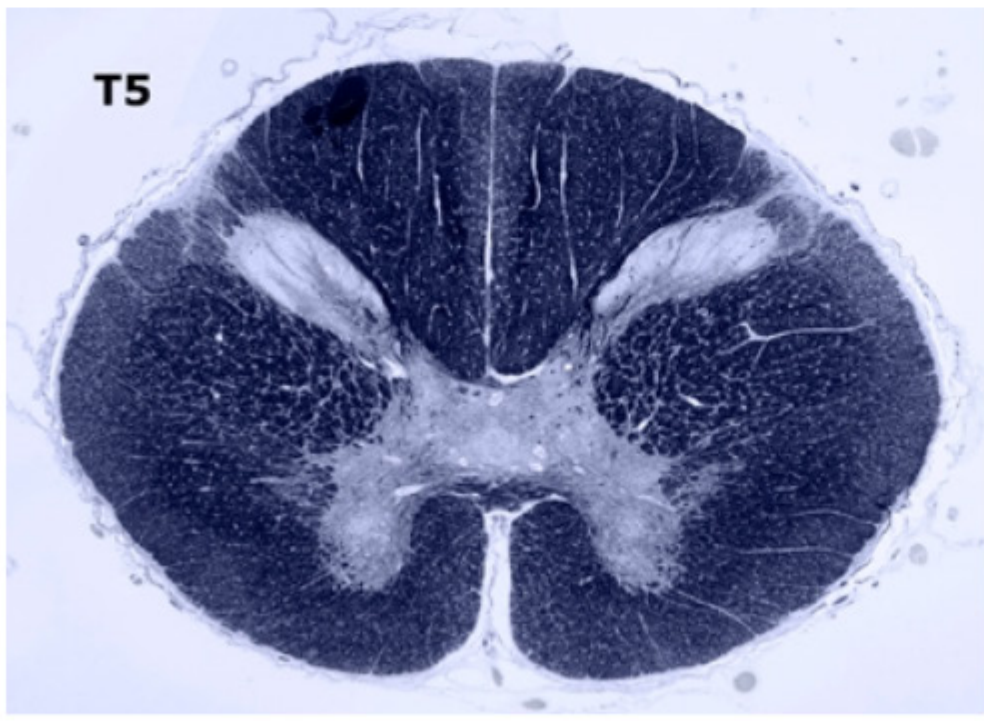

Jean-Claude Revy-ISM/Phototake, Inc.

▲ **Figure 16–3.0B** Spinal Cord Cross Section

Important Concept

1. Long tract lesions in white matter result in deficits that are *at and below the lesion*, either ipsilateral or contralateral.
2. Gray matter lesions result in deficits that are *ipsilateral and at the level of the lesion*.

Please visit us at www.Groupinsiders.com

© DeVry/Becker Educational Development Corp. All rights reserved.

3.1 White Matter

The external mantle or layer of the spinal cord forms the white matter. The white matter contains a few glial cells, but mostly bundles of myelinated axons organized into ascending and descending long tracts. The *ascending long tracts* are sensory in function and provide sensory information from the trunk and limbs to higher brain centers. The *descending long tracts* are *motor* in function and are involved with volitional and reflex contractions of skeletal muscles of the trunk and limbs. The white matter is divided into areas called *funiculi* (dorsal, lateral, and ventral).

3.2 Gray Matter

The internal mantle or layer of the spinal cord forms the H- or butterfly-shaped central gray matter, which contains groups of neuronal cell bodies, organized into *nuclei*, along with many glial cells and initial segments of axons. The gray matter is organized into areas called *dorsal, ventral,* and *lateral horns* that contain laminae of nuclei (10 Rexed laminae) of nerve cell bodies.

Important Concept

- Rexed layers 1-VI in dorsal horn
- Rexed layers VIII-IX in ventral horn
- Rexed layer VII in lateral horn

Important Concept

Alpha motor neurons innervate skeletal muscle (extrafusal muscle)

Gamma motor neuron innervate muscle spindle (intrafusal muscle)

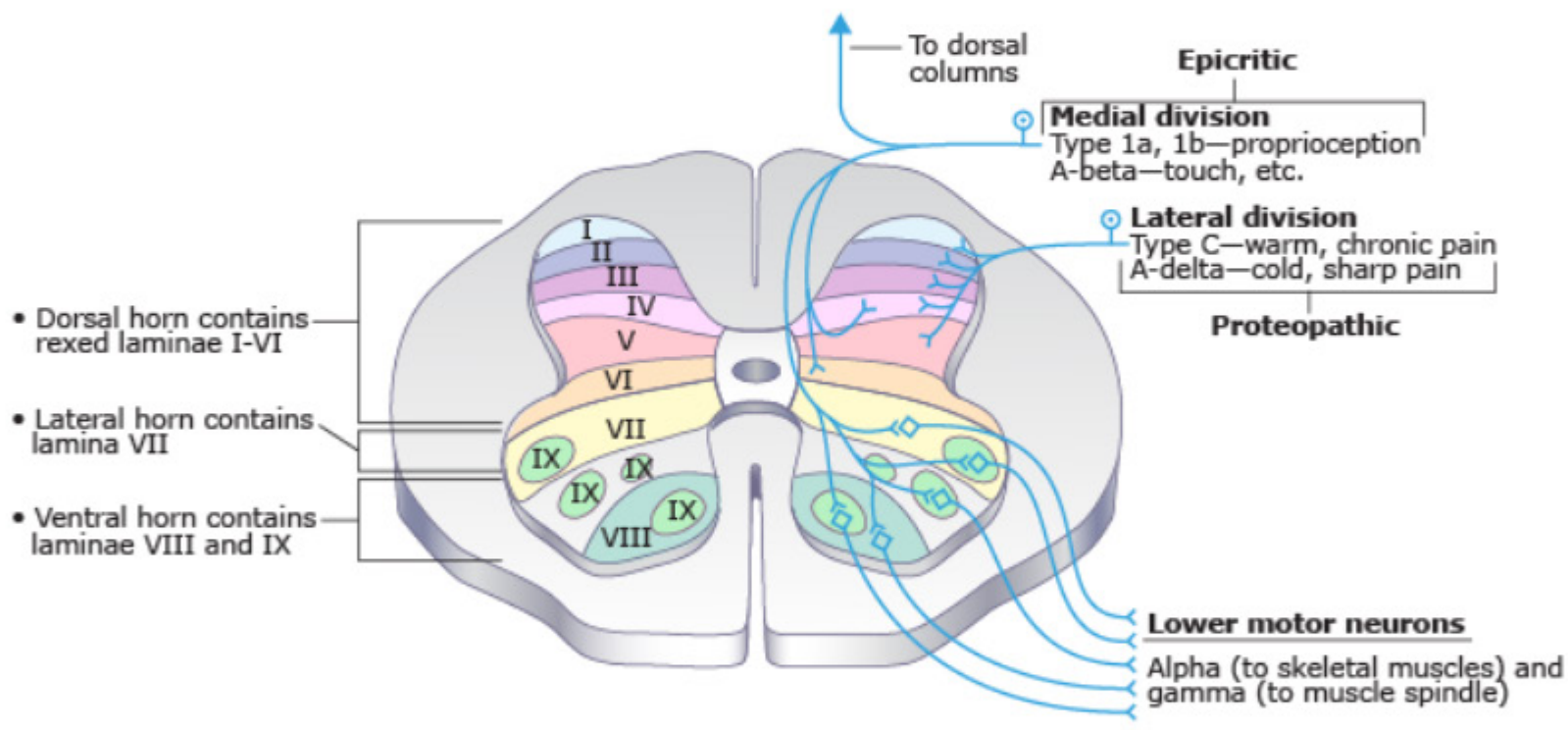

▲ **Figure 16–3.2A** Organization of Gray Matter

- **Dorsal Horn:** The *dorsal horn* contains laminae of neurons (Rexed layers I–VI) that are *sensory* in function and are found in all segments of the cord. The nuclei in the dorsal horn mostly receive central processes of unipolar neurons in the lateral division of the dorsal root. These fibers primarily process pain and temperature. Some of the deeper nuclei of the dorsal horn also deal with reflexes.

Please visit us at www.Groupinsiders.com

© DeVry/Becker Educational Development Corp. All rights reserved.

- **Ventral Horn:** The *ventral horn* is motor in function and contains two groups of lower motor neurons (Rexed layers VIII and IX): alpha and gamma. The *alpha motor neurons* innervate the extrafusal skeletal muscle fibers at the neuromuscular junction, whereby the *gamma motor neurons* innervate intrafusal skeletal muscle fibers within the muscle spindle involved in regulating muscle tone and reflexes. There is a somatotopic arrangement of the neurons in the ventral horn:
  - *The neurons* providing innervation to *extensor muscles* are located *ventrally*, and the neurons providing innervation to *flexor muscles* are located *dorsally* in the ventral horn.
  - The neurons that innervate *axial musculature* of the trunk are located *medially* in the ventral horn, and the neurons innervating muscles in the *distal* limbs are located *laterally* in the ventral horn.
- **Lateral (Intermediate) Horn**: The lateral horn is not found in all cord segments, but is located in cord segments T1–L2, where it is called the *intermediolateral cell column.* The lateral horn contains *preganglionic sympathetic* neuronal cell bodies of the ANS. It also contains the Clarke nucleus, which is a relay nucleus for unconscious proprioception from the lower limb to the cerebellum.

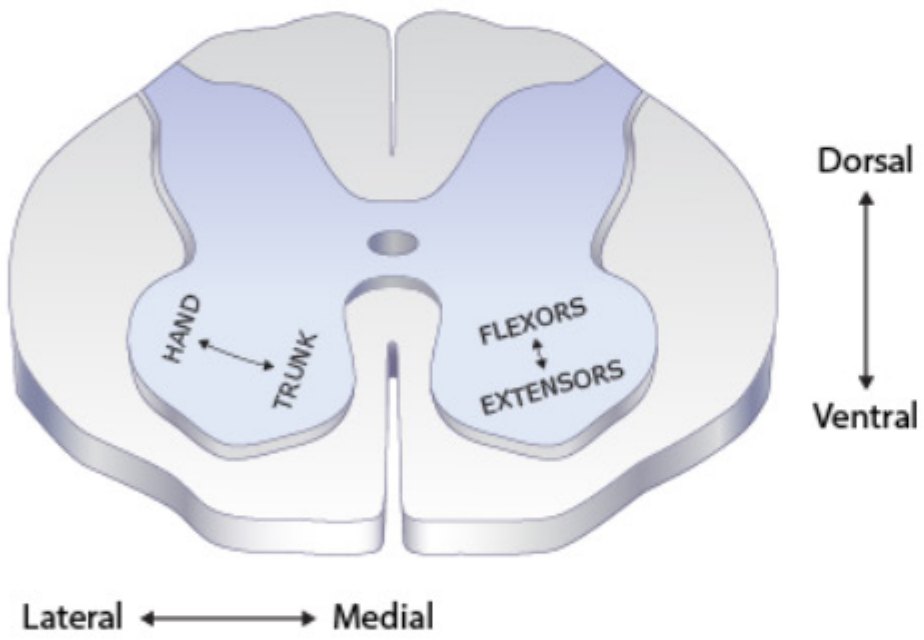

▲ **Figure 16–3.2B** Topographic Organization of Ventral Horn

Please visit us at www.Groupinsiders.com

© DeVry/Becker Educational Development Corp. All rights reserved.

4 Overview of Long Tract Systems of the Spinal Cord

The dorsal, lateral, and ventral funiculi of the white matter contain numerous ascending and descending long tract systems. The *ascending long tracts* represent sensory pathways carrying information to higher brain centers. The *descending long tracts* are motor pathways concerned with voluntary and reflex motor functions for skeletal muscles of the trunk and limbs. Most of the long tract systems run the entire axis of the CNS between the distal spinal cord and the cerebral cortex and other higher brain centers.

Of the many long tracts present, there are three major long tract systems in the cord that are critical to review. These three long tracts are important clinically and are the basis for understanding the neurology of lesions in the spinal cord:

- **Corticospinal Tract:** Descending—Motor tract to limb muscles.
- **Dorsal Columns:** Ascending—Epicritic and conscious proprioceptive long tract.
- **Spinothalamic Tract:** Ascending—Protopathic long tract.

Important Concept

When evaluating a long tract, ask three questions:

1. How many neurons?
2. Where are the cell bodies located and the general pathway of the tract?
3. Where does the pathway decussate?

Please visit us at www.Groupinsiders.com

© DeVry/Becker Educational Development Corp. All rights reserved.

5 Descending Long Tract Systems

Most of the descending motor systems in the cord are primarily concerned with either voluntary or reflex control of skeletal muscles. The typical descending motor system is formed by two neurons (upper and lower motor neurons) that decussate:

- *Upper motor neuron (UMN)* cell bodies are located in one of two places in the CNS: *cerebral cortex* or *brainstem*. In the cerebral cortex, upper motor neuron cell bodies are found in the primary and premotor cortex of the frontal lobe (Brodmann areas 4 and 6, respectively). In contrast, in the brainstem most of the upper motor neuron cell bodies are found in the red nucleus, pontine and medullary reticular formation, and the vestibular system.

  The UMN axons descend through the CNS and enter the spinal cord in a descending motor tract. The upper motor neurons synapse on lower motor neurons (or interneurons) in the ventral horn to initiate a contraction of skeletal muscles. The UMN usually begins on the contralateral side of the CNS from the lower motor neurons and skeletal muscles that they innervate. Note that the entire course of the upper motor neuron is in the CNS.

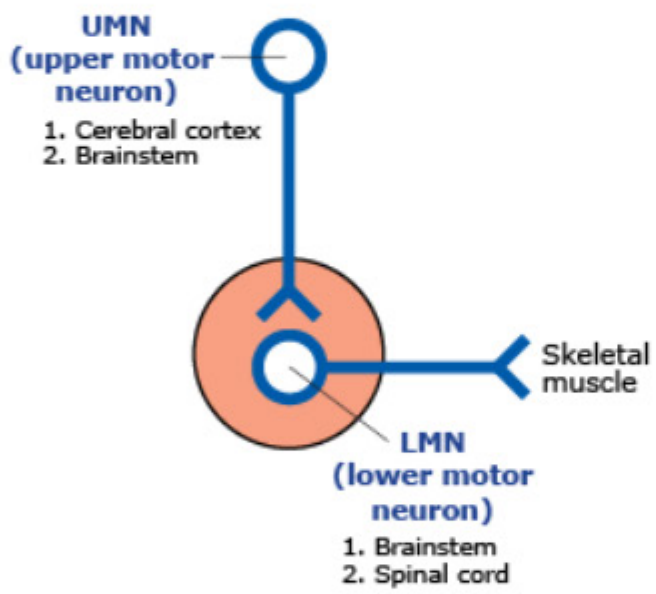

▲ **Figure 16–5.0** Organization of Descending Long Tract

- *Lower motor neuron (LMN)* cell bodies are also found in one of two places in the CNS: nuclei in the *ventral horn of the spinal cord* and the *cranial nerve motor nuclei in the brainstem*. The axons of the lower motor neurons exit the CNS either in the ventral root of the spinal nerve or in a cranial nerve to innervate the skeletal muscle at the motor end plate.

  In the ventral horn of the spinal cord, there are two types of LMN: *alpha* (to extrafusal skeletal muscles at the motor end plate) and *gamma* (to intrafusal skeletal muscle fibers in the muscle spindle). LMN are always on the ipsilateral side of the CNS to the muscles they innervate.

Please visit us at www.Groupinsiders.com

© DeVry/Becker Educational Development Corp. All rights reserved.

5.1 Corticospinal Tract

Voluntary contraction consists of a two-neuron chain:
1. The upper motor neuron (UMN) is located in the cerebral cortex.
2. The lower motor neuron (LMN) is a ventral horn cell located in the spinal cord.

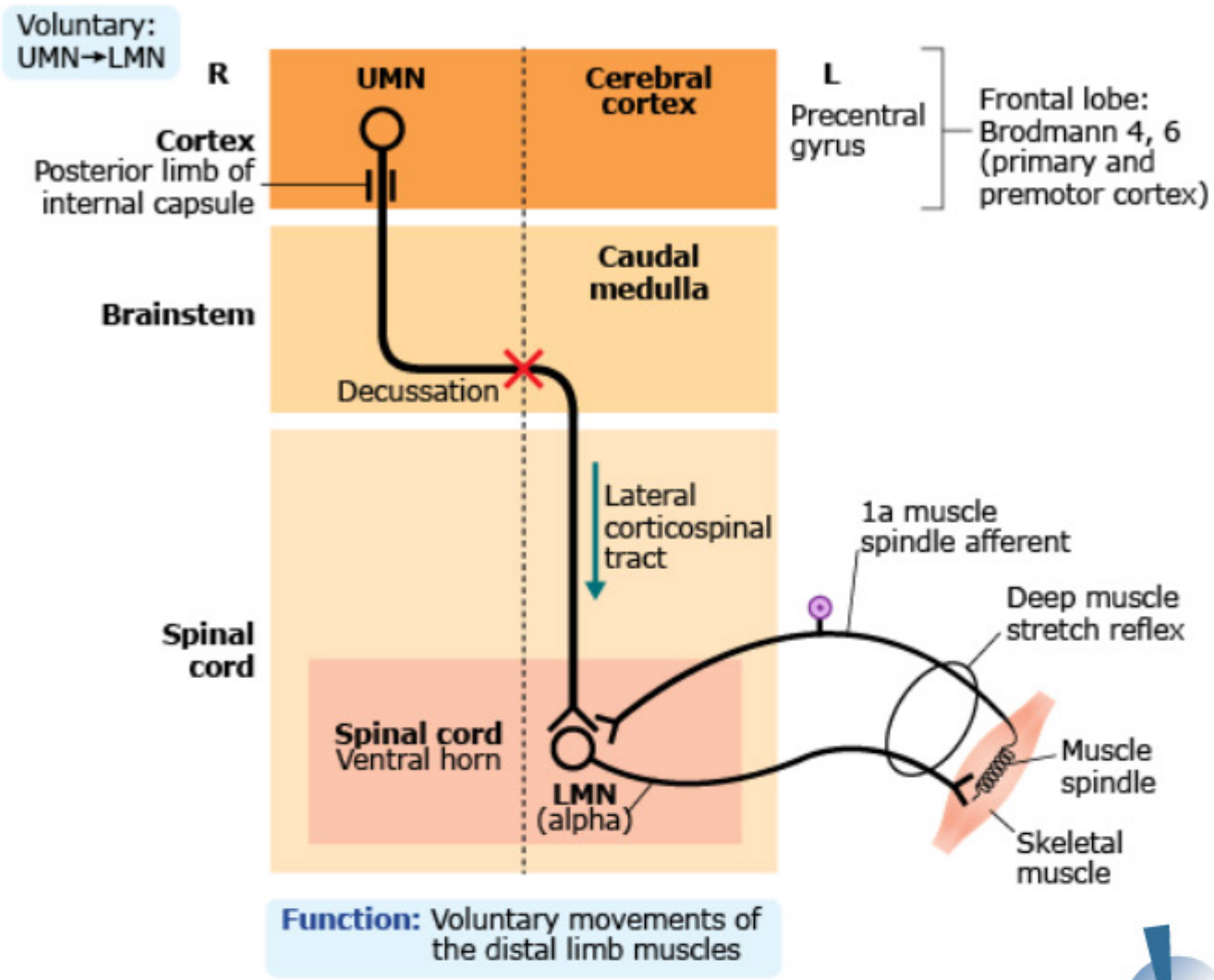

▲ **Figure 16–5.1A** Corticospinal Tract

The *corticospinal tract* is the primary descending motor system under review because of its extreme importance in providing highly skilled, volitional motor control of limb muscles, primarily distal limb muscles. A few other descending motor systems will be briefly mentioned later in the notes. The components of the corticospinal tract are outlined below:

- The majority of the UMN cell bodies (60%) of the corticospinal tract are located in the *primary* and *premotor cortex* of the *frontal lobe* (Brodmann areas 4 and 6, respectively) immediately anterior to the central sulcus. The remainder of the cell bodies are found in the somatosensory cortex of the postcentral gyrus of the parietal lobe.
- The axons exit the cortex by passing through the *posterior limb of the internal capsule.*
- The fibers of the corticospinal tract then descend through the ventral aspect of brainstem.
- At the level of the *caudal medulla* (ventral surface), most of the upper motor axons (90%) of the corticospinal tract *decussate* at the pyramidal decussation and descend the contralateral side of the spinal cord.

Important Concept

Above the decussation, the upper motor neurons course on the side of the nervous system contralateral to the LMN and the moving muscles. However, below the decussation in the spinal cord, the upper motor neurons of the corticospinal tract are on the side of the cord ipsilateral to the LMN and the moving muscle. Note that the lower motor neuron is always on the ipsilateral side of the CNS of the moving muscle. Therefore, stimulation of upper motor neurons on one side of the cortex results in excitation of lower motor neurons and muscles on the contralateral side. Identifying the level of decussation in a long tract is very important when determining the side of a lesion, ipsilateral or contralateral.

Please visit us at www.Groupinsiders.com

© DeVry/Becker Educational Development Corp. All rights reserved.

- In the spinal cord, the upper motor neurons of the corticospinal tract descend in the dorsal aspect of the lateral funiculus of the white matter through the entire length of the spinal cord.
- At each spinal cord segment, some of the UMN fibers peel from the corticospinal tract and enter the ventral horn, where they synapse on the *alpha and gamma lower motor neurons*.
- The *lower motor neuron axons* leave the spinal cord via the ventral roots of the spinal nerves and distribute in the PNS via the spinal nerve in either the dorsal or ventral rami to reach the motor end plate of the skeletal muscles.

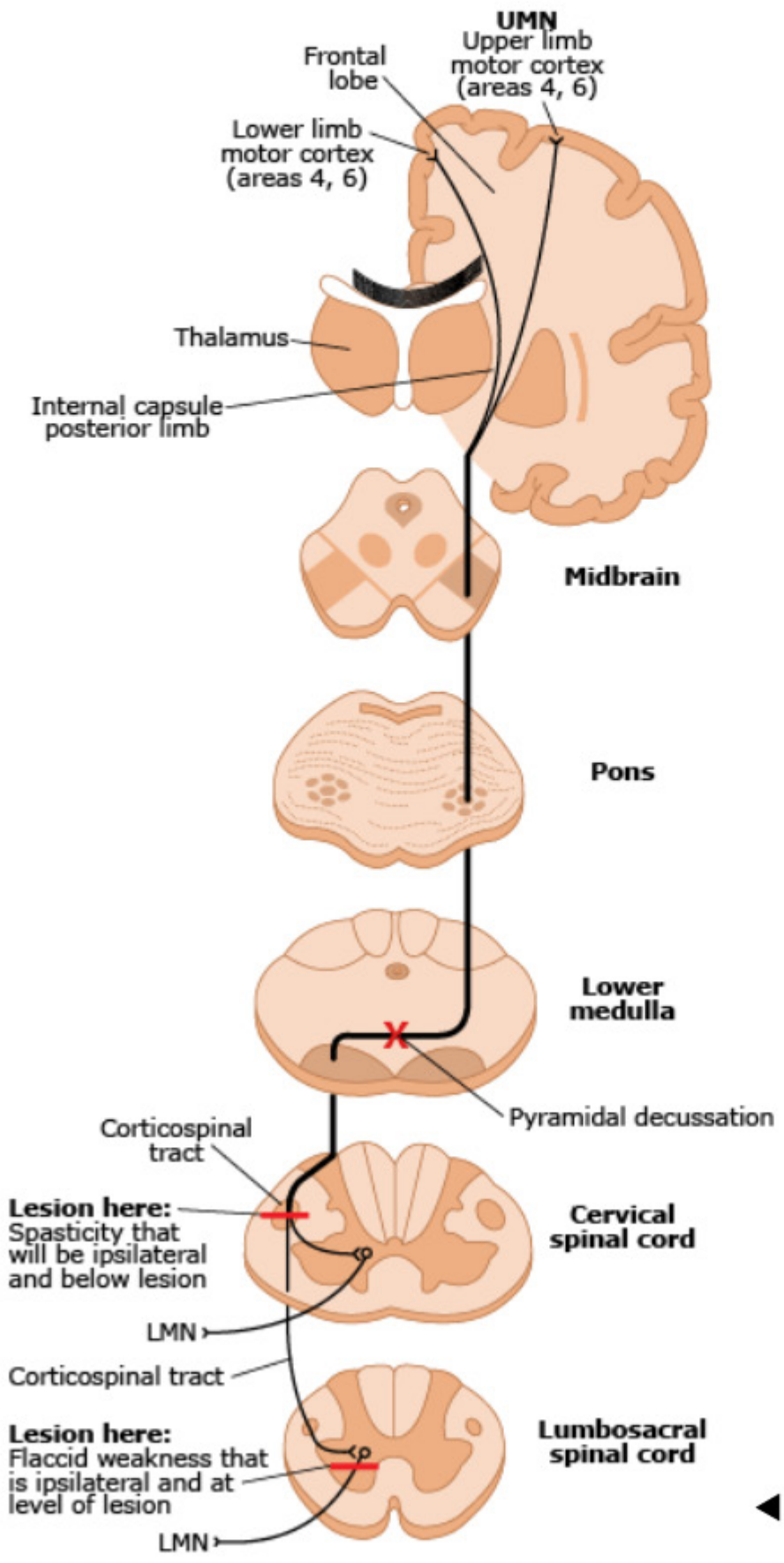

◀ **Figure 16–5.1B** Corticospinal Tract with Cross Sections

Please visit us at www.Groupinsiders.com

© DeVry/Becker Educational Development Corp. All rights reserved.

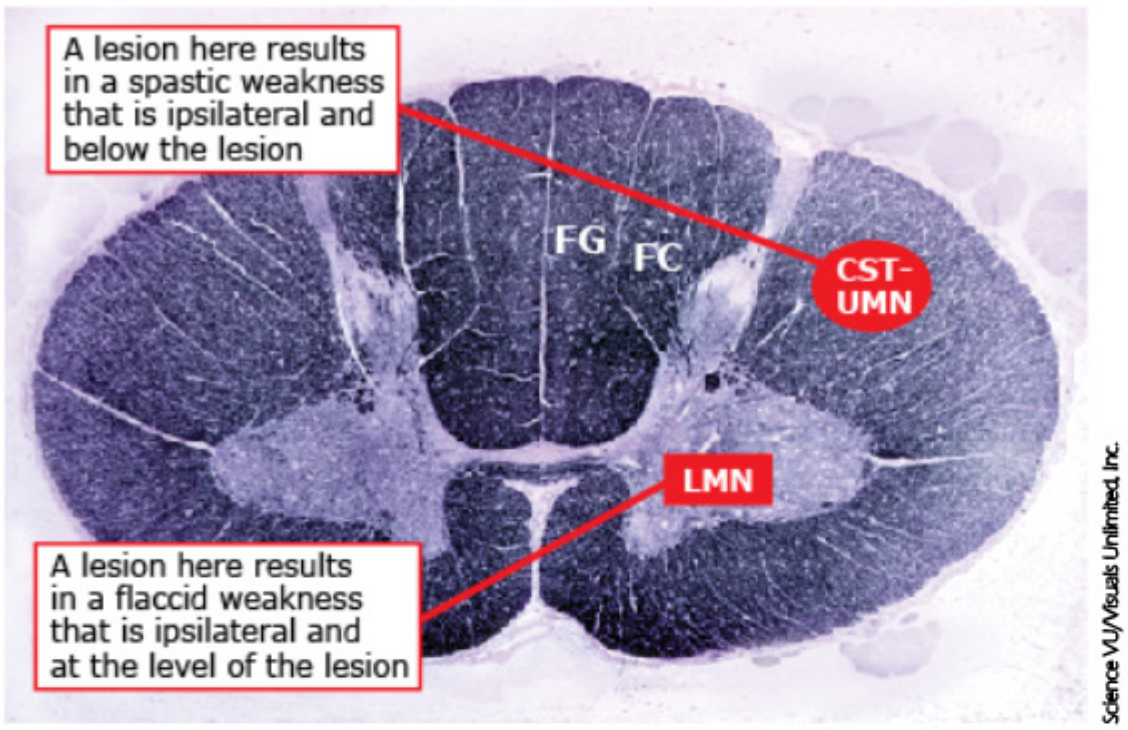

▲ **Figure 16–5.1C** Motor Systems of Spinal Cord

5.2 Lesions of Corticospinal Tract

Because the corticospinal tract extends considerable distances through many levels of the CNS, it is susceptible to numerous vascular, trauma, tumor, or demyelination lesions at various levels of the CNS. Noting the level of the decussation is critical in localizing the lesion.

- If the UMN lesion is *above the decussation* between the cortex and the decussation of the pyramids at the lower medulla, *spastic paresis* will be below the lesion and on the *contralateral* side of the body.
- If the UMN lesion is *below the decussation* in the corticospinal tract of the spinal cord, spastic paresis will be *below the lesion* and on the *ipsilateral side*.
- Because cell bodies of lower motor neurons are on the same side as the moving muscle, a lesion anywhere along the course of the lower motor neuron (central or peripheral) will result in *flaccid paralysis* that is *at the level of the lesion* and ipsilateral.

Please visit us at www.Groupinsiders.com

© DeVry/Becker Educational Development Corp. All rights reserved.

6 Reflex Innervation of Skeletal Muscles

Reflex contractions of skeletal muscles are involuntary motor responses to a sensory stimulus. Reflex innervation of skeletal muscles requires a minimum of two neurons: (1) a sensory neuron that initiates a motor response from (2) lower motor neurons. Reflexes range from simple two-neuron circuits to more complex reflexes that use multiple interneurons in addition to the sensory and motor neurons.

6.1 Deep Muscle Stretch (Myotatic) Reflex

- The *deep muscle stretch reflex* is the simplest of the reflexes and involves only one synapse between one sensory and one motor neuron. Testing the integrity of deep muscle stretch reflexes in the limbs provides important clinical information when assessing different types of motor weaknesses and dysfunction.
- The deep muscle stretch reflex is present in most skeletal muscles and provides the important *physiological mechanism of regulating and maintaining proper muscle tone* throughout the skeletal muscular system. Some of the more common tested reflexes are shown below.

▼ **Table 16–6.1** Common Tested Reflexes

Ankle Reflex	Sacral 1
Knee reflex	Lumbar 2, 3, 4 (Femoral N)
Ankle reflex	S1 (Tibial N)
Biceps reflex	Cervical 5, 6 (Musculocutaneous N)
Triceps reflex	Cervical 7, 8 (Radial N)

- The two neurons of a deep muscle stretch reflex are discussed below (Figures 16–6.1A and 16–6.1B):

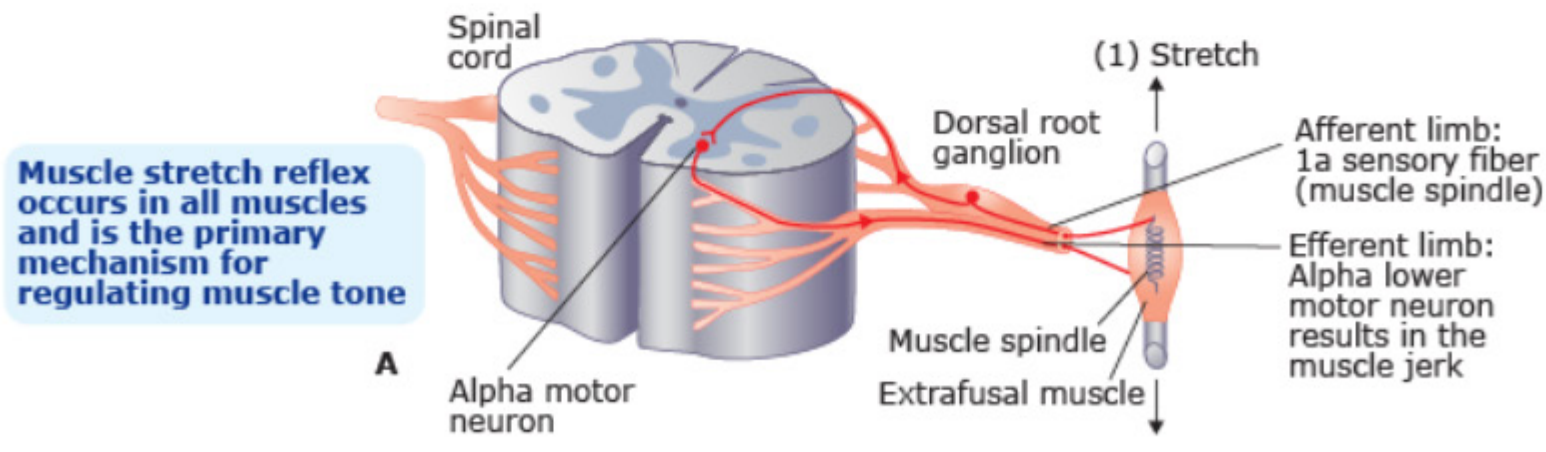

▲ **Figure 16–6.1A** Deep Muscle Stretch (Monosynaptic) Reflex

Please visit us at www.Groupinsiders.com

© DeVry/Becker Educational Development Corp. All rights reserved.

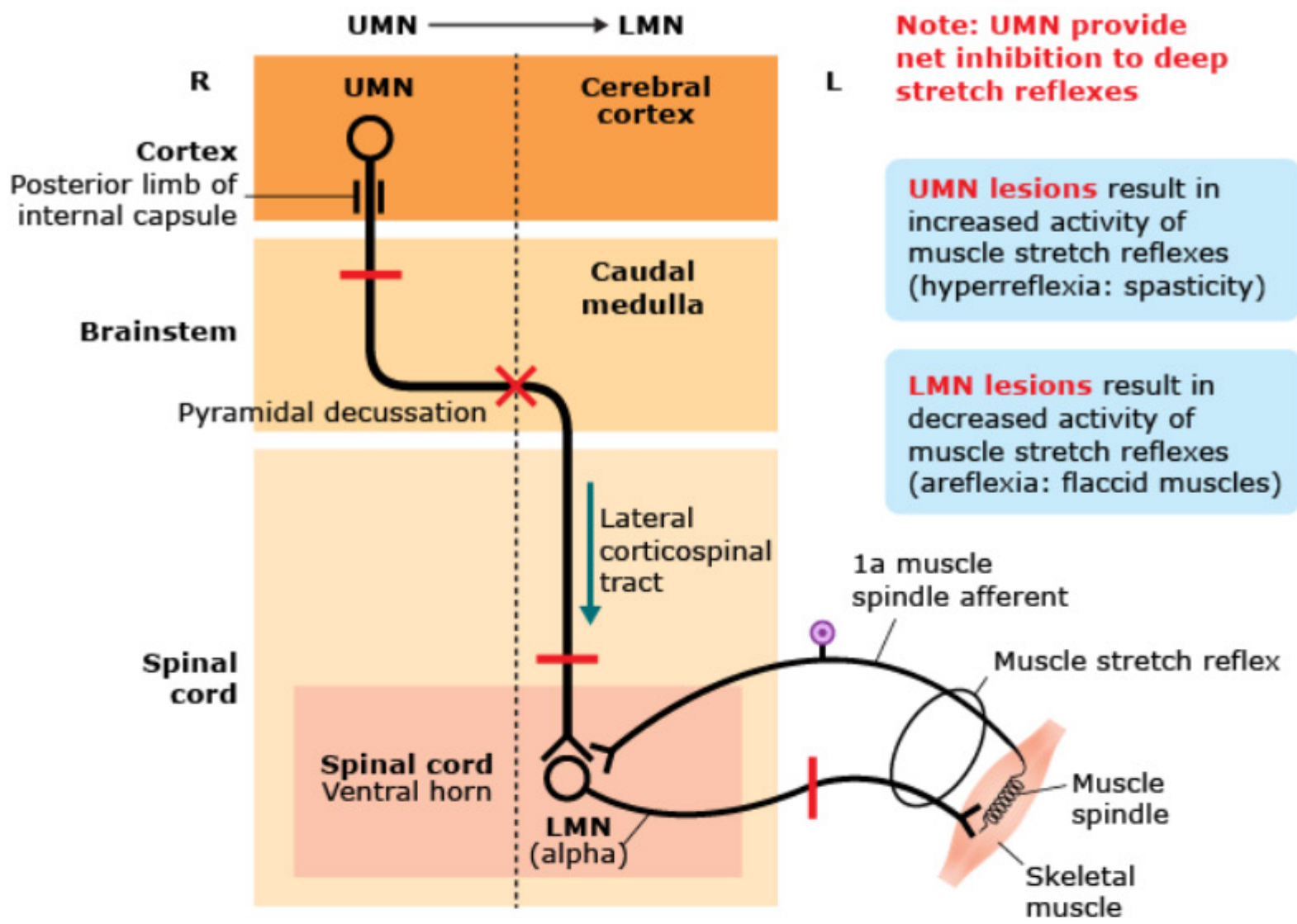

▲ **Figure 16–6.1B** Upper and Lower Motor Neuron Lesions

1. The sensory receptor involved in the initiation of the deep muscle stretch reflex is the *muscle spindle*. Muscle spindles are sensory receptors embedded in skeletal muscles that are arranged in parallel with the muscle fibers. Muscle spindles respond to stretching of the muscle and the change in length and the force and rate of change in length of the extrafusal muscle fibers. The muscle spindle initiates a sensory stimulus using the *1a sensory neuron*. The central processes of the 1a neuron enter the spinal cord via the dorsal root of the spinal nerve and synapse directly on the alpha lower motor neuron in the ventral horn. The 1a fibers also provide reciprocal inhibition, which inhibits alpha neurons of the antagonist muscles.
2. The *motor* component of the reflex is the *alpha lower motor neuron* in the ventral horn of the spinal cord. The lower motor neuron results in contraction of the extrafusal muscle fibers and the muscle jerk.

Please visit us at www.Groupinsiders.com

© DeVry/Becker Educational Development Corp. All rights reserved.

6.1.1 Upper Motor Neuron Control of Deep Muscle Stretch Reflex

Upper motor neuron systems, like the corticospinal tract, play a role in regulating muscle tone and have a *net inhibitory control over muscle stretch reflexes*. An upper motor neuron lesion results in hyperactive reflexes (*spasticity*) (Figures 16–6.1C and 16–6.3B).

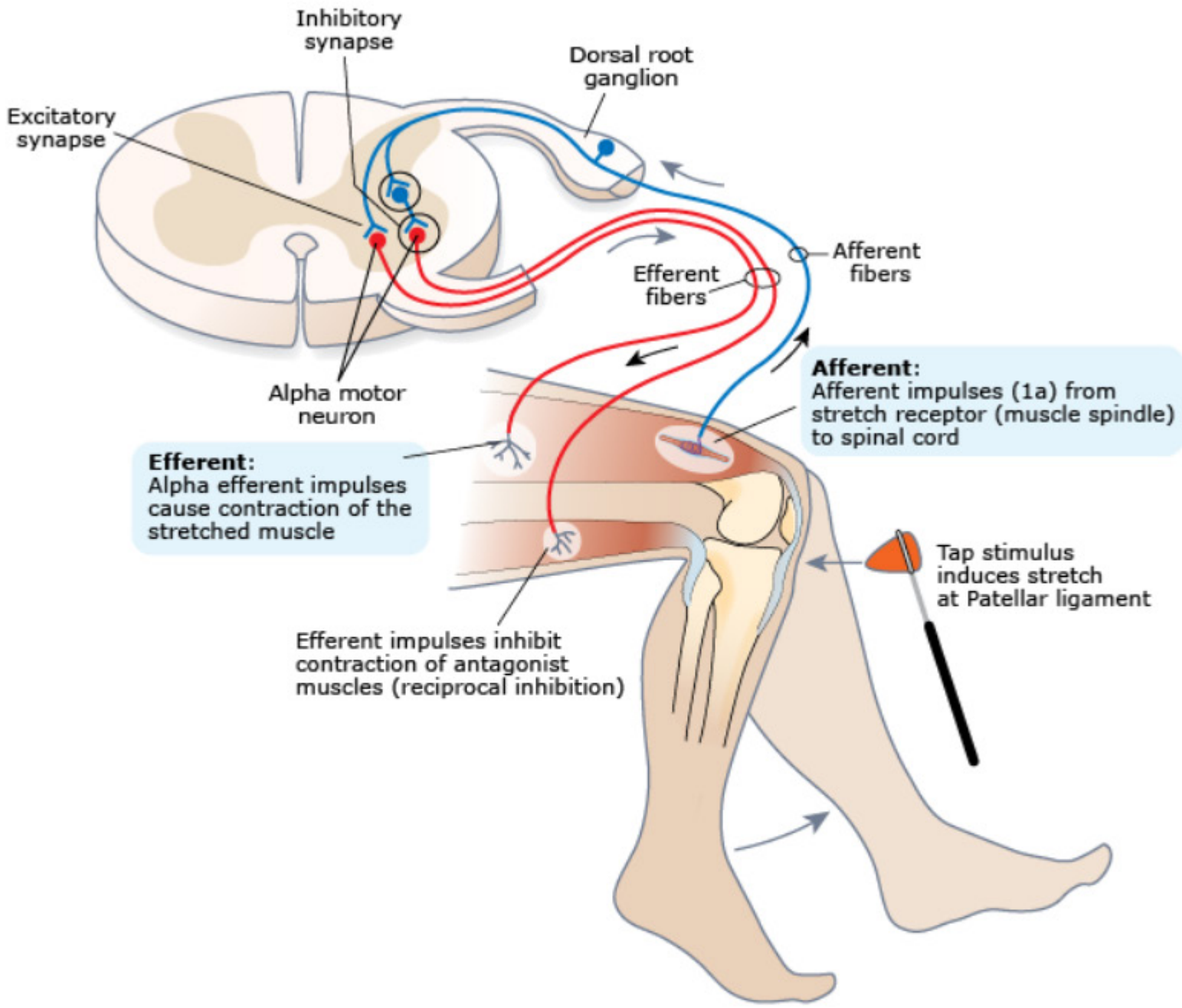

▲ **Figure 16–6.1C** Muscle Stretch Reflex

Please visit us at www.Groupinsiders.com

© DeVry/Becker Educational Development Corp. All rights reserved.

6.2 Gamma Motor Neurons

Muscle spindles contain a strip of modified skeletal muscle fibers called the *intrafusal muscle*. The intrafusal muscle fibers are innervated by the *gamma neurons* in the ventral horn that are coactivated by upper motor neurons at the same time as the alpha motor neurons. The gamma neuron ensures that the stretch reflex stays active during contraction of the extrafusal muscle when one would anticipate that the muscle spindle would be unloaded and would go quiet. Thus, the gamma neurons innervate the muscle spindle and modulate their sensitivity to stretch during movement. Contraction of the intrafusal muscle fibers activates sensory firing of the 1a neuron, which then activates the alpha lower motor neurons, resulting in increased muscle tone. This circuitry is referred to as the *gamma loop*.

6.3 Inverse Myotatic Reflex

The *inverse myotatic reflex* provides the opposite effect from the deep muscle stretch reflex. The inverse reflex uses another sensory receptor called *Golgi tendon organs,* which are imbedded in the tendons of the skeletal muscles. The Golgi receptors monitor the degree of tension and force placed on the skeletal muscle. Stimulation of these receptors results in the firing of *1b afferent neurons* that route through the dorsal roots back into the ventral horn of the spinal cord to *inhibit* the alpha motor neurons and *decrease* contraction of the muscle.

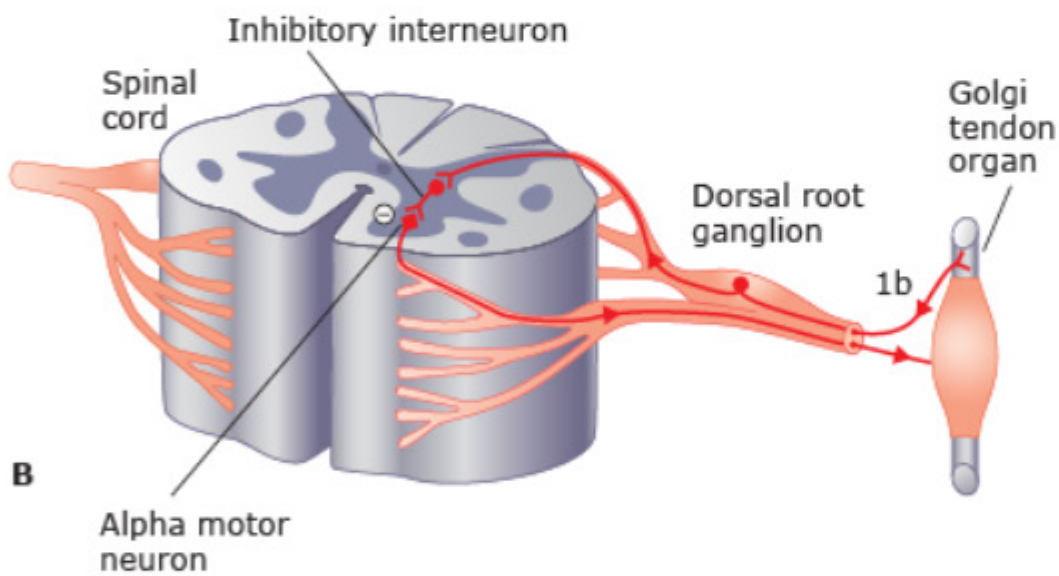

▲ **Figure 16–6.3A** Inverse Myostatic Reflex

Please visit us at www.Groupinsiders.com

© DeVry/Becker Educational Development Corp. All rights reserved.

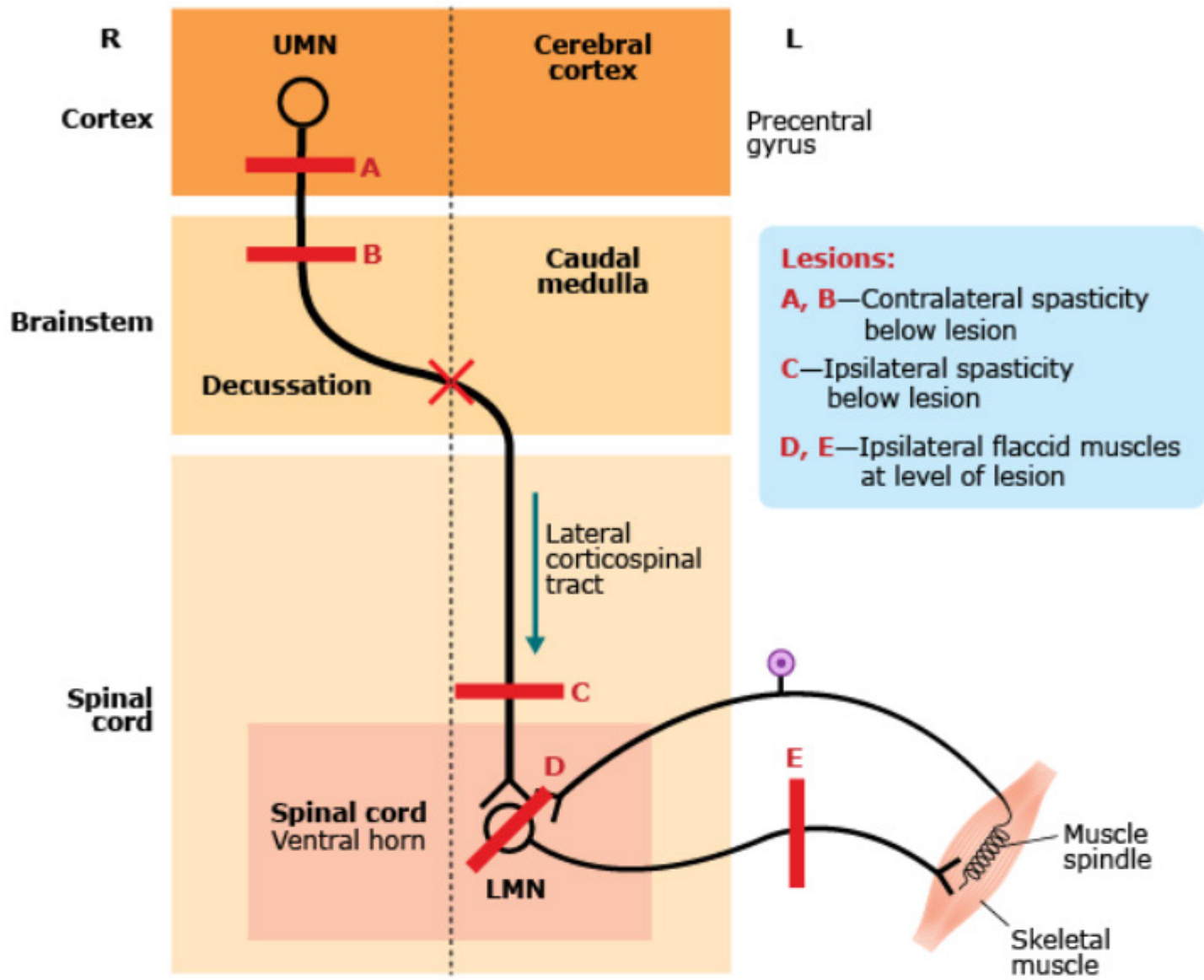

▲ **Figure 16–6.3B** Contralateral vs. Ipsilateral Lesions

Lesion strategies for upper and lower motor neuron lesions are shown in Table 16–6.3.

▼ **Table 16–6.3** Comparison of Upper and Lower Motor Neuron Lesions

Upper Motor Neuron Lesion (deficits contralateral or ipsilateral and below level of the lesion)	Lower Neuron Lesion (deficits ipsilateral and at the level of lesion)
Spastic muscles	Flaccid muscles
Hyperreflexia	Areflexia
Babinski sign present (extensor reflex)	Babinski absent
Increased muscle tone (hypertonic)	Decreased muscle tone or atonia
Clonus	Fibrillations
Clasp knife reflex (hyperactive Golgi tendon)	Fasciculations
Disuse atrophy of muscles	Atrophy of muscle(s)—over time
Decreased speed of voluntary movements	Loss of voluntary movements
Large area of the body involved	Small area of the body affected

Please visit us at www.Groupinsiders.com

© DeVry/Becker Educational Development Corp. All rights reserved.

7 Ascending Sensory Long Tract Systems

- *Ascending long tracts* convey sensory information from the trunk and limbs to higher brain centers. A typical sensory long tract system has three characteristics:
  1. Consists of three neurons from receptor to cortex.
  2. Usually has a decussation site.
  3. Relays through a thalamic nucleus.
- An overview of a general sensory pathway is shown in Figure 16–7.0. The two ascending long tracts discussed below follow this typical pattern.
- The areas of skin supplied by sensory fibers are segmentally divided into *dermatomes* that can be used to help identify the location of a lesion.

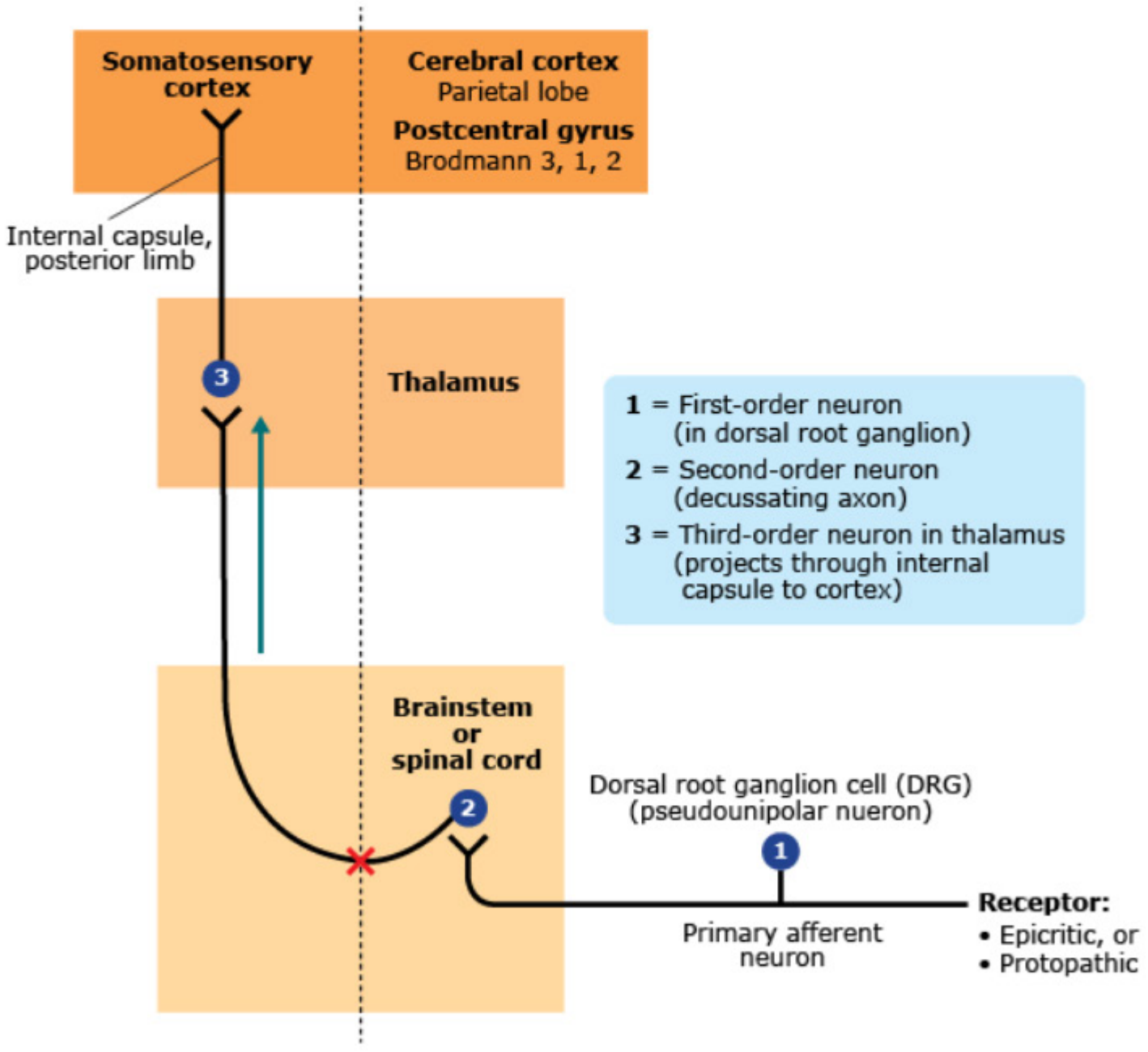

▲ **Figure 16–7.0** Typical Sensory Pathway

Please visit us at www.Groupinsiders.com

© DeVry/Becker Educational Development Corp. All rights reserved.

7.1 Dorsal Column/Medial Lemniscus Pathway

The *dorsal column/medial lemniscus* long tract conveys the following sensations:

- Epicritic sensations of *touch, two-point discrimination, vibration,* and *deep pressure* from mechanoreceptors in the skin (Pacinian corpuscles for vibration and Meissner corpuscles for touch). These sensations provide tactile sensations and allow an individual to identify the shape and texture of objects placed in the hand.
- *Conscious proprioceptive fibers* conduct sensations of limb position from muscle receptors (muscle spindles and Golgi tendon organs), which allow an individual to identify the position of a limb in space.
- The three neurons of the tract are the first-order (primary) neurons, the second-order neurons, and the third-order neurons (see Figures 16–7.1A, 16–7.1B, and 16–7.1C).

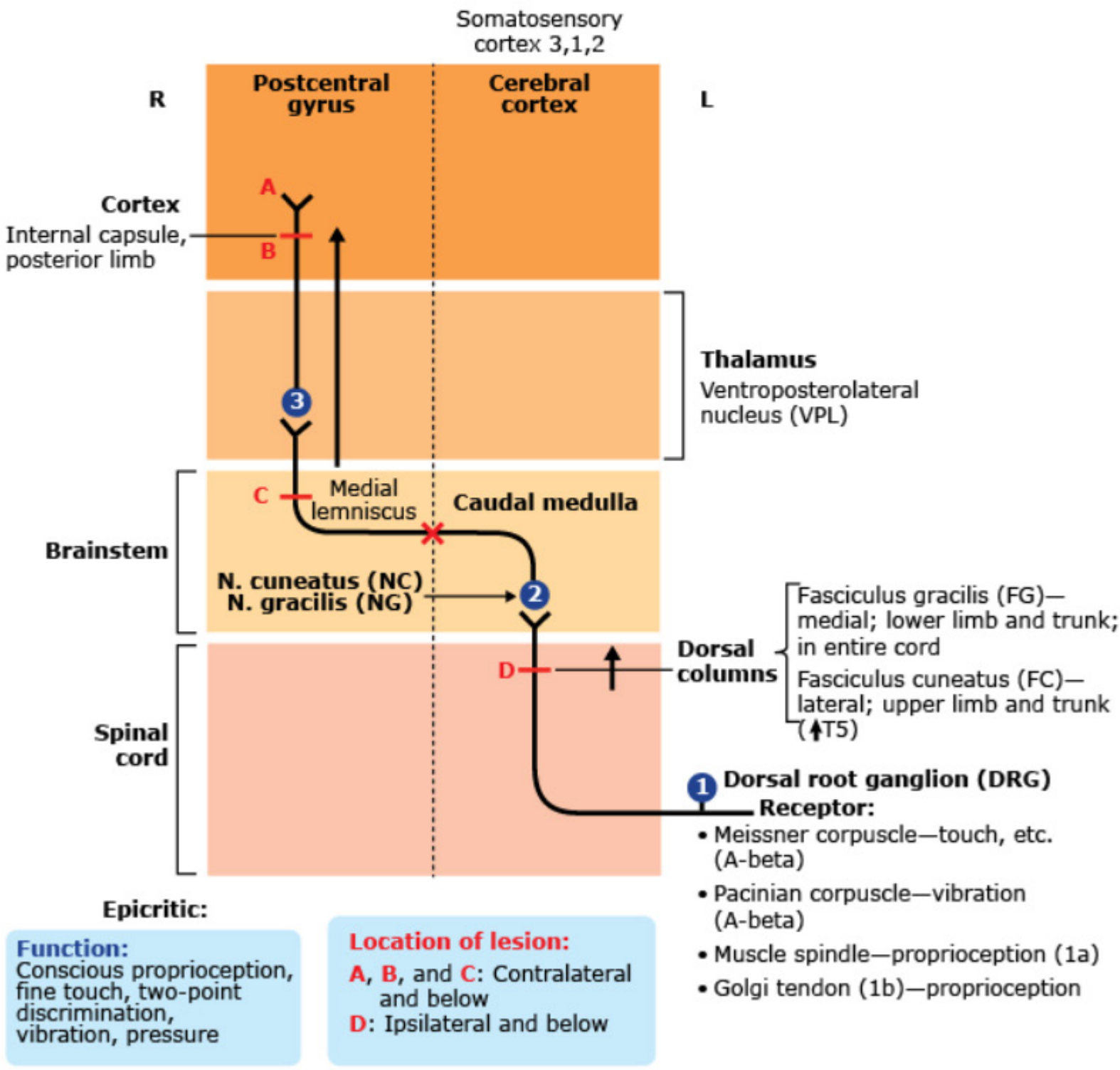

▲ **Figure 16–7.1A** Dorsal Column/Medial Lemniscus Pathway

Please visit us at www.Groupinsiders.com

© DeVry/Becker Educational Development Corp. All rights reserved.

Please visit us at www.Groupinsiders.com

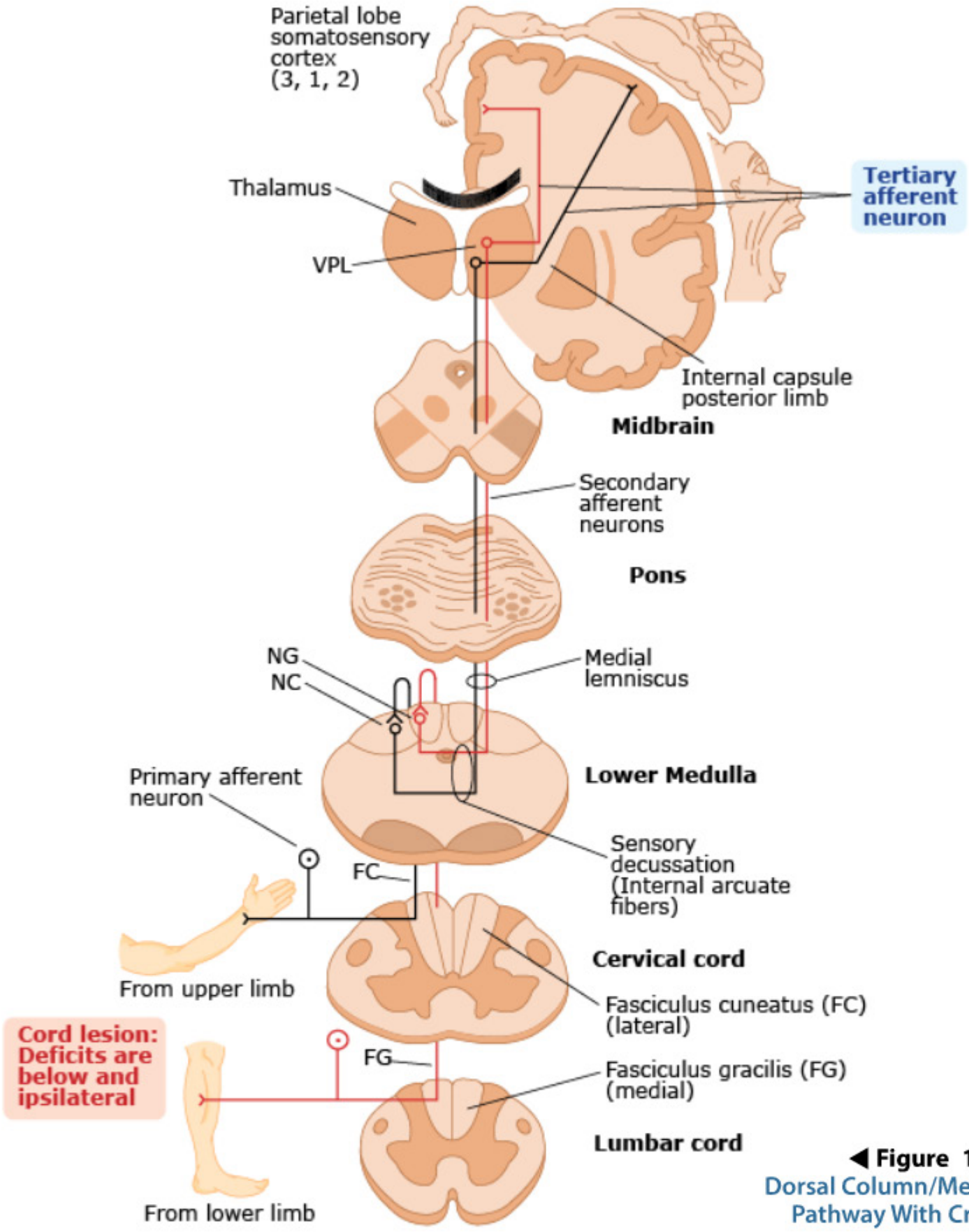

◀ **Figure 16–7.1B**
Dorsal Column/Medial Lemniscus Pathway With Cross Sections

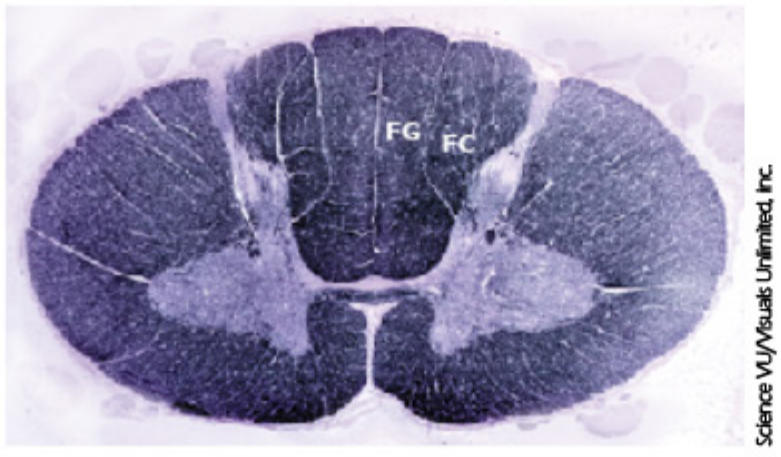

◀ **Figure 16–7.1C**
Dorsal Columns in Spinal Cord Cross Section

© DeVry/Becker Educational Development Corp. All rights reserved.

7.1.1 First-Order (Primary) Neurons

- The *primary afferent neurons* are large, fast-conducting myelinated unipolar neurons (1a, 1b, and A-beta) with cell bodies located in the *dorsal root ganglia* at each spinal nerve level.
- *Central processes* of these unipolar neurons enter the spinal cord via the medial division of the dorsal root of the spinal nerve. The central processes primarily enter the dorsal white matter, where they ascend the length of the spinal cord in the dorsal columns to reach the lower medulla, where they synapse on the second-order neurons.
- In the dorsal funiculus of the cord, the central processes of the first-order neurons form two dorsal columns: fasciculus cuneatus and fasciculus gracilis.
- *Fasciculus cuneatus* forms the *lateral* dorsal column that develops in the upper aspect of the spinal cord (above T5–T6) and relays sensory information from the upper trunk and upper limb.
- *Fasciculus gracilis* forms the *medial* dorsal column that is found in all segments of the cord and relays sensory information from the lower trunk and lower limb. Below T5, the fasciculus gracilis is the only dorsal column.

7.1.2 Second-Order Neurons

- The axons of the fasciculus cuneatus and fasciculus gracilis ascend to the lower (caudal) medulla, where they synapse with the *second-order neurons* located in the *nucleus cuneatus* and *nucleus gracilis*, respectively, on the dorsal aspect of the caudal medulla.
- The axons of the second neuron decussate (internal arcuate fibers) across the dorsal midline of the lower medulla.
- After decussation, the axons of the second-order neurons form a fiber bundle, the *medial lemniscus*, which ascends the contralateral side of the brainstem. Thus, the medial lemniscus is carrying sensations from the contralateral limbs. The medial lemniscus courses medially at the midline of the medulla and pons, and begins to shift more laterally in the midbrain. The axons of the medial lemniscus terminate in the *ventral posterolateral* (VPL) nucleus of the thalamus.

7.1.3 Third-Order Neurons

- The third-order neurons are located in the VPL nucleus of the thalamus.
- The axons of the thalamic neurons project via the posterior limb of the internal capsule to the *somatosensory cortex* (areas 3, 1, and 2) in the postcentral gyrus and paracentral lobule of the parietal lobe.

Please visit us at www.Groupinsiders.com

© DeVry/Becker Educational Development Corp. All rights reserved.

Clinical Application

Study Tips

Dorsal column lesions result in the loss of conscious proprioception and epicritic functions of two-point discrimination, touch, pressure, and vibration. Testing vibration sense with a tuning fork is one of the efficient ways to evaluate this pathway. With a dorsal column tract lesion, the individual has difficulty judging the shape of an object (asterognosis) placed against the skin.

With loss of conscious proprioception in the lower limb, there is difficulty in the gait and maintaining balance. Dorsal column lesions are found in cord lesions such as tabes dorsalis and subacute combined degeneration, which are discussed later.

The medial fasciculus gracilis conducts epicritic and conscious proprioceptive sensations below mid-thoracic levels (lower trunk and limbs). The lateral fasciculus cuneatus conducts these same sensations above mid-thoracic levels (upper trunk and limbs).

Lesions of Dorsal Columns/Medial Lemniscus Long Tract

- If this long tract system is damaged *above the decussation* (between caudal medulla and the cortex) the sensory deficits are *below the lesion* and on the *contralateral side* of the body.
- If the lesion is *below the decussation* (dorsal columns in spinal cord), the sensory deficits are *below the lesion* but on the *ipsilateral* side of the body.

The Romberg Sign

The *Romberg sign* is useful in testing the proprioceptive functions of the dorsal columns and to be able to distinguish lesions of the dorsal columns from cerebellar vermal lesions. In the Romberg test, the patient is asked to put the feet together and note if he/she can stand erect with the eyes open and then with the eyes closed. With a dorsal column lesion, the patient can stand vertical with eyes open (using visual circuits to the cerebellum), but with eyes closed the patient will sway and lose balance, referred to as *sensory ataxia* (a positive Romberg sign). This is due to the loss of conscious proprioceptive input from the lower limbs. Falling over with eyes open then indicates cerebellar vermal damage, referred to as *motor ataxia*.

Please visit us at www.Groupinsiders.com

© DeVry/Becker Educational Development Corp. All rights reserved.

7.2 Spinothalamic Tract (Anterolateral System)

The *spinothalamic tract* conveys protopathic pain and temperature sensations. Sensory receptors consist of free nerve endings and thermal receptors located in the skin. This pathway uses three neurons that decussate and relay through the thalamus. The three neurons of the tract are outlined below (see Figures 16–7.2A, 16–7.2B, and 16–7.2C).

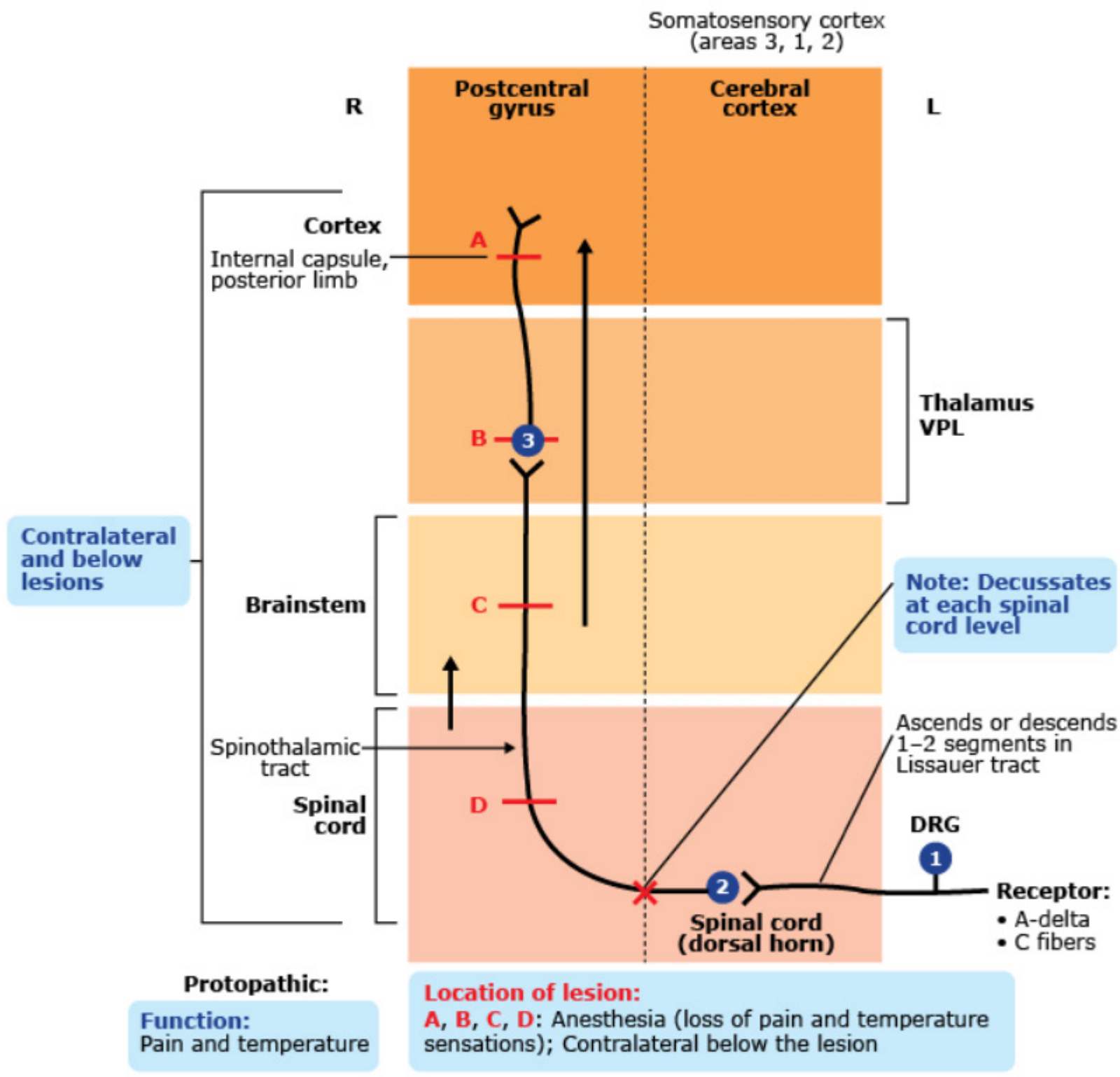

▲ **Figure 16–7.2A** Spinothalamic Tract (Anterolateral System)

Please visit us at www.Groupinsiders.com

© DeVry/Becker Educational Development Corp. All rights reserved.

Please visit us at www.Groupinsiders.com

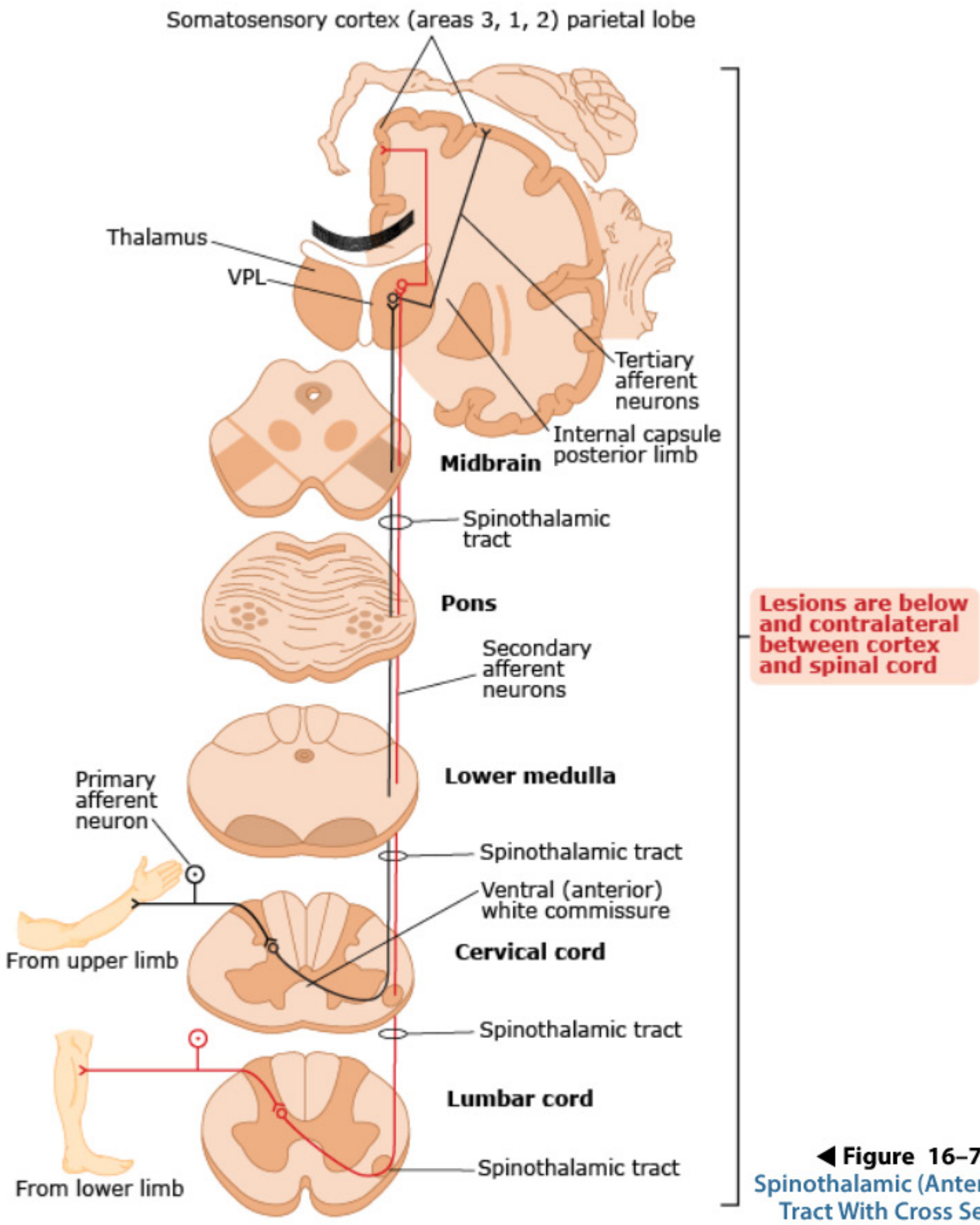

◀ **Figure 16–7.2B**
Spinothalamic (Anterolateral) Tract With Cross Sections

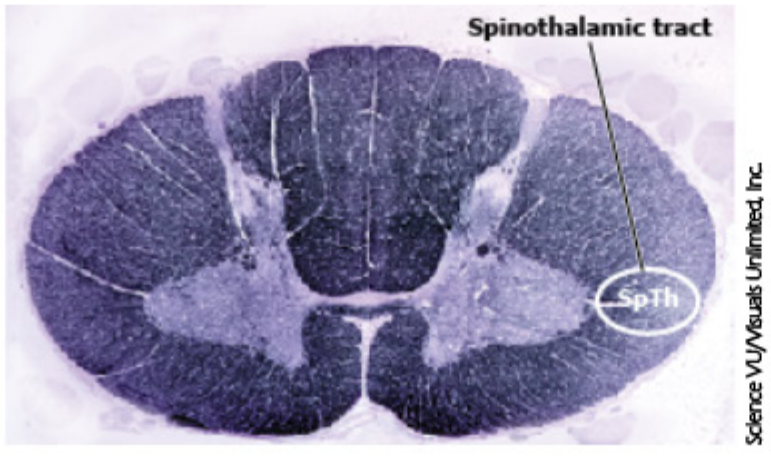

◀ **Figure 16–7.2C**
Spinothalamic Tract in Spinal Cord Cross Section

© DeVry/Becker Educational Development Corp. All rights reserved.

7.2.1 First-Order (Primary) Neurons

- The smaller, slower-conducting *primary afferent unipolar neurons* in the dorsal root ganglia conduct pain and temperature sensations. These neurons are A-delta and C fibers, which are thinly myelinated or unmyelinated fibers, respectively.
- The central processes enter the spinal cord in the lateral division of the dorsal root and enter the *Lissauer tract*. These axons ascend or descend one or two segments in the Lissauer tract and then synapse on *second-order neurons* in the outer laminae of the *dorsal horn*.

7.2.2 Second-Order Neurons

The *second-order neurons* in the dorsal horn of the spinal cord pass medially and decussate in the *ventral (anterior) white commissure,* located just ventral to the central canal, to form the *contralateral spinothalamic track* in the ventral part of the lateral fasciculus on the opposite side of the cord. Note that with pain and temperature, there are decussations at *each level of the cord*.

- After decussation, the axons form and ascend the spinothalamic tract on the contralateral side of the spinal cord. At each ascending segmental level, new fibers are added to the medial side of the tract so that fibers from the lower body are located laterally in the tract.
- The spinothalamic tract ascends the lateral aspect of the medulla, pons, and midbrain, and synapses on the third-order neurons in the VPL nucleus of the thalamus.

7.2.3 Third-Order Neurons

- The third-order neurons are located in the *VPL nucleus of the thalamus.*
- The thalamic axons project through the *posterior limb of the internal capsule* to reach the *somatosensory cortex* (area 3, 1, 2) in the postcentral gyrus and paracentral lobule of the parietal lobe.

Please visit us at www.Groupinsiders.com

© DeVry/Becker Educational Development Corp. All rights reserved.

7.2.4 Lesions of Spinothalamic Tract

Destruction of the spinothalamic tract at any level (spinal cord to cortex) results in *contralateral* loss of pain and temperature sensations (analgesia), usually one to two segments *below the level* of the lesion in the spinal cord. Note that the contralateral nature of spinothalamic lesions is an important clinical sign in neurology because the side of the trunk and limbs with loss of pain and temperature will be on the opposite side of the body from the lesion.

7.2.5 Lesions of UPL Nucleus of Thalamus

- Unilateral lesions of the VPL thalamic nucleus result in total contralateral anesthesia (epicritic and protopathic) on the opposite side of the body.
- Figure 16–7.2D is an overview of these two major ascending long tract systems.

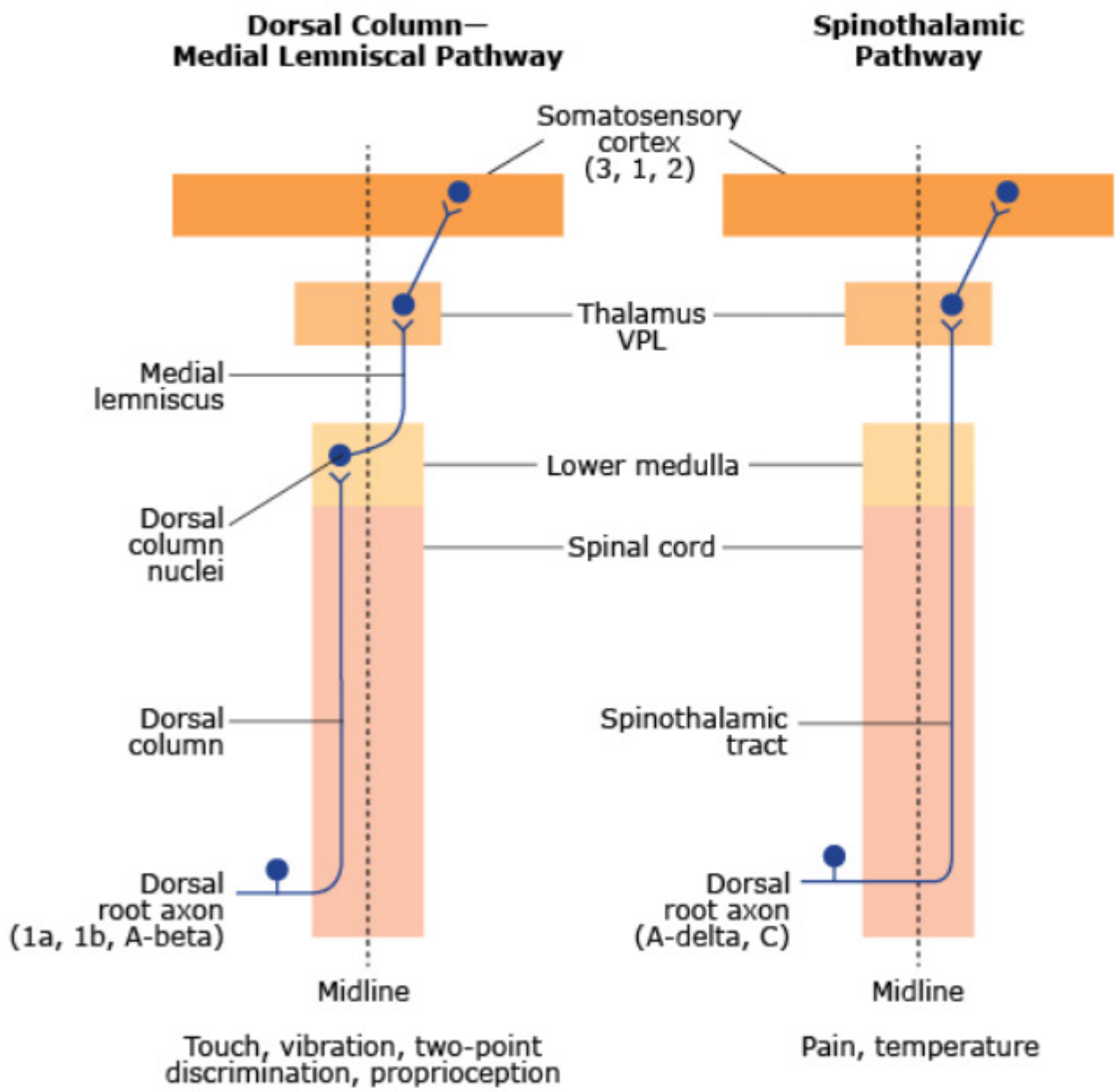

▲ **Figure 16–7.2D** Comparison of Epicritic and Protopathic Pathways

Please visit us at www.Groupinsiders.com

© DeVry/Becker Educational Development Corp. All rights reserved.

7.3 Spinocerebellar Tracts

- There are two sensory spinocerebellar tracts that transmit *unconscious proprioceptive information* from muscle spindles and Golgi tendon organs in muscles of the trunk and limbs to the cerebellum. This information is essential for fine muscular coordination and control of muscle movements by the cerebellum. Lesions of this tract (such as hereditary degeneration of these fibers seen in Friedreich ataxia) present with an uncoordinated gait.
- Although these are ascending sensory long tracts, they do not follow the classic pattern of a sensory tract. They consist of only two neurons, are uncrossed (do not decussate), and do not relay through the thalamus. Thus, the spinocerebellar tracts project to the ipsilateral cerebellum.
- The two major spinocerebellar tracts are the:

  1. *Cuneocerebellar tract,* which transmits unconscious proprioceptive information from the *upper limb* and trunk.

  2. *Dorsal spinocerebellar tract,* which transmits unconscious proprioceptive information from the *lower limb* and trunk.

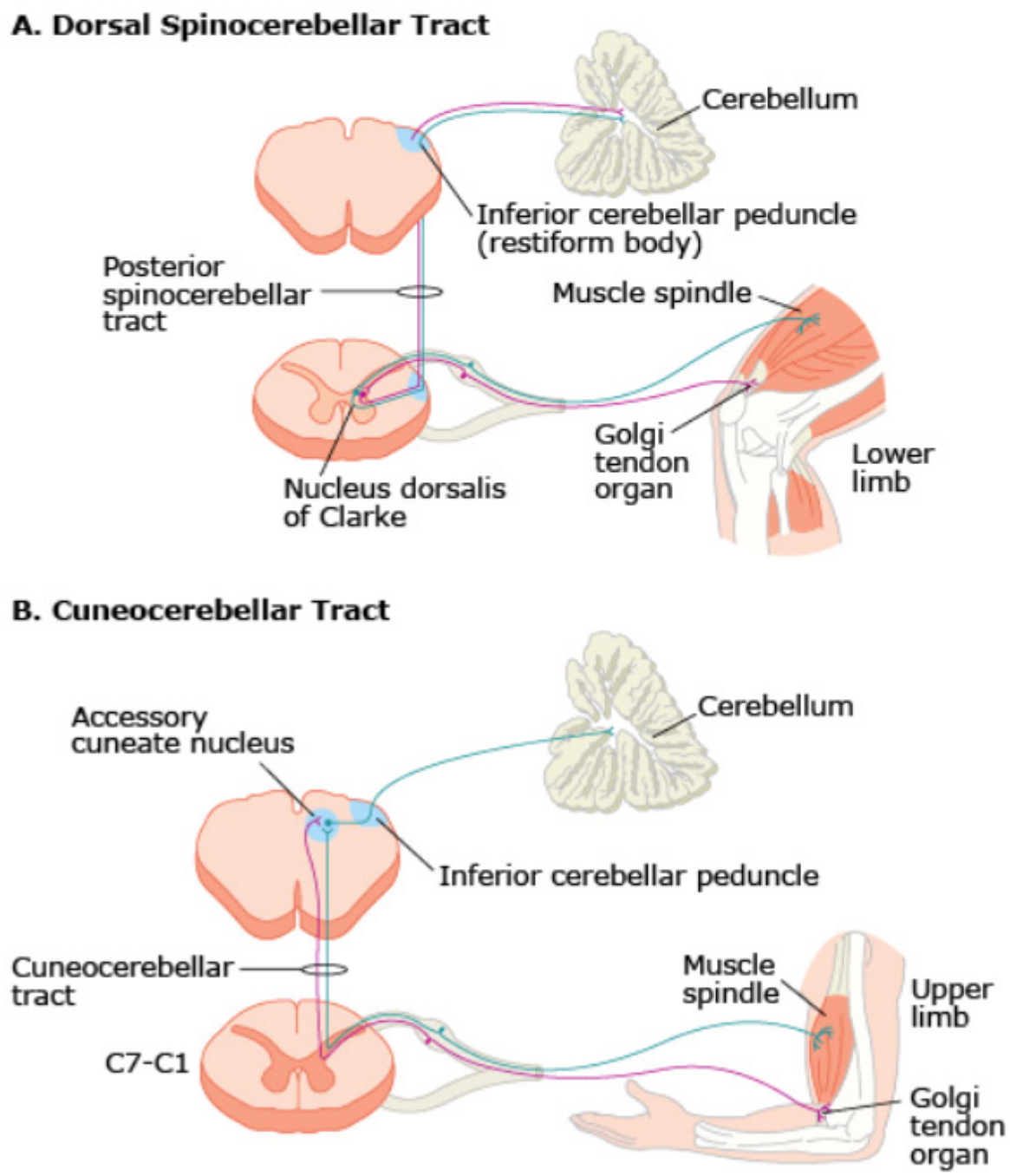

▲ **Figure 16–7.3** Spinocerebellar Tracts

Please visit us at www.Groupinsiders.com

© DeVry/Becker Educational Development Corp. All rights reserved.

8 Spinal Cord Lesions

The features of different cord regions and how to identify a cord section by region are illustrated in Figure 16–8.0A.

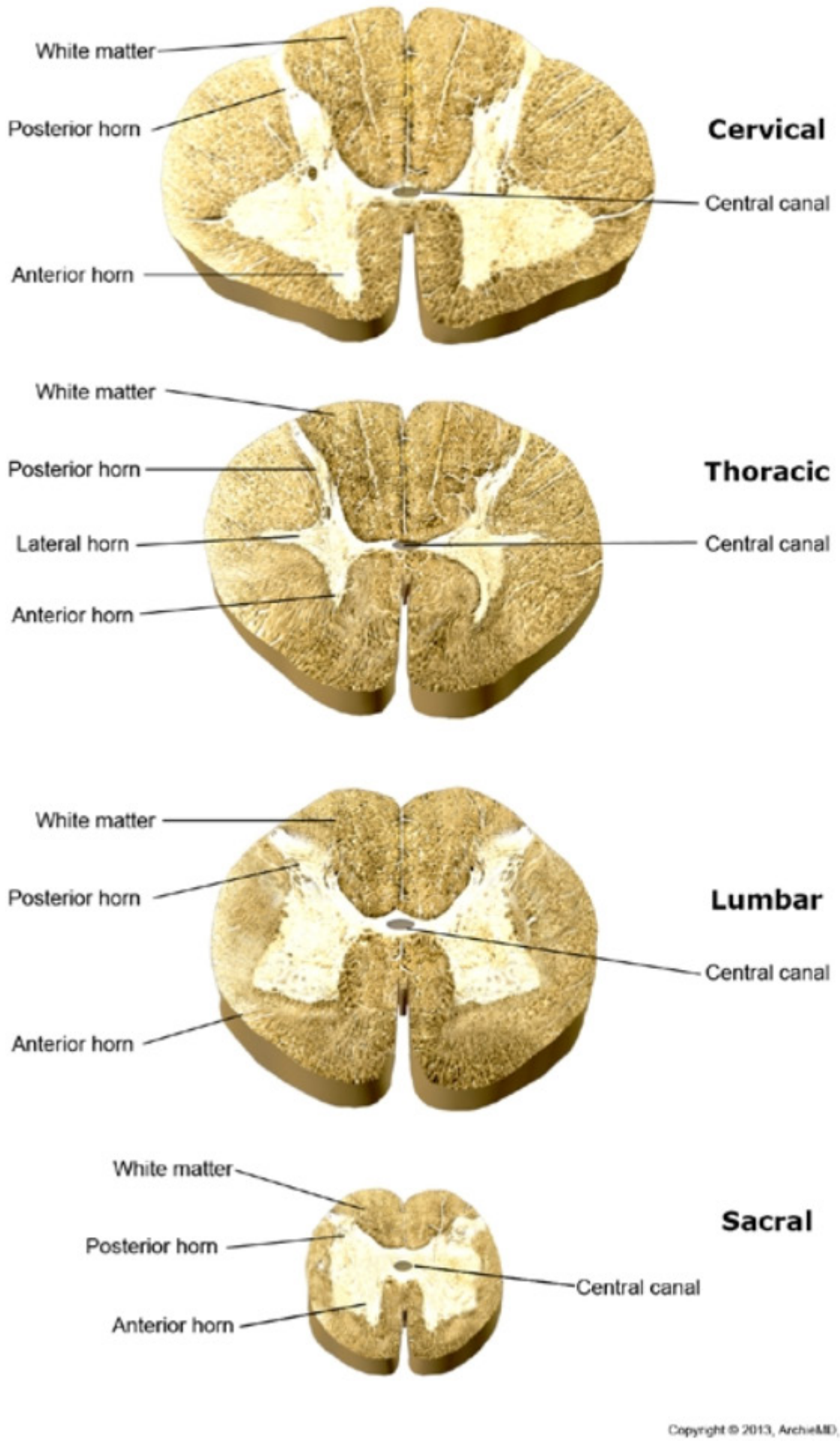

▲ **Figure 16–8.0A** Regional Sections of the Spinal Cord

Please visit us at www.Groupinsiders.com

© DeVry/Becker Educational Development Corp. All rights reserved.

- The sensory and motor systems and lesions of the spinal cord are reviewed in a cross section of the spinal cord (Figure 16–8.0B). Shown below, some of the basic spinal cord lesions are discussed.

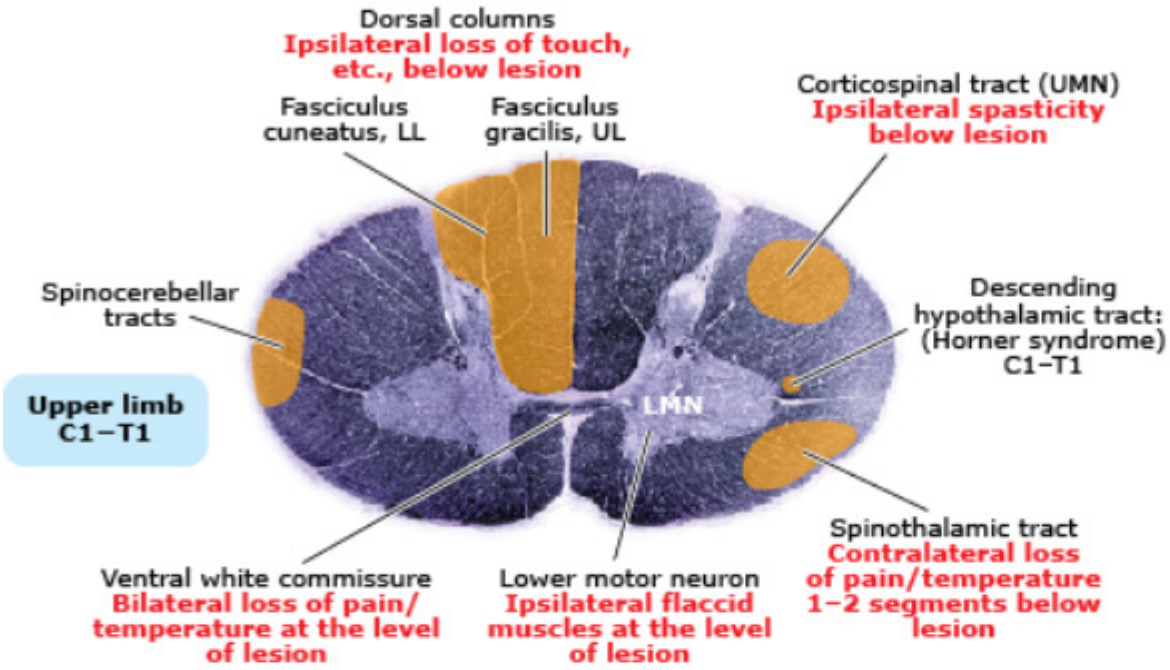

▲ **Figure 16–8.0B** Lesions of the Spinal Cord

8.1 Poliomyelitis

Poliomyelitis is an acute inflammatory viral infection that targets the specific destruction of lower motor neurons in the ventral horns. The viral inflammation can be unilateral or affect bilateral ventral horns. Polio results in flaccid paralysis of the limb muscles with decreasing reflexes, hypotonia, and fasciculations.

- Flaccid paralysis
- Hypotonia
- Fasciculations
- Areflexia
- Muscle atrophy
- Usually occurs at lumbar segments

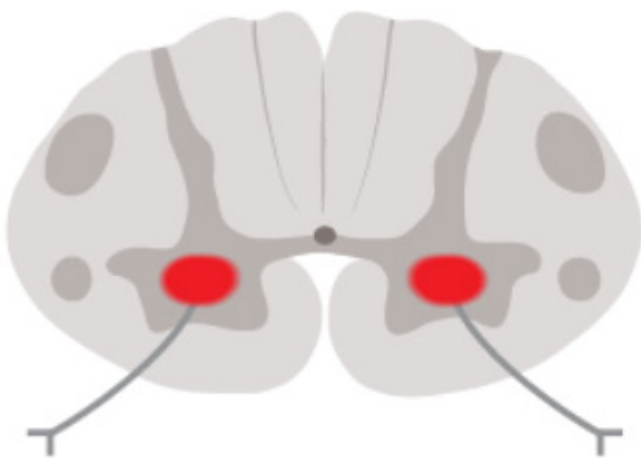

▲ **Figure 16–8.1** Poliomyelitis

Important Concept

Model of Spinal Cord Case

1. No cranial nerve signs
2. Sensory and motor deficits are on trunk and limbs
3. Spasticity, Flaccid, and Epicritic deficits are on the same side of the lesion
4. Pain and temperature are contralateral to the side of the lesion
5. Involves both limbs and Horner if lesions are between C1–T1 or 2

Please visit us at www.Groupinsiders.com

© DeVry/Becker Educational Development Corp. All rights reserved.

8.2 Amyotrophic Lateral Sclerosis (ALS)/ Lou Gehrig Disease

Amyotrophic lateral sclerosis is a progressive demyelination disease that results in the destruction of bilateral corticospinal tracts (upper motor neurons) and bilateral ventral horn cells (lower motor neurons) at each cord segment. Thus, at each affected cord segment, there is a combination of lower motor (flaccid paralysis) and upper motor (spastic paralysis) neuron lesions. There are progressive bilateral flaccid muscles in the upper limbs and progressive bilateral spasticity in the lower limbs. ALS usually begins in the cervical spinal cord and later involves the entire spinal cord and brainstem. There are no sensory deficits. The cause is unknown, and the disease is progressive to death.

- Upper limbs: Flaccid paralysis.
- Lower limbs: Spastic paralysis.
- Usually begins at cervical levels.

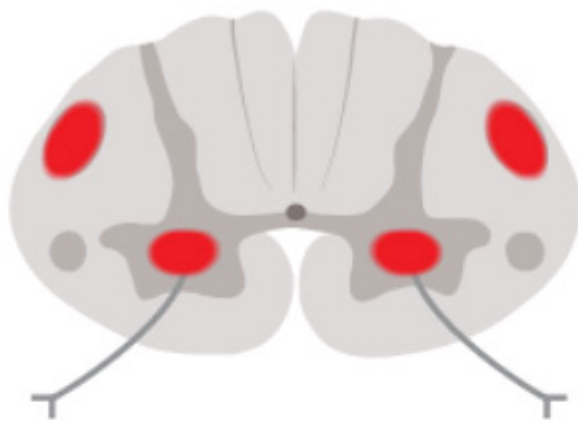

◀ **Figure 16–8.2** Amyotrophic Lateral Sclerosis (ALS)

8.3 Tabes Dorsalis

Tabes dorsalis is a bilateral degeneration of the dorsal columns and dorsal roots that presents as a late consequence of *neurosyphilis*. Occurring in the lower spinal cord (lumbar levels), tabes dorsalis involves the bilateral degeneration of the fasciculus gracilis, thus affecting both lower limbs. There is altered vibration, touch, and position sense. The loss of conscious proprioception in the lower limbs results in an uncoordinated limb movement and a high-step gait. There are also abnormal pupil responses.

- Three Ps: paresthesias, pain, polyuria.
- High-step gait.
- Positive Romberg sign: Sensory ataxia.
- Decreased stretch reflexes.
- Argyll Robertson pupils.
- Usually occurs at lumbar levels.

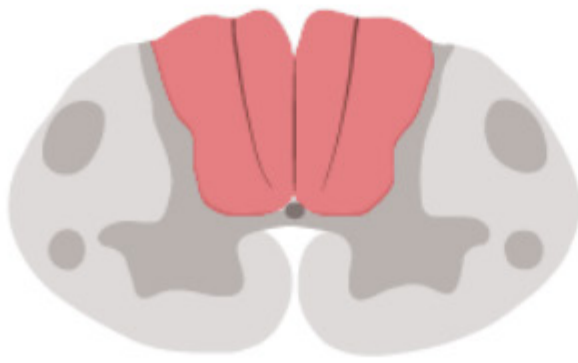

◀ **Figure 16–8.3** Tabes Dorsalis

Please visit us at www.Groupinsiders.com

© DeVry/Becker Educational Development Corp. All rights reserved.

8.4 Anterior Spinal Artery (ASA) Occlusion

The upper half of the spinal cord (above mid-thoracic level) receives blood supply from a single, midline anterior spinal artery (ASA) that provides blood flow bilaterally to the ventral two thirds of the spinal cord. The dorsal columns and dorsal tips of the dorsal horns are supplied by a pair of posterior spinal arteries (PSA). An ASA occlusion results in the loss of about 75% of the ventrolateral areas of the cord. There is bilateral loss of pain and temperature and spasticity below the lesion and flaccid muscles at the level of the lesion.

- Bilateral spasticity below lesion.
- Bilateral loss of P/T below lesion.
- Bilateral flaccid weakness at level of lesion.
- DC sensations spared.
- Usually occurs at mid-thoracic and above.

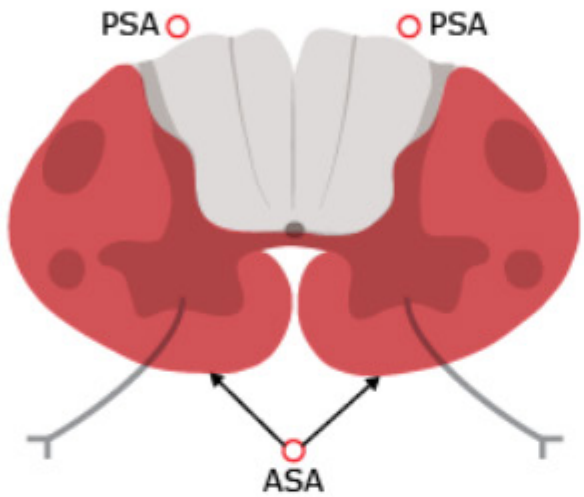

▲ **Figure 16–8.4** Anterior Spinal Artery (ASA) Occlusion

8.5 Subacute Combined Degeneration

Subacute combined degeneration results in bilateral demyelination of dorsal columns and corticospinal tracts. This disease results from deficiency of vitamin B12 and results in pernicious anemia. There are both sensory and motor function losses. Bilateral spasticity and bilateral loss of dorsal column functions occur below the level of the lesion. There is demyelination of the:

- Dorsal columns.
- Corticospinal and spinocerebellar tracts.
- Affects upper thoracic and lower cervical cord levels.

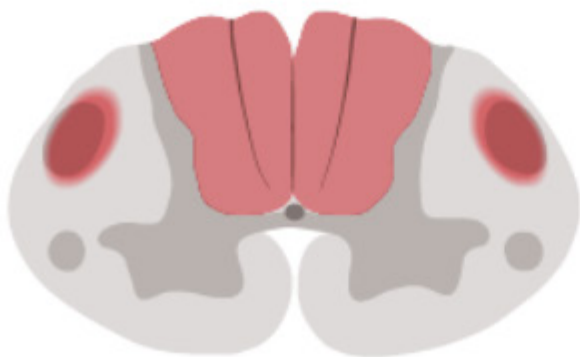

▲ **Figure 16–8.5** Subacute Combined Degeneration

Please visit us at www.Groupinsiders.com

© DeVry/Becker Educational Development Corp. All rights reserved.

8.6 Syringomyelia

Syringomyelia results from progressive cavitation of the central canal and occurs mostly at the upper thoracic and cervical cord levels. The cavitation results in a central cord lesion with damage to the anterior white commissure and the decussating spinothalamic fibers. Initially there is bilateral loss of pain and temperature at the level of the lesion on the upper chest or upper limb, followed later by flaccid paralysis of the upper limbs as the cavitation enlarges and extends into and damages the adjacent ventral horns. With further lateral extension of the cavitation, the descending hypothalamic tract can be affected and produces ipsilateral Horner syndrome.

- Bilateral loss of P/T at level of lesion.
- Later develops flaccid muscles and Horner syndrome.
- Usually occurs at upper thoracic or cervical levels.
- Hydrocephalus and Arnold-Chiari II may be present.

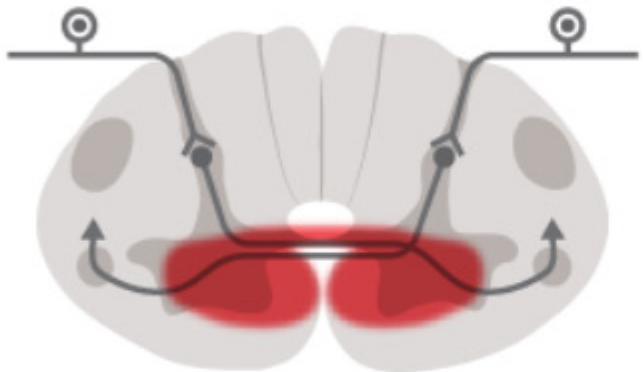

▲ **Figure 16–8.6A** Syringomyelia

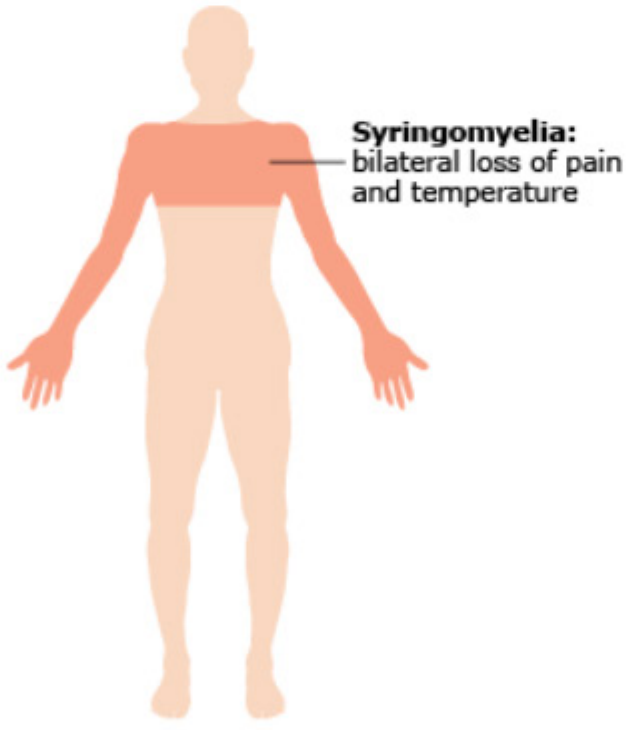

▲ **Figure 16–8.6B** Syringomyelia: Areas of Effect

Please visit us at www.Groupinsiders.com

© DeVry/Becker Educational Development Corp. All rights reserved.

8.7 Brown-Séquard Syndrome: Hemisection

Brown-Séquard syndrome involves a total hemisection of the spinal cord, often including damage to the dorsal root fibers. It occurs after a period of spinal shock. The hallmark of this lesion is the presence of two ipsilateral long tract signs (posterior columns and corticospinal) and one contralateral long tract sign (spinothalamic) below the lesion. At the level of lesion and ipsilateral, there are total dermatome anesthesia and flaccid muscles.

- CST: Ipsilateral spasticity *below the level of the lesion*.
- DC: Ipsilateral epicritic/position loss *below the level of the lesion*.
- ST: Contralateral P/T loss one to two segments *below the level of the lesion*.
- LMN: Ipsilateral flaccid muscles *at the level of the lesion*.
- Ipsilateral total dermatome sensory loss *at the the level of the lesion*.
- Ipsilateral Horner syndrome (if lesion is above T1–2).

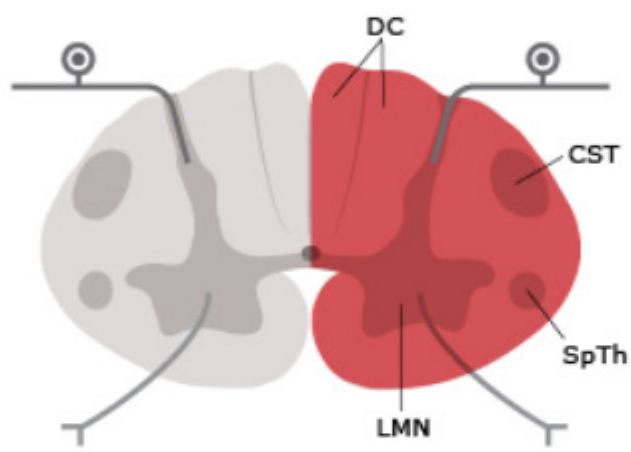

▲ **Figure 16–8.7A** Brown-Séquard Syndrome

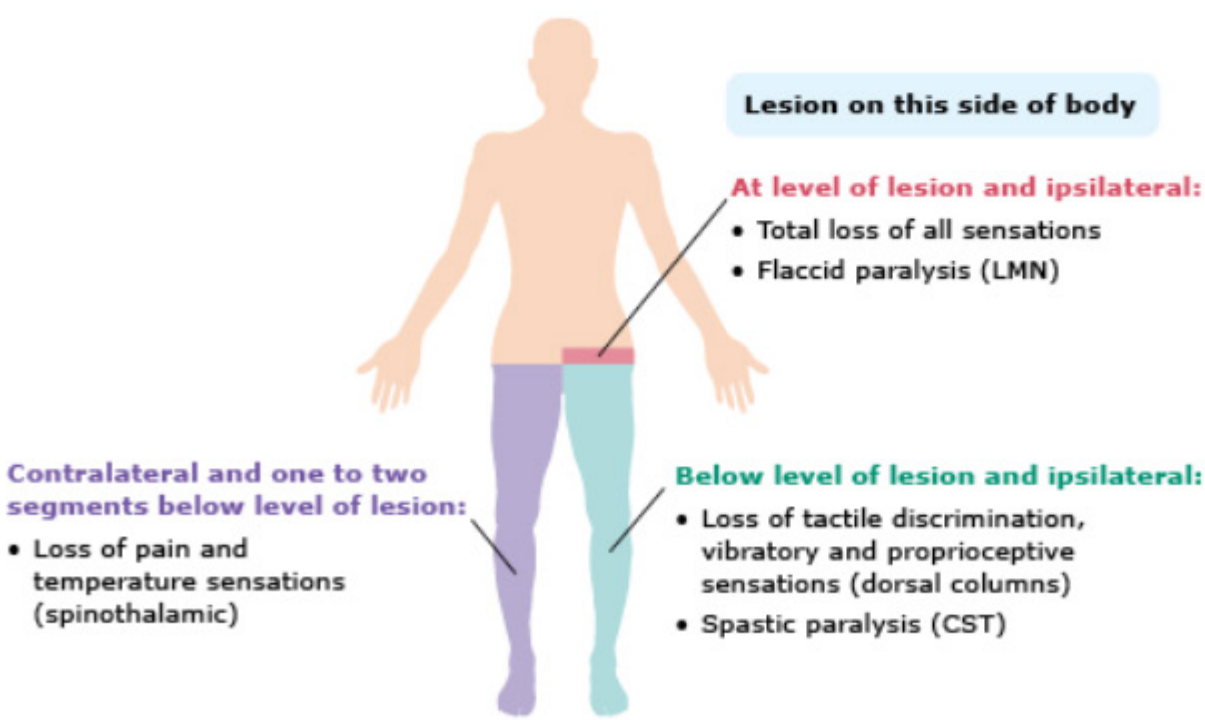

▲ **Figure 16–8.7B** Brown-Séquard Syndrome: Areas of Effect

Please visit us at www.Groupinsiders.com

© DeVry/Becker Educational Development Corp. All rights reserved.

Chapter 16 Review Questions

1. A patient presents with hypertonia and loss of vibration sensations on the left upper and lower limbs and loss of pain and temperature on the right limbs. On the left side of the face there is a drooping eyelid and miosis of the left pupil. These signs and symptoms would result from lesions in which of the following areas?

A. Right lower thoracic spinal cord
B. Left cervical spinal cord
C. Right lumbar spinal cord
D. Left lumbar spinal cord
E. Left brainstem

2. A 25-year-old man complains to his physician that he has lost sensation in his right hand. The physical exam shows that there is loss of two-point discrimination and vibration in his hand. Which of the following is part of the neural pathway for these functions?

A. Left fasciculus cuneatus
B. Left spinothalamic tract
C. Right cuneate nucleus
D. Ventral white commissure
E. Right lateral funiculus

3. A 45-year-old man is admitted to the hospital for neurological evaluation. He complains of shooting pain in both legs and has modified touch sensations in both lower limbs. In addition, he is not able to detect the vibrations of a tuning fork when placed on his legs. He has a slow gait but normal flexion of the toes when the sole of the foot is stimulated. It was noted that his pupils would respond to near vision but not to light stimulation. These signs and symptoms would suggest that the patient has which of the following?

A. Anterior spinal artery occlusion
B. Amyotrophic lateral sclerosis
C. Syringomyelia
D. Tabes dorsalis
E. Subacute combined degeneration

4. A patient complains to the physician that he has lost the ability to distinguish between hot and cold water with both of his hands. Which of the following could possibly be a lesion site for these symptoms?

A. Bilateral dorsal column lesion at the C3 section of the cord
B. Spinothalamic tract on the right side
C. Bilateral corticospinal tracts
D. Corticospinal tract on the right
E. Ventral white commissure

Please visit us at www.Groupinsiders.com

© DeVry/Becker Educational Development Corp. All rights reserved.

Review Questions Chapter 16

5. A 65-year-old-man is evaluated by a neurologist after complaining about progressive weakness in both of his lower limbs. The physical exam shows both limbs to have a positive Babinski sign with increasing hyperreflexia. A short time later, the upper limbs become progressively weak with decreasing muscle stretch reflexes. All sensory functions are normal. The neurologist's diagnosis for this patient would likely be:

A. Multiple sclerosis
B. Guillain-Barré syndrome
C. Amyotrophic lateral sclerosis
D. Tabes dorsalis
E. Syringomyelia

6. A patient experiences trauma to the neck resulting in damage to the ventral roots of several upper cervical spinal nerves. Which of the following signs and symptoms would be expected in the individual?

A. Muscle atrophy over time in the innervated muscles
B. Loss of touch on the contralateral side of the body
C. Loss of pain and temperature on the contralateral side of the body
D. Spasticity in the innervated muscle
E. Loss of sympathetic innervation to the sweat glands in the skin of the neck

7. A 55-year-old man was taken to the hospital after a car accident which resulted in damage to some of the nerve fibers in the C5 dorsal root terminating in the lower medulla. Which of the following symptoms would the patient be more likely to demonstrate?

A. Hypotonia
B. Loss of sympathetic efferent innervation to the heart
C. Spasticity
D. Loss of pain and temperature sensations
E. Loss of touch in the ipsilateral C5 dermatome

Please visit us at www.Groupinsiders.com

© DeVry/Becker Educational Development Corp. All rights reserved.

Chapter 16 Review Questions

8. A 35-year-old female presents with loss of motor functions, spasticity, and loss of pain in both lower limbs. However, she has intact touch and proprioceptive functions of both lower limbs. The most likely location of the lesion is in the:

A. Bilateral dosal horns of the spinal cord
B. Bilateral ventral half of the spinal cord
C. Left side of the spinal cord
D. Bilateral ventral roots of the lumbar spinal nerve
E. Bilateral dorsal funiculus

9. A tumor pressing against the dorsal funiculus of the spinal cord at the T10 would result in which of the following neurological deficits?

A. Bilateral loss of pain and temperature in the lower limbs
B. Flaccid muscles at the T10 level
C. Altered vibratory sense in the lower limbs
D. Bilateral spastic weakness in the lower limbs
E. A loss of reflexes in the upper limbs

10. The axons of the neurons whose cell bodies are located in the outer Rexed lamina of the spinal cord's left dorsal horn terminate into which of the following structures?

A. Left fasciculus gracilis
B. Right VPL nucleus of the thalamus
C. Left spinothalamic tract
D. Dorsal root ganglion
E. Right lower medulla

Please visit us at www.Groupinsiders.com

© DeVry/Becker Educational Development Corp. All rights reserved.

Review Answers Chapter 16

1. The correct answer is B. This question is an example of a Brown-Séquard spinal cord lesion on the left side of the spinal cord at the cervical level. This case is at the cervical level because there is Horner syndrome and both limbs are involved. Note that pain and temperature deficits are on the opposite side of the other signs.

2. The correct answer is C. The sensory loss of touch and vibration on the right hand idicates a lesion of the dorsal column-medial lemniscal pathway. The only possible site for the lesion listed in this question would be the right cuneate nucleus, which is before the decussation of the pathway in the lower medulla.

3. The correct answer is D. The type of sensory and proprioceptive losses observed in both lower limbs of this patient suggests tabes dorsalis. This disease usually presents in the late stages of syphilis and results from bilateral degeneration of the dorsal columns and the dorsal roots in the lumbar region. The patient will show a positive Romberg sign with polyuria, paresthesia, and pain. An Argyll Robertson pupil also is present.

4. The correct answer is E. The loss of temperature sensations of both hands results from a central spinal cord lesion involving cavitation of the central canal. The lesion damages the decussation of the pain and temperature fibers from both sides of the body at the anterior (ventral) white commissure.

5. The correct answer is C. As described in this patient, the progressive development of the upper motor neuron signs in both lower limbs with the development of lower motor neuron signs in both upper limbs is consistent with amyotrophic lateral sclerosis. The disease involves progressive demyelination of bilateral corticospinal tracts and bilateral ventral horns of the spinal cord, usually beginning in the cervical region. There are no sensory deficits and the disease is progressive to death.

6. The correct answer is A. The ventral roots of spinal nerves transmit lower motor neurons from the spinal cord to the periphery. Alpha and gamma lower motor neurons are located in the spinal nerves' vental roots, where damage would result in typical lower motor neuron signs, including atrophy of the innervated muscles over time following the damage. There are no preganglionic fibers originating at the cervical levels.

7. The correct answer is E. The fibers that enter the spinal cord at C5 and terminate in the lower medulla are the central processes of the primary afferent neurons of the dorsal column-medial lemniscal pathway. The deficit would be the loss of touch and other epicritic functions at the ipsilateral C5 dermatome.

8. The correct answer is B. The bilateral spasticity and loss of pain and temperature in the lower limbs results from bilateral damage of the corticospinal and spinothalamic tracts, respectively. Such an injury suggests damage to the ventral half of the spinal cord as seen with an anterior spinal artery occlusion. The dorsal columns of the cord were spared from injury as indicated by the intact epicritic functions.

9. The correct answer is C. Compression on the spinal cord's dorsal side at the T10 level will bilaterally damage the fasciculus gracilis. The damage would result in loss of touch, vibration, and proprioceptive functions of the lower trunk and both lower limbs.

10. The correct answer is B. The neuron cell bodies located in the outer laminia of the spinal cord's dorsal horn are secondary neurons of the spinothalamic pathway that carry pain and temperature sensations. The axons of these neurons cross the midline of the spinal cord at the ventral white commissure and form the spinothalamic tract located in the lateral fasciculus on the contralateral side of the cord. The axons ascend the spinothalamic tract without interruption to the VPL nucleus of the thalamus.

Please visit us at www.Groupinsiders.com

© DeVry/Becker Educational Development Corp. All rights reserved.

Please visit us at www.Groupinsiders.com

1 Overview

The brainstem is a unique and important area of the CNS located in the posterior cranial fossa of the skull. It is continuous with the spinal cord at the foramen magnum and continues superiorly with the diencephalon at the tentorial notch. The brainstem is formed by three basic parts: *medulla oblongata, pons, and midbrain*. The brainstem contains motor and sensory nuclei associated with most cranial nerves, provides attachments for 9 of the 12 cranial nerves, and is responsible for complex functions such as respiratory and cardiovascular activities and maintenance of consciousness. The brainstem also houses ascending and descending long tracts that traverse the brainstem.

Note that there are three important questions to ask in order to localize a brainstem lesion.

1. Side of lesion: right or left
2. Medial or lateral lesions
3. Level of lesion within the brainstem: medulla, pons, midbrain, etc.

2 Surface Features of the Brainstem

The major surface features of the brainstem are shown in Figures 17–2.0A and 17–2.0B. These landmarks can be useful in identifying a level of the brainstem and localizing a lesion. Note that cranial nerves III and IV are related to the midbrain; cranial nerves V, VI, VII, and VIII are related to the pons; and cranial nerves IX, X, and XII are related to the medulla. One should be able to identify cranial nerve attachments to the ventral surface of the brainstem (Figure 17–2.0C).

USMLE® Key Concepts

For Step 1, you must be able to:

- List features of the brainstem, including points where the cranial nerves attach.
- Define the functions of the 12 cranial nerves and the clinical presentation of cranial nerve lesions.
- Identify axial sections of the brainstem, the location of the major cranial nerve motor and sensory nuclei, and the location of the three major long tracts.
- Describe the corticobulbar upper motor neuron system and its relationship to the lower motor neurons.
- Explain features of the external, middle, and inner ear.
- Describe the peripheral and central neural circuitry involved in auditory and vestibular functions and their major lesions.
- Explain the circuitry and lesions involved in volitional horizontal gaze.
- Define the five classic brainstem lesions and their clinical features.

© DeVry/Becker Educational Development Corp. All rights reserved.

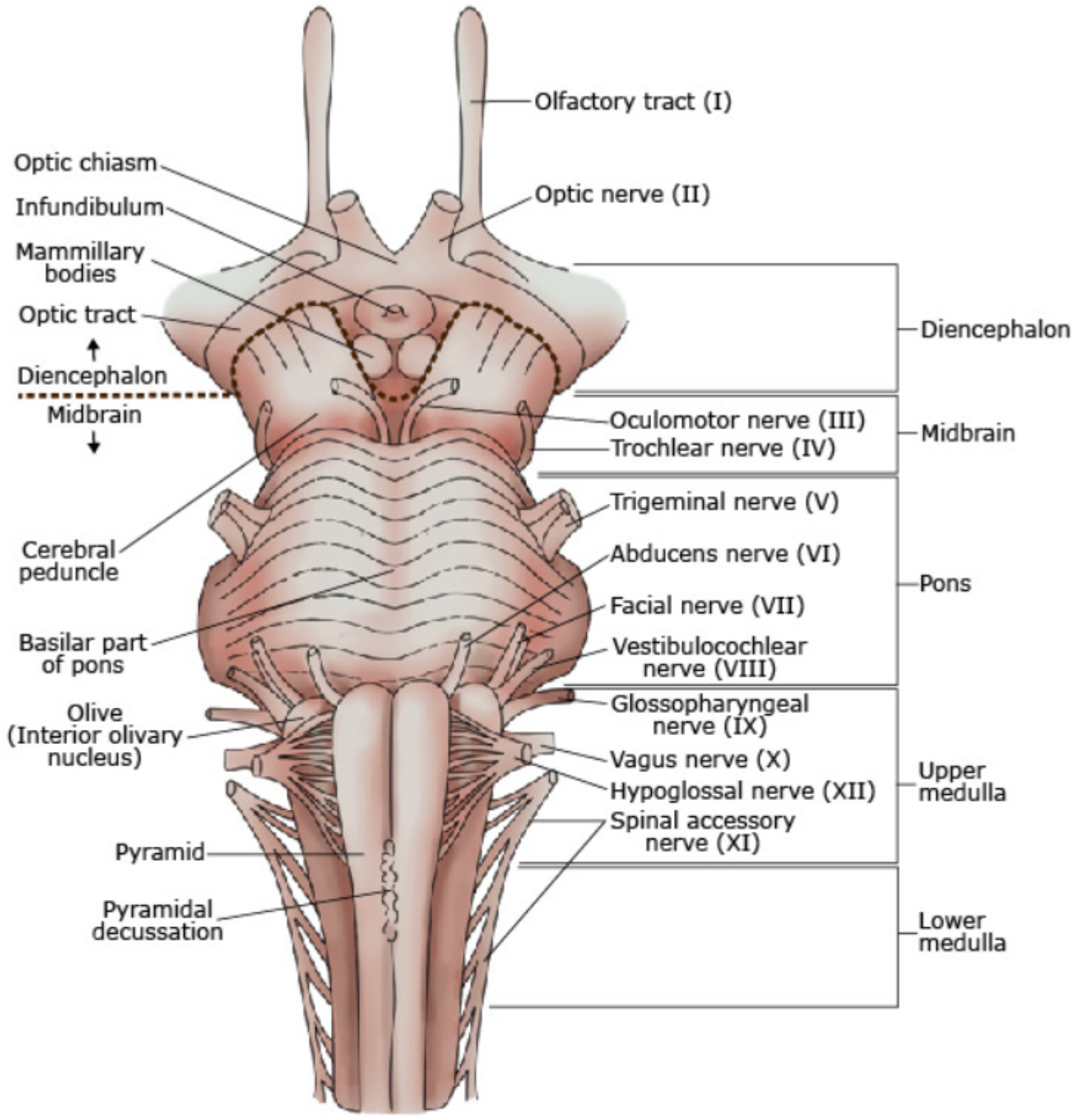

▲ **Figure 17–2.0A** Ventral Surface of Brainstem

Please visit us at www.Groupinsiders.com

© DeVry/Becker Educational Development Corp. All rights reserved.

Please visit us at www.Groupinsiders.com

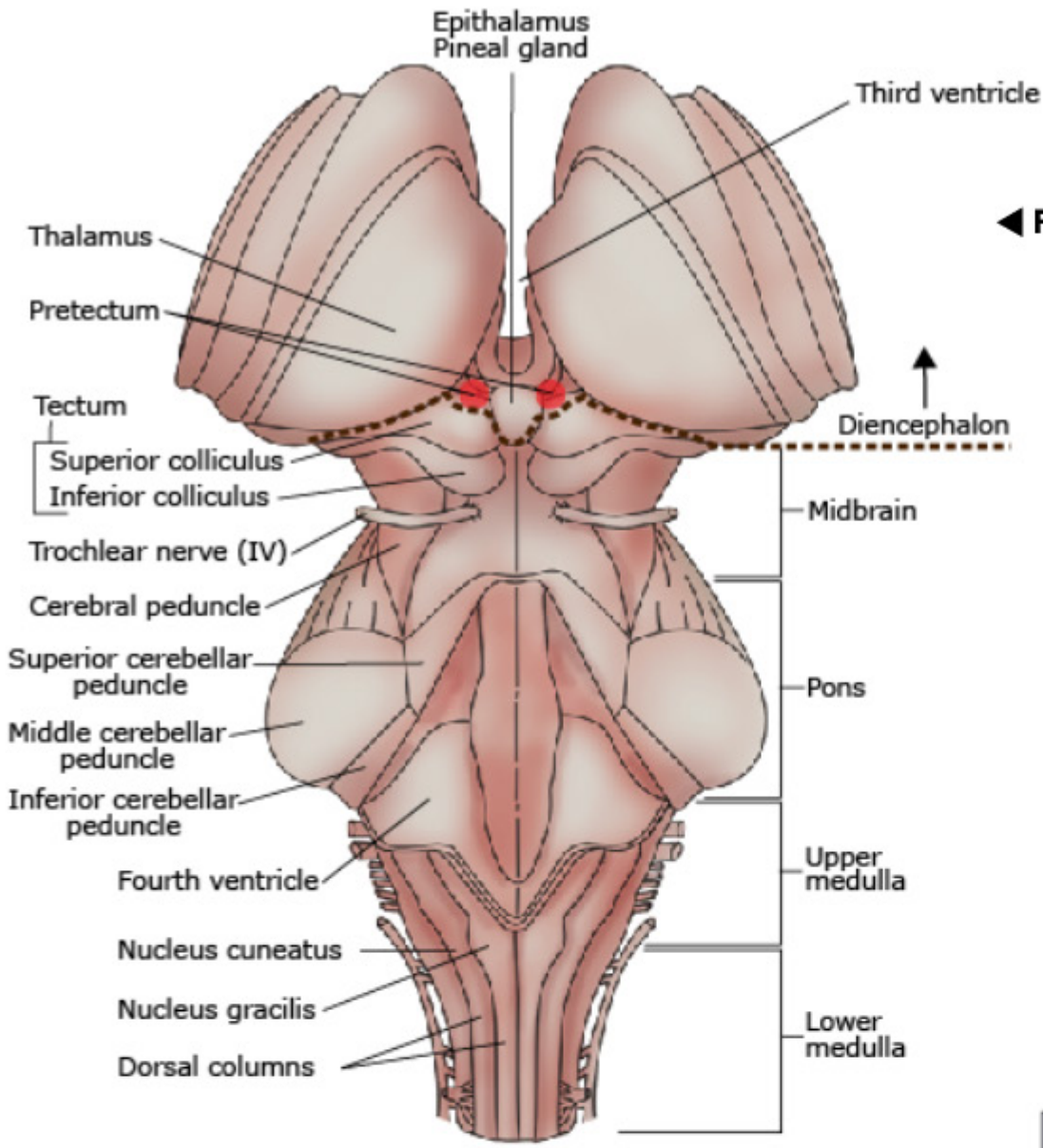

◀ **Figure 17–2.0B** Dorsal Surface of Brainstem

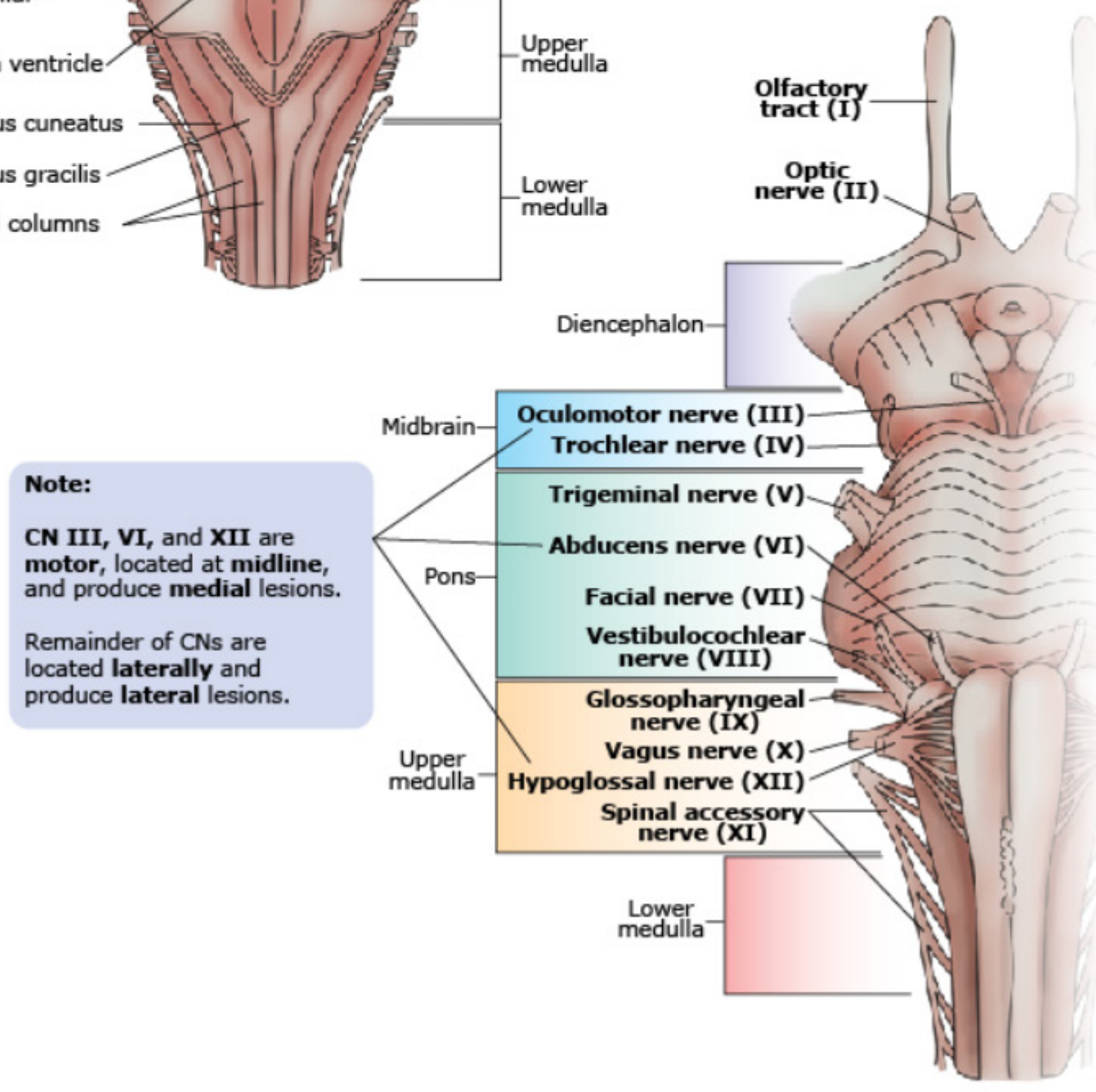

▲ **Figure 17–2.0C** Cranial Nerves

© DeVry/Becker Educational Development Corp. All rights reserved.

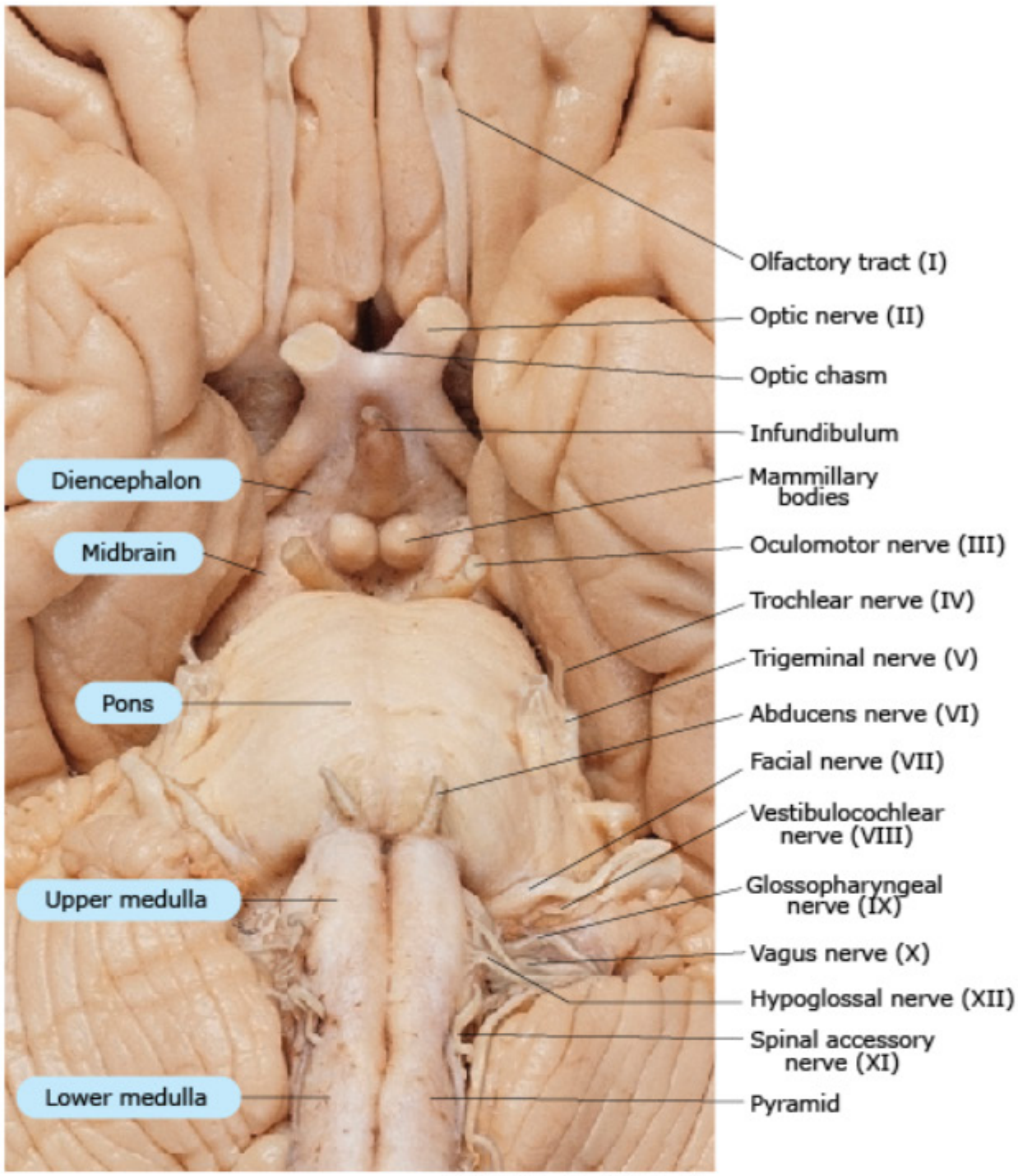

Ralph Hutchings/Visuals Unlimited, Inc.

▲ **Figure 17–2.0D** Attachment of Cranial Nerves to Brainstem

Please visit us at www.Groupinsiders.com

© DeVry/Becker Educational Development Corp. All rights reserved.

3 Cranial Nerve Organization and Function

A thorough understanding of the normal motor and sensory functions of cranial nerves and the symptoms and signs of cranial nerve lesions will provide significant clues in localizing brainstem lesions. Table 17–3.0 outlines the major functions and lesions of the 12 cranial nerves.

▼Table 17–3.0 Cranial Nerves

Cranial Nerve	Site of Exit From Skull	Type	Normal Function	Cranial Nerve Signs and Symptoms (Ipsilateral Signs)
I-Olfactory	Cribriform	Sensory	Smell	Anosmia
II-Optic	Optic canal	Sensory	Sight	• Visual field deficits (anopsia) • Loss of light reflex with III • Only cranial nerve affected by MS
VIII-Vestibulocochlear	Internal acoustic meatus	Sensory	Equilibrium, hearing	• Sensorineural hearing loss • Loss of balance, nystagmus
III-Oculomotor	Superior orbital fissure	Motor	**1. Motor** to medial rectus, superior rectus, inferior rectus, inferior oblique	• Diplopia • External strabismus • Loss of parallel gaze
			2. Motor to levator palpebrae superioris (elevates eyelid)	Ptosis (severe)
			3. Parasympathetic to ciliary and sphincter pupillae muscles	• Dilated pupil, loss of light reflex with II • Loss of near response
IV-Trochlear	Superior orbital fissure	Motor	**Motor** to superior oblique muscle (Depresses eye)	• Weakness looking down with adducted eye • Trouble going down stairs • Head tilts away from lesioned side
VI-Abducens	Superior orbital fissure	Motor	**Motor** to lateral rectus muscle	• Diplopia, internal strabismus • Loss of parallel gaze
XI-Accessory	Jugular foramen	Motor	**Motor** to Sternocleidomastoid and trapezius muscles	• Weakness turning chin to opposite side • Shoulder droop
XII-Hypoglossal	Hypoglossal canal	Motor	**Motor** to intrinsic and extrinsic tongue muscles (genioglossus, hyoglossus, and styloglossus)	• Tongue pointing toward lesion side on protrusion

(continued on next page)

Please visit us at www.Groupinsiders.com

© DeVry/Becker Educational Development Corp. All rights reserved.

▼ **Table 17–3.0** Cranial Nerves *(continued)*

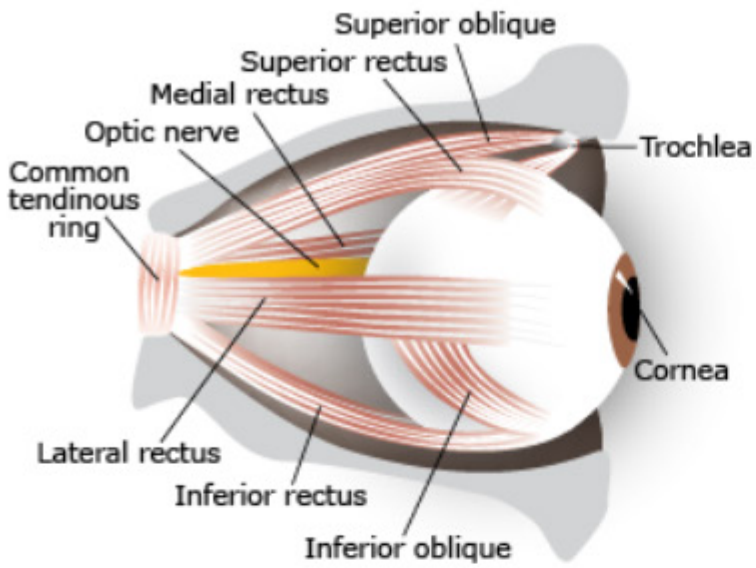

▲ **Figure 17–3.0A** Ocular Muscles

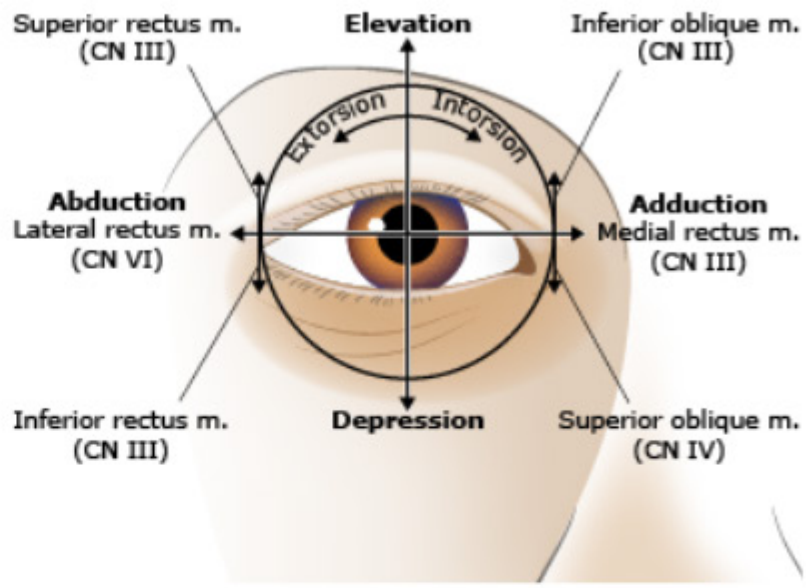

▲ **Figure 17–3.0B** Movement of Eye Muscles

External Strabismus
- Occulomotor lesion
- Eye moves down and out at rest by unopposed IV and VI.

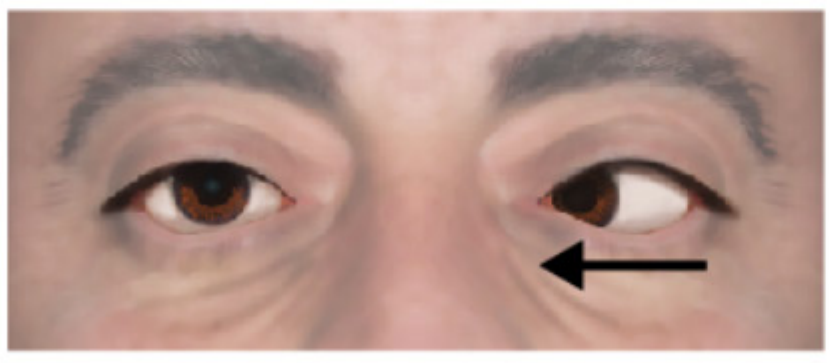

Internal Strabismus
- Abducens lesion
- Eye moves medially at rest by unopposed III

▲ **Figure 17–3.0C** External and Internal Strabismus

(continued on next page)

Please visit us at www.Groupinsiders.com

© DeVry/Becker Educational Development Corp. All rights reserved.

▼Table 17–3.0 Cranial Nerves *(continued)*

Cranial Nerve	Site of Exit From Skull	Type	Normal Function	Cranial Nerve Signs and Symptoms (Ipsilateral Signs)
V-Trigeminal V1-Ophthalmic	Superior orbital fissure	Sensory	**General sensory** from bridge nose, upper eyelid, forehead, cornea	• V1 loss of general sensation in skin of forehead/scalp • Loss of blink reflex with VII
V2-Maxillary	Foramen rotundum	Sensory	**General sensory** from lateral nose, lower eyelid, upper lip, cheek, upper teeth, and gingiva	V2 loss of general sensation in skin over maxilla, maxillary teeth
V3-Mandibular	Foramen ovale	Mixed	**Motor to muscles** of mastication, tensor tympani, tensor veli palatine	Jaw deviation toward side of lesion
			General sensory from lower lip, chin, lower teeth and gingiva, and anterior two thirds of tongue (not taste)	• V3 loss of general sensation in skin over mandible, mandibular teeth, tongue; weakness in chewing • Trigeminal neuralgia—pain in V2 or V3 territory
VII-Facial	Internal acoustic meatus	Mixed	**1. Motor to muscles** of facial expression and stapedius, stylohyoid muscle; posterior belly of digastric muscle	Corner of mouth droops, cannot close eye, cannot wrinkle forehead, loss of blink reflex, hyperacusis; Bell palsy—lesion of nerve in facial canal
			2. Taste from anterior two thirds of tongue, taste via chorda tympani	Loss of taste (ageusia)
			3. Parasympathetic to lacrimal, submandibular, and sublingual glands	Dry eye; dry mouth
IX-Glossopharyngeal	Jugular foramen	Mixed	**1. General sensory** from oropharynx, middle ear, auditory tube, carotid body and sinus, external ear, posterior third of tongue (including taste)	Loss of gag reflex with X
			2. Motor to stylopharyngeus muscle	
			3. Parasympathetic to parotid gland	Dry mouth
X-Vagus	Jugular foramen	Mixed	**1a. Motor** to pharyngeal muscles (5)	Dysphagia
			b. Motor to soft palate muscles	• Nasal speech, nasal regurgitation; palate droop • Uvula pointing away from lesion side
			c. Motor to laryngeal muscles	Hoarseness/fixed vocal cord
			2. General sensory from larynx,trachea, esophagus, viscera, external ear, epiglottis (including taste)	• Loss of gag reflex with IX • Loss of cough reflex
			3. Parasympathetic to viscera of thorax, and foregut, and midgut	

Please visit us at www.Groupinsiders.com

© DeVry/Becker Educational Development Corp. All rights reserved.

3.1 Cross Section Features of the Brainstem

The brainstem contains numerous sensory and motor nuclei of cranial nerves. Afferent fibers of cranial nerves enter the brainstem and synapse on neurons located in sensory nuclei. The motor axons of cranial nerves have their cell bodies in motor nuclei (somatic or autonomic) and exit via the cranial nerves for peripheral distribution.

There is an orderly arrangement of the nuclei in the brainstem. Columns of neuronal cell groups associated with cranial nerves follow a medial-to-lateral arrangement in the brainstem. The motor nuclei are located medially toward the midline of the brainstem, and the sensory nuclei are located more laterally in the brainstem. Knowledge of the locations of nuclei in the brainstem (level and lateral versus medial) as well as the locations of long tracts that traverse the brainstem is important in localizing a brainstem lesion (Figures 17–3.1A–D).

Two major goals in studying cross sections are:

1. Be able to identify the level of the brainstem based on a few distinguishing characteristics; and
2. Identify the medial and lateral location of the major motor and sensory nuclei within each section.

Will first identify the major motor nuclei and then will identify the major sensory nuclei.

Please visit us at www.Groupinsiders.com

© DeVry/Becker Educational Development Corp. All rights reserved.

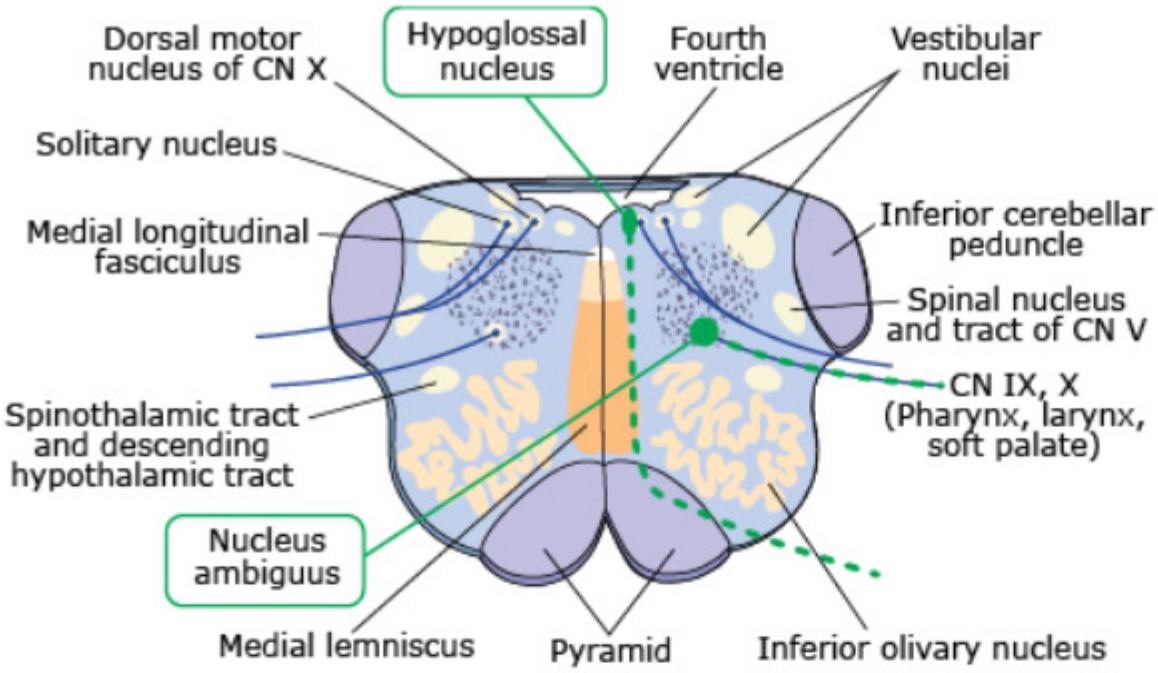

Note: LMN nuclei of cranial nerves (green)

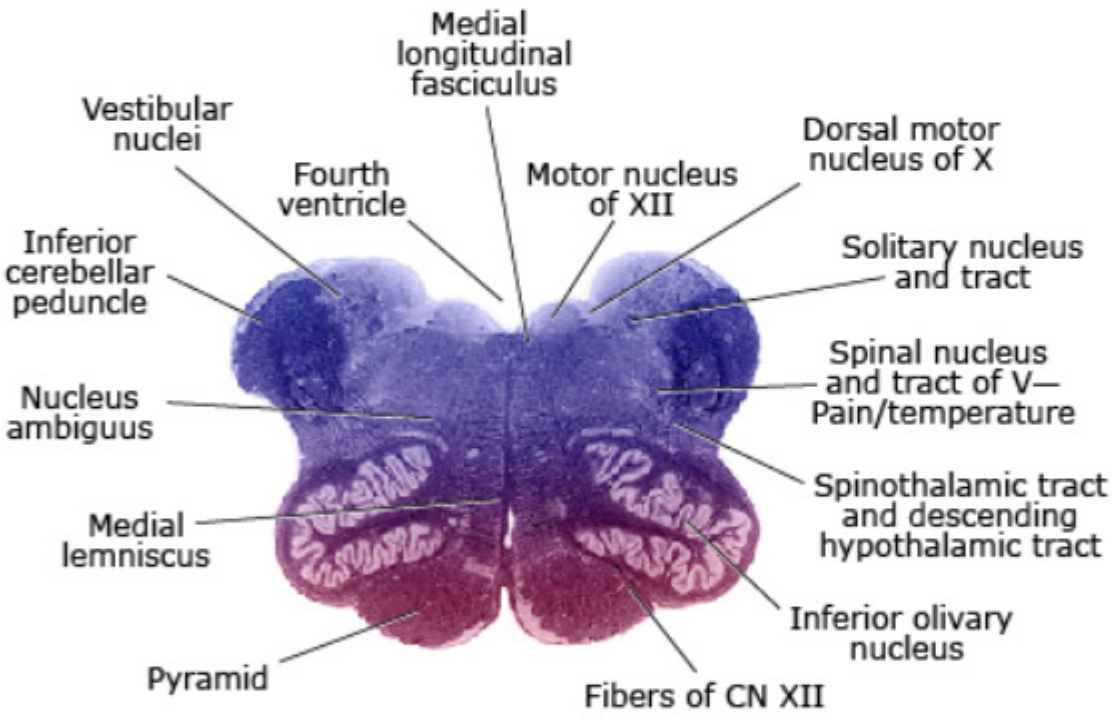

▲ **Figure 17–3.1A** Upper Medulla

Please visit us at www.Groupinsiders.com

© DeVry/Becker Educational Development Corp. All rights reserved.

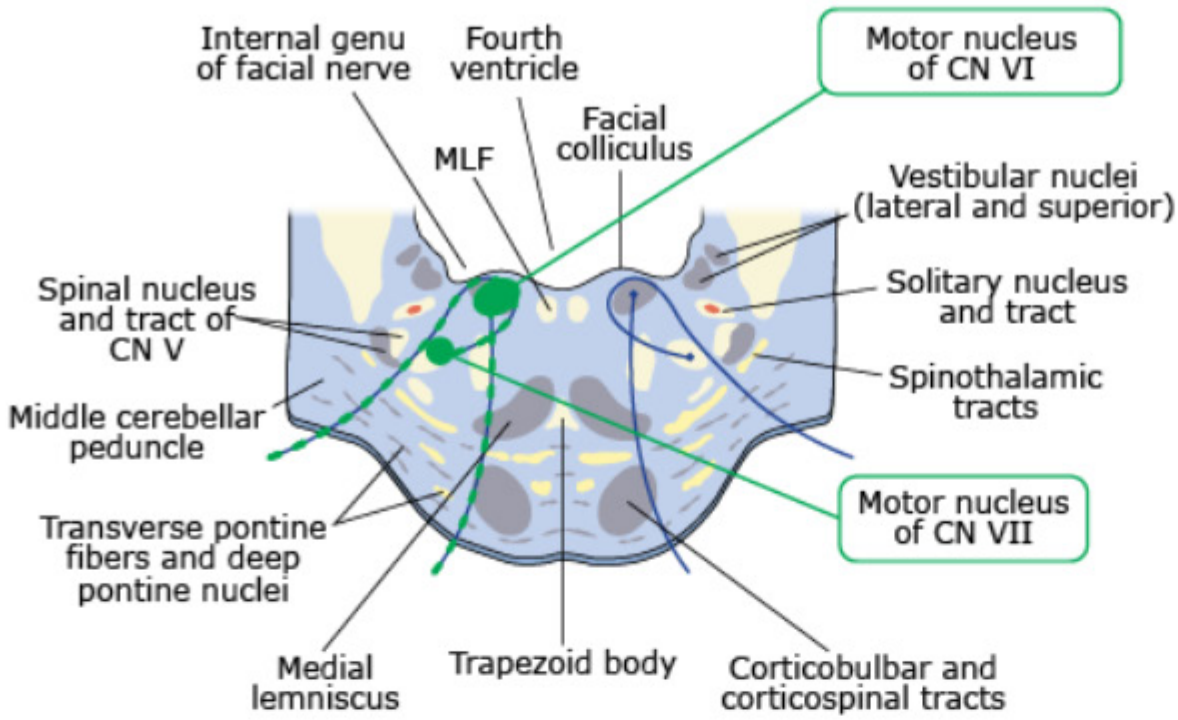

Note: LMN nuclei of cranial nerves (green)

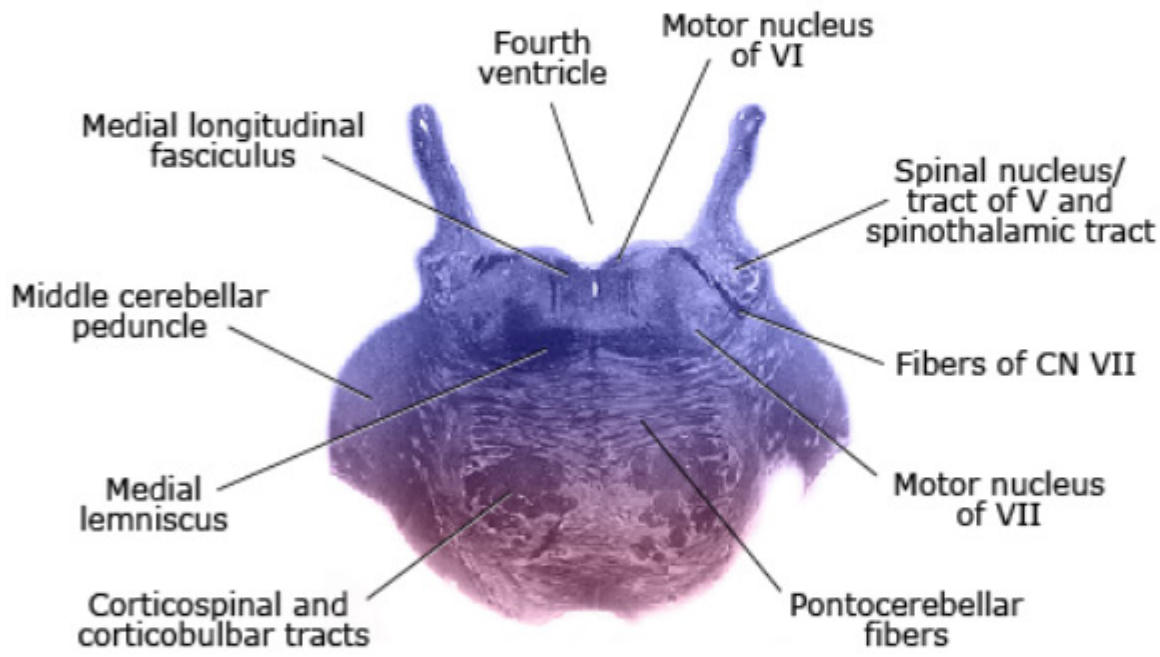

▲ **Figure 17–3.1B** Lower Pons

Please visit us at www.Groupinsiders.com

© DeVry/Becker Educational Development Corp. All rights reserved.

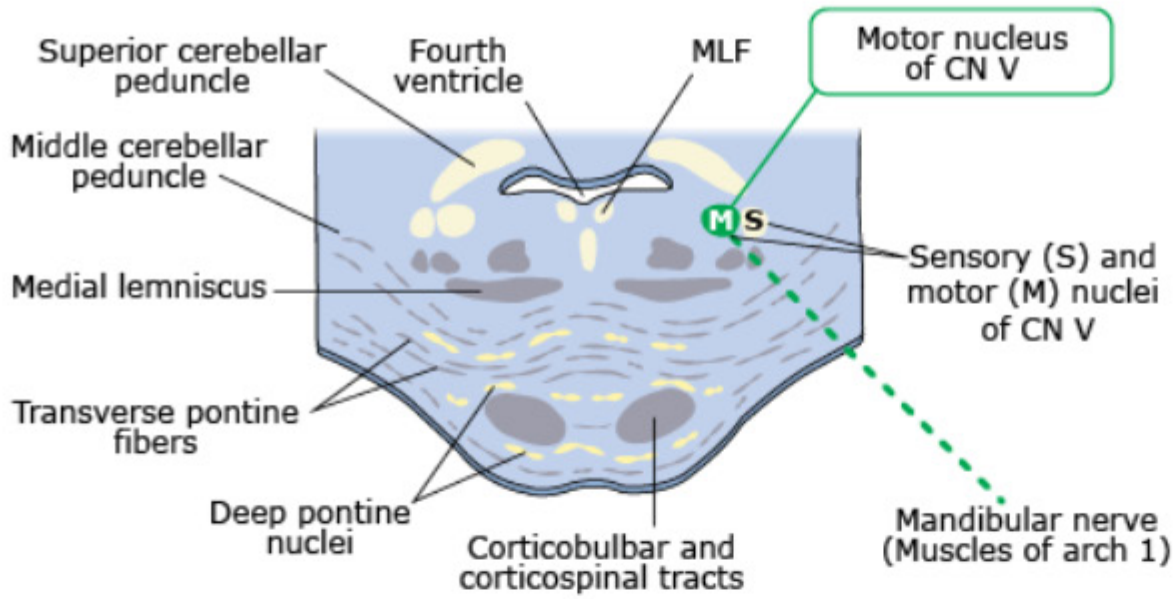

Note: LMN nuclei of cranial nerves (green)

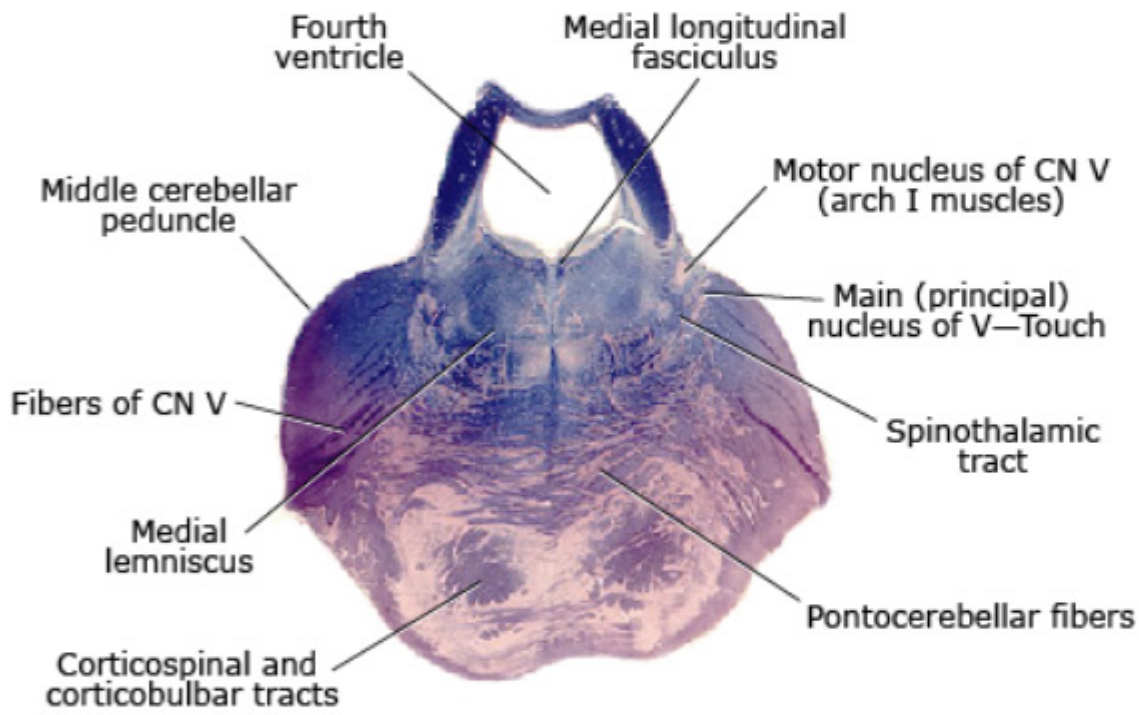

▲ **Figure 17–3.1C** Mid Pons

Please visit us at www.Groupinsiders.com

© DeVry/Becker Educational Development Corp. All rights reserved.

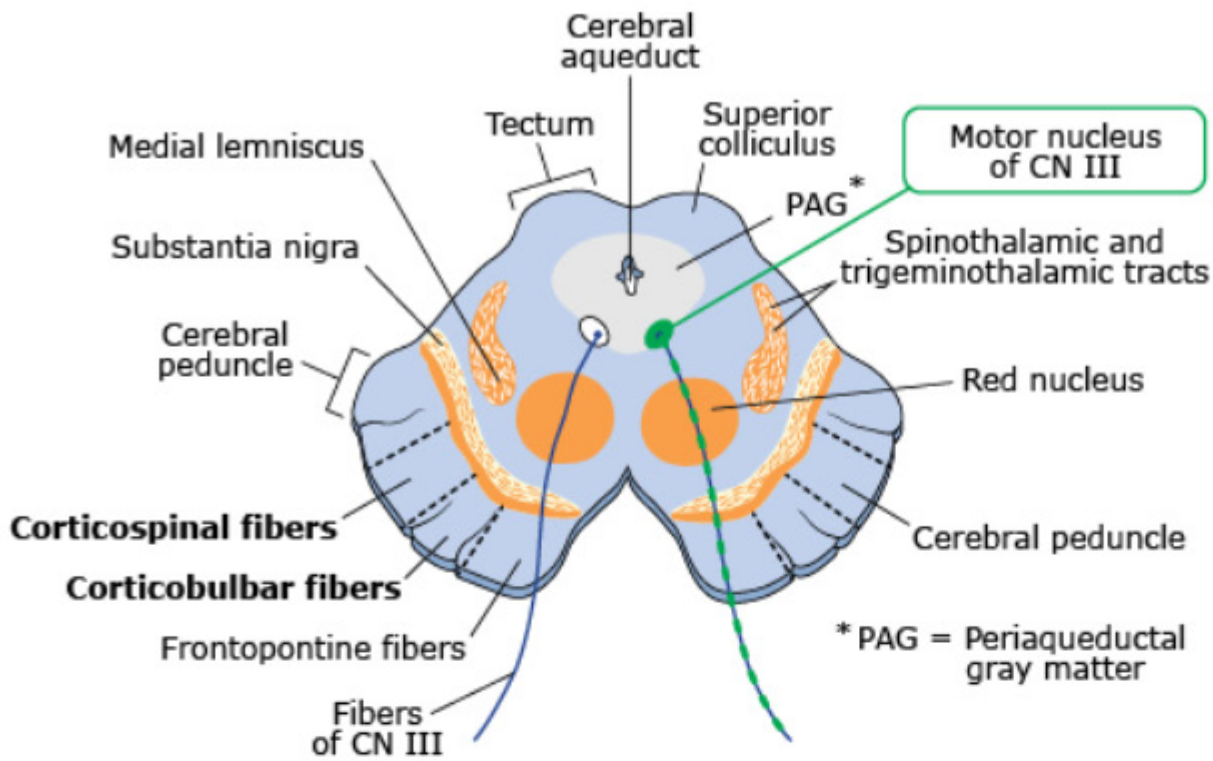

Note: LMN nuclei of cranial nerves (green)

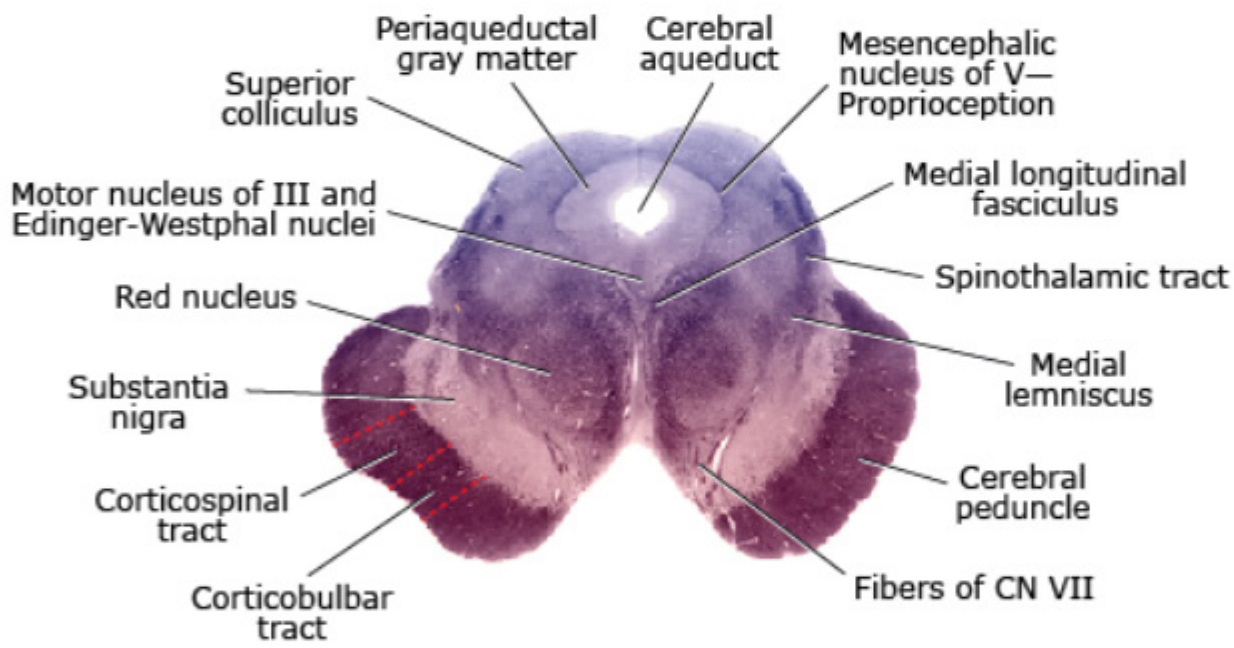

▲ **Figure 17–3.1D** Midbrain

Please visit us at www.Groupinsiders.com

© DeVry/Becker Educational Development Corp. All rights reserved.

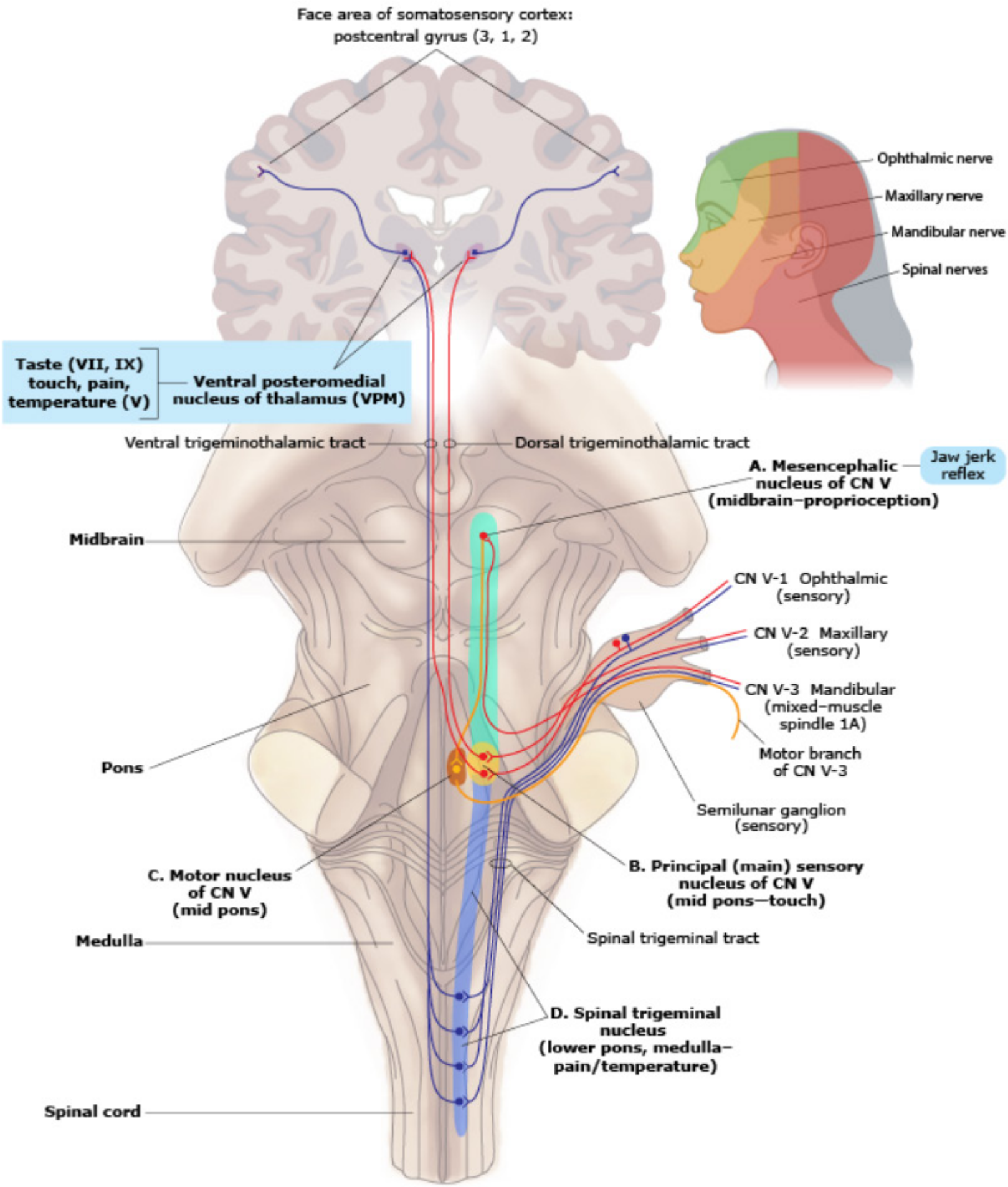

▲ **Figure 17–3.1E** Trigeminal Nucleus

Please visit us at www.Groupinsiders.com

© DeVry/Becker Educational Development Corp. All rights reserved.

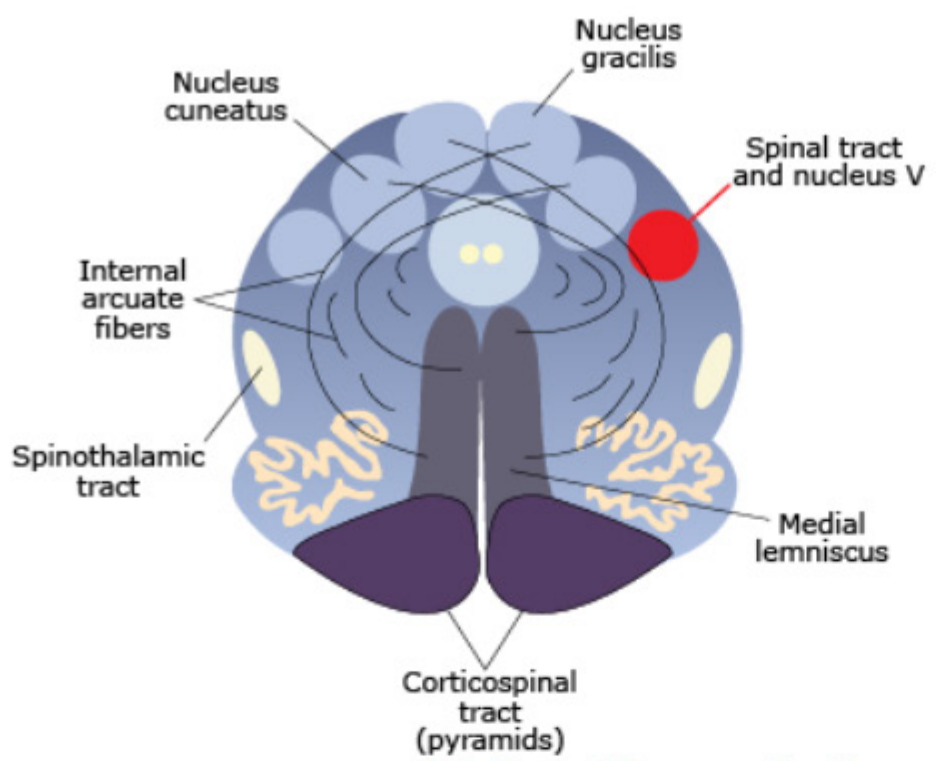

Note: Sensory nuclei of cranial nerves (red)

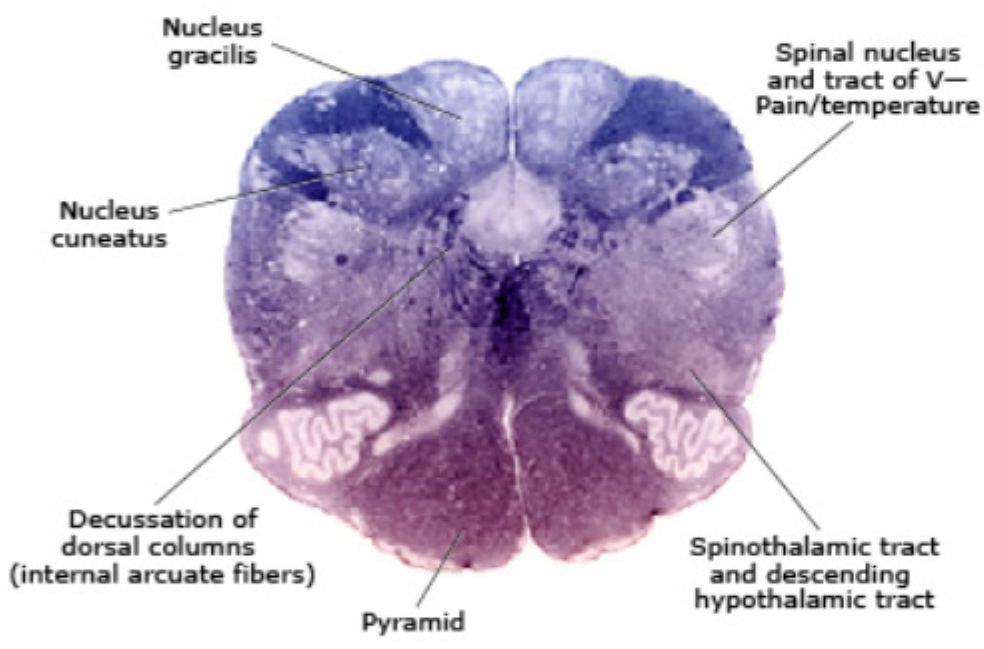

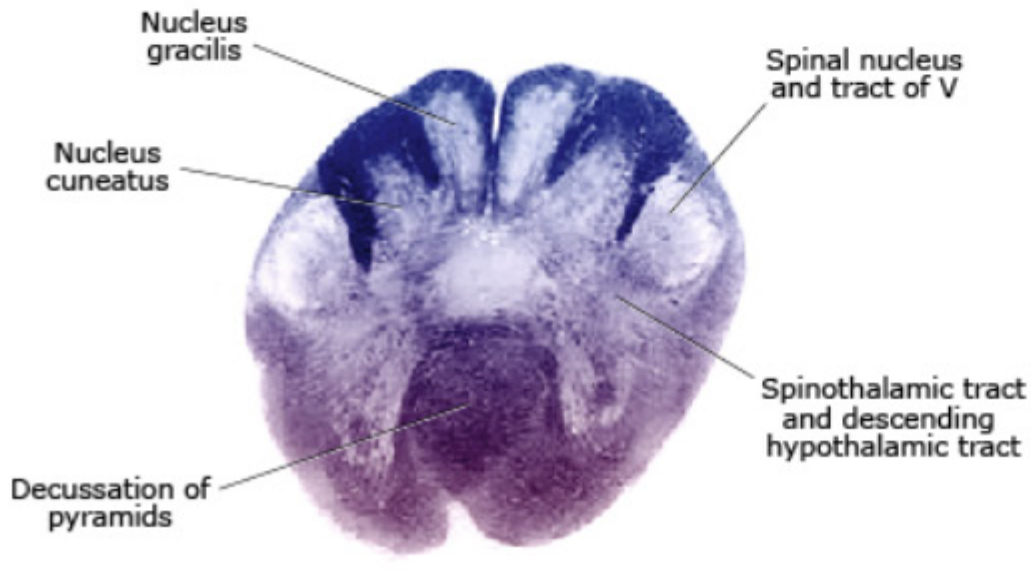

▲ **Figure 17–3.1F** Lower Medulla

Please visit us at www.Groupinsiders.com

© DeVry/Becker Educational Development Corp. All rights reserved.

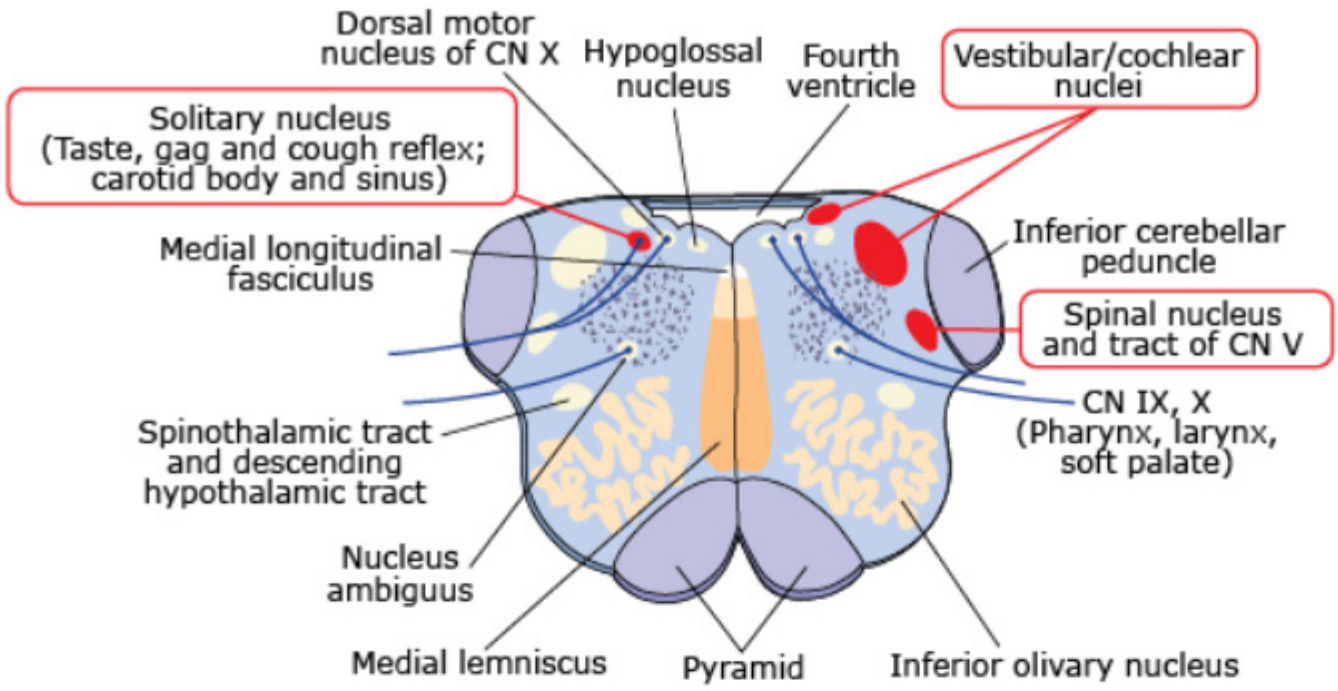

Note: Sensory nuclei of cranial nerves (red)

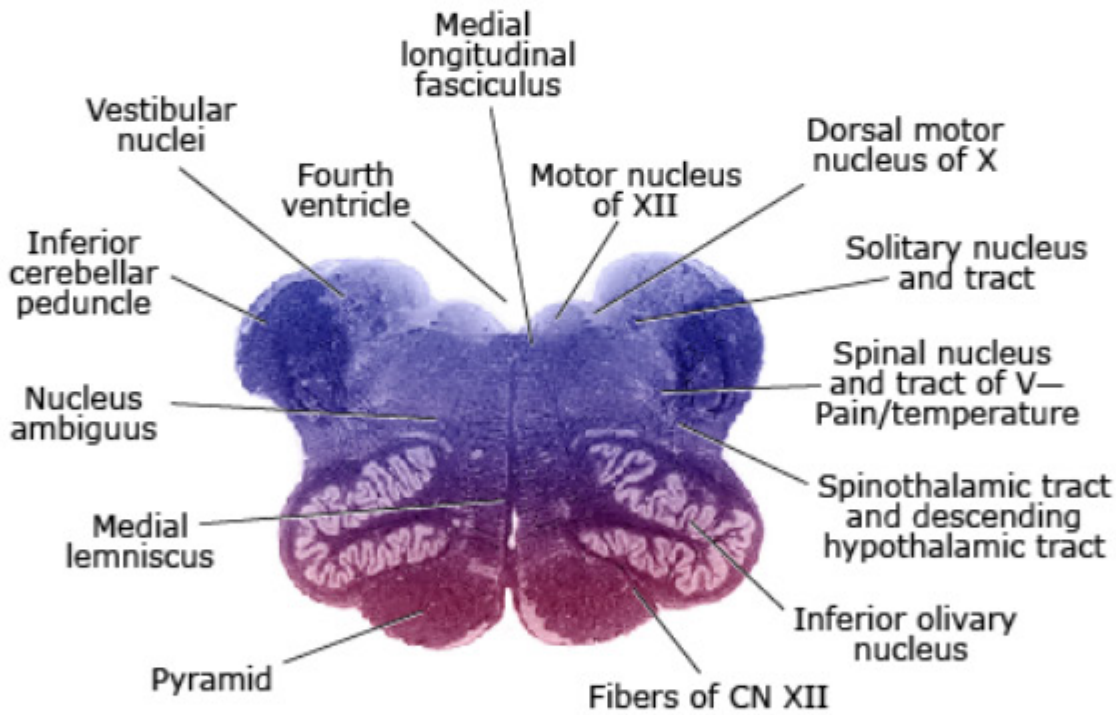

▲ **Figure 17–3.1G** Upper Medulla

Please visit us at www.Groupinsiders.com

© DeVry/Becker Educational Development Corp. All rights reserved.

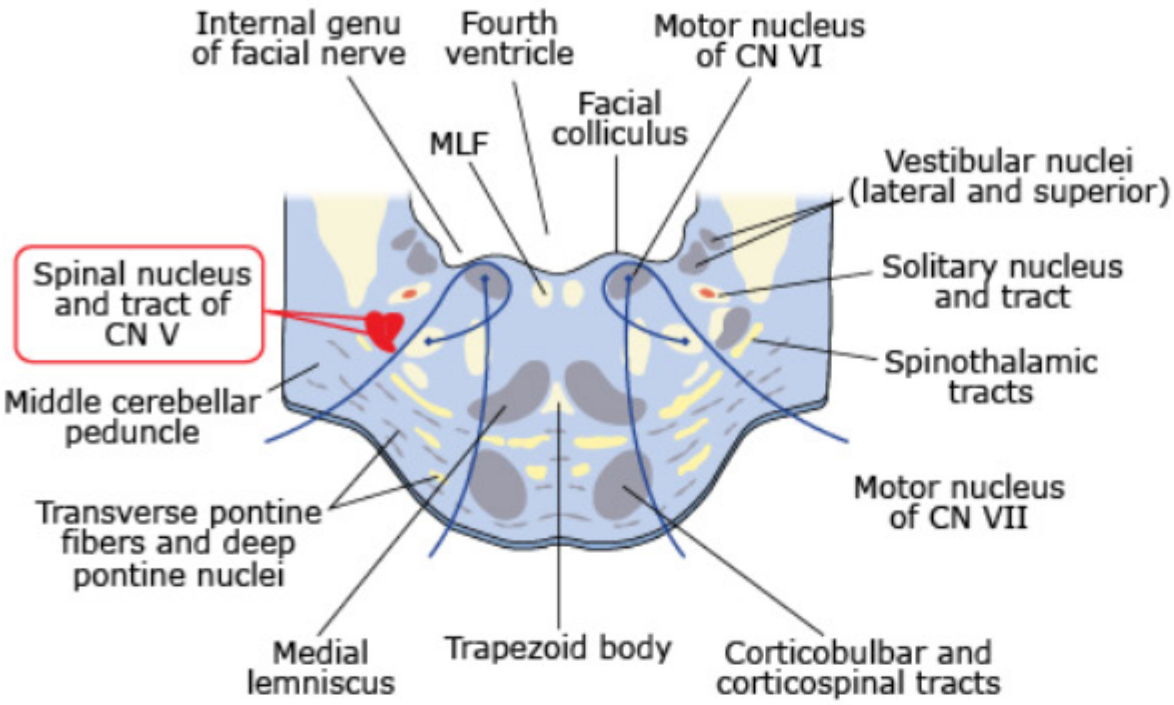

Note: Sensory nuclei of cranial nerves (red)

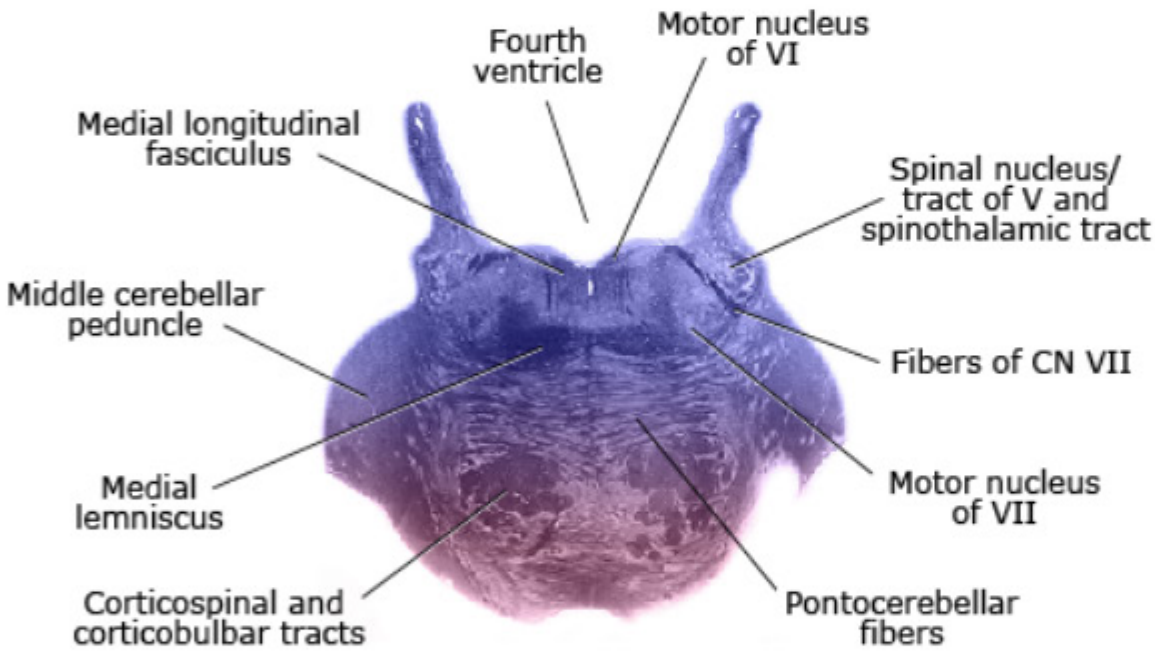

▲ **Figure 17–3.1H** Lower Pons

Please visit us at www.Groupinsiders.com

© DeVry/Becker Educational Development Corp. All rights reserved.

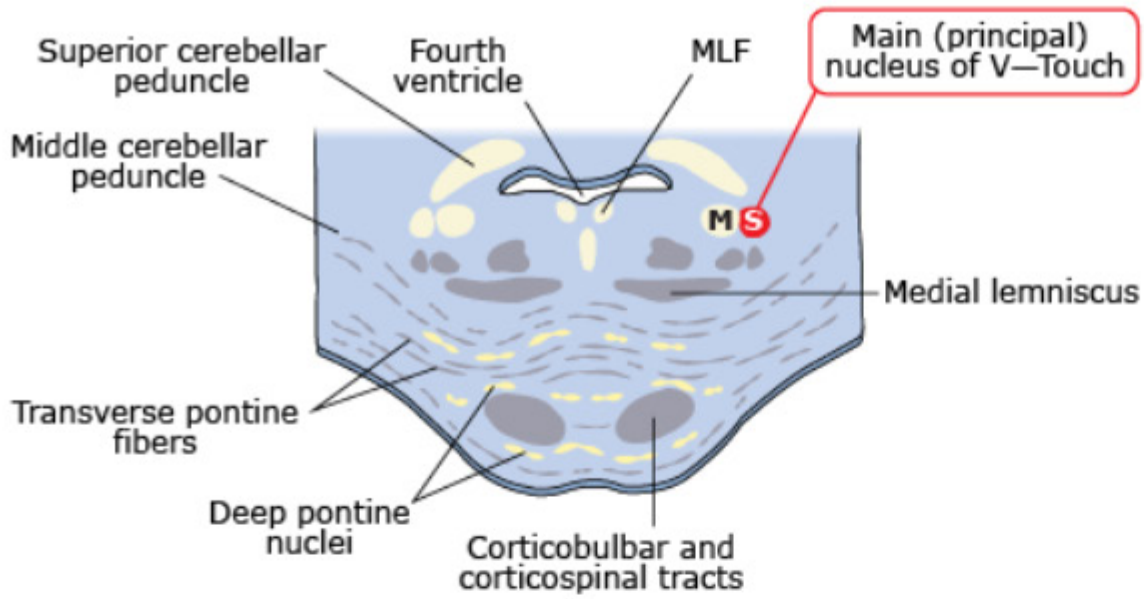

Note: Sensory nuclei of cranial nerves (red)

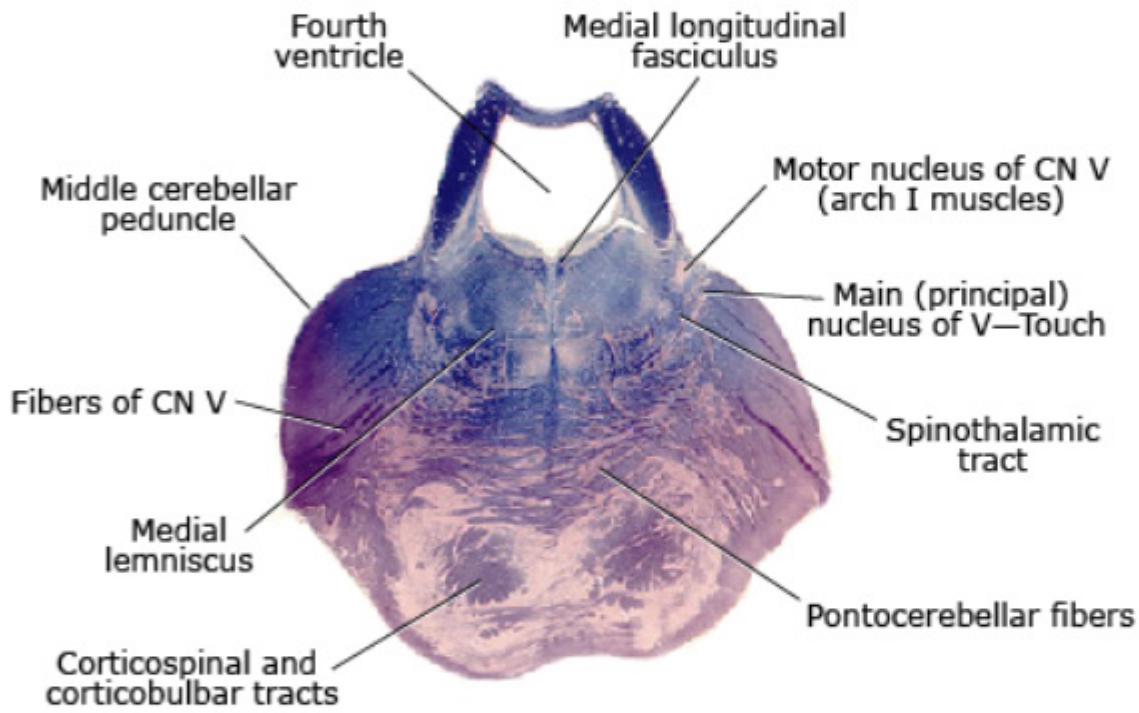

▲ **Figure 17–3.1l** Mid-Upper Pons

Please visit us at www.Groupinsiders.com

© DeVry/Becker Educational Development Corp. All rights reserved.

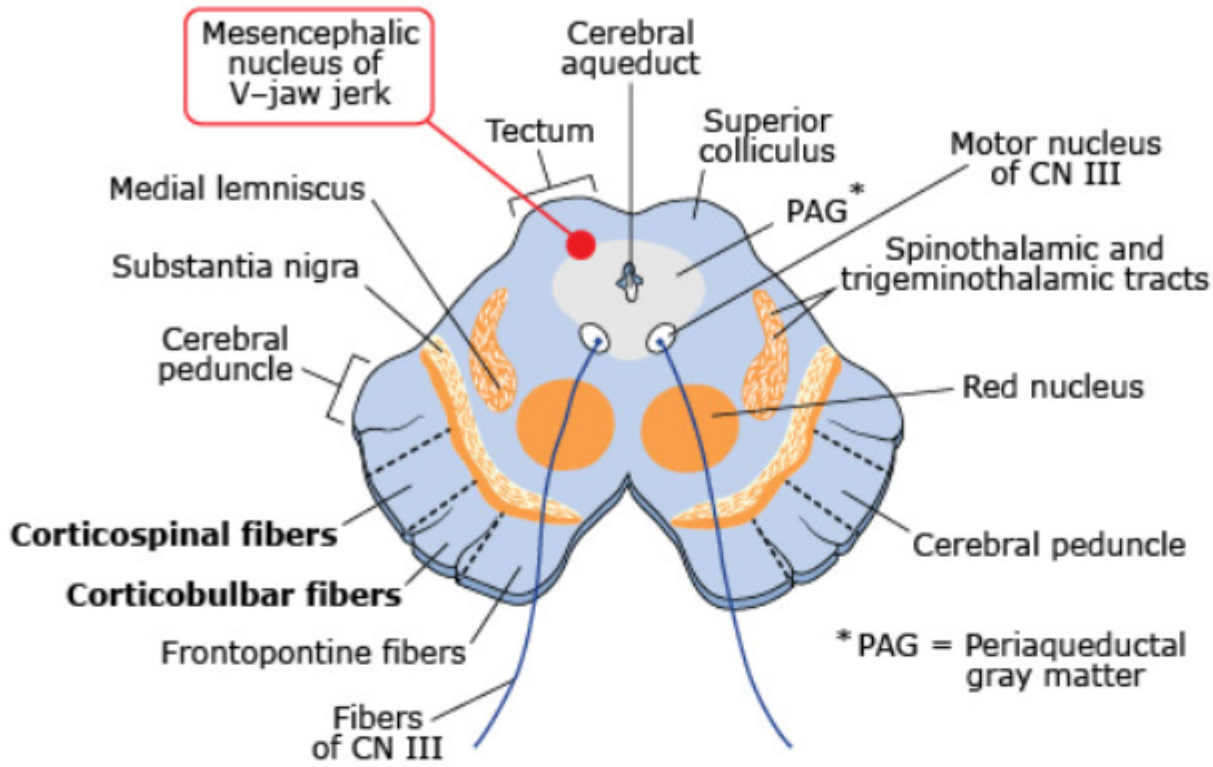

Note: Sensory nuclei of cranial nerves (red)

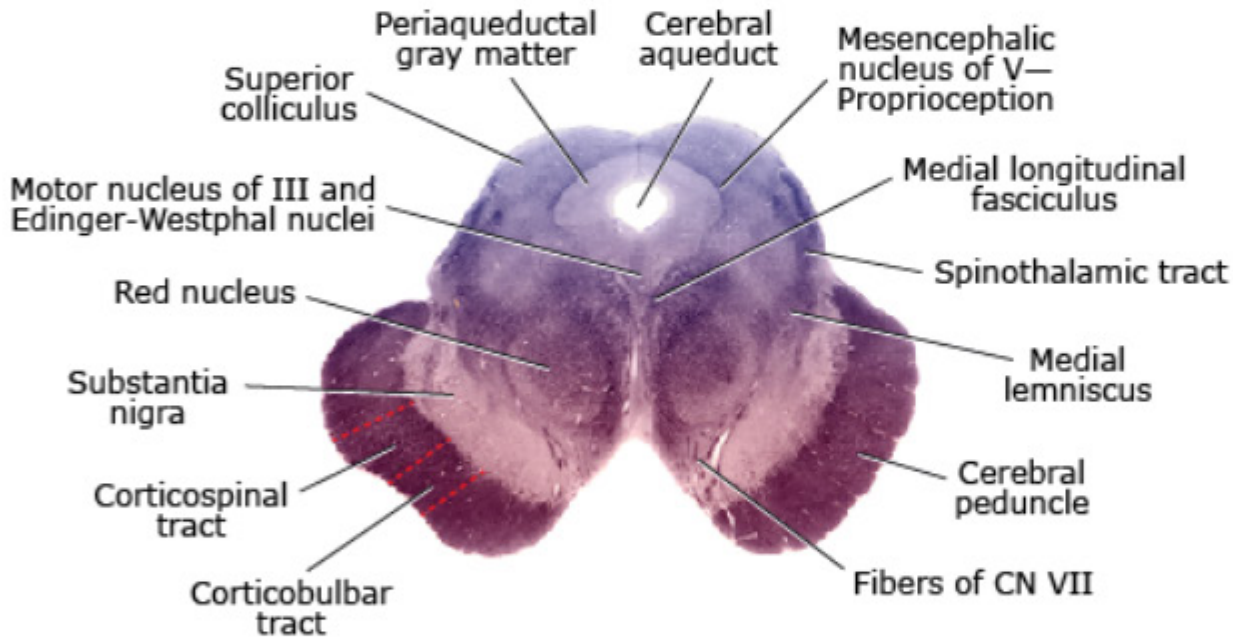

▲ **Figure 17–3.1J** Midbrain

Please visit us at www.Groupinsiders.com

© DeVry/Becker Educational Development Corp. All rights reserved.

4 Position of Long Tracts in Brainstem

- Corticospinal tract runs medial and ventral through the brainstem.
- Medial lemniscus begins medial in lower two thirds of the brainstem but moves laterally in midbrain.
- Spinothalamic tract and descending hypothalamic tract run laterally throughout the brainstem.

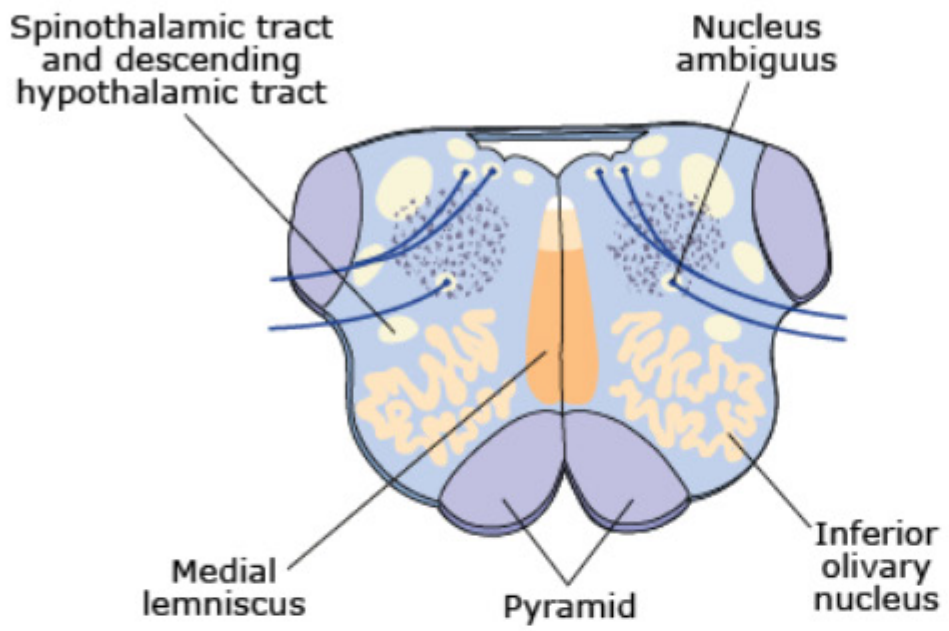

▲ **Figure 17–4.0** Long Tracts in Brainstem

Please visit us at www.Groupinsiders.com

© DeVry/Becker Educational Development Corp. All rights reserved.

5 Internal Organization of the Brainstem and Medulla Oblongata

5.1 Lower or Closed Medulla

The lower medulla is the most caudal part of the brainstem and is the area of transition from the spinal cord to the brainstem. The lower medulla is the site of two long tract decussations: *dorsal columns and corticospinal tract*. There are no lower motor neuron nuclei of cranial nerves in the lower medulla. Sensory pathways of the trigeminal system are found laterally.

5.2 Long Tracts of the Lower Medulla

- **Corticospinal Tract**
  The *pyramids* are located *ventrally* on either side of the midline of the lower medulla and contain the descending fibers of the *corticospinal tract*. The *pyramidal decussation* of the corticospinal fibers is a major feature of the lower medulla and is where most of the axons of the corticospinal tract decussate.
- **Dorsal Column—Medial Lemniscus Tract**
  On the *dorsal* aspect of the caudal medulla, the ascending axons of the *dorsal columns* course on each side of the midline. These fibers carry epicritic and conscious proprioceptive fibers from the trunk and limbs that synapse with the second-order neurons in the *nucleus gracilis* and *cuneatus* on the dorsal aspect of the lower medulla. The axons of these second-order neurons leave the nuclei and *decussate* across the midline (internal arcuate fibers) to form the *medial lemniscus* that ascends to the VPL nucleus of the thalamus.
- **Spinothalamic Tract**
  The *spinothalamic tract* carries pain and temperature fibers from the trunk and limbs and courses with the *descending hypothalamic fibers* on the lateral aspect of the lower medulla.

Important Concept

The spinothalamic tract courses with the descending hypothalamic tract

5.3 Major Nuclei of Lower Medulla

- **Spinal Nucleus and Tract of V:** The *spinal nucleus of V* is located on the dorsolateral aspect of the lower and upper medulla and contains the second-order neurons of the trigeminal fibers that convey pain and temperature from the face. Just lateral to the spinal nucleus is the *spinal tract of the trigeminal nerve*. The central processes of the first–order neurons in the trigeminal ganglion enter the tract at the midpons and descend in the spinal tract, where they synapse on the neurons in the spinal nucleus of V. The nucleus and tract will continue inferiorly for a few segments into the upper cervical spinal cord, where they blend into the dorsal horn of spinal cord gray matter. Superiorly, the nucleus and tract ascend through the lateral upper medulla and into the lateral pons.
- **Nucleus Gracilis and Cuneatus:** These two nuclei are located on the dorsal aspect of the lower medulla. The nuclei contain the cell bodies of the second-order neurons of the dorsal column-medial lemniscus pathway.

Please visit us at www.Groupinsiders.com

© DeVry/Becker Educational Development Corp. All rights reserved.

5.4 Upper or Open Medulla

The *upper medulla* is one of the most distinctive levels of the brainstem. It houses two lower motor neuron nuclei of the brainstem: *nucleus ambiguus* laterally and the *hypoglossal nucleus* medially. The *inferior cerebellar peduncle* attaches to the dorsolateral surface and connects the upper medulla with the cerebellum.

5.5 Long Tracts of the Upper Medulla

- **Pyramids:** The pyramids ascend on either side of the ventral midline of the upper medulla and contain the fibers of the corticospinal tract *above their decussation*. The two pyramids form very distinctive features on the ventral surface of the upper medulla.
- **Spinothalamic Tract:** The pain and temperature fibers of the spinothalamic tract courses on the lateral aspect of the upper medulla. The *descending hypothalamic tract* travels with the spinothalamic tract.
- **Medial Lemniscus:** The medial lemniscus courses on either side of the midline just dorsal to the pyramids.
- **Medial Longitudinal Fasciculus:** The medial longitudinal fasciculi (MLF) are paired, heavily myelinated tracts on either side of the dorsal midline just posterior to the medial lemniscus close to the floor of the fourth ventricle. The MLF fibers ascend all the way up to the midbrain and convey visual functions concerned with horizontal gaze and the vestibulo-ocular reflex (discussed later).

5.6 Major Nuclei of the Upper Medulla

- **Hypoglossal Nucleus:** In the upper medulla, the hypoglossal nuclei are located *medially* on either side of the dorsal midline in the floor of the fourth. The nucleus contains alpha lower motor neurons whose axons pass ventrally and medially to exit the upper medulla anterior to the olive. The fibers innervate most of the muscles of the tongue. A unilateral lesion of the hypoglossal fibers will cause the tongue to *deviate to the side of the lesion* upon protrusion of the tongue.
- **Nucleus ambiguus:** The nucleus ambiguus is located *laterally* in the upper medulla immediately dorsal to the inferior olivary nucleus. The nucleus ambiguus contains the lower motor neurons whose axons course in CN IX and X. The axons of the CN IX supply a single muscle (stylopharyngeus) but the vagal fibers supply a large group of skeletal muscles of the pharynx (except one muscle), larynx, and the soft palate. A unilateral lesion will result in a severe weakness in swallowing (*dysphasia*), a paralysis of ipsilateral vocal folds with a *hoarse, rough voice*, and a weakness in the muscles of the soft palate with *deviation of the soft palate away from the lesioned side*.
- **Dorsal Motor Nucleus of CN X:** The dorsal motor nucleus of X is lateral to the hypoglossal nucleus in the floor of the fourth ventricle. The dorsal nucleus contains preganglionic parasympathetic neuron cell bodies of the vagus nerve. These fibers synapse in the terminal ganglia of the viscera of the thorax, foregut, and midgut.

Please visit us at www.Groupinsiders.com

© DeVry/Becker Educational Development Corp. All rights reserved.

- **Spinal Nucleus and Tract of V:** The spinal nucleus of V is located on the dorsolateral aspect of the medulla and contains the second-order neurons of the trigeminal nerve, which conveys pain and temperature from the face. Just lateral to the spinal nucleus is the spinal tract of the trigeminal nerve. The central processes of the first-order neurons in the trigeminal ganglion enter the tract and synapse on the neurons in the spinal nucleus of V.
- **Solitary Nucleus:** The solitary nucleus is lateral to the dorsal motor nucleus of X in the dorsal lateral upper medulla. The solitary nucleus is a visceral relay nucleus for taste from the ipsilateral side of the tongue, gag and cough reflex (CN IX and X), and the visceral circuits of the carotid body and sinus.
- **Inferior Olivary Nucleus:** The inferior olivary nucleus is a large, distinctive, convoluted nuclear complex located in the ventral upper medulla. The inferior olivary nucleus is a cerebellar relay nucleus that projects climbing fibers from the olivary nucleus via the inferior cerebellar peduncle to the contralateral cerebellar cortex.

  The inferior olivary nucleus forms a prominent, oval swelling on the ventrolateral surface of the upper medulla called the olive, one of the distinguishing features of the upper medulla. Cranial nerves IX and X attach to the lateral medulla dorsal to the olive, and cranial nerve XII attaches to the lateral medulla ventral to the olive.
- **Vestibular Nuclei:** The vestibular nuclei form a group of nuclei in the dorso lateral aspect of the lateral upper medulla. These nuclei are the first CNS relay to receive sensory input from vestibular receptors of CN VIII.

Please visit us at www.Groupinsiders.com

© DeVry/Becker Educational Development Corp. All rights reserved.

6 Pons

The pons is the central level of the brainstem containing a series of cranial nerve nuclei and other nuclear groups. The large trunk of CN V is attached laterally at the midpontine level, and cranial nerves VI, VII, and VIII derive from the pons at the pontomedullary junction. CN VI emerges medially close to the midline, CN VIII is most laterally, and CN VII (two roots) emerges between VI and VIII. The same three long tracts observed in the medulla continue through the pons.

6.1 Surface Features

- The *dorsal surface* of the pons and upper medulla form the floor of the fourth ventricle. The cerebellum covers the dorsal aspect of the pons and forms the roof of the fourth ventricle.
- The *ventral surface* of the pons is dominated by a large, rounded convex surface referred to as the *basilar pons*, which is a characteristic landmark used to identify the pons. Each side of the basilar pons contains numerous pontine nuclei, which receive frontal cortical fibers that descend through the cerebral peduncle of the midbrain to reach the nuclei in the pons. These pontine nuclei then send axons across the midline through the *middle cerebral peduncle* to enter the contralateral cerebellum.

6.2 Long Tracts of the Pons

- **Corticospinal and Corticobulbar Tracts:** The upper motor neuron fibers of the *corticospinal and corticobulbar tracts* descend as diffuse bundles in the basilar pons among the pontine nuclei.
- **Medial Lemniscus:** These fibers continue to course medially on either side of the midline.
- **Spinothalamic and Descending Hypothalamic Tract:** These fibers continue on the lateral aspect of the pons.
- **Lateral Lemniscus:** The lateral pons contains auditory relay circuits and fibers within the lateral lemniscus. The vestibular and cochlear nuclei of cranial nerve VIII are lateral at the pontomedullary junction.
- **MLF:** The MLF tracts for visual circuits continue in the dorsomedial position on both sides of the midline as it ascends to the midbrain. The MLF tracts are medial to the abducens nuclei.

6.3 Major Nuclei of the Pons

The pons contains several lower motor neuron nuclei of the brainstem: *abducens* and *facial nuclei* in the lower pons and the *motor nucleus of V* in the midpontine region.

- **Abducens Nucleus:** The *abducens nucleus* is located *medially* in the lower pons and lies on each side of the dorsal midline close to the floor of the fourth ventricle. The axons course ventral and medial to exit the ventral surface of the lower pons. The abducens nucleus contains the *lower motor neurons* to the lateral rectus, which functions in abduction of the eye. A lesion of this nucleus results in *ipsilateral medial strabismus*.

Please visit us at www.Groupinsiders.com

© DeVry/Becker Educational Development Corp. All rights reserved.

- **Motor Nucleus of VII:** The **motor nucleus of VII** is also a lower motor neuron nucleus of the lower pons but lies in a *ventrolateral* position in the pons. The motor nucleus of VII contains the lower motor neurons of CN VII that innervate the skeletal muscles that develop from the second pharyngeal arch, including the muscles of facial expression and the stapedius muscle. The axons leaving the nucleus course first dorsomedially and make a medial loop around the abducens nerve forming the facial colliculus (internal genu) in the floor of the fourth ventricle. The facial fibers then course laterally to exit the lateral surface of the lower pons.
- **Vestibular and Cochlear Nuclei:** The vestibular/cochlear nuclei form a cluster of nuclei in the *dorsolateral aspect* of the lateral upper medulla and lateral lower pons at the pontomedullary junction. These nuclei are the first CNS relay neurons to receive sensory input from the vestibular and auditory receptors of the inner ear via CN VIII. The trapezoid body is located in the midline of the central pons and is the site of decussation of auditory fibers from the cochlear nuclei. The superior olivary nucleus (relay nucleus for sound direction) and the lateral lemniscus (ascending fibers of the auditory pathway) are in the lateral pons.

6.4 Trigeminal Nuclei of Pons

Figures 17–3.1E through 17–3.1J illustrate the trigeminal cranial nerve system in the brainstem with its connections.

- **Spinal Nucleus and Tract of V:** This is the upward continuation into the *lateral pons* of the same nucleus and tract of the trigeminal nerve for pain and temperature discussed earlier.
- **Motor Nucleus of V:** The *motor nucleus of V* is the lower motor neuron nucleus of CN V located in the *lateral* midpontine level immediately medial to the main (principal) sensory nucleus of V. The alpha motor neurons of this nucleus exit the lateral midpons and distribute via the *mandibular division* of the trigeminal nerve to supply the skeletal muscles developed from the first pharyngeal arch (muscles of mastication and others). A lesion of the motor nucleus of V results in weakness of the masticator muscles and causes the *mandible to deviate to the side of the lesion*.
- **Main (Principal) Sensory Nucleus of V:** The *main sensory nucleus of V* is located lateral to the motor nucleus of V in the lateral midpons. The main sensory nucleus receives epicritic touch and vibration sensations from the face via the three divisions of CN V.
- **Mesencephalic Nucleus of V:** This *mesencephalic nucleus of V* begins in the lateral upper pons rostral to the main sensory nucleus and most of its course continues in the dorsolateral midbrain. The mesencephalic nucleus contains the 1a unipolar neurons that receive proprioceptive input from CN V.

Please visit us at www.Groupinsiders.com

© DeVry/Becker Educational Development Corp. All rights reserved.

7 Midbrain

The midbrain forms the rostral end of the brainstem and is continuous superiorly with the diencephalon. The midbrain contains two lower motor neuron nuclei of two cranial nerves: the *oculomotor (III) nerve* and the *trochlear nerve (IV)*. The narrow cerebral aqueduct courses through the center of the periaqueductal gray matter.

7.1 Surface Landmarks

The dorsal and ventral surfaces of the midbrain are marked by several unique landmarks that provide distinguishing features used to identify the upper midbrain:

- **Cerebral Peduncle:** Ventrally, the cerebral peduncles are two large, massive bundles of fibers on the ventrolateral aspects of each side of the midbrain. These bundles contain the descending axons of two major upper motor neuron systems, the *corticospinal* and *corticobulbar tracts*, and a massive number of frontopontine fibers to the basilar pons.
- **Tectum (Superior and Inferior Colliculi):** Dorsally, the surface of the midbrain is marked by four prominent masses, two superior and two inferior colliculi, which are referred to as the tectum. The superior colliculi are involved in reflex eye movements and the inferior colliculi are part of the auditory circuit that receives fibers from the lateral lemniscus and projects superiorly to the medial geniculate body of the thalamus.
- The *pretectum* lies on both sides of the pineal gland and cranial to the superior colliculi. This area is involved in the circuit for the pupillary light reflex and contains a center for vertical gaze. The pretectum is a lesion site following a pituitary tumor.

7.2 Long Tracts of the Midbrain

- **Medial Lemniscus and Spinothalamic Tracts:** The medial lemniscus fibers (MLF) have moved laterally and joined with the spinothalamic tract dorsolateral to the periaqueductal gray matter.
- The *MLF* courses dorsomedially on each side of the midline on the ventral surface of the periaqueductal gray matter.
- **Corticospinal and Corticobulbar Tracts:** These two upper motor neuron systems descend through the cerebral peduncle. The corticospinal fibers occupy the middle third of the peduncle and the corticobulbar fibers are medial to the corticospinal fibers.

7.3 Nuclei of the Midbrain

- **Oculomotor Nucleus:** The oculomotor nuclei are located on either side of the midline in the ventral periaqueductal gray matter at the level of the superior colliculi. The nucleus contains the lower motor neurons of CN III that innervate five of the seven muscles in the orbit. The Edinger-Westphal nuclei of CN III are immediately lateral to the oculomotor nuclei and contain preganglionic fibers of CN III that project to the ciliary ganglion. The ciliary ganglion contains the postganglionic fibers that innervate the ciliary muscle and the constrictor muscle of the pupil.

Please visit us at www.Groupinsiders.com

© DeVry/Becker Educational Development Corp. All rights reserved.

- **Trochlear Nucleus:** The trochlear nucleus is located at the level of the inferior colliculus in the ventral aspect of the periaqueductal gray matter. The lower motor neurons of the trochlear nucleus innervate the superior oblique muscle. The axons decussate in the dorsal aspect of the midbrain and are the only lower motor neurons in the brainstem that decussate.
- **Substantia Nigra:** The substantia nigra are large paired pigmented nuclei that are part of the circuitry of the basal ganglia. The neurons of the compact part project *dopaminergic fibers* to the striatum that are critical for initiating movement.
- **Red Nucleus:** The red nuclei are located dorsal to the substantia nigra and are relay nuclei of fibers from the cerebellar deep nuclei. These neurons form the rubospinal tract.
- **Mesencephalic Nucleus:** The mesencephalic nucleus is located dorsolaterally to the periaqueductal gray at the level of the superior colliculus. The mesencephalic nucleus contains the unipolar proprioceptive neurons that receive proprioceptive input of Ia CN V from muscle spindles primarily from the muscles of mastication, extraocular muscles and the periodontal ligaments of the teeth. The sensory input from the masticator muscles is the sensory side of the *jaw jerk reflex*, with the motor side being the lower motor neurons of the motor nucleus of V in the lateral mid pons.

Clinical Application

Jaw Jerk Reflex

The jaw jerk reflex is a deep muscle stretch reflex that is initiated by a tap on the chin which stimulates the 1a neurons of the muscle spindles in the masticator muscles. The 1a output of the muscle spindles routes through the trigeminal nerve to the mesencephalic nucleus which forms the sensory side of the jaw jerk reflex. The fibers of the mesencephalic neurons project to the lower motor neurons in the motor nucleus of V which innervate the muscles of mastication, resulting in a jerk of the jaw.

Please visit us at www.Groupinsiders.com

© DeVry/Becker Educational Development Corp. All rights reserved.

8 Corticobulbar Tract: Upper Motor Neurons for Cranial Nerve and Lower Motor Neurons

Important Concept

Corticobulbar UMN provide bilateral innervation to many of the LMN nuclei of the brain stem.

- The *corticobulbar (corticonuclear) tract* provides the upper motor neuron innervation of lower motor neurons in the brainstem. The corticobulbar fibers originate from the head region of the motor cortex on the lateral surface of the frontal lobe (areas 4 and 6). These fibers descend through the genu of the internal capsule and then course through the cerebral peduncle of the midbrain medial to the corticospinal fibers. In the brainstem, corticobulbar fibers *bilaterally* innervate most of the cranial nerve's lower motor nuclei on both sides of the brainstem. Therefore, many of the lower motor neuron nuclei on one side of the brainstem are innervated by contralateral and ipsilateral UMN. A major exception is CN VII, which receives only partial bilateral innervation (discussed below).

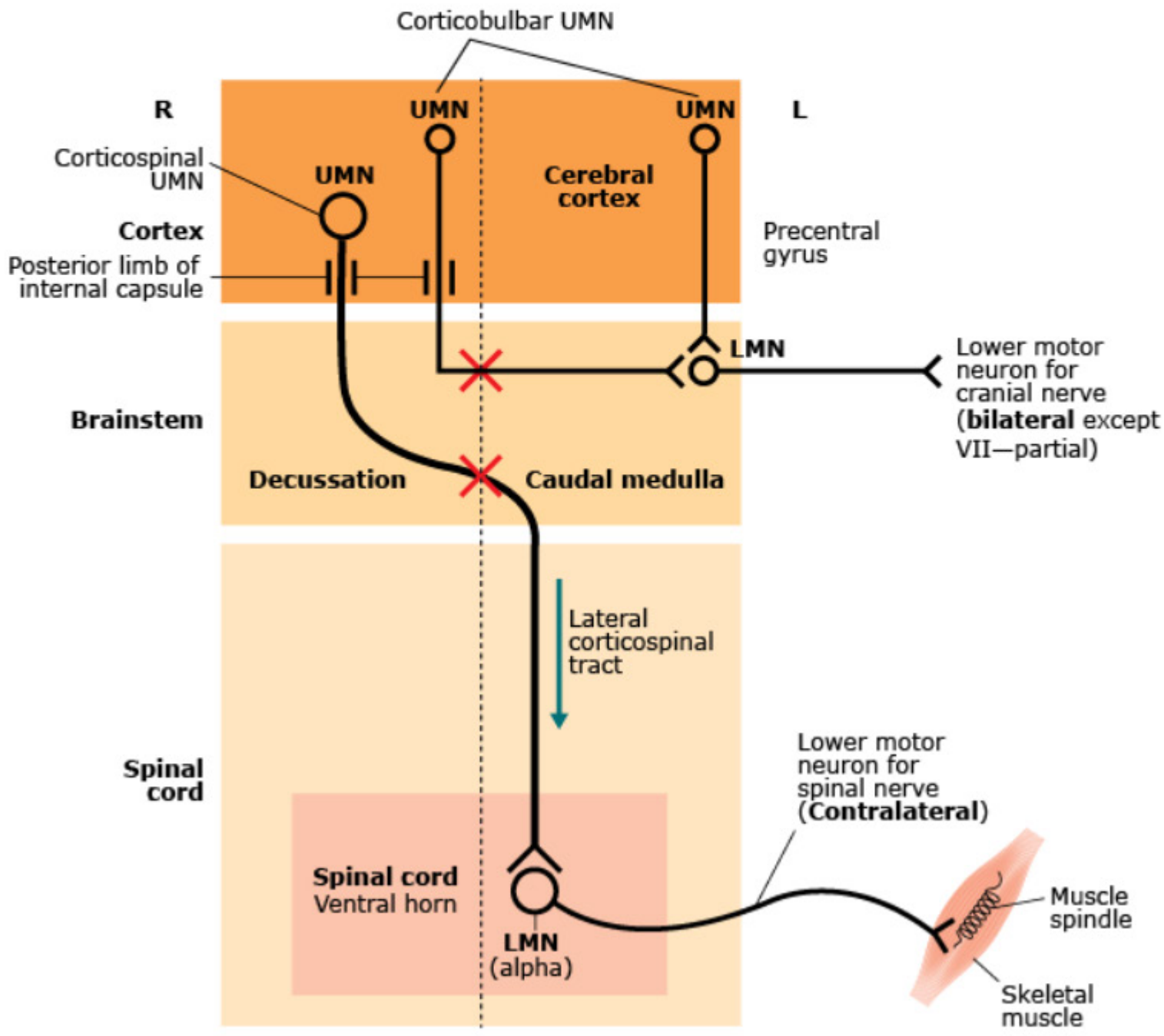

▲ **Figure 17–8.0** Corticobulbar Tract

Please visit us at www.Groupinsiders.com

© DeVry/Becker Educational Development Corp. All rights reserved.

- The major cranial nerve nuclei receiving bilateral corticobulbar innervation are listed below. Note that lower motor neurons in cranial nerves III, IV, and VI do not receive any significant direct corticobulbar fibers:
  - Motor nucleus of V to muscles of first arch.
  - Nucleus ambiguus of IX and X to muscles of larynx, pharynx, and soft palate.
  - Motor nucleus of VII: Receives only partial bilateral supply.
  - Hypoglossal nucleus of XII to muscles of tongue.
  - CN XI to sternocleidomastoid and trapezius muscles.
- In contrast, the corticospinal upper motor neuron fibers to the limbs descend from the cortex and decussate in the caudal medulla to supply contralateral lower motor neurons in the spinal cord.

8.1 Relationship of Cranial Nerve VII to the Corticobulbar Innervation

As noted, the motor nucleus of CN VII receives only partial bilateral innervation from corticobulbar upper motor neurons. The LMN to the upper facial muscles around the eye and forehead receive *bilateral* upper motor neuron innervation from both the right and left motor cortex, while the lower motor neurons to lower facial muscles around the mouth receive only *contralateral* corticobulbar innervation from the opposite cortex (Figure 17–8.1A). Thus, the muscles of the lower face receive upper motor innervation similar to the crossed fibers of the corticospinal tract, which supplies contralateral lower motor neurons of the trunk and limbs.

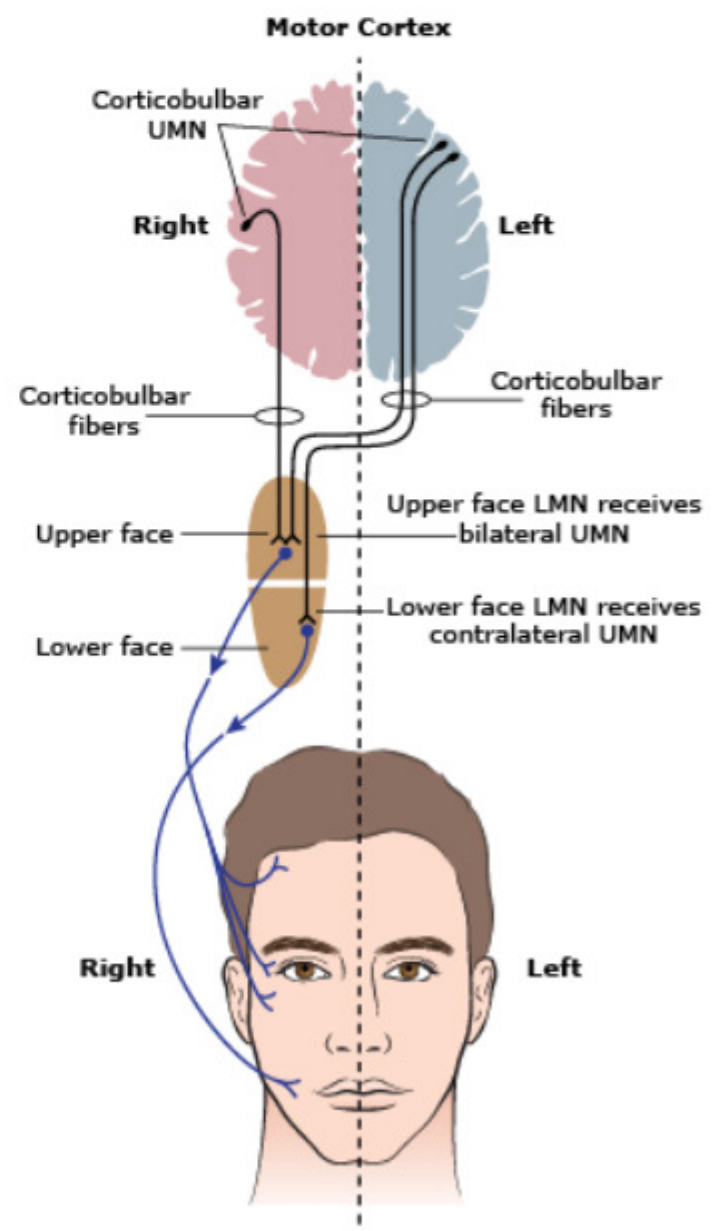

▲ **Figure 17–8.1A** Corticobulbar Innervation of CN VII

Please visit us at www.Groupinsiders.com

© DeVry/Becker Educational Development Corp. All rights reserved.

Clinical Application

Lesions of the CN VII

The consequence of this pattern of partial bilateral innervation by corticobulbar fibers to CN VII is that unilateral lesions of the corticobulbar fibers above the pons result in contralateral muscle weakness of the muscles around the mouth, while the muscles around the eye are minimally affected and can close the eye.

This pattern of innervation provides several distinguishing clinical deficits of CN VII that are critical in distinguishing between supranuclear, nuclear, and peripheral lesions of CN VII. These three types of lesions of CN VII are shown in Figures 17–8.1B, 17–8.1C, and 17–8.1D:

1. **Supranuclear Lesion:** One of the more common causes of a unilateral lesion of the corticobulbar tract at or above the internal capsule is a vascular stroke. A unilateral supranuclear lesion results in *contralateral lower* face weakness at the mouth; the eyes close normally.
2. **Nuclear Lesion:** A brainstem nuclear lesion of the motor nucleus of VII at the lateral lower pons (usually due to a vascular stroke) results in total *ipsilateral paralysis* of facial muscles. The lateral pontine lesion would also damage other cranial nerve nuclei (V and VIII), resulting in multiple cranial nerve lesions.
3. **Peripheral Lesion:** A peripheral nerve lesion of the seventh cranial nerve between the brainstem and the facial muscles (usually at stylomastoid foramen or parotid gland) also produces total *ipsilateral paralysis* of facial muscles but *without* any other cranial nerve deficits. Bell palsy is a common cause of a peripheral lesion.

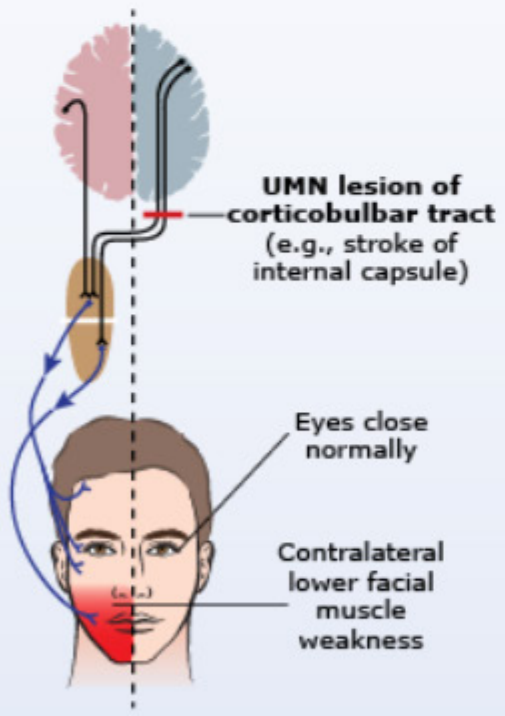

▲ **Figure 17–8.1B**
Supranuclear Lesion

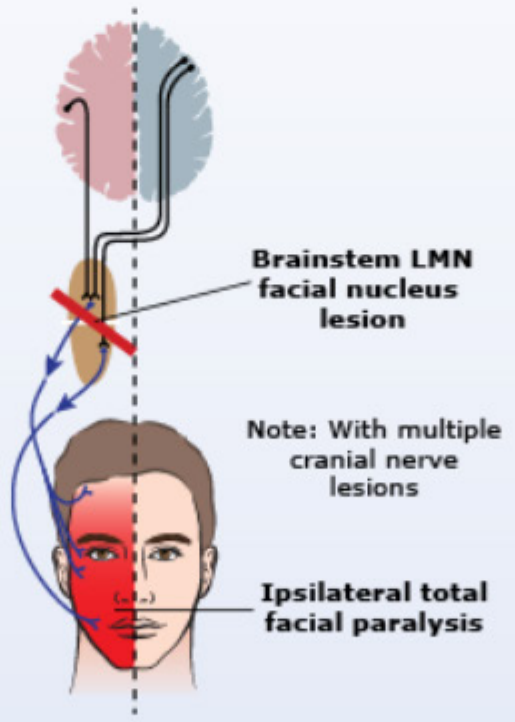

▲ **Figure 17–8.1C**
Nuclear Lesion

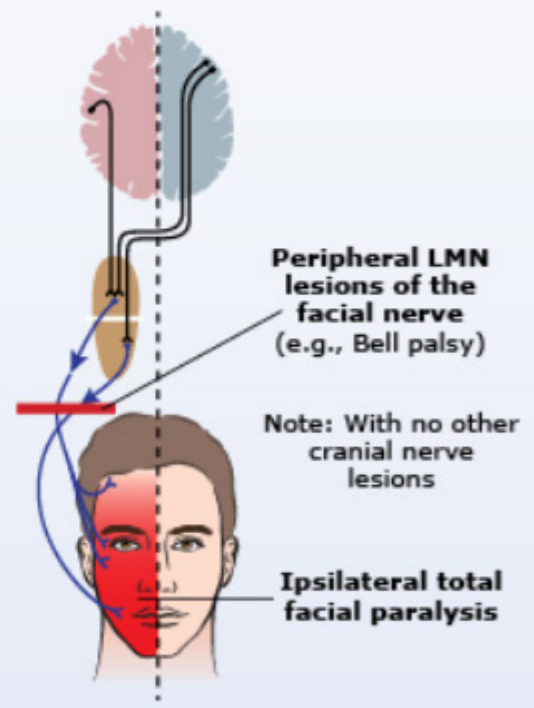

▲ **Figure 17–8.1D**
Peripheral Lesion

Please visit us at www.Groupinsiders.com

© DeVry/Becker Educational Development Corp. All rights reserved.

9 Auditory and Vestibular Systems: CN VIII

9.1 Auditory System

Auditory functions depend on the structure and physiology of the ear, which consists of three parts: *external, middle, and inner ear* (Figure 17–9.1A). The external and middle ear are air filled and the inner ear is fluid filled:

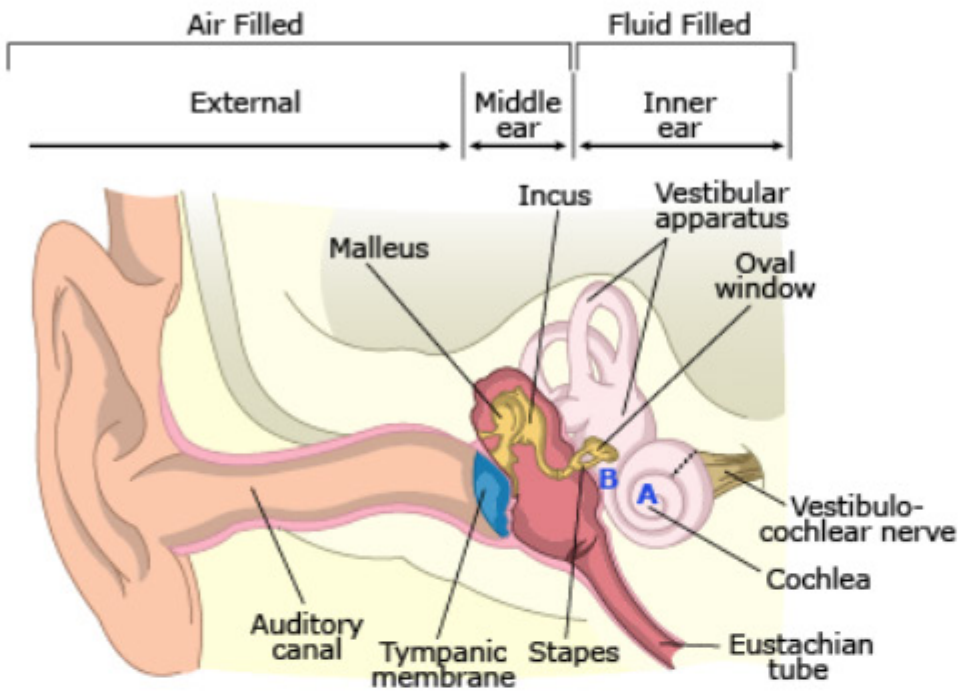

▲ **Figure 17–9.1A** Organization of Ear

- *The external ear* includes the pinna, external acoustic meatus, and the tympanic membrane. The auricle and external acoustic meatus collect the sound vibrations and direct the waves to the tympanic membrane. The tympanic membrane is set in vibration by the sound waves, and the movement of the tympanic membrane results in movement of the ossicles in the middle ear.
- *The middle ear or tympanic cavity* is the air-filled space located in the petrous part of the temporal bone. The tympanic cavity contains three small, bony ossicles (malleus, incus, and stapes) and two small, skeletal muscles. The ossicles articulate with each other by true, although minute, synovial joints. The malleus is attached to the medial surface of the tympanic membrane and articulates with the incus, which articulates with the stapes.
  - The foot plate of the stapes sits in the *oval window* located on the medial wall of the middle ear and is the entrance to the inner ear. The sound vibrations produced by the tympanic membrane are amplified (about 21 times) through the ossicles to the oval window. Sound transmission also can be conducted to the internal ear through the temporal bone (bone conduction), which normally is not as effective as air conduction. The middle ear is connected via the eustachian tube to the nasopharynx.

Clinical Application

Hyperacusis

A lesion of the facial nerve with loss of the stapedius results in hyperacusis, which is abnormal sensitivity to loud sounds.

Clinical Application

Conductive Hearing Loss

Conductive hearing loss is a defect in the transmission of sounds in either the external or middle ear. Conduction deafness results from obstruction by wax or a foreign structure in the external ear, middle ear infections, or, more seriously, from sclerosis of the ossicles (otosclerosis).

Clinical Application

Bone conduction through the cranial bones is still present and is better than air conduction.

Please visit us at www.Groupinsiders.com

© DeVry/Becker Educational Development Corp. All rights reserved.

- The two muscles in the middle ear are the (1) *tensor tympani muscle*, innervated by CN V and attached to the malleus, and the (2) *stapedius muscle*, innervated by CN VII and attached to the stapes. Both of these muscles are protective of the inner ear by dampening and decreasing sound intensity through the middle ear.

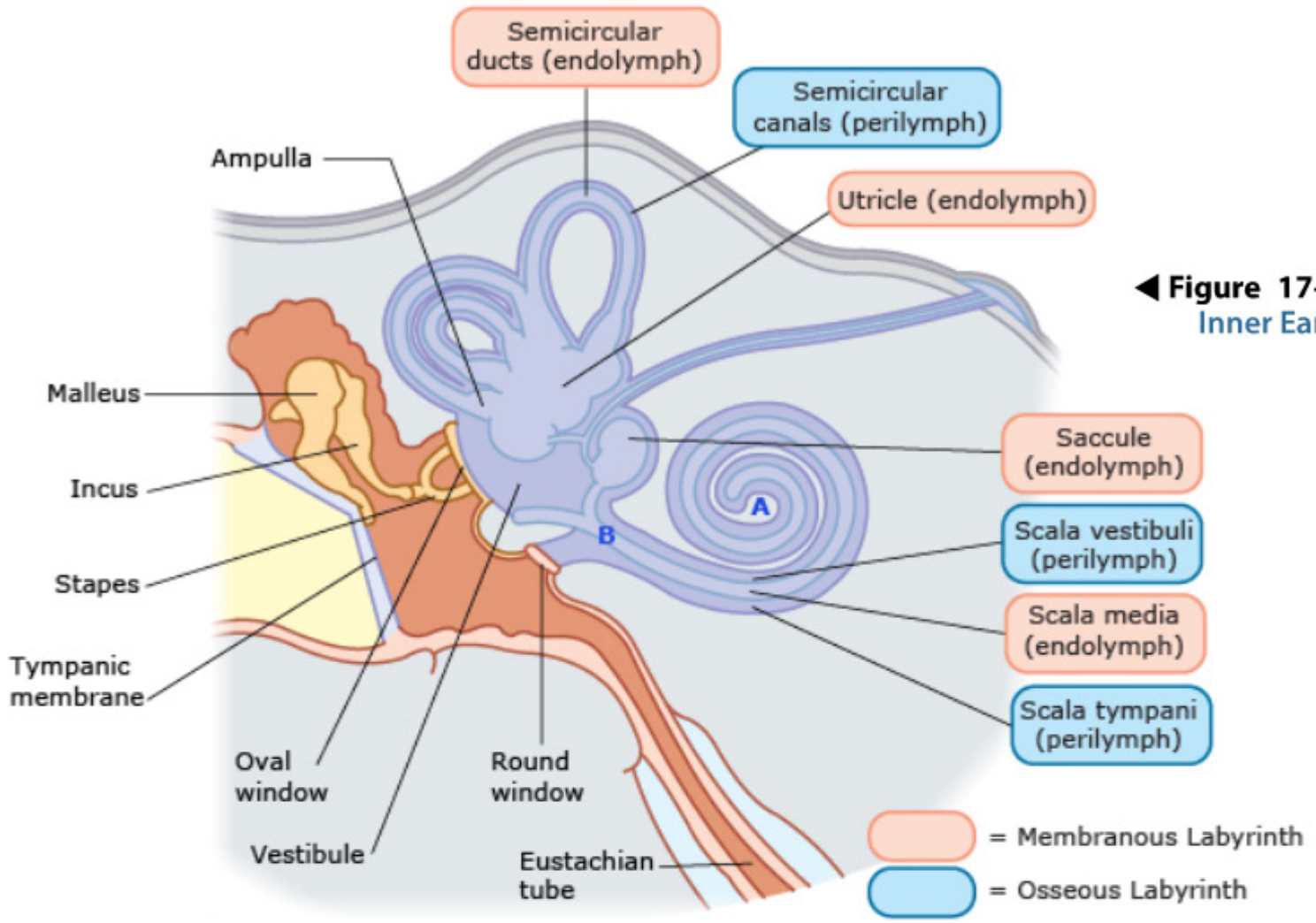

◀ **Figure 17–9.1B**
Inner Ear

- The *inner ear* is the space located deeper in the petrous part of the temporal bone and is composed of two fluid-filled spaces or labyrinths (Figure 17–9.1B): the *bony (osseous) labyrinth* and *membranous labyrinth*. The fluid medium of the bony labyrinth is *perilymph* and the fluid in the membranous labyrinth is called *endolymph*. The membranous labyrinth contains the receptors for processing auditory and vestibular functions of CN VIII.
  - The *bony labyrinth* is a complex series of bony spaces and canal that consists of the *semicircular canals* of the vestibular apparatus and the *scala vestibuli* and *scala tympani* of the cochlear.
  - The *membranous labyrinth* contains *endolymph* and consists of the *semicircular ducts, utricle and saccule* of the vestibular system, and the *scala media (cochlear duct)* of the cochlea. The endolymph is unique because although it is extracellular fluid, it has the inorganic composition of intracellular fluid (high K+ and low Na+), which is necessary for receptor function.
  - There are two openings, or windows, located between the middle and inner ear on the medial wall of the middle ear: the *oval window* (filled in by the stapes) and the *round window* (closed by a movable membrane). The movement of the stapes at the oval window initiates movement of the fluid components of the inner ear, which stimulates the receptors of the CN VIII.

Please visit us at www.Groupinsiders.com

© DeVry/Becker Educational Development Corp. All rights reserved.

9.1.1 Cochlea

- The *cochlea* is the snail-shaped tube located anteriorly in the petrous temporal bone and contains three fluid-filled spaces involved in auditory function:

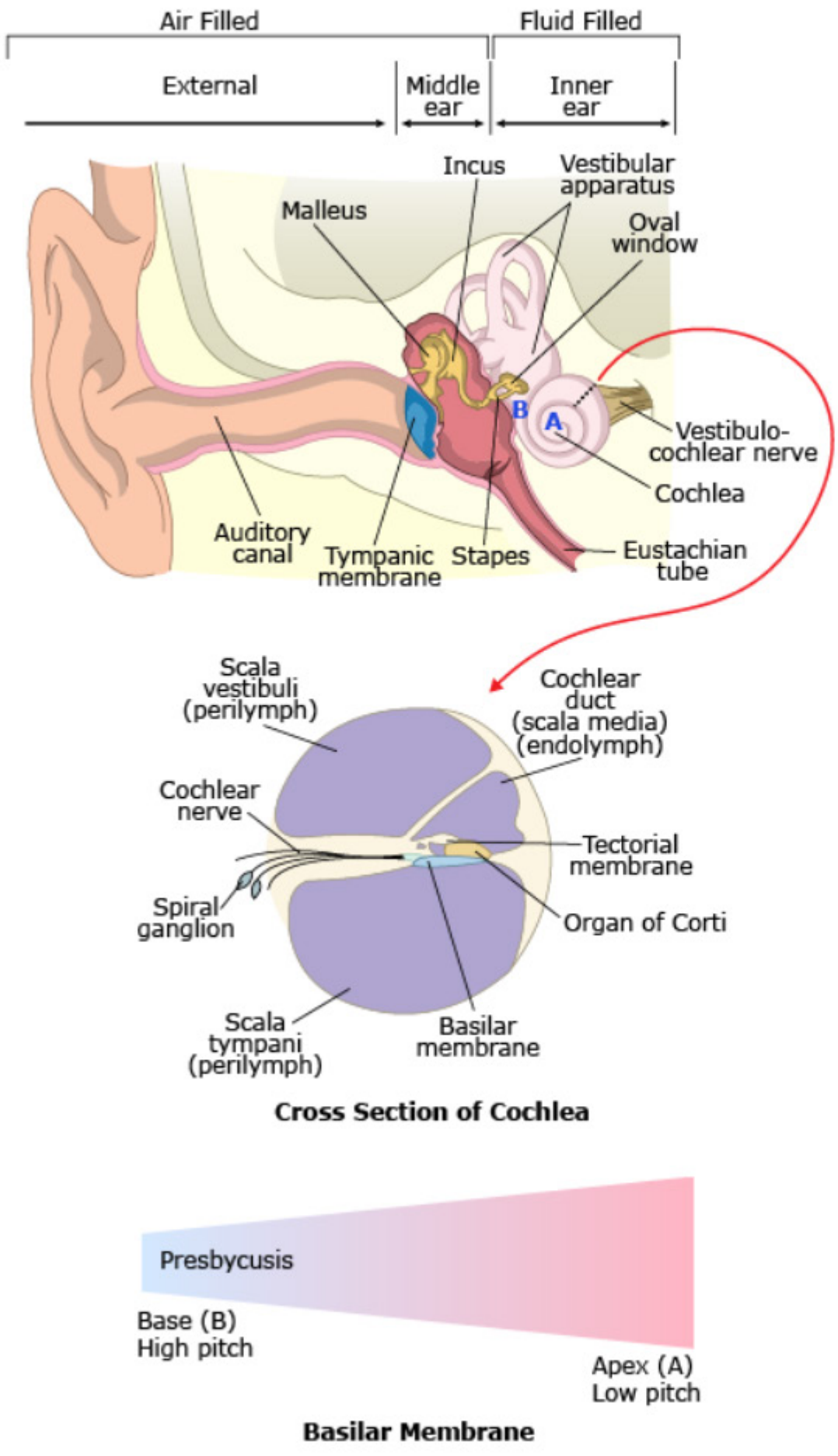

▲ **Figure 17–9.1C** Organization of Cochlea

Please visit us at www.Groupinsiders.com

© DeVry/Becker Educational Development Corp. All rights reserved.

- The *scala vestibuli* and *scala tympani* contain perilymph and are part of the bony labyrinth.
- The *scala media* or cochlear duct is part of the membranous labyrinth and is interposed between scalae vestibuli and tympani.
- The scala media contains endolymph and the auditory receptor, the *organ of Corti.*
- The receptor contains inner and outer hair cells with sterocilia and rests on the *basilar membrane* that separates the scala media and the scala tympani.
- The basilar membrane is narrow at the base and widens as it reaches the apex of the cochlea. Thus, hair cells at the base detect high-pitch sounds and hair cells at the apex detect low-pitch sounds.

- When perilymph moves in the scala tympani, the basilar membrane is put into motion that stimulates the hair cells in the organ of Corti and results in changes in membrane potentials and the firing of the peripheral fibers of the bipolar cells of the spiral ganglion. The mechanical energy produced by the vibration of the basilar membrane is converted to electrical signals at the organ of Corti.

9.1.2 Auditory Pathways

The *spiral ganglion* is the sensory ganglion (contains bipolar neurons) of the cochlear division of CN VIII located in the bony cochlea. The central fibers of the bipolar cells travel in CN VIII and enter the lateral aspect of the brainstem at the pontomedullary junction.

- These fibers synapse on the second-order neurons in the *cochlear nuclei* in the lateral lower pons.
- The axons of the auditory pathway ascend the lateral aspect of the brainstem from the cochlear nucleus first to the *superior olivary nuclei (a sound directional center in the pons)* and then through the *lateral lemniscus* to the *inferior colliculus* of the tectum on the dorsal midbrain.
- From the tectum, the fibers project to the *medial geniculate body* of the thalamus, which then projects through the internal capsule to the *auditory cortex* in the upper gyrus of the temporal lobe (Brodmann areas 41, 42).
- In the mid pons, the *trapezoid body* is the decussating site for sound transmission between both sides of the brainstem, resulting in *bilateral sound input* to the auditory cortex from each ear.

Please visit us at www.Groupinsiders.com

© DeVry/Becker Educational Development Corp. All rights reserved.

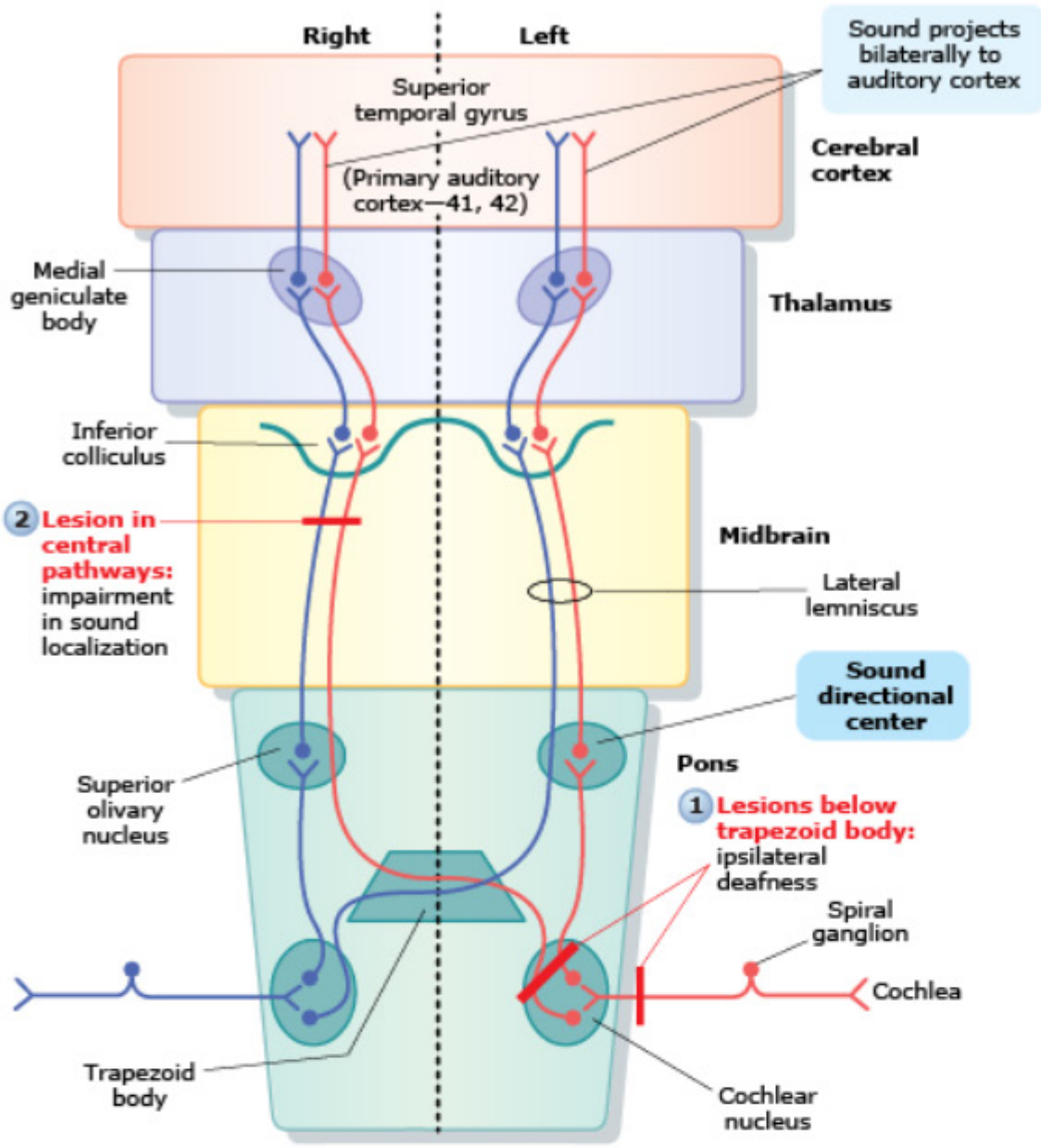

▲ **Figure 17–9.1D** Auditory Pathways

Important Concept

Each ear projects sound bilaterally to each auditory cortex.

Clinical Application

Lesions:

1. Lesions below trapezoid body result in unilateral hearing loss (cochlea, CN VIII, or cochlear nucleus).
2. Lesions above trapezoid body result in bilateral reduction of hearing and significant decrease in ability to determine sound direction.

Please visit us at www.Groupinsiders.com

© DeVry/Becker Educational Development Corp. All rights reserved.

Clinical Application

Sensorineural Hearing Loss

Sensorineural hearing loss results from pathologies involving the cochlea in the temporal bone, CN VIII, or any of the central pathways in the CNS (see Figure 17–9.1C). Drugs, rubella infections, and loud noises all contribute to sensorineural hearing deafness. Air conduction is greater than bone conduction with sensorineural hearing loss.

- Lesions below the trapezoid body in the mid pons involving the cochlea, CN VIII, or the cochlear nucleus will produce *ipsilateral deafness*. Tinnitus is common with cochlear disorders.
- Lesions in the central auditory pathways on either side above the trapezoid body including the cortex, will produce minimal bilateral reduction of hearing but substantial impairment of the ability to localize sound direction.
- In sensorineural hearing loss air conduction is greater than bone conduction.

Clinical Application

Acoustic Neuroma

An acoustic neuroma is a peripheral lesion of CN VIII resulting from a benign Schwann cell tumor (schwannoma) of the eighth nerve at the cerebellopontine angle. Initially, there is progressive hearing loss and disequlibrium. As the tumor spreads at the pontocerebellar angle and the internal acoustic meatus, the facial nerve (VII) may be damaged, with facial muscle weakness, and later CN V may be involved with sensory deficits on the face. Notice that an acoustic neuroma is a peripheral lesion of the cranial nerves and not a central lesion as indicated by the absence of any long track signs.

Prebycusis

Prebycusis is the loss of hair cells at the base of the basilar membrane resulting in the loss of the ability to hear high-pitch sound. This is the most common type of hearing loss.

Please visit us at www.Groupinsiders.com

© DeVry/Becker Educational Development Corp. All rights reserved.

9.2 Vestibular System

The vestibular system has two important functions:

1. Mechanisms for maintaining posture, balance, and equilibrium; and
2. Coordination of head and eye movements that allows visual fixation on an object while the head is turning (vestibulo-ocular reflex).

These functions are provided by a series of structures of the vestibular apparatus within the inner ear and a series of nuclei and fiber projections within the brainstem and spinal cord. There are also major connections with the cerebellum (flocculonodular lobe) that also have a role to play in balance and the control of eye movements.

9.2.1 Vestibular Receptors

The receptors (see Figure 17–9.1B) for vestibular functions are found within the membranous labyrinth of the inner ear: *utricle*, *saccule*, and *semicircular ducts*.

- The receptors of the utricle and saccule are located in an area called the macula. The hair cells and sterocilia of these two sacs are displaced by the movement of endolymph and detect linear acceleration and the pull of gravity.
- The receptor area of the semicircular ducts is in the ampulla. Deflection of these hair cells and sterocilia by endolymph mediates the sense of *angular or circular (spinning) movements* of the head or body. There are three semicircular canals in the temporal bone that are oriented in the three planes of space:
  1. Anterior
  2. Posterior
  3. Horizontal

9.2.2 Vestibular Pathways

The primary afferent neurons are bipolar cells located in the vestibular ganglion within the temporal bone. The central processes of the bipolar cells travel through CN VIII to the lateral aspect of the brainstem at the pontomedullary junction and terminate in the vestibular nuclei in the lateral upper medulla and caudal pons:

- The connections to the vestibular nuclei from the utricle and saccule are mainly concerned with maintenance of posture and balance via connections in the spinal cord (vestibulospinal tract).
- The connections to the vestibular nuclei from the semicircular ducts are primarily concerned with coordination of eye and head movements via connections with motor nuclei of eye muscles in the brainstem.
- Some of the central processes of the primary afferent neurons project directly to the flocculonodular lobe of the cerebellum.

Please visit us at www.Groupinsiders.com

© DeVry/Becker Educational Development Corp. All rights reserved.

9.2.3 Posture and Balance: Vestibulospinal Tracts

The *lateral vestibulospinal tract* (Figure 17–9.2) is a descending long tract of the spinal cord with upper motor neurons located in the vestibular nuclei. Central afferents from the utricle and saccule carry information about linear movement of the body and project to the vestibular nuclei. The tract descends uncrossed through the brainstem and spinal cord, where it terminates on the lower motor neurons of antigravity muscles in the ventral horns of the ipsilateral spinal cord. This tract primarily facilitates extensor muscle tone and inhibits flexor muscles to maintain upright posture. The *medial vestibulospinal tract* terminates mostly in the ventral horn of the cervical cord and plays a role in maintaining head position.

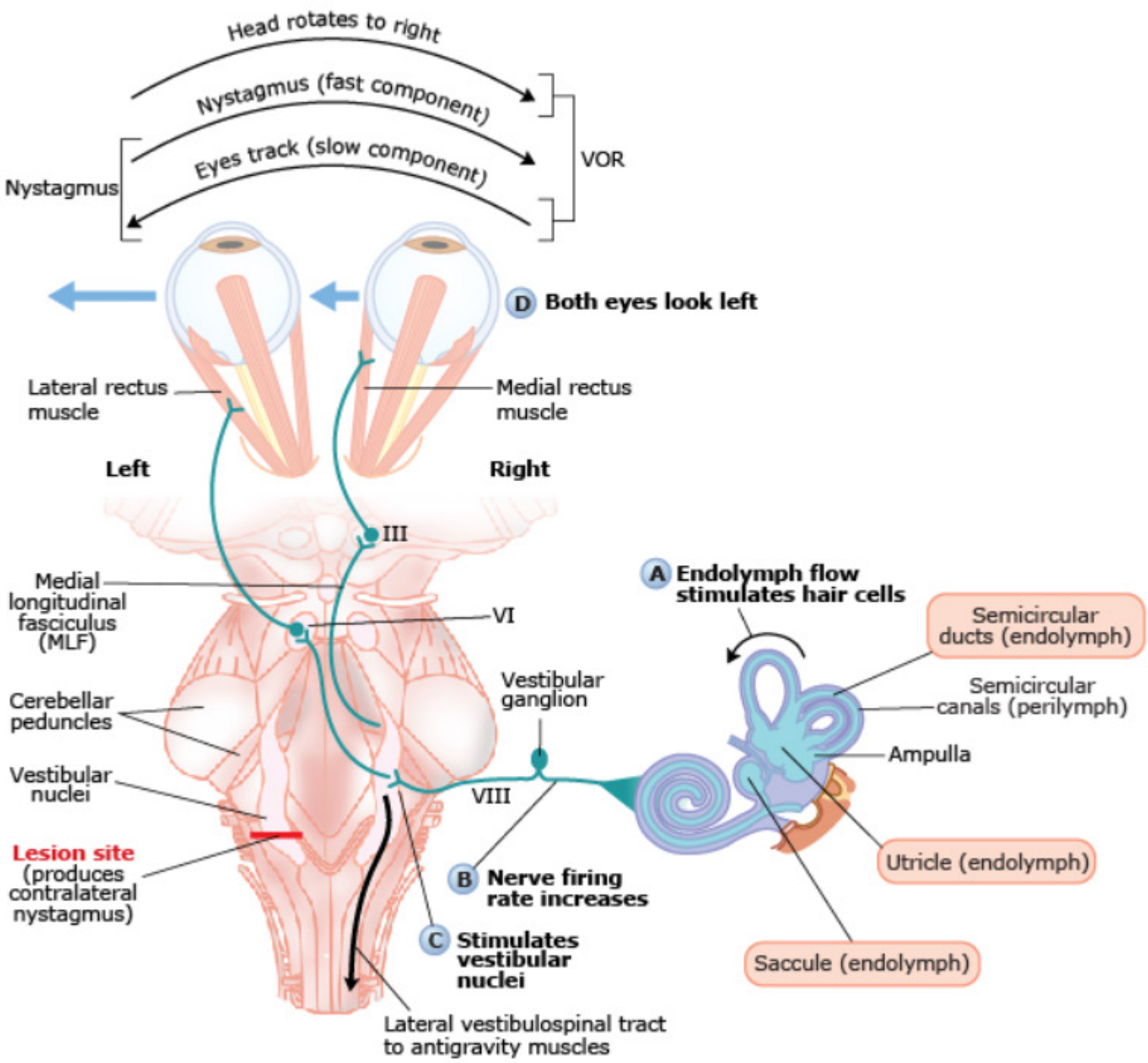

▲ **Figure 17–9.2** Vestibular Pathway

Please visit us at www.Groupinsiders.com

© DeVry/Becker Educational Development Corp. All rights reserved.

9.2.4 Coordination of Head and Eye Movement: Vestibulo-Ocular Reflex

One of the important functions of the vestibular system is to produce conjugate eye movements in response to head turning. The *vestibulo-ocular reflex (VOR)* (Figure 17–9.2) allows the eyes to keep a fixed gaze on an object as the head turns right and left. For example, when the head turns to the right, both eyes will move in the opposite left direction using the vestibulo-ocular circuits in order to keep a fixed gaze on an object. This is a very rapid reflex and can be tested in either a conscious or unconscious individual (doll's eye movement in the unconscious patient).

- The *sensory limb* of the VOR is formed by the primary afferent fibers of the vestibular division of CN VIII. These fibers arise from the sensory receptors of the semicircular ducts that mediate angular movements of the head. In the direction of head turning, the hair cells of the semicircular ducts on that side will respond and project into the brainstem vestibular nuclei via CN VIII. Axon projections from the vestibular nuclei then ascend the ipsilateral midline of the brainstem via the MLF to the ipsilateral oculomotor nucleus (medial rectus) and across the midline to the contralateral abducens nucleus (lateral rectus). The MLF tracts interconnect the oculomotor and abducens nuclei.
- The *motor side* of the reflex is formed by the neurons in the motor nuclei of CN III and CN VI to the medial rectus and the lateral rectus muscles, respectively. The oculomotor nerve will result in adduction of the ipsilateral eye (medial rectus) and the abducens nerve will result in abduction of the contralateral eye (lateral rectus). Thus, the eyes will be turning in the opposite direction of head turning.

Clinical Application

Pathological Nystagmus

Lateral brainstem lesions at the pontomedullary junction with damage to the vestibular nuclei can produce horizontal pathological vestibular nystagmus. Nystagmus is the involuntary dancing or rhythmic movements of the eyes that consist of two components:

1. A *slow phase*, in which the eyes drift to the side of the brainstem lesion.
2. A *fast phase*, in which the eyes rapidly jerk away from the side of the brainstem lesion. The direction of nystagmus is named for the direction of the fast component.
   - The slow movement is in response to the brainstem lesion of the vestibular nuclei, and the fast phase is a corrective eye movement produced by the frontal eye fields of the cortex to reverse the slow drift of the eyes. For example, with a right vestibular nuclear brainstem lesion, the eyes would drift slowly to the right (due to the brainstem lesion) followed by a rapid movement of the eyes to the left (cortical correction), thus, a left nystagmus.

Please visit us at www.Groupinsiders.com

© DeVry/Becker Educational Development Corp. All rights reserved.

9.2.5 Caloric Test: COWS

The *caloric test* can be used to test for disorders of the vestibulo-ocular circuits. With the patient's head tilted, either warm or cold water is irrigated into the external auditory meatus. The hot or cold water will introduce movement of the endolymph in opposite directions. In an individual with an intact brainstem, cold water will produce nystagmus (fast phase) to the opposite direction from the side where water was introduced, and warm water will produce nystagmus in the same direction that water was introduced—thus, *cold opposite, warm same (COWS)*.

9.2.6 Vertigo

Vertigo is the illusion or perception of a whirling or spinning motion in the absence of actual rotation and is usually accompanied by nausea and vomiting. Vertigo can be caused by a peripheral lesion in the membranous labyrinth (more severe) or a central lesion of the brainstem affecting the vestibular nuclei and pathways (less severe). Peripheral vertigo is usually intermittent, lasting shorter periods.

9.2.7 Ménière Disease

Ménière disease is intermittent, episodic attacks of vertigo that vary in severity and duration. The cause of the disorder is unknown and may be caused by excess accumulation of endolymph in the membranous labyrinth. In addition, there may be nausea, vomiting, hearing loss, and tinnitus (ringing noise in the ear).

Please visit us at www.Groupinsiders.com

© DeVry/Becker Educational Development Corp. All rights reserved.

10 Voluntary Horizontal Gaze

The eyes move in conjugate, parallel gaze, ensuring that the image will project to the same spot of each retina and prevent diplopia (double vision).

- In horizontal, voluntary gaze, the two eyes demonstrate conjugate movement to the right or left (Figure 17–10.0A). The two muscles used in horizontal gaze are the lateral rectus (CN VI) for abduction of the eye and the medial rectus (CN III) responsible for adduction of the eye. For example, to look to the left with both eyes, the left eye has to abduct using the lateral rectus muscle (CN VI) and the right eye has to adduct using the medial rectus muscle (CN III). Then to look to the right, these two innervations are reversed.

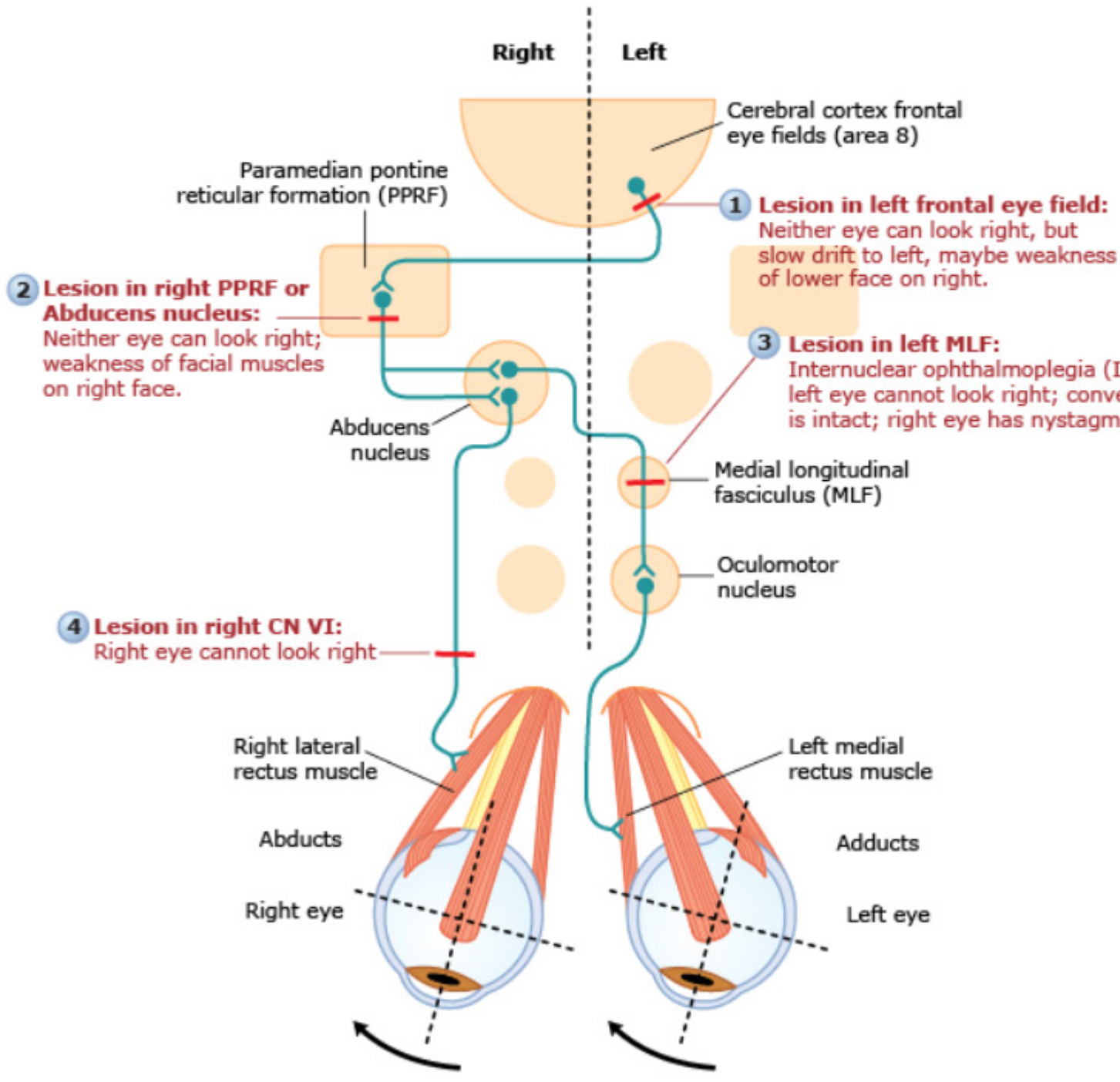

▲ **Figure 17–10.0A** Voluntary Horizontal Gaze Circuit

Please visit us at www.Groupinsiders.com

© DeVry/Becker Educational Development Corp. All rights reserved.

- The oculomotor nucleus is located in the medial midbrain and the abducens nucleus is located in the medial lower pons. These two nuclei are interconnected by the MLF, which is utilized for part of this pathway. The circuitry for horizontal gaze is shown in Figure 17–10.0A. There are two motor control gaze centers for horizontal movements of the eyes:
  1. The cortical control centers are the *frontal eye fields* (area 8), located in each of the frontal lobes anterior to areas 4 and 6. Stimulation of the frontal eye fields produces *contralateral gaze* of the eyes. The axons of the frontal eye fields project through the internal capsule into the brainstem, where they decussate to the contralateral *paramedian pontine reticular formation (PPRF)* of the pons.
  2. The *PPRF* of the pons is the brainstem control center for *ipsilateral horizontal gaze*.
- Short interneurons from the PPRF project to the *abducens nucleus* that is embedded in the PPRF in the medial lower pons. The lower motor neurons in the abducens nucleus project to the ipsilateral lateral rectus to cause abduction.
- Another set of neurons in the abducens nucleus sends interneurons that immediately cross the midline and ascend in the contralateral MLF to the *oculomotor nucleus* on the opposite side of the medial midbrain, which results in adduction of the contralateral eye. Therefore, activation of the left frontal eye fields will result in conjugate movement of both eyes to the right. Note that the MLF is utilized in horizontal gaze and in the vestibulo-ocular reflex circuitry.
- The classic lesion sites are listed in Table 17–10.0 and illustrated in Figure 17–10.0B.

▼ Table 17–10.0 Clinical Correlate

Lesion Examples	Symptoms
1. Left front eye field	Neither eye can look right, but slow drift to left.
2. Right PPRF or abducens nucleus	Neither eye can look right.
3. Left MLF	*Internuclear opthalmoplegia (INO)* Left eye cannot look right; convergence is intact (this is how to distinguish an INO from an oculomotor lesion); right eye has nystagmus; seen in multiple sclerosis.
4. Right CN VI	Right eye cannot look right.

Abbreviations: MLF, medial longitudinal fasciculus; PPRF, paramedian pontine reticular formation

▲ Figure 17–10.0B Abnormal Horizontal Gaze

Please visit us at www.Groupinsiders.com

© DeVry/Becker Educational Development Corp. All rights reserved.

11 Blood Supply to Brainstem

Many lesions and syndromes involving the brainstem result from some type of vascular insufficiency and stroke. Thus, it is important to understand the blood supply to the brainstem and its relationship to brainstem lesions. Blood supply to the brainstem arises from two arteries that form the posterior circulation (Figure 17–11.0) within the cranial cavity: *vertebral artery* and *basilar artery*.

Important Concept

Blood supply to Brain Stem

Vertebral Artery:

- Anterior spinal (ASA)
- Posterior inferior cerebellar (PICA)

Basilar Artery:

- Anterior inferior cerebellar (AICA)
- Paramedian branches
- Superior cerebellar
- Posterior cerebral

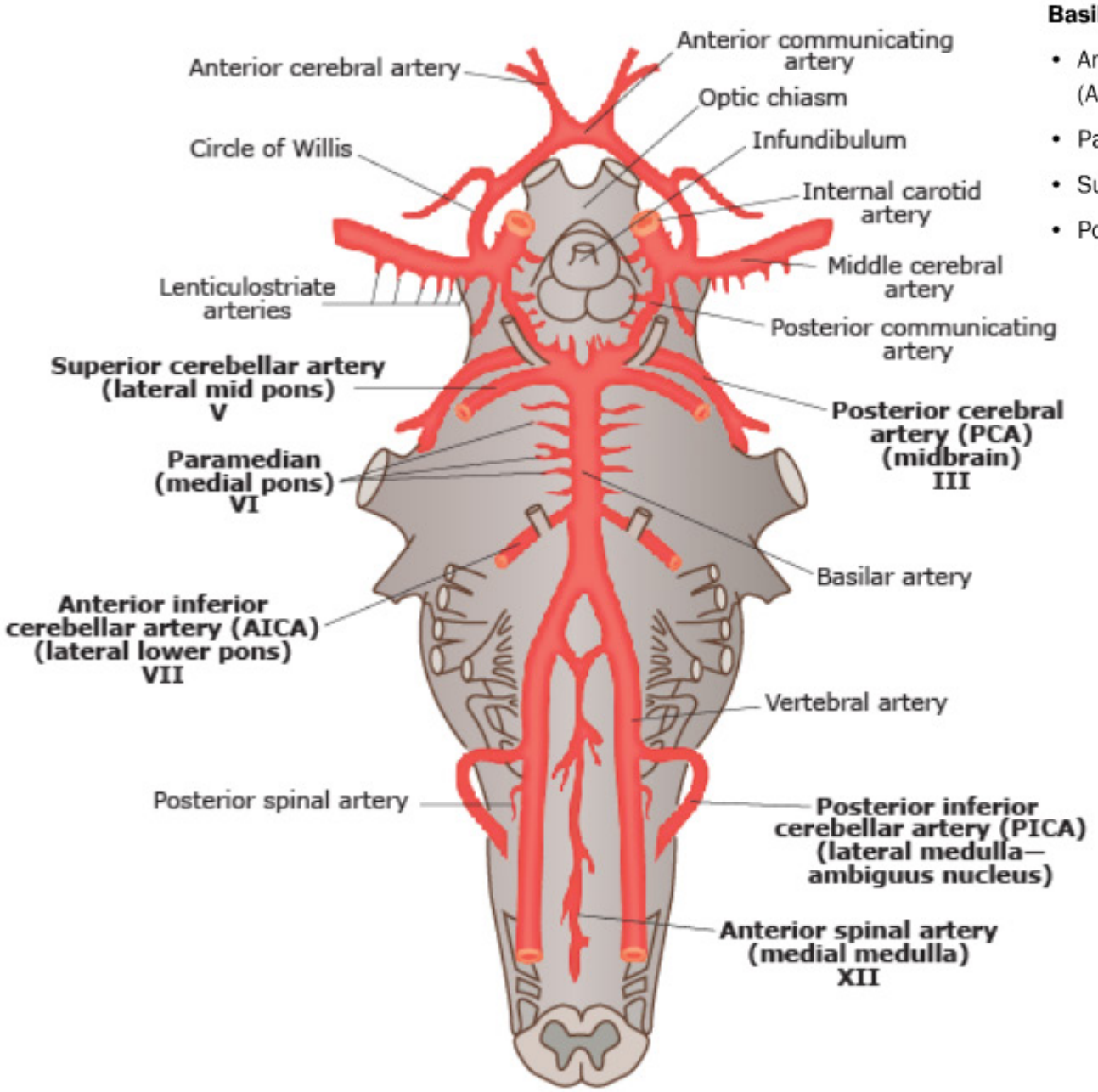

▲ **Figure 17–11.0** Blood Supply to Brainstem

Please visit us at www.Groupinsiders.com

© DeVry/Becker Educational Development Corp. All rights reserved.

11.1 Vertebral Artery

The paired vertebral arteries arise from the subclavian arteries on both sides of the root of the neck. The vertebral arteries ascend the neck in the transverse foramina of the cervical vertebra and enter the cranial fossa through the foramen magnum. The two vertebral arteries then course superiorly on the ventral surface of the medulla and fuse to form the basilar artery at the pontomedullary junction. The vertebral artery provides two branches that supply parts of the brainstem:

1. The *anterior spinal artery* (ASA) is formed by contributions of both vertebral arteries on the ventral surface of the medulla. The ASA descends on the ventral midline of the medulla and supplies the *ventromedial parts of the medulla*.
2. The *posterior inferior cerebellar arteries* (PICA) are paired vessels that arise from each of the vertebral arteries and supply the dorsolateral zone of the upper *medulla* and the cerebellum.

11.2 Basilar Artery

The *basilar artery* is formed by the fusion of the two vertebral arteries at the pontomedullary junction. The basilar artery courses on the ventral midline surface of the basilar pons and divides into the right and left posterior cerebral arteries at the junction of the pons and midbrain. The basilar artery provides the following branches:

- The *anterior inferior cerebellar arteries* (AICA) are paired vessels that arise from both sides of the initial segment of the basilar artery. The AICA supplies the *lateral lower pons* and the inferior surface of the cerebellum.
- The *paramedian arteries* are three or four paired branches of the basilar artery that penetrate into and supply the *medial pons*.
- The *superior cerebellar arteries* are paired branches of the upper segment of the basilar artery and supply the *lateral aspect of the mid and rostral pons*.
- The right and left *posterior cerebral arteries* (PCAs) are formed by the bifurcation of the basilar artery. The PCAs provide several branches that supply the entire *midbrain* and contribute to the circle of Willis.

Important Concept

Lesions and syndromes of the brainstem often result from vascular strokes and interruption of the posterior circulation of the vertebrobasilar system. Brainstem lesions will involve damage to one or more cranial nerves. As has been described, deficits of the motor nucleus of CN III localize a lesion to the medial midbrain; deficits of the motor nucleus of V localize a lesion to the lateral mid/rostral pons; deficits of the motor nucleus of VI localize a lesion to the medial lower pons; and deficits of CN VII localize to the lateral lower pons. The loss of the motor nucleus of XII will localize the lesion to the medial upper medulla and deficits of the nucleus ambiguus (CN IX and X) will localize the lesion to the lateral upper medulla. In general, sensory deficits occur more commonly in lateral brainstem lesions.

11.3 Model of Brainstem Lesion

The hallmark of brainstem lesions is that there is a combination of cranial nerve sign(s) and long tract signs described as *crossed or alternating signs* (Figure 17–11.3). Central cranial nerve lesions in the brainstem produce *ipsilateral signs* on the face and head, and long tract lesions at most levels of the brainstem produce *contralateral signs* below on the trunk and limbs, except for descending hypothalamic fibers, which will produce *ipsilateral Horner syndrome* on the face.

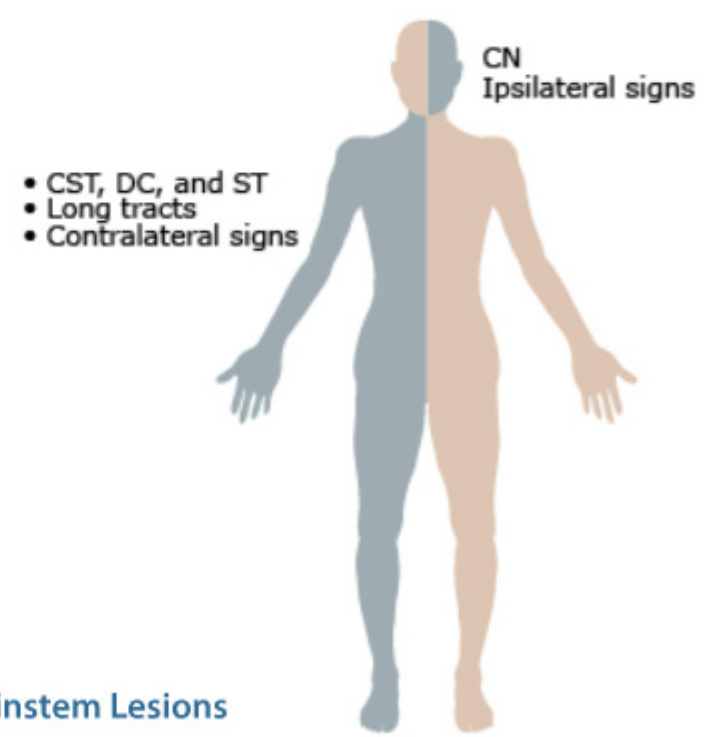

▶ **Figure 17–11.3** Model of Brainstem Lesions

Please visit us at www.Groupinsiders.com

© DeVry/Becker Educational Development Corp. All rights reserved.

12 Brainstem Syndromes

The more common brainstem syndromes with their deficits and arterial involvement are listed in the following section.

12.1 Medulla Oblongata

12.1.1 Medial Medullary Syndrome

- *Medial medullary syndrome* (Figure 17–12.1A) can result from an occlusion of the branches of the *anterior spinal artery*, usually to one side of the ventromedial zone of the upper medulla. The lesion involves two medial long tracts, the pyramids (corticospinal tract) and medial lemniscus, and one cranial nerve, the central fibers of the hypoglossal nerve.

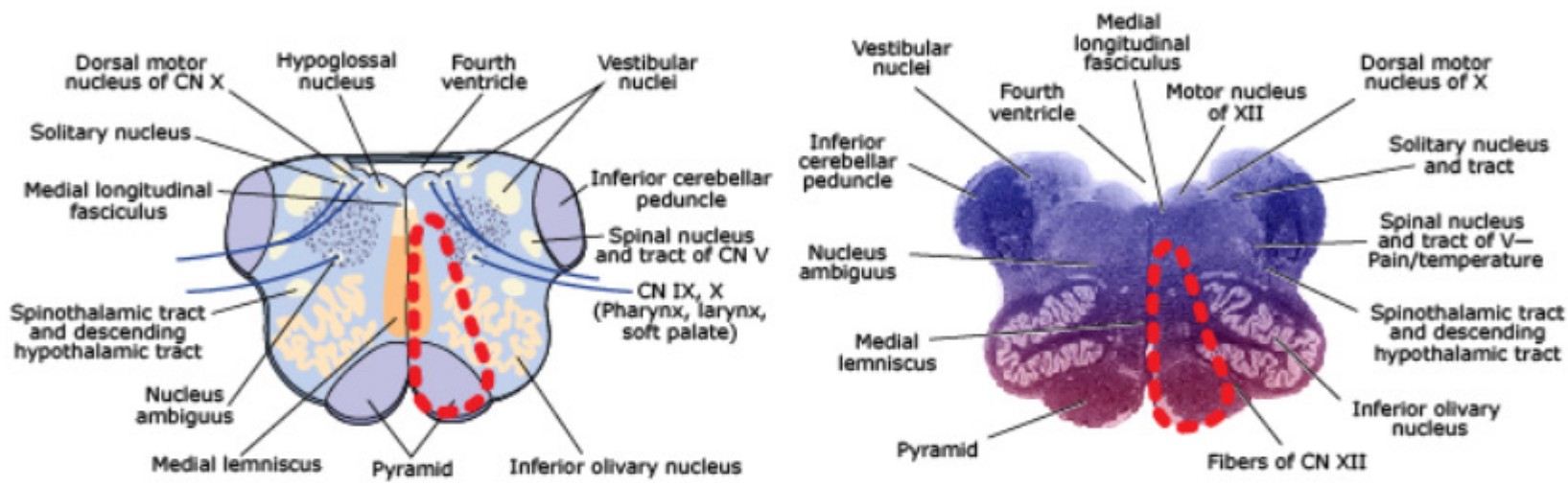

▲ **Figure 17–12.1A** Medial Medullary Syndrome (ASA)

- The neurological signs are:
  - **Medial Lemniscus:** Contralateral loss of dorsal column functions (touch, vibration, conscious proprioception) on the opposite trunk.
  - **Pyramids:** Contralateral spastic paresis of both limbs.
  - **CN XII Fibers:** Ipsilateral paralysis of muscles on one half of the tongue resulting in tongue deviation to the side of the lesion upon protrusion.

Please visit us at www.Groupinsiders.com

© DeVry/Becker Educational Development Corp. All rights reserved.

12.1.2 Lateral Medullary Syndrome (Wallenberg Syndrome)

- *Lateral medullary syndrome* (Figure 17–12.1B) can result from occlusion of the *posterior inferior cerebellar artery* (PICA). This lesion is also known as the Wallenberg syndrome.

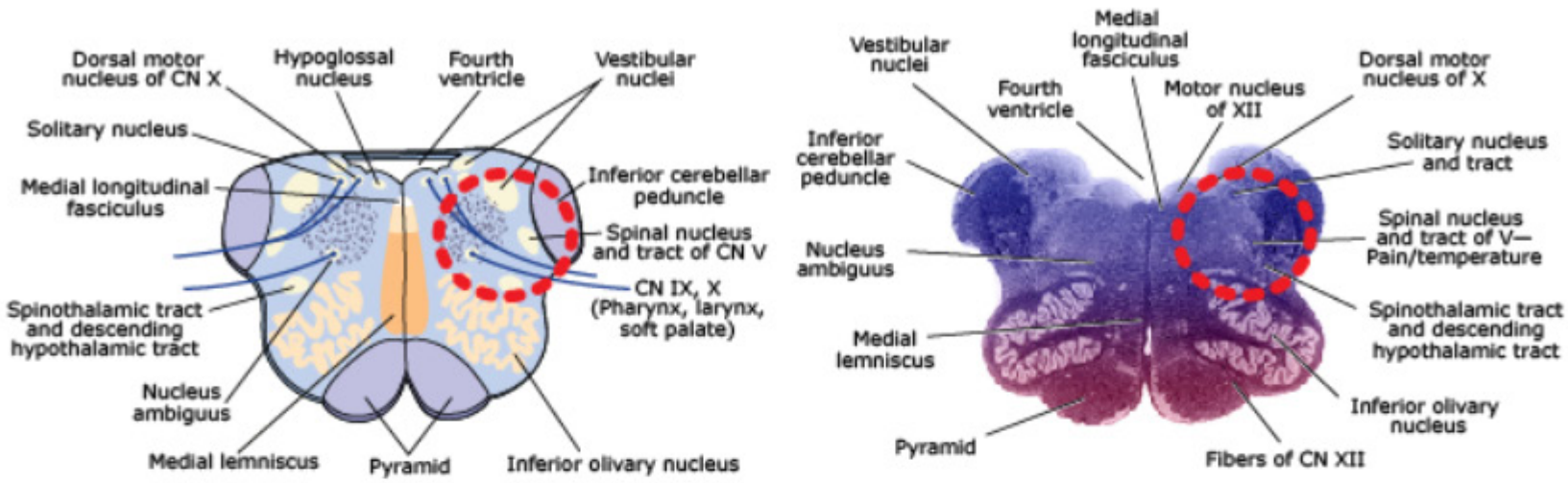

▲ **Figure 17–12.1B** Lateral Medullary Syndrome (PICA)

- The affected structures and neurological signs are:
  - **Inferior Cerebellar Peduncle:** Loss of ipsilateral limb coordination (ataxia).
  - **Vestibular Nuclei:** Nausea, vertigo, and nystagmus (fast component to the side opposite the side of the lesion).
  - **Cochlear Nucleus:** Ipsilateral sensorineural hearing loss.
  - **Spinal Nucleus and Tract of V:** Ipsilateral loss of pain and temperature on the face.
  - **Spinothalamic Tract:** Contralateral loss of pain and temperature on the limbs and trunk.
  - **Descending Hypothalamic Fibers:** Ipsilateral Horner syndrome on face with small pupil (miosis), slight drooping of the eyelid (ptosis), and dry skin (anhidrosis).
  - **Solitary Nucleus:** Loss of taste on ipsilateral side of tongue.
  - **Nucleus Ambiguus:** Affects the lower motor neurons of the CN IX and X resulting in loss of gag reflex; difficulty swallowing (dysphasia); hoarse, rough voice (paralysis of vocal fold); dysarthria; and uvula deviated away from the side of lesion.

Please visit us at www.Groupinsiders.com

© DeVry/Becker Educational Development Corp. All rights reserved.

12.2 Pons

12.2.1 Medial Pontine Syndrome

- The *medial pontine syndrome* (Figure 17–12.2A) can result from occlusion of the *paramedian branches* of the basilar artery to the ventromedial caudal pons. The lesion involves two medial long tracts (corticospinal and medial lemniscus) and one cranial nerve (VI).

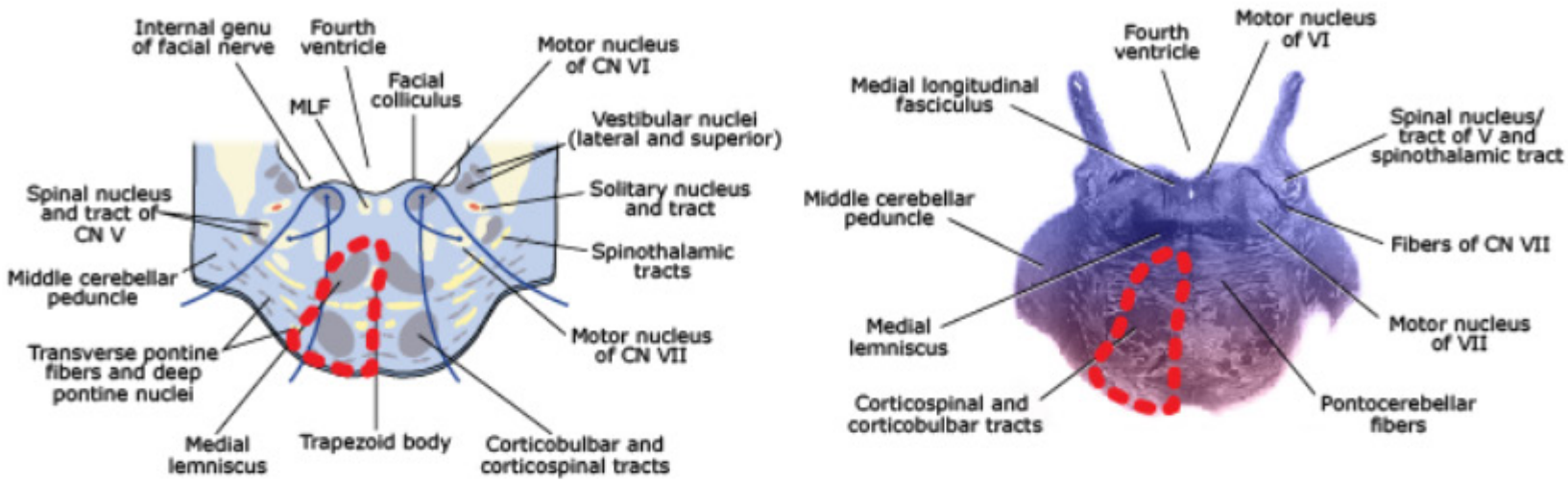

▲ **Figure 17–12.2A** Medial Pontine Syndrome (Paramedian)

- The neurological signs are:
  - **Medial Lemniscus:** Contralateral loss of dorsal column functions on the trunk and limbs (touch, vibration, conscious proprioception).
  - **Pyramids:** Contralateral spastic paresis of both limbs.
  - **CN VI Fibers:** Ipsilateral paralysis of the lateral rectus muscle resulting in medial deviation of the eye (internal strabismus).

Please visit us at www.Groupinsiders.com

© DeVry/Becker Educational Development Corp. All rights reserved.

12.2.2 Lateral Pontine Syndrome

- **Lateral Lower (Caudal) Pons:** The *lateral pontine syndrome of the lower pons* (Figure 17–12.2B) is caused by occlusion of the *anterior inferior cerebellar artery (AICA)*. These neurological deficits will be similar to Wallenberg syndrome with the exception of a different cranial nerve lower motor neuron lesion (VII).

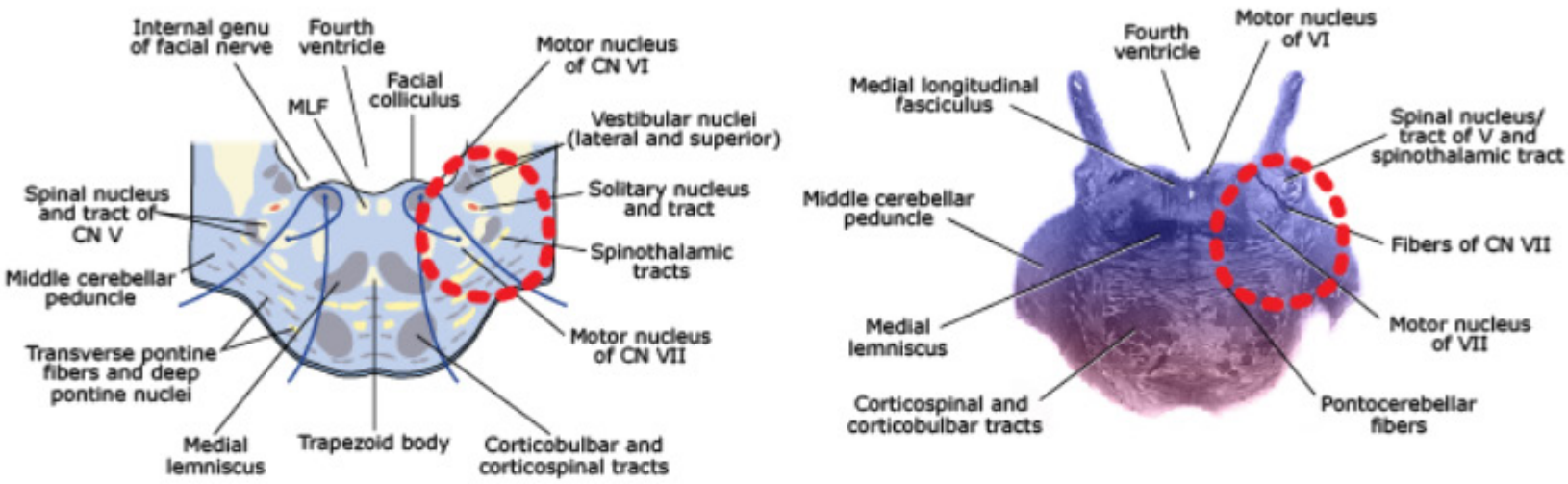

▲ **Figure 17–12.2B** Lateral Pontine Syndrome (Lower) (AICA)

- The affected structures and neurological signs are:
  - **Middle Cerebellar Peduncle:** Loss of ipsilateral limb coordination (ataxia).
  - **Vestibular Nuclei:** Nausea, vertigo, and nystagmus (fast component toward the opposite side of the lesion).
  - **Spinal Nucleus and Tract of V:** Ipsilateral loss of pain and temperature on the face.
  - **Spinothalamic Tract:** Contralateral loss of pain and temperature on the limbs and trunk.
  - **Descending Hypothalamic Fibers:** Ipsilateral Horner syndrome on face with small pupil (miosis), slight drooping of the eyelid (ptosis), and dry skin (anhidrosis).
  - **Facial Nucleus and Fibers:** Affects the lower motor neurons of the CN VII resulting in ipsilateral facial paralysis, ipsilateral loss of taste on anterior two thirds of tongue, hyperacusis, and loss of lacrimation and salivation (dry mouth and dry eye).

Please visit us at www.Groupinsiders.com

© DeVry/Becker Educational Development Corp. All rights reserved.

12.2.3 Lateral Mid Pontine Syndrome

The *lateral pontine syndrome* at the mid/rostral pons (Figure 17–12.2C) is caused by occlusion of the *superior cerebellar artery*. The primary difference between a lateral mid/rostral pontine lesion and a lesion of the lateral lower pons is the involvement of the motor nucleus of V (results in mandible deviated to side of lesion) and the principal sensory nucleus of V (results in epicritic sensory loss on the ipsilateral face).

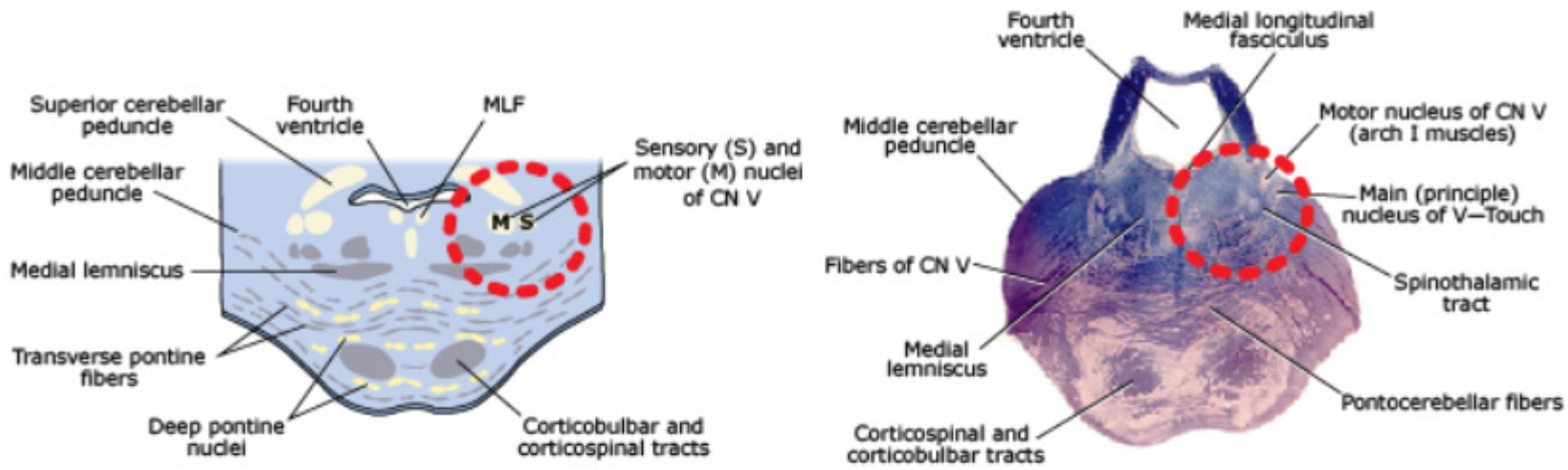

▲ **Figure 17–12.2C** Lateral Pontine Syndrome (Mid Pons) (Superior Cerebellar)

12.2.4 Locked-in Syndrome

The locked-in syndrome is caused by an occlusion of the basilar artery producing a large bilateral infarct in the medial and ventral pons. The infarct involves bilateral lesions of (a) the corticospinal tract resulting in quadriplegic spasticity and (b) the bilateral corticobulbar fibers producing bilateral loss of cranial nerve lower motor neuron nuclei, except for the oculomotor nerve of the midbrain, which is sparred. The lateral sensory functions to the face and body and the arousal system of the pons are not affected. The patient has lost spinal and most cranial nerve motor functions but is awake and aware of the surroundings and can communicate by moving the eyelids and the eyes.

Please visit us at www.Groupinsiders.com

© DeVry/Becker Educational Development Corp. All rights reserved.

12.3 Midbrain

12.3.1 Weber Syndrome

- **Weber syndrome** (Figure 17–12.3) is caused by occlusion of the branches of the posterior cerebral artery that supply the ventromedial area of the midbrain at the level of the superior colliculus. The lesion affects the fibers of CN III and the descending motor fibers of the corticospinal and corticobulbar tracts coursing in the medial half of the cerebral peduncle.

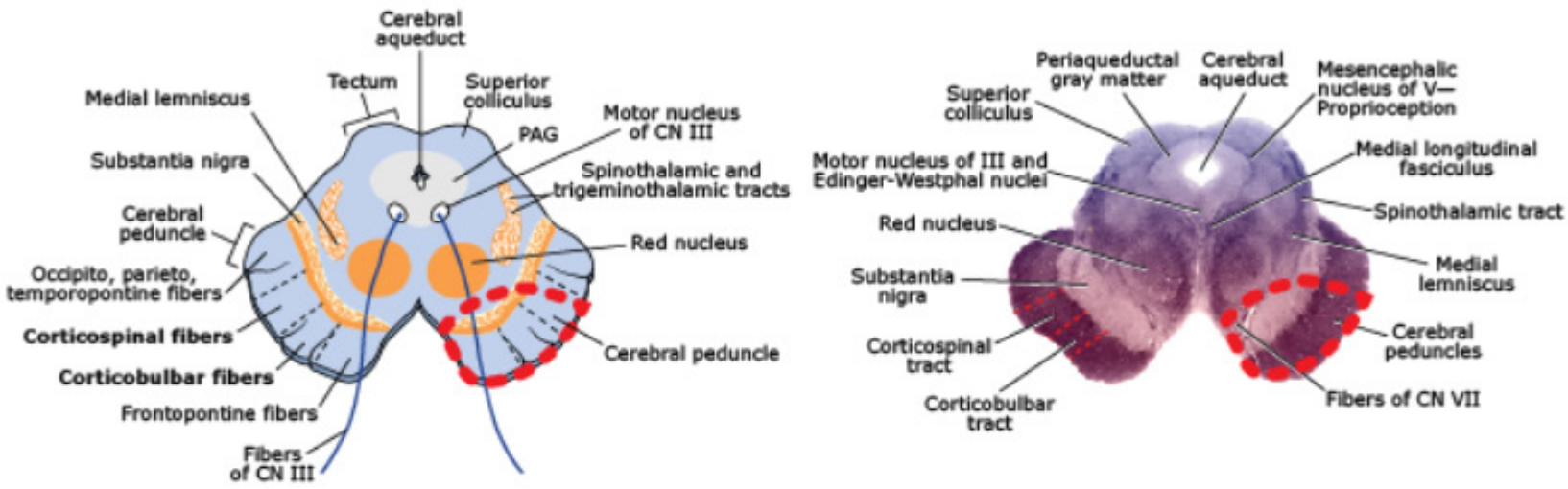

▲ **Figure 17–12.3** Medial Midbrain Syndrome (Weber) (PCA)

- The affected structures and neurological signs are:
  - **Oculomotor Nerve (CN III):** Ipsilateral oculomotor deficits—lateral strabismus; dilated, fixed pupil; sever ptosis.
  - **Corticospinal Tract:** Contralateral limb spasticity.
  - **Corticobulbar Tract:** Contralateral lower face muscle weakness.

Please visit us at www.Groupinsiders.com

© DeVry/Becker Educational Development Corp. All rights reserved.

Review Questions Chapter 17

1. A 35-year-old-woman loses the sense of touch on her face and experiences weakness in the muscles of mastication. The primary afferent neurons involved in the sensory loss terminate in which of the following?

A. Solitary nucleus
B. Trigeminal ganglion
C. Medial lemniscus
D. Main sensory nucleus of V
E. Nucleus ambiguus

2. A 45-year-old man is admitted to the emergency room after experiencing double vision and trouble moving the muscles of his face. The neurological exam shows that he cannot move his left eye to the left when trying to look to the left and that there is weakness in closing his left eye and the muscles around his mouth on the left. Which of the following is the likely site of lesion?

A. Dorsal medial lower pons
B. Lateral lower medulla
C. Medial ventral midbrain
D. Dorsal lower medulla
E. Medial lower medulla

3. A patient is experiencing a dry mouth and weakness in swallowing. In addition, there is absence of the gag reflex. Which of the following cranial nerves would more likely be damaged?

A. Facial
B. Glossopharyngeal
C. Vagus
D. Trigeminal
E. Vagus and trigeminal

4. A 35-year-old female suffers a vascular stroke to the upper medulla of the brainstem. The neurological exam shows that the woman has lost vibration sensation on the left upper and lower limbs. She also shows hypertonia on the same limbs. Which of the following arteries was involved in the stroke?

A. Posterior inferior cerebellar
B. Anterior spinal
C. Posterior cerebral
D. Anterior inferior cerebellar
E. Superior cerebellar

5. An elderly man complains to his physican about difficulties hearing. The audiology examination finds deafness in one ear. Which of the following structures would be the most likely site of damage?

A. Lateral lemniscus
B. Medial lemniscus
C. Cochlear nucleus
D. Medial geniculate nucleus
E. Auditory cortex of temporal lobe

Please visit us at www.Groupinsiders.com

© DeVry/Becker Educational Development Corp. All rights reserved.

6. When a patient is asked to look laterally to the left, the left eye abducts correctly but the right eye does not adduct. However, both eyes will move medially when a finger is brought to the tip of the patient's nose. This defect in lateral gaze would result from a lesion in which of the following locations?

A. Left abducens nucleus
B. Right paramedian pontine reticular formation
C. Left occulomotor nucleus
D. Right medial longitudinal fasciculus
E. Left paramedian pontine reticular formation

7. Following a vascular occlusion, the patient shows muscle weakness on the lower face on the left, hyperreflexia on the left upper and lower limbs, and external strabismus of the right eye. A lesion in which part of the central nervous system would result in these signs?

A. Dorsomedial upper medulla
B. Lateral lower pons
C. Medial upper medulla
D. Medial lower pons
E. Ventromedial midbrain

8. A 70-year-old man is brought to the emergency room following a vascular stroke of the brainstem. He has lost pain and temperature sensations on right upper and lower limbs and also has lost the same sensations on the left side of his face. There is ataxia of his left limbs, but no paralysis or weakness of the facial muscles on the left. Which of the following conditions also would be expected?

A. Loss of conscious proprioception from the right limbs
B. Ulvula deviated to the right
C. Internal strabismus of the left eye
D. Loss of touch on the left side of the face
E. Loss of touch on the left side of the body

9. In the stroke patient in the above question, damage to which of the following arteries resulted in these neurological signs?

A. Paramedian branches
B. Posterior cerebral
C. Posterior inferior cerebellar
D. Anterior spinal
E. Posterior spinal

10. During a neurological exam of a 23-year-old man, the physician places her finger on the midline of the mandible and taps it with a percussion hammer to stimulate the jaw-jerk reflex. Fibers from which of the following brainstem nuclei enter the trigeminal motor nucleus to initiate the motor response?

A. Hypoglossal
B. Mesencephalic
C. Principal sensory
D. Spinal trigeminal
E. VPM of thalamus

Please visit us at www.Groupinsiders.com

© DeVry/Becker Educational Development Corp. All rights reserved.

Review Answers Chapter 17

1. The correct answer is D. The fibers of the primary afferent neurons that carry touch sensations from the face course through the three divisions of the trigeminal nerve and enter the brainstem through the trunk of CN V. These central fibers terminate in the main (principal) sensory nucleus of V, where they synapse with the secondary neurons that project to the VPM nucleus of the thalamus. The main sensory nucleus of V is in the lateral mid pons.

2. The correct answer is A. The combination of loss of abduction of the left eye with weakness of left facial muscles suggests that the lesion is at the level of the abducens nucleus where the axons of the facial nerve course around the abducens nucleus (internal genu of VII). The abducens nucleus is at the dorsomedial aspect of the lower pons.

3. The correct answer is B. The glossopharyngeal nerve provides parasympathetic innervation to the parotid gland and sensory innervation from the oropharyngeal mucosa (which is the sensory side of the gag reflex). It also innervates one of the six muscles (stylopharyngeus) used in swallowing. Deficits of all three of these functions were observed in this patient.

4. The correct answer is B. Following the vascular stroke of the upper medulla, the presence of hypertonia and the loss of vibration sensation on the left limbs result from damage to two long tracts in the medulla, corticospinal tract, and medial lemniscal fibers, respectively. At the medullary level, these long tracts course medially in the upper medulla, which is supplied by the anterior spinal artery.

5. The correct answer is C. The development of unilateral deafness indicates a sensorineural hearing loss below the trapezoid body. The only structure listed in this position is the cochlear nucleus in the lateral lower pons, which is the first relay of fibers of the CN VIII entering the brainstem. All of the other structures are above the trapezoid body between the mid pons and the auditory cortex.

6. The correct answer is D. Horizontal gaze to the left is being tested in this patient. The absence of adduction of the right eye sugggests an MLF lesion, which is supported by the fact that with convergence testing both medial recti contract under reflex movement. The MLF lesion will be on the side of the non-adducting eye—in this case, the right.

7. The correct answer is E. The presence of two upper motor neuron signs on the patient's left side and an oculomotor nerve lesion on the right eye is the model for Weber syndrome on the left side of the ventromedial midbrain. The lower face weakness results from a contralateral corticobulbar UMN lesion and the spasticity of the left limbs results from a contralateral corticospinal UMN lesion. The oculomotor lesion of the eye includes ptosis, a dilated pupil, and external strabismus.

8. The correct answer is B. The patient presents with crossed signs that describe a brainstem lesion. There is loss of pain and temperature on the left side of the face and the right side of the body, which point to a left brainstem lesion. The normal function of the facial expression muscles will then localize this lesion to the lateral upper medulla (Wallenberg syndrome). The motor nucleus of CN VII is at the lateral lower pons. The lower motor neuron nucleus at the lateral upper medulla is the nucleus ambiguus. The lesion of this nucleus will affect the muscles of the larynx, pharynx, and ulvula. Because the lesion is on the left side, the ulvula will deviate to the right.

9. The correct answer is C. Blood supply to the lateral upper medulla is provided by the posterior inferior cerebellar branch of the vertebral arteries.

10. The correct answer is B. The sensory input of the 1a fibers from the muscles of mastication have their cell bodies in the mesencephalic nucleus of V located in the lateral midbrain. The fibers of the mesencephalic nucleus project to the motor nucleus of CN V in the lateral mid pons to synapse with the lower motor neurons of the mandibular nerve.

Please visit us at www.Groupinsiders.com

© DeVry/Becker Educational Development Corp. All rights reserved.

1 Overview

The *cerebellum* is an essential part of the CNS, involved with the effective execution of purposeful movements. Functioning with a loop circuitry, the cerebellum affects the sequence, timing, and force of contractions of voluntary muscles, resulting in smooth and coordinated movement.

Sensory information from almost any point in the nervous system projects to the primary functional cell of the cerebellum, the *Purkinje cells of the cortex*, which then project to deep cerebellar nuclei. The deep nuclei then provide the motor output of the cerebellum that relays through the thalamus to reach the UMN and affects movement.

The cerebellum has three main functions: (1) planning of movements; (2) coordination and fine-tuning of ongoing voluntary movements; and (3) maintenance of posture, balance, and muscle tone. The cerebellum compares planned movements with the actual movements and corrects errors of movement.

The cerebellum develops from the *metencephalon* (with the pons) and overlies the dorsal aspect of the pons and brainstem, where it contributes in forming the roof of the fourth ventricle.

USMLE® Key Concepts

For Step 1, you must be able to:

- Define the organization of the cerebellum into three strips and their functions.
- Describe the major afferent and efferent circuits, the neurotransmitters involved, and their cerebellar functions.
- Identify the cellular components and circuits in the cortex and medulla of the cerebellum.
- Explain the lesions of the cerebellum and the principle of ipsilateral presentation of cerebellar dysfunction.

Please visit us at www.Groupinsiders.com

© DeVry/Becker Educational Development Corp. All rights reserved.

2 Organization of the Cerebellum

The cerebellar surface has extensive foldings called folia separated by deep fissures extending into the body of the cerebellum. The *cortex* forms the outer layer of the cerebellum and consists of *gray matter*. The deeper central *medulla* of the cerebellum is the *white matter* and contains the four deep cerebellar nuclei.

The cerebellum is attached to the brainstem by three peduncles: *superior, middle,* and *inferior*. These peduncles attach to the midbrain, pons, and medulla, respectively. The inferior and middle cerebellar peduncles primarily carry *afferents* to the cerebellum, and the superior peduncle contains mostly cerebellar *efferents*.

The cerebellum can be divided by transverse fissures into lobes: anterior, posterior, and flocculonodular. The flocculonodular lobe is the most inferior part, referred to as the vestibulocerebellum, which functions in the control of balance and control of eye movements.

However, structurally and functionally, the cerebellum is better divided into three longitudinal zones, or strips (Figure 18–2.0 and Table 18–2.0) that are associated with precise nuclei and circuits of the cerebellum: (1) a midline *vermis*, (2) an intermediate or *paravermis* on each side of the vermis, and (3) the *lateral hemisphere*.

- **The Vermis:** This provides motor control and coordination of ongoing movements of *axial* and *proximal limb muscles*. Primary sensory input to the vermis is from the spinal cord (spinocerebellar tracts). The muscle spindles and Golgi tendon organs of the trunk and limb muscles provide tremendous volumes of information via the spinocerebellar tracts to the cerebellum concerning the activity of the skeletal muscles during movement.

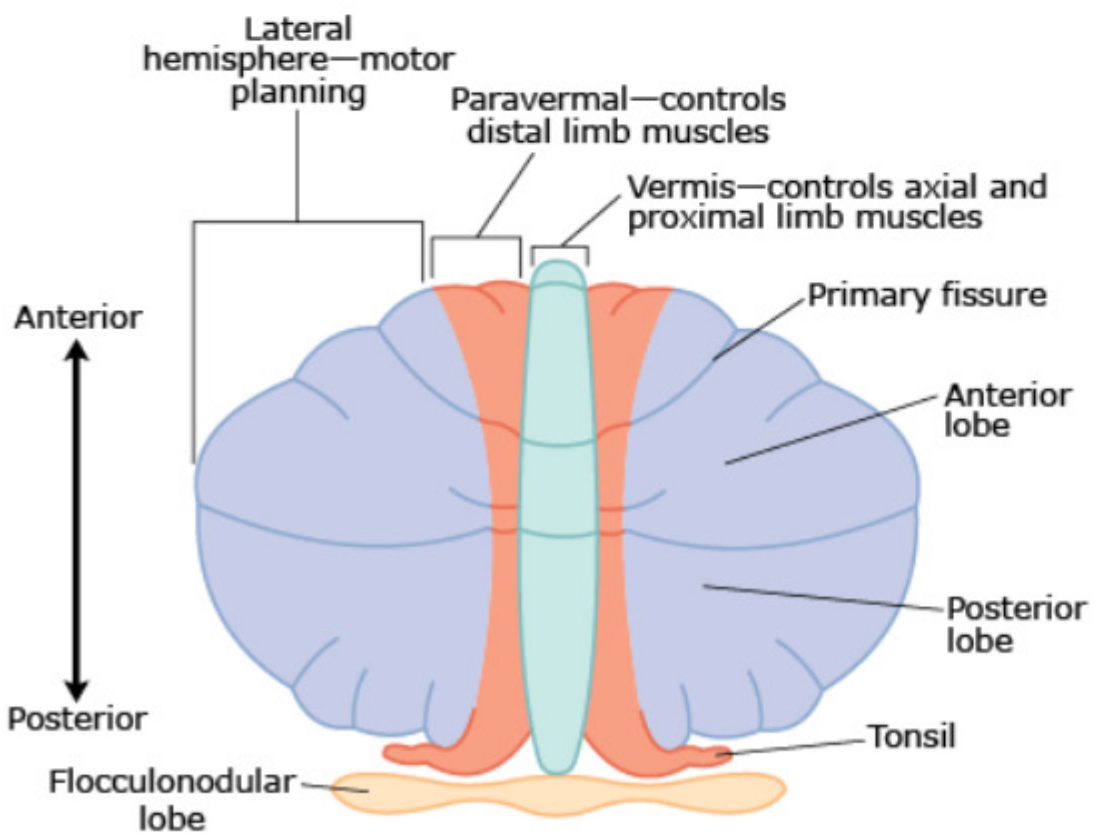

▲ **Figure 18–2.0** Cerebellar Organization

Please visit us at www.Groupinsiders.com

© DeVry/Becker Educational Development Corp. All rights reserved.

- **The Paravermis:** This provides motor control and coordination of ongoing movement of *distal limb muscles*. Primary sensory input again is via the *spinocerebellar tracts*.
- **The Lateral Hemisphere:** This is the largest part of the cerebellum and is concerned with the *planning of movement* (sequence, timing, force, distance). The planning functions of the lateral hemispheres' activity occur before movement begins.
- Primary sensory input is from the *contralateral cortex* via the corticopontocerebellar fibers that project from the cortex to the pontine nuclei on the basilar pons, which then project via the middle cerebellar peduncle to the contralateral hemispheres.
- In addition, the contralateral inferior *olivary nucleus* (olivocerebellar tract) projects to the hemispheres via the inferior cerebellar peduncle; see further discussion.

▼Table 18–2.0 Cerebellar Organization

Region	Function	Principle Input
Vermis and intermediate zones	Motor control during movement	Spinal cord (spinocerebellar tract)
Hemisphere (lateral)	Planning of movement and coordination	Cerebral cortex and inferior olivary nucleus
Flocculonodular lobe	Equilibrium; eye movements	Vestibular nuclei (VIII)

Please visit us at www.Groupinsiders.com

© DeVry/Becker Educational Development Corp. All rights reserved.

3 Cerebellar Afferents (Inputs)

The cerebellum receives sensory input from almost all major parts of the nervous system, with the major inputs from the spinal cord, cortex, brainstem, and vestibular system. All afferent neurons are excitatory (glutamate) and synapse directly or indirectly upon the Purkinje cells in the cortex. The cerebellar afferents are organized into two major sets of incoming fibers to the cerebellar cortex: *climbing* and *mossy*.

▼Table 18–3.0 Cerebellar Afferents

Name	Tract	Enter Cerebellum Via	Target and Function
Climbing fibers	Olivocerebellar	Inferior cerebellar peduncle (decussate)	Excitatory terminals on Purkinje cells (glutamate)
Mossy fibers	Vestibulocerebellar	Inferior cerebellar peduncle	Excitatory terminals on granule cells (glutamate) which are excitatory to Purkinje cells
	Spinocerebellar	Inferior cerebellar peduncle and superior cerebellar penduncle	
	(Cortico) pontocerebellar	Middle cerebellar peduncle (decussate)	

- **Climbing Fibers:** These fibers arise from the contralateral inferior olivary nucleus in the upper medulla. These fibers course through the *inferior cerebellar peduncle* and synapse directly on the *Purkinje cells* (olivocerebellar tract). A single climbing fiber will end on a single Purkinje cell (one-to-one ratio) and has a very powerful, excitatory influence on the cell, producing a prolonged, complex spike action potential. The inferior olive complex serves to detect errors in movement and make appropriate corrections.
- **Mossy Fibers:** These are excitatory sensory inputs to the cerebellum that arise from areas of the nervous system (spinal cord, cortex, and vestibular system) other than the inferior olivary nucleus.
- The afferent fibers from the contralateral *cortex* utilize the *middle cerebellar peduncle* and are the only ones that do so.
- The remaining mossy fibers from the spinal cord and vestibular system enter primarily via the *inferior cerebellar peduncle* to reach Purkinje cells of the ipsilateral hemisphere.
- The mossy fibers synapse on the dendrites of the *granule cells* in the cortex. Then the axons of the granule cells form parallel fibers that synapse on the dendritic tree of the Purkinje cell in the molecular layer of the cortex.
- This mossy input is very diffuse, with multiple synapses to the Purkinje cells.

Please visit us at www.Groupinsiders.com

© DeVry/Becker Educational Development Corp. All rights reserved.

4 Microscopic Structure

4.1 Cerebellar Cortex

The *cortex* is the outer layer of gray matter and contains five cell types. The *Purkinje* and the *granule* cells are the two major cell types in the cortex; the *stellate, basket,* and *Golgi* cells are support cells for the other two. The granule cell is the only excitatory (glutamate) neuron in the cortex. The remaining four cells are inhibitory (GABA) neurons. The Purkinje cell is the one cell of the cortex whose axon projects into the deeper medulla of the cerebellum.

▼ Table 18–4.1 Cerebellar Cortex Neurons

Neuron	Layer	Projection	Synaptic Action
Purkinje	Purkinje	Deep cerebellar nuclei	Inhibitory (GABA)
Granule	Granule	Purkinje cell	Excitatory (glutamate)
Basket	Molecular	Purkinje cell	Inhibitory (GABA)
Stellate	Molecular	Purkinje cell	Inhibitory (GABA)
Golgi	Granule	Granule cell	Inhibitory (GABA)

Please visit us at www.Groupinsiders.com

© DeVry/Becker Educational Development Corp. All rights reserved.

The cortex is organized into three layers (Figure 18–4.1A):

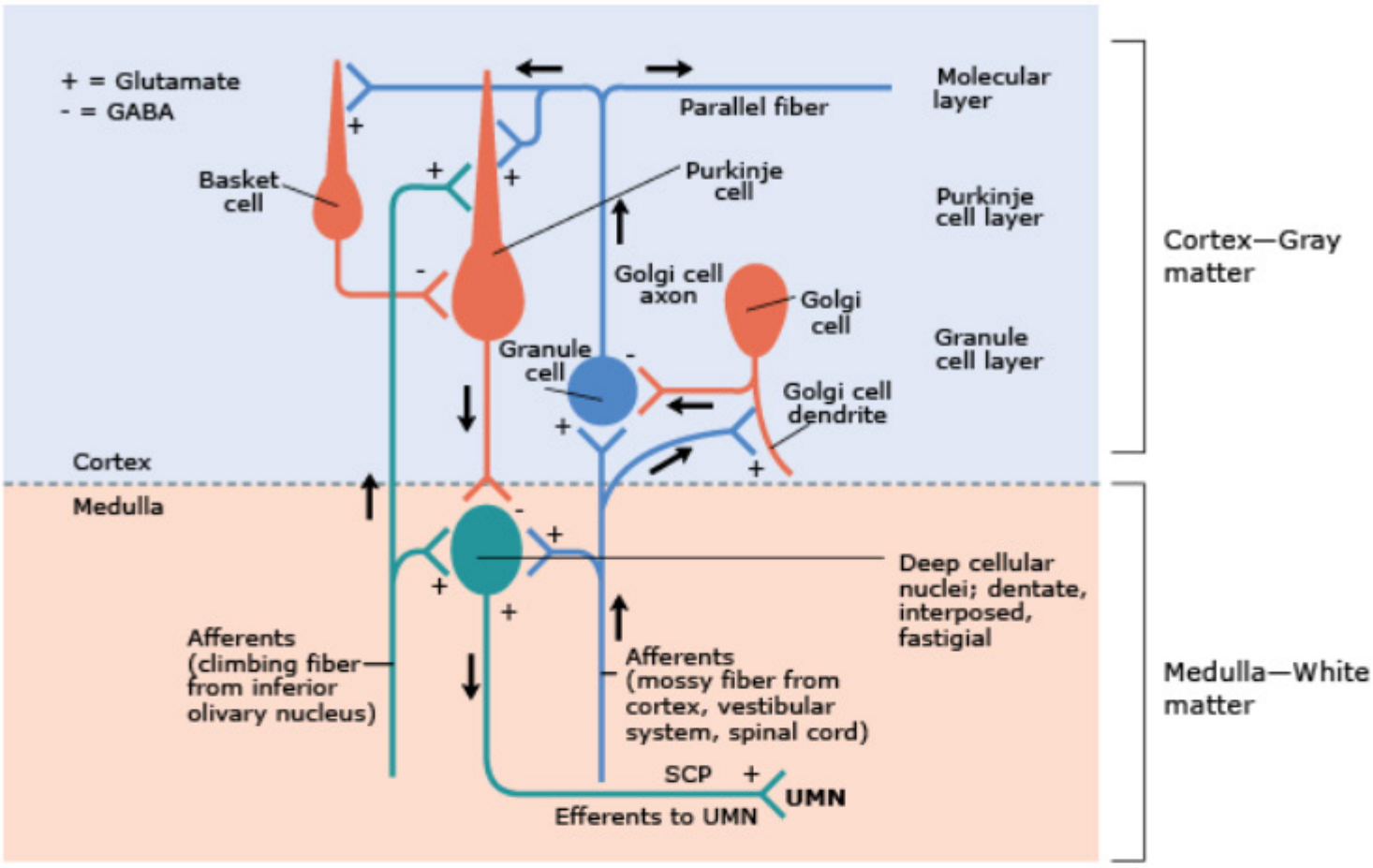

▲ **Figure 18–4.1** Cerebellar Cytology

1. **Molecular Layer:** This is the outer layer of the cortex and contains:
   - Axons of granule cells extend into the molecular layer and turn 90 degrees to run long distances as *parallel fibers* below the surface of the cerebellum. These axons synapse (glutamate) on the elaborate dendritic tree of the Purkinje cells.
   - Extensive *dendrites of the Purkinje cells*, which extend into the molecular layer.
   - Stellate and basket cells.
2. **Purkinje Cell Layer:** This is the important middle layer of the cortex and contains:
   - The large *Purkinje neurons*, whose cell bodies receive direct or indirect input from the afferent climbing and mossy fibers, respectively. The Purkinje dendrites extend into the molecular layer.
   - The axons of the Purkinje cells, which are inhibitory (GABA), course from the cortex to the medulla. They are the only fibers that project from the cortex and are inhibitory (GABA) to the deep nuclei in the medulla.
3. **Granule Cell Layer:** This is the deepest layer of the cortex and contains:
   - Layers of numerous *granule cells,* which receive excitatory input from mossy fibers. The axons of granule cells pass through the molecular layer and turn 90 degrees to run long distances as parallel fibers that synapse on the dendrites of the Purkinje cells. Granule cells are the only excitatory neurons in the cortex.
   - Golgi cells, which are inhibitory to the granule cell.

Please visit us at www.Groupinsiders.com

© DeVry/Becker Educational Development Corp. All rights reserved.

4.2 Cerebellar Medulla

Embedded in the white matter of the medulla are four deep cerebellar nuclei arranged from lateral to medial: *dentate, interposed (emboliform and globose), and fastigial*. The deep nuclei receive inhibitory projections (GABA) from Purkinje axons in a very precise and organized topographic arrangement.

- Vermis Purkinje cell axons project to the *fastigial nucleus.*
- Intermediate (paravermis) Purkinje cell axons project to the *interposed nuclei* (globose and emboliform).
- Lateral hemisphere Purkinje cell axons project to the *dentate nucleus.*

These nuclei also receive tonic excitatory drive via collaterals from the climbing and mossy fibers. Thus, the inhibition from the Purkinje cells modulates the firing of the deep nuclei in the white matter.

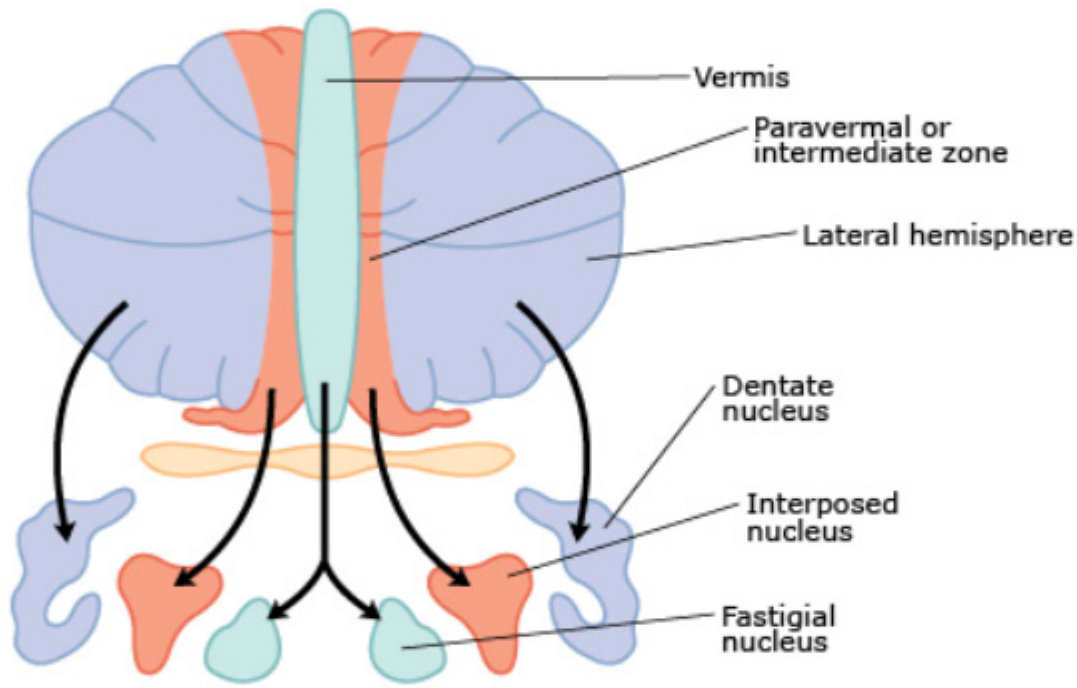

▲ **Figure 18–4.2** Projection of Purkinje Axons

Please visit us at www.Groupinsiders.com

© DeVry/Becker Educational Development Corp. All rights reserved.

5 Cerebellar Efferents (Outputs)

The neurons of the deep nuclei are excitatory (glutamate), and their axons form the cerebellar efferents that leave the cerebellum primarily via the superior cerebellar peduncle. The efferents relay through the contralateral thalamus and project to *upper motor neurons* to affect movement.

5.1 Efferents From the Lateral Hemispheres

- The lateral dentate nucleus receives input mainly from Purkinje cell axons of the lateral hemispheres.
- The efferents from the dentate nucleus exit through the superior cerebellar peduncle, *decussate* across the midline of the midbrain, and terminate in the contralateral ventral anterior (VA and VL) nuclei of the thalamus.
- The thalamic neurons project to the ipsilateral motor cortex of the frontal lobe to modulate firing of the corticospinal and corticobulbar upper motor neurons.
- The corticospinal tract descends, decussates, and innervates contralateral limb muscles.

Thus, one side of the cerebellum controls and coordinates *ipsilateral limb muscles*. For instance, the right cerebellum projects to the left thalamus and then to the left motor cortex. The upper motor neurons of the left motor cortex then descend and decussate back to the right limb muscles (Figure 18–5.1).

Efferents of Hemisphere to Limbs and Trunk:

Hemisphere Purkinje cells → Dentate nucleus → SCP → Decussates in midbrain → Contralateral thalamus (VA, VL) → UMN Corticospinal of motor cortex → Decussates in lower medulla → LMN of spinal cord

Please visit us at www.Groupinsiders.com

© DeVry/Becker Educational Development Corp. All rights reserved.

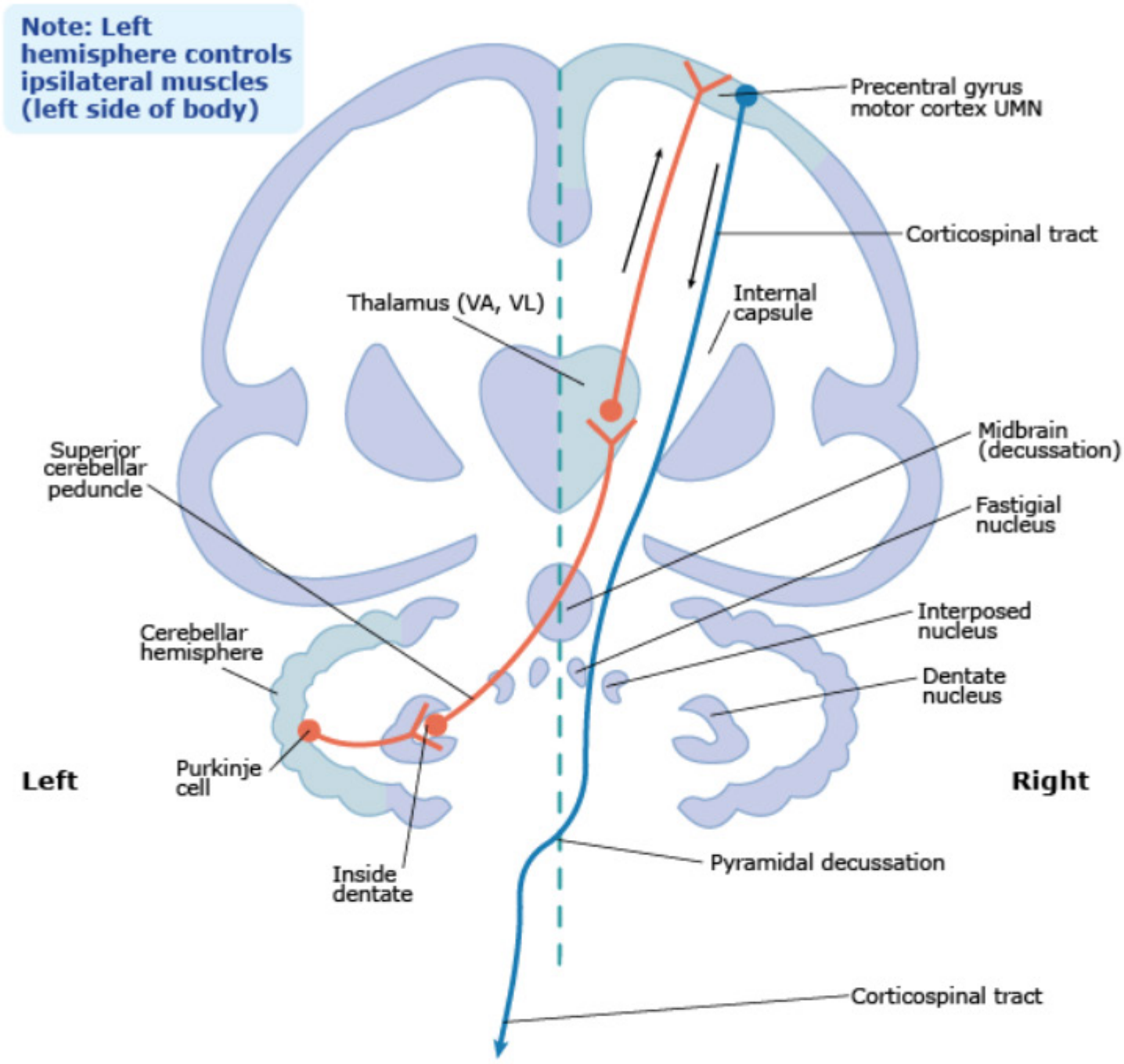

Cerebellar Areas	Deep Cerebellar Nucleus	Efferents to:	Function
Prontocerebellum (lateral hemispheres)	Dentate nucleus	Thalamus (VA, VL) then cortex	Influence on LMNs via the corticospinal tract, which effect voluntary movements, especially sequence and precision
Purkinje cell		Decussation in midbrain	

▲ **Figure 18–5.1** Cerebellar Efferents

Please visit us at www.Groupinsiders.com

© DeVry/Becker Educational Development Corp. All rights reserved.

6 Lesions of the Cerebellum

6.1 Lateral Hemisphere Lesions

The lateral hemispheres make up the largest part of the cerebellum and are often damaged in cerebellar lesions, which are characterized by changes in coordination of movement, muscle tone, and reflexes. Cerebellar lesions occur without sensory deficits and without muscle paralysis. Some of the common features and symptoms of lesions of the hemispheres are:

- **Ipsilateral Deficits:** Hemispheres project to contralateral cortex and upper motor neurons descend to contralateral limbs, discussed above.
- **Intention Tremor:** Increases in intensity with movement, in contrast to a resting tremor seen in disorders of the basal ganglia.
- **Lack of Coordination (Ataxia):** Most prominent in the limbs. Patient tends to fall to side of lesion when walking.
- **Dysmetria:** Manifested in an inability to judge distance; the patient under- or overshoots a target.
- **Dysdiadochokinesia:** The inability to rapidly produce alternating movements (pronation and supination).
- **Hypotonia** and **Decreased Deep Tendon Reflexes:** Occur with lesions of the deep nuclei.

6.2 Vermal Lesions

The *vermis* functions in coordination and muscle control of the *axial (trunk) muscles*, and lesions result in problems with control of balance, posture, and gait. The lower limbs are mostly represented in the anterior part of the vermis. Chronic alcoholism causes degeneration of the anterior vermis and results in a broad-based staggering gait (gait ataxia).

The Romberg sign can be used to differentiate between vermal cerebellar lesions and lesions of the dorsal columns. With a dorsal column lesion, patients demonstrate a positive Romberg sign by swaying and falling over with eyes closed *(sensory ataxia)* when the feet are pulled together. With a vermal lesion, patients sway and fall over with eyes open when the feet are pulled together *(motor ataxia)*.

Alcohol abuse usually results in degeneration of anterior vermis.

CNS tumors result in posterior vermis lesions.

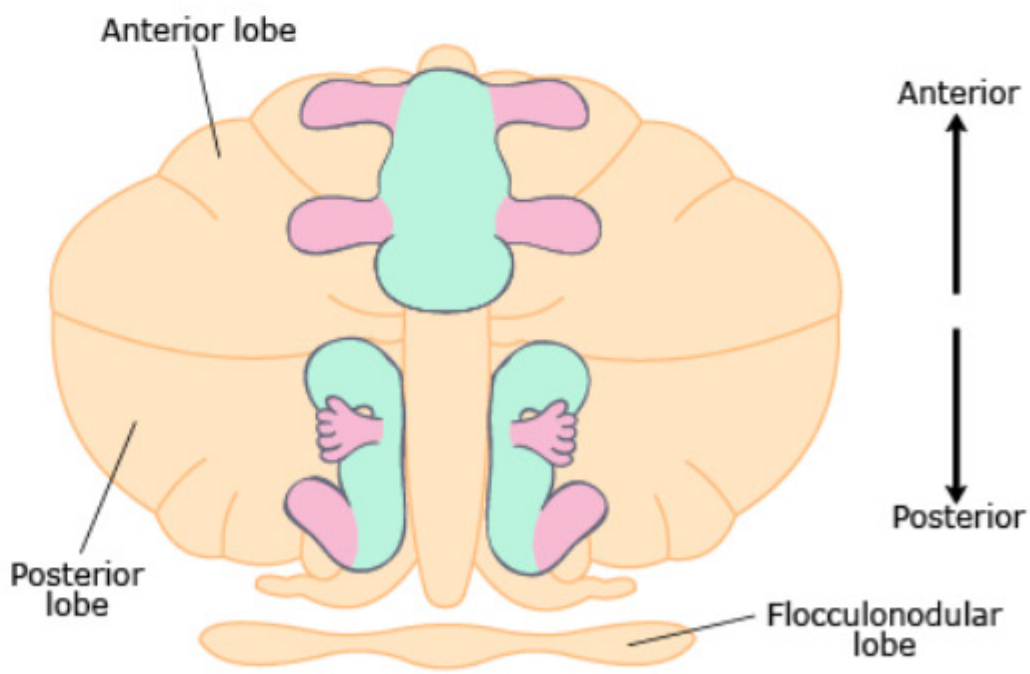

▲ **Figure 18–6.2** Topographic Organization of Cerebellum

Please visit us at www.Groupinsiders.com

© DeVry/Becker Educational Development Corp. All rights reserved.

1 Components of the Basal Ganglia

The *basal ganglia* are a series of integrated interconnections of nuclei. Along with the thalamus and the cortex, they play an important role in the initiation of voluntary movements and suppression of movements to keep the motor cortex quiet and prevent unwanted movement at rest. The basal ganglia also have nonmotor cognitive functions.

The basal ganglia consist of five major nuclei located deep in the cerebral hemispheres, diencephalon, and the midbrain. Different names are given to different groups of nuclei (Figures 19–1.0A, 19–1.0B, and 19–1.0C).

1.1 Cerebral Hemisphere

1.1.1 Caudate Nucleus

The *caudate nucleus* is a C-shaped subcortical structure with a large head that bulges into the lateral ventricle, body, and tail.

1.1.2 Putamen

The *putamen* is located lateral to the caudate nucleus and separated from it by the anterior limb of the internal capsule. When the caudate nucleus and putamen are combined, they are referred to as the *striatum* (neostriatum). The striatum forms the *input center*.

1.1.3 Globus Pallidus

The *globus pallidus*, located between the putamen and internal capsule, is divided into an *internal segment*, adjacent to internal capsule, and an *external segment*, adjacent to the putamen. The external segment is part of the indirect pathway, and the internal segment is integrated in both the direct and indirect pathways.

- The internal segment is referred to as the *output center* because its inhibitory neurons (GABA) project to the thalamus (VA and VL nuclei).
- The combination of the caudate nucleus, putamen, and the globus pallidus is referred to as the *corpus striatum*.

1.2 Midbrain

1.2.1 Substantia Nigra

Bilateral, large, heavily pigmented nuclei located in the ventral midbrain consisting of a *pars reticularis* and a *pars compacta*. The pars compacta contains *dopamine neurons*, and the pars reticularis contains *GABA neurons*.

USMLE® Key Concepts

For Step 1, you must be able to:

- Define and locate the major structures forming the basal ganglia.
- Describe the circuits and neurotransmitters of the direct and indirect pathways and their functions.
- Identify basal ganglia structures on axial and frontal images of the brain.
- List the major lesions of the basal ganglia and their primary lesion sites.

Please visit us at www.Groupinsiders.com

© DeVry/Becker Educational Development Corp. All rights reserved.

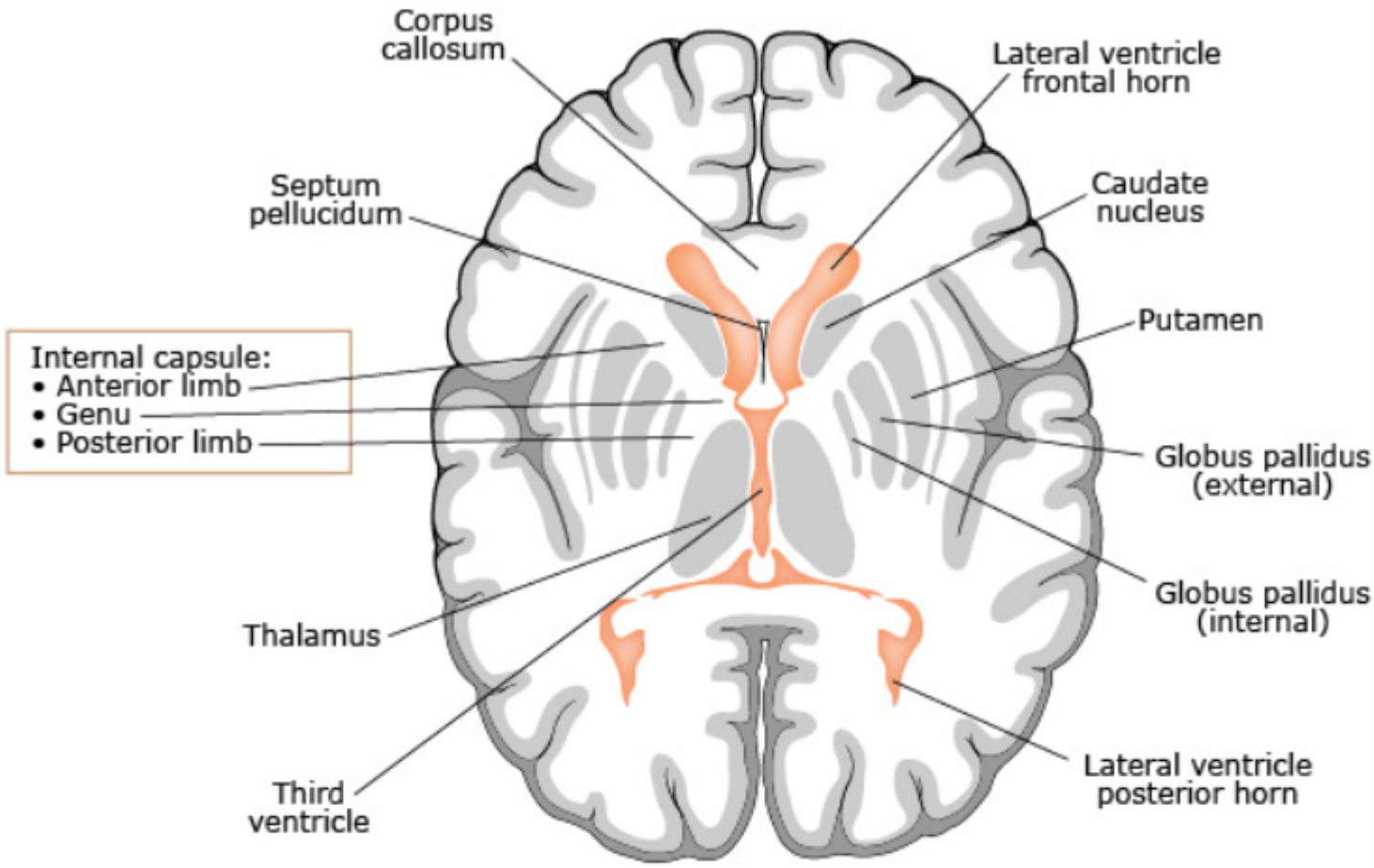

▲ **Figure 19–1.0A** Basal Ganglia and Internal Capsule

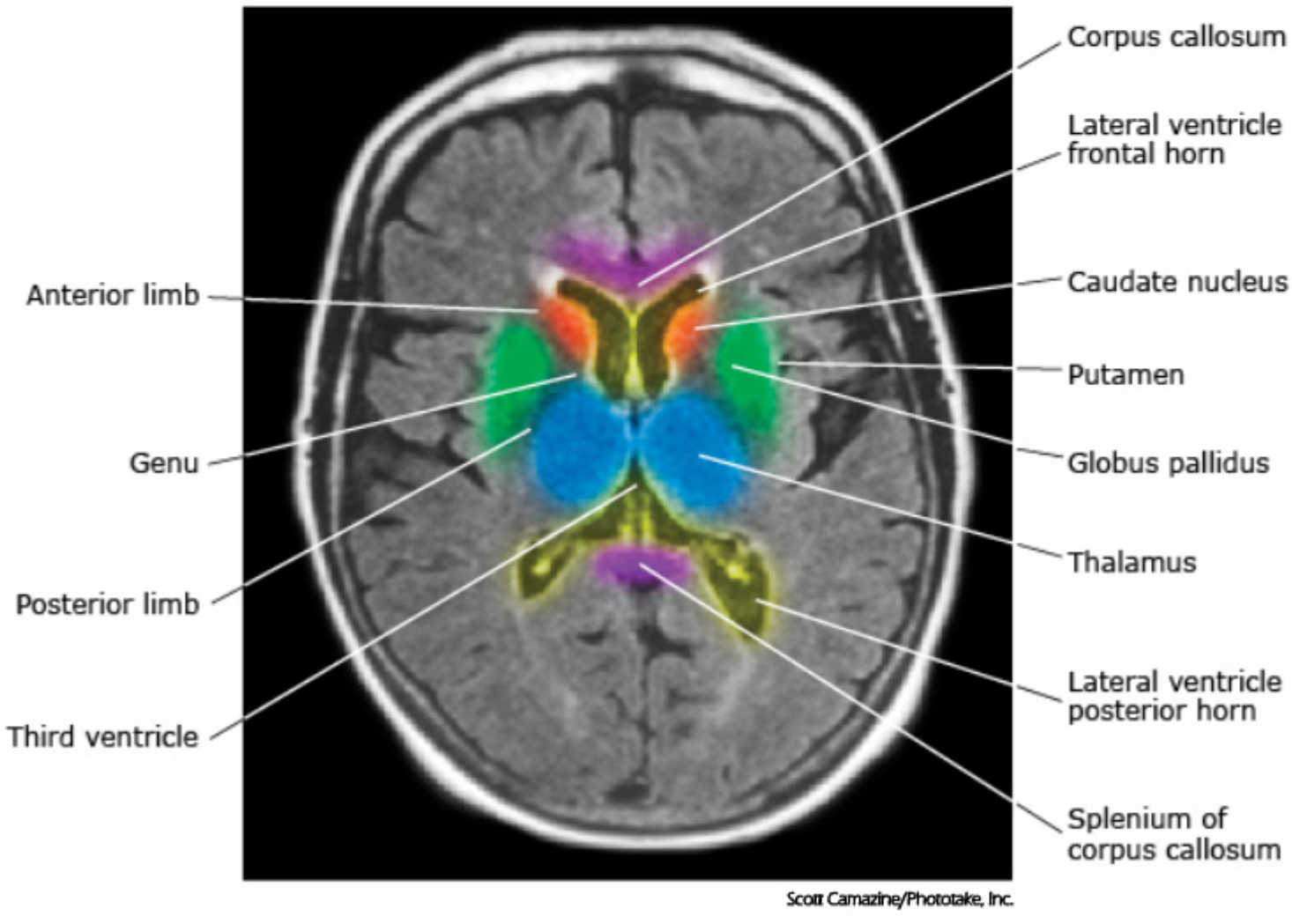

Scott Camazine/Phototake, Inc.

▲ **Figure 19–1.0B** Axial Section

Please visit us at www.Groupinsiders.com

© DeVry/Becker Educational Development Corp. All rights reserved.

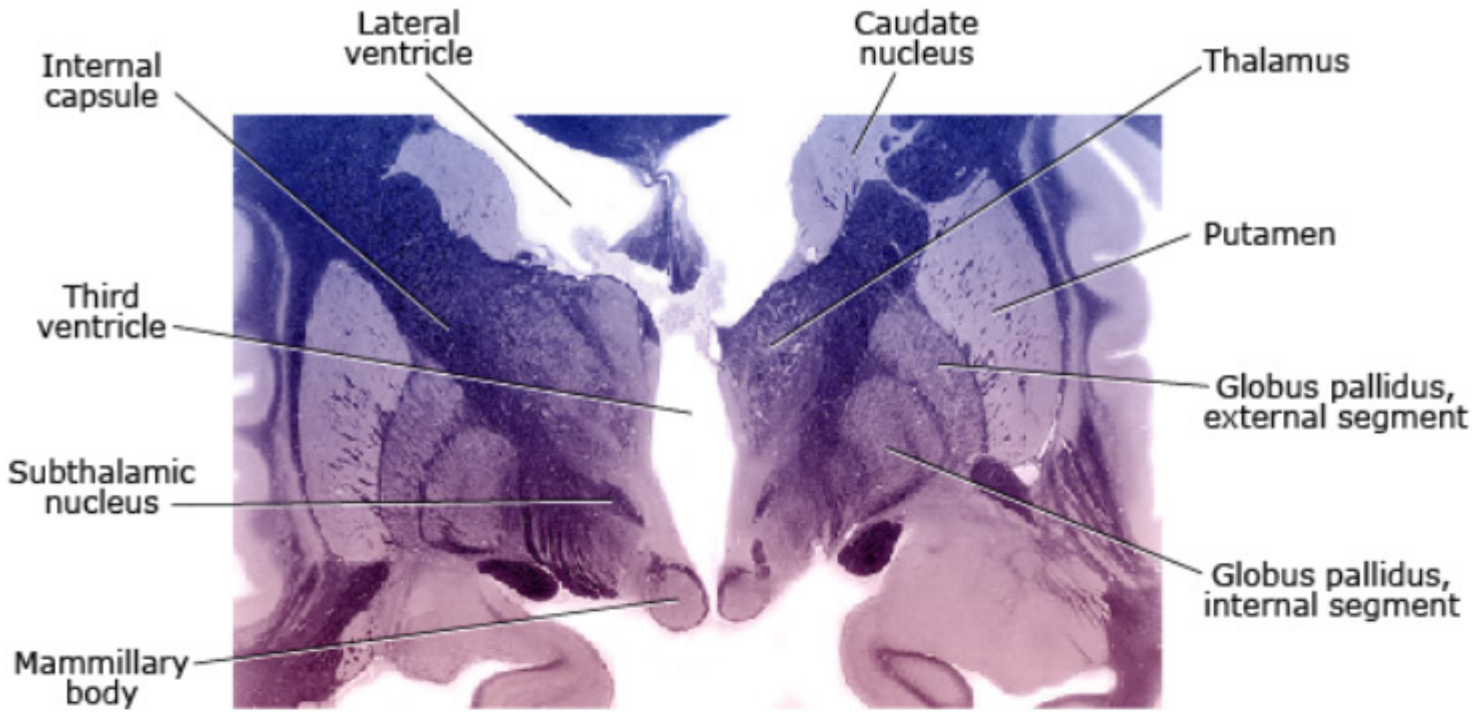

▲ **Figure 19–1.0C** Coronal Section at Level of Mammillary Bodies

1.3 Diencephalon

1.3.1 Subthalamic Nucleus

Bilateral, large nuclear masses located ventral to the thalamus containing glutamate neurons. It is part of the indirect basal ganglia pathway (Figure 19–1.3).

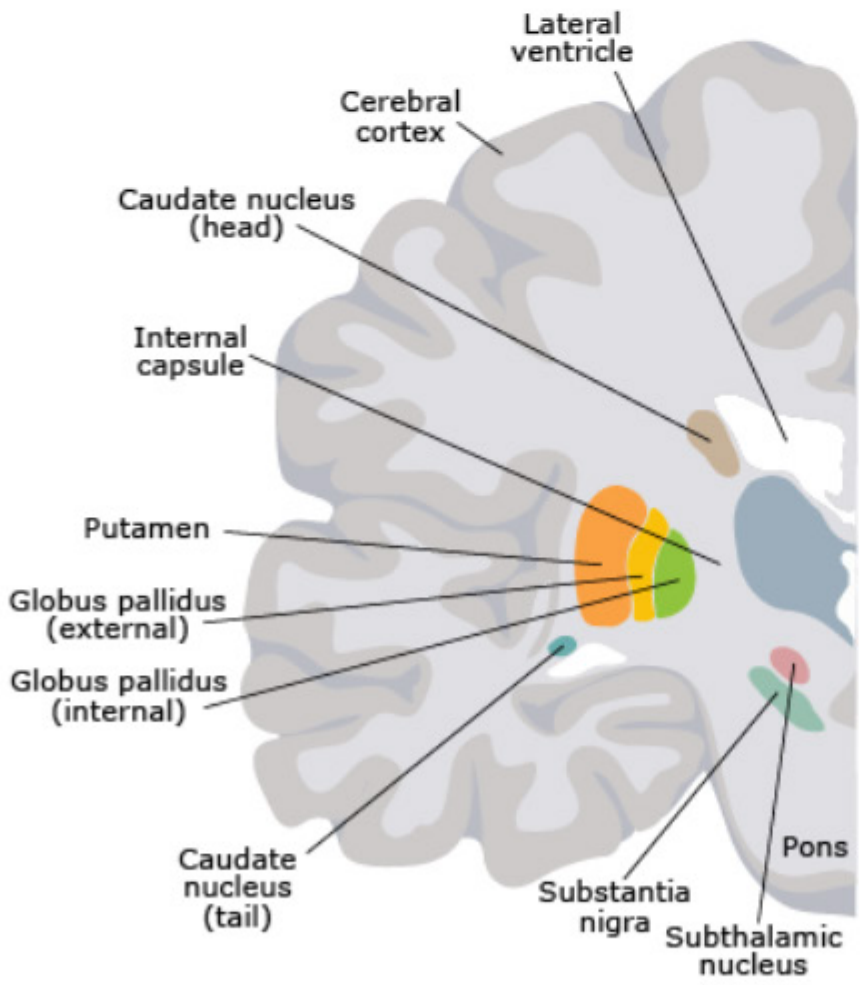

▲ **Figure 19–1.3** Basal Ganglia—Frontal Section

Please visit us at www.Groupinsiders.com

© DeVry/Becker Educational Development Corp. All rights reserved.

2 Basal Ganglia Afferents

The major source of sensory input fibers to the striatum (input center) is from most regions of the *cortex*. The afferents directed to the *putamen* are mainly from the motor cortical areas of the frontal lobe and the somatosensory areas of the parietal lobe. The afferents to the *caudate nucleus* are mostly from association areas and limbic regions of the cortex. This suggests that the putamen is more involved with motor functions, but the caudate nucleus may be more involved with cognitive and emotional functions.

Another important source of afferents to the striatum is from the compact part of the *substantia nigra* (dopamine) of the midbrain.

3 Interconnections of Basal Ganglia: Direct and Indirect Pathways

The interconnections of the basal ganglia, along with the cortex and the ventral anterior (VA) and ventral lateral (VL) nuclei of the thalamus, are extensive. These connections influence voluntary movements through two parallel loop circuits (*direct* and *indirect pathways*) that provide opposite functions.

- Both of these circuits receive extensive excitatory afferents (glutamate) from the cortex to the striatum.
- The pathways employ the same two same neurotransmitters used in the cerebellum (glutamate and GABA), but also incorporate dopamine and acetylcholine in parts of the circuits.
- The striatum contains two populations of inhibitory GABA neurons that project into the direct or the indirect pathways. Each of these sets of inhibitory neurons forms the beginning of the two pathways from the striatum.
- Both pathways use the process of *disinhibition*, which is defined by the presence of two inhibitory neurons in sequence, resulting in the third neuron in sequence being excitatory.
- Both pathways relay through the VA and VL nuclei of the thalamus.
- The basal ganglia connections are all in the ipsilateral cortex.

3.1 Direct Basal Ganglia Pathway

1. In the *direct pathway* (Figure 19–3.1), neurons of the cortex project excitatory (glutamate) neurons primarily to the putamen and the caudate nuclei of the striatum.
2. The activated neurons of the striatum are inhibitory (GABA) to the internal segment of the globus pallidus, which then *disinhibits the VA and VL nuclei of the thalamus*.
3. The removal and release of the tonic inhibition of the internal segment allows the thalamus to have a strong, excitatory (glutamate) input on the cortex and results in an *increased activity in cortical excitation and promotion of movement*.

Important Concept

1. Direct Pathway: increases cortical excitation and initiates movement.
2. Indirect Pathway: decreases cortical excitation and suppresses movement.

Please visit us at www.Groupinsiders.com

© DeVry/Becker Educational Development Corp. All rights reserved.

4. Note that the striatal and internal segment neurons are inhibitory (GABA). Therefore, when these two neurons are placed in sequence, disinhibition of the thalamus occurs, which has the net effect of excitation of the motor cortex.
5. Essential for excitation and activation of the striatal GABA neurons in the direct pathway is the release of *dopamine* from the compact part of the substantia nigra that projects to the striatum.
6. Dopamine acting at *D1 receptors* on the cell membranes of the striatum results in the release of GABA from the striatal neurons in the direct pathway that drive the direct pathway and promote movement. But at the *D2 receptors* of the striatum, dopamine suppresses the indirect pathway by inhibiting GABA neurons of the indirect pathway, allowing the direct pathway to open. Thus, dopamine excites the direct pathway, but inhibits the indirect pathway.

Important Concept

Dopamine excites the direct pathway (D1 receptor) and inhibits the indirect pathway (D2 receptor).

Acetylcholine excites the indirect pathway.

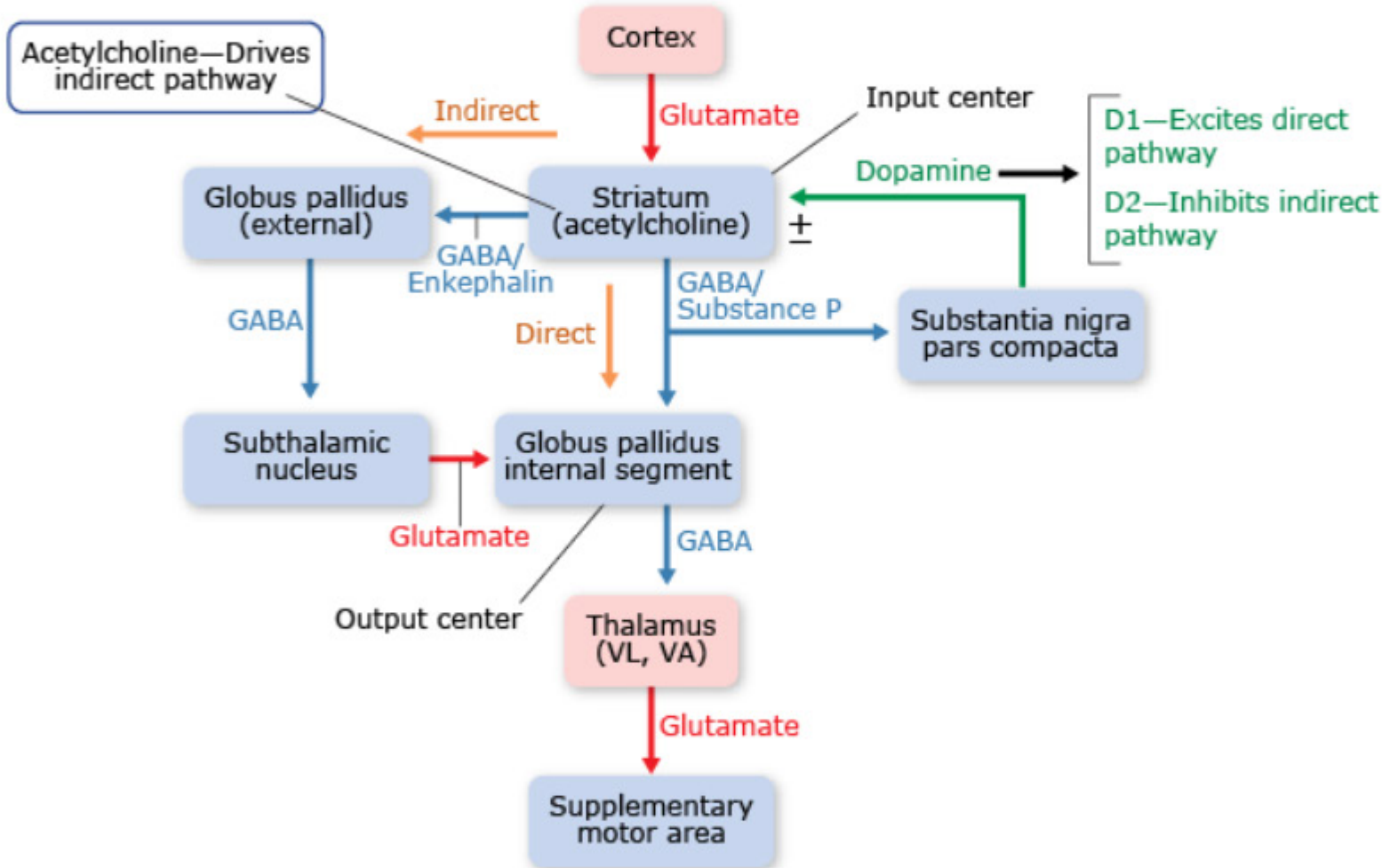

▲ **Figure 19–3.1** Direct and Indirect Pathways

Please visit us at www.Groupinsiders.com

© DeVry/Becker Educational Development Corp. All rights reserved.

3.2 Indirect Basal Ganglia Pathway

The *indirect pathway* (Figures 19–3.1 and 19–3.2) is a series of connections that result in decreasing cortical activity and suppression of movement.

1. In the indirect pathway, the cortex is also excitatory (glutamate) to the striatum.
2. The striatial GABA-inhibitory neurons of the indirect pathway project to and inhibit the external segment of the globus pallidus.
3. The external segment is then inhibitory (GABA) to the subthalamic nucleus.
4. These two inhibitory neurons in sequence result in *disinhibition of the subthalamic nucleus*. This allows the subthalamic neurons to provide a very strong excitatory (glutamate) input to the internal segment of the globus pallidus, resulting in strong inhibition (GABA) of the thalamic VA and VL nuclei that decreases excitation of the cortex.
5. Thus, the indirect pathway results in *decreased excitation of the cortex and suppression of movements*. Acetylcholine neurons in the striatum excite the GABA neurons of the striatum and drive the indirect pathway to suppress movement.

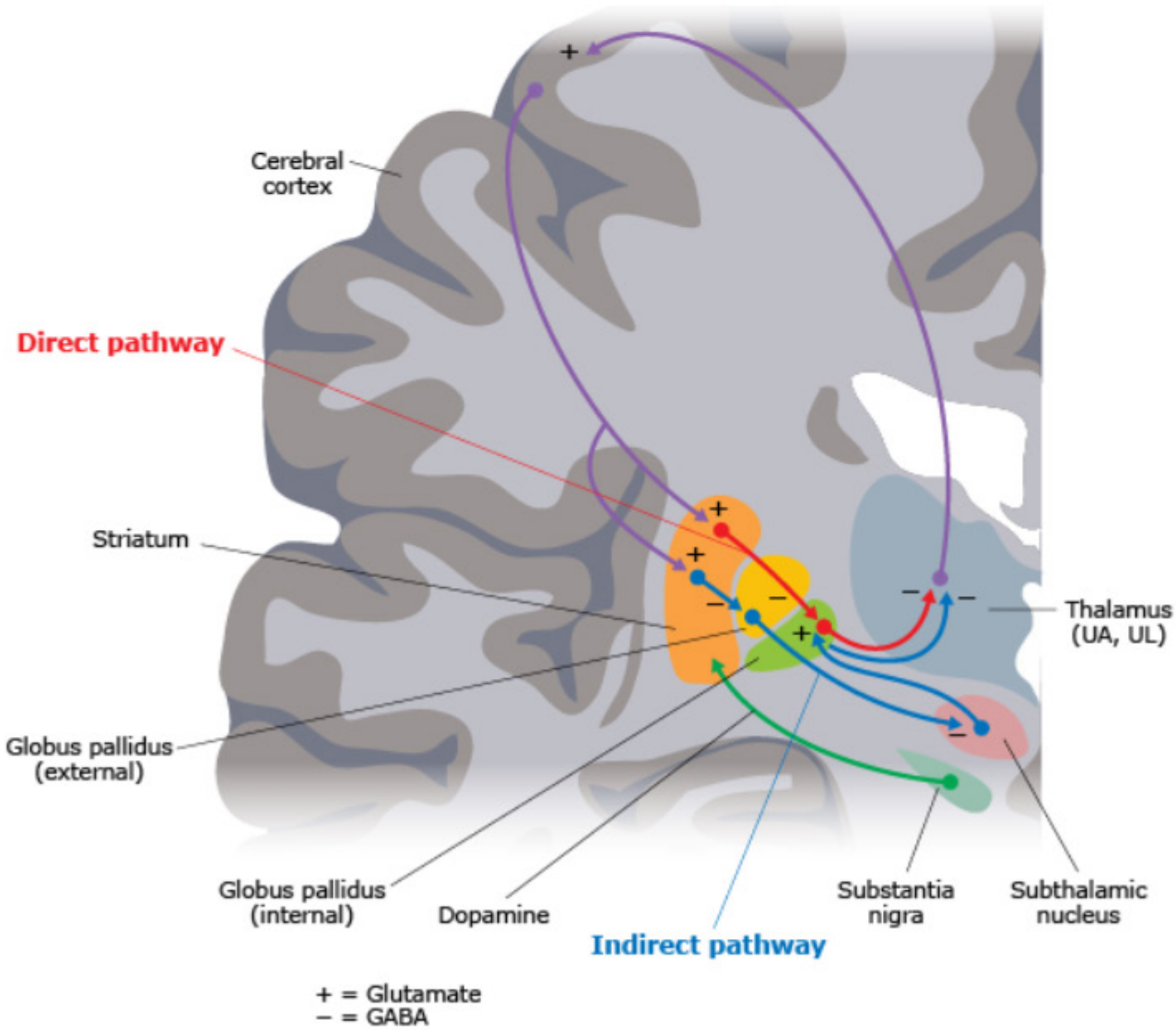

▲ **Figure 19–3.2** Basal Ganglia Pathways

Please visit us at www.Groupinsiders.com

© DeVry/Becker Educational Development Corp. All rights reserved.

4 Cognitive Function

Basal ganglia also have a nonmotor role to play in cognition and emotions. For *cognitive function*, prefrontal inputs to the striatum are mainly directed to the caudate nucleus. Lesions in these circuits affect motor activities that require spatial memory and are connected to cognitive disturbances, as seen in cases of Huntington chorea.

5 Functional Review

The functional considerations of the basal ganglia are complex. In summary, the major circuit interconnections and neurotransmitters can be briefly outlined as follows:

- Cortical input of a desired movement projects excitatory neurons (glutamate) to the striatum (*input center*) for both the direct and indirect pathways.
- Tonic inhibition (GABA) from the globus pallidus internal segment (*output center*) to the VA and VL nuclei of the thalamus inhibits thalamic neurons, decreasing cortical activation and suppressing movement. This tonic thalamic inhibition by the internal segment is modulated by the parallel circuits of the direct and indirect pathways.
- In the *direct pathway,* striatal neurons are inhibitory (GABA) to the internal segment that are then inhibitory to the thalamus, which disinhibits the thalamus and allows thalamic activation (glutamate) of the cortex and movement.
- In the *indirect pathway*, striatal neurons are inhibitory (GABA) to the external segment of the globus pallidus that are inhibitory to the subthalamus, resulting in disinhibition of the subthalamic nucleus. Disinhibition of the subthalamic neurons leads to excitation (glutamate) and activation of the internal segment of the globus pallidus. Excitation of the internal segment increases inhibition (GABA) to the thalamic neurons, and suppresses cortical activity and movement.
- Note that in the direct pathway, the internal segment is inhibited, but in the indirect pathway, the internal segment is activated.
- *Dopamine* modulates the activity of the direct and indirect pathways by activation of the *D1* and *D2 receptors* of the striatum. At the D1 receptors, dopamine activates and drives the direct pathway, but at the D2 receptors, dopamine decreases and suppresses the indirect pathway.
- *Acetylcholine* neurons of the striatum activate and drive the indirect pathway.

Please visit us at www.Groupinsiders.com

© DeVry/Becker Educational Development Corp. All rights reserved.

6 Basal Ganglia Disorders

Lesions of the basal ganglia (Table 19–6.0) affect the balance between the direct and indirect pathways and are associated with several kinds of movement disorders. They are divided into two types: hypokinetic and hyperkinetic movement disorders.

▼Table 19–6.0 Major Movement Disorders Stemming from Basal Ganglia Lesions

Diseases	Characteristics	Structure Implicated
Parkinson disease: Hypoactive cortex	• Pill-rolling tremor at rest • Difficulty initiating movement (bradykinesia) • Masked face—hypertonia • Small movements—shuffling gait • Cogwheel rigidity	Degeneration of dopaminergic neurons of substantia nigra
Huntington disease (Hereditary on gene in chromosome 4) Hyperactive cortex	• Chorea: Small, quick, involuntary movements of fingers, hands, occasionally head, arms and legs • Lilting, dance-like gait • Athetosis: Nearly constant, slow, writhing movements • Personality changes	Degeneration of GABA neurons of striatum-caudate nucleus primarily
Hemiballismus Hyperactive cortex	Violent, flinging movements, usually involving an entire arm on one side	Subthalamic nucleus Contralateral hemorrhagic damage

6.1 Direct Pathway Lesions

Direct pathway lesions are *hypokinetic* and characterized by an *underactive cortex* with slowness (*bradykinesia*) or lack (*akinesia*) of movement. The most common lesion of the direct pathway is Parkinson disease, which results from bilateral degeneration of the dopamine neurons in the substantia nigra nucleus of the midbrain. With the loss of dopamine, the direct pathway is suppressed and there is difficulty initiating movements.

Parkinson Disease

- *Bradykinesia* (difficulty in starting and performing volitional movements) is a common clinical finding.
- Very characteristic is the presence of a *pill-rolling tremor* at rest that disappears with movement. This is a hallmark of basal ganglia diseases.
- There is *hypertonia* and a *cogwheel* or *lead-pipe* rigidity, which are in contrast to the spasticity seen with an upper motor neuron lesion.
- Patients present with a *masked face* (loss of facial expression), *stooped posture*, and a slow, *shuffling, propulsive gait*.
- L-DOPA, a precursor of dopamine, is used for treatment.

Please visit us at www.Groupinsiders.com

© DeVry/Becker Educational Development Corp. All rights reserved.

6.2 Indirect Pathway Lesions

Indirect pathway lesions are *hyperkinetic* and characterized by an *overactive cortex* with breakthrough of excessive involuntary movements that occur at rest, with decreased muscle tone. Some of the more typical movement disorders involving the indirect pathways are listed below.

1. *Huntington disease* is characteristic of an indirect pathway lesion. This hereditary disorder of chromosome 4 is associated with bilateral degeneration of the GABA neurons (preferential loss of neurons in the indirect circuit) and cholinergic neurons of the striatum, primarily the caudate nucleus. The caudate nucleus is associated with cognitive functions, and patients show gradual development of dementia and changes in personality. Typical movement disorders include chorea and athetosis.

   Chorea disorders are bilateral rapid, dance-like, jerking movements of the limbs. They are spontaneous, uncontrollable, and purposeless movements. Head jerking, lip smacking and tongue movements are also present.

   Athetosis is characterized by slow, serpentine movements, mainly in the upper limbs. It is also found in Huntington disease and other indirect basal ganglia disorders.

2. *Hemiballismus* is a unique movement disorder of the basal ganglia in that it is not bilateral and involves either the right or left limbs. *Ballismus* is a very violent, forceful, swinging movement of one limb. Hemiballismus is most often caused by a hemorrhagic stroke of the *contralateral subthalamic nucleus*.

3. Additional movement disorders are *dystonia* (slow twisting and contorting positions of body posture) and *Tourette syndrome* (motor and vocal tics).

Please visit us at www.Groupinsiders.com

© DeVry/Becker Educational Development Corp. All rights reserved.

Review Questions Chapters 18–19

1. During a neurological exam, a 55-year-old man was unable to touch his nose with his left hand. His finger would miss his nose, and the movement was not smooth but occurred with stops and starts. In addition, his hand shook during movement. Where would the physician expect to locate a lesion?

A. Right paravermis
B. Left fastigial nucleus
C. Right dentate nucleus
D. Left cerebellar hemisphere
E. Left aspect of the flocculonodular lobe

2. A patient presents with strong, violent swinging movements of the right upper limb. An MRI indicates a hemorrhagic lesion in the left subthalamic nucleus. Which of the following neurotransmitters is directly affected following damage to the neurons in this region?

A. GABA to the striatum
B. Glutamate to internal segment of globus pallidus
C. GABA to the VA and VL nuclei
D. Glutamate to the striatum
E. Dopamine to the striatum

3. Cortical excitation of neurons in the striatum that project through the indirect pathway results in:

A. Inhibition of the external segment of the globus pallidus
B. Disinhibition of the subthalamic nucleus
C. Excitation of the motor cortex
D. Disinhibition of the internal segment of the globus pallidus
E. Excitation of the D1 receptors of the striatum

4. Which of the following is a common neurotransmitter of the neurons in the putamen and the external segment of the globus pallidus?

A. GABA
B. Acetylcholine
C. Glutamate
D. Dopamine
E. L-3,4-dihydroxyphenylalanine

5. Within cerebellar circuits, the neurons of the dentate nucleus project directly to which of the following?

A. Lower motor neurons
B. Purkinje layers of the cerebellar cortex
C. Upper motor neurons of the precentral gyrus
D. VA/VL nuclei of the thalamus
E. Granule cell layer of the cerebellar cortex

Please visit us at www.Groupinsiders.com

© DeVry/Becker Educational Development Corp. All rights reserved.

Chapters 18–19 Review Questions

6. Over time, a 70-year-old man has developed a progressive movement disorder in his left lower limb which affects his gait. He stumbles and tends to fall to the left when walking. His upper limb on the left shows signs of a tremor when he makes purposeful movements. Which of the following signs also can be seen in this patient?

A. Cogwheel rigidity
B. Motor ataxia
C. Sensory ataxia
D. Positive Babinski
E. Dysmetria

7. A patient develops movement disorders following a lesion to the output center of the basal ganglia. Which of the following project GABAergic neurons to the output center of the basal ganglia?

A. External segment of the globus pallidus
B. Striatum
C. VA nucleus of the thalamus
D. Substantia nigra
E. Subthalamic nucleus

8. Neurons that send axons to the cerebellum through the middle cerebellar peduncle have cell bodies in which of the following locations?

A. Spinal cord gray matter
B. Vestibular nuclei
C. Cerebral cortex
D. Inferior olivary nucleus
E. Deep cerebellar nuclei

Please visit us at www.Groupinsiders.com

© DeVry/Becker Educational Development Corp. All rights reserved.

Review Answers Chapters 18–19

1. The correct answer is D. The signs and symptoms shown by this patient are typical for a hemisphere lesion of the cerebellum. Cerebellar lesions are ipsilateral and present with an intention tremor, ataxia, and dysmetria, as indicated in this case.

2. The correct answer is B. The subthalamic nucleus is part of the indirect pathway of the basal ganglia, which serves to supress movement. The neurons of the subthalamus are excitatory (glutamate) and project to the internal segment of the globus pallidus.

3. The correct answer is B. The neurons of the striatum that project through the indirect pathway are GABA neurons that inhibit the external segment of the globus pallidus resulting in disinhibition of the subthalamic nucleus and excitation of the internal segment.

4. The correct answer is A. GABA neurons are found in both the putamen and the external segment of the globus pallidus.

5. The correct answer is D. The Purkinje axons of the cortex of the hemispheres project to the dentate nucleus. The dentate neurons then project to the contralateral VA/VL nuclei of the thalamus.

6. The correct answer is E. The patient demonstrates cerebellar hemisphere damage, which presents with symptoms as seen in this patient. In addition, dysmetria is commonly observed; the individual is not able to correctly judge distances and will miss the target.

7. The correct answer is B. The striatum projects GABA neurons to the output center (internal segment of the globus pallidus). These GABA neurons inhibit the internal segment, which results in disinhibition of the thalamus.

8. The correct answer is C. The middle cerebellar peduncle carries only afferent fibers to the hemisphere of the cerebellum. The cell bodies of these fibers are in the pons (corticopontocerebellar fibers).

Please visit us at www.Groupinsiders.com

© DeVry/Becker Educational Development Corp. All rights reserved.

Please visit us at www.Groupinsiders.com

1 Overview

Visual perception is one of the most important of all sensory functions, providing the ability to see images, shapes, colors, and moving structures. Visual processing begins with light entering through the cornea, pupil, lens, and the vitreous humor to reach the photoreceptors (rods and cones) in the retina. The neurons of the retina project to and relay in the thalamus, which then projects to the visual cortex.

2 Components of the Eyeball

The eye is composed of three layers, or coats (Figure 20–2.0):

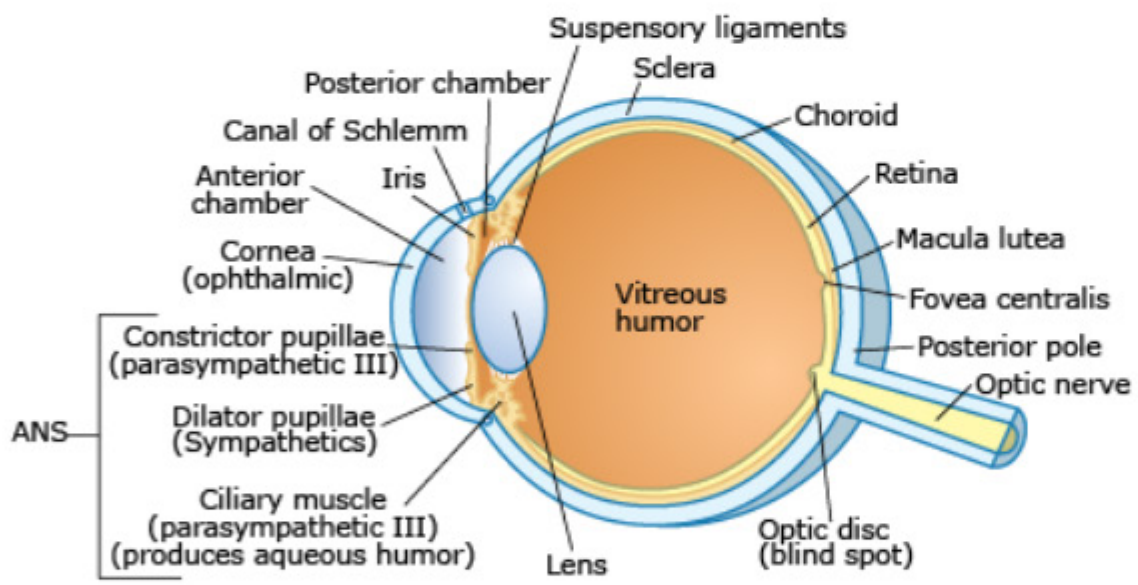

▲ **Figure 20–2.0** Structure of Eyeball

1. The *sclera*, the outermost layer, is composed of the fibrous connective tissue that gives the eye its shape and structure. The sclera also provides for the insertion of the ocular skeletal muscles. Anteriorly, the sclera becomes the transparent *cornea*, the main fixed refractive mechanism for bending light as it enters the eye. Sensory innervation of the cornea is provided by the opthalmic nerve.

USMLE® Key Concepts

For Step 1, you must be able to:

- Describe the basic structure of the eyeball.
- Explain the neural circuits and lesions of the pupillary light reflex.
- Identify the visual pathways and the visual field defects caused by lesions of the visual circuits.

© DeVry/Becker Educational Development Corp. All rights reserved.

2. The *choroid* is the middle or vascular layer. Anteriorly, it becomes the *ciliary body* and the *iris*. The ciliary body actively secretes aqueous humor and contains the *ciliary muscle*. The ciliary muscle is innervated by the parasympathetic fibers of CN III, which is involved in changing the shape and thickness of the lens during accommodation.

   The *lens* also functions in bending the light rays and is important in focusing, because its shape can be changed, resulting in different refractive powers. The lens is connected to the ciliary muscle by the suspensory ligaments. Contraction of the ciliary muscle relaxes the suspensory ligaments, allowing the natural elasticity of the lens to round and thicken for close vision.

   The *pupil* is the opening of the iris. Its size is regulated by two smooth muscles: the *dilator pupillae muscle* (innervated by sympathetics) and the *constrictor pupillae muscle* (innervated by the parasympathetic fibers of CN III).

   The *anterior and posterior chambers* of the eye are located anterior and posterior to the iris and contain aqueous humor that is produced by the ciliary body in the posterior chamber. Aqueous humor drains out of the anterior chamber through the canal of Schlemm. Increased pressure in the chamber produces *glaucoma*, which usually occurs due to a blockage of drainage at the canal of Schlemm.

3. The *retina* is multilayered and forms the innermost component of the wall of the eye, housing the receptors and cells involved in the beginning of the visual pathway. Light rays pass through the transparent layers of the retina to reflect off the pigmented epithelial layer of the retina back onto the photoreceptors: *rods* and *cones*.

   Rods function in dim light and night vision. Cones function in color vision and for high visual acuity. Hyperpolarization of the rods and cones sends signals to the *bipolar cells*, which synapse with the *ganglionic cells* of the retina. The ganglionic axons leave the retina at the optic disc to form the optic nerve. Both the retina and optic nerve develop from *neuroectoderm* of the neural tube, and the optic nerve is myelinated by *oligodendrocytes*.

   Lateral to the optic disc is a yellowish spot on the retina called the *macula lutea*. At the center of the macula there is a depression and thinning of the retina called the *fovea centralis*, which contains cone photoreceptors only. This area of the retina has the highest visual acuity.

Please visit us at www.Groupinsiders.com

© DeVry/Becker Educational Development Corp. All rights reserved.

3 Pupillary Light Reflex

The *pupillary light reflex* (Figure 20–3.0) occurs when light is shone into one eye, resulting in constriction of both pupils: *direct* and *consensual light reflex*. As a reflex, there are sensory and motor components.

Afferent Limb: CN II

CNII projects light to the **pretectal nuclei** (midbrain)

The pretectal nucleus projects **bilaterally** to the **Edinger-Westphal nuclei (CN III)**

Efferent Limb: CN III

Edinger-Westphal nucleus (preganglionic parasympathetic) projects to **ciliary ganglion** (postganglionic parasympathetic) projects to **pupillary sphincter muscle = miosis**

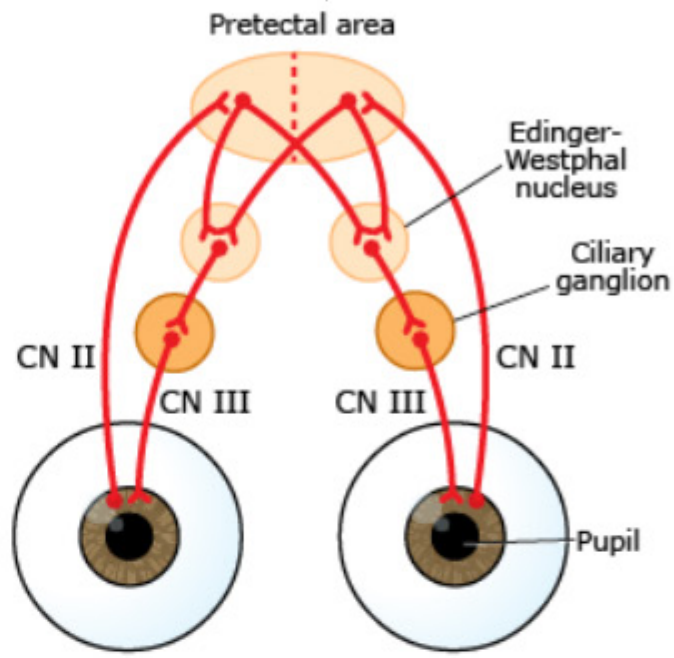

Because cells in the pretectal area supply the Edinger-Westphal nuclei bilaterally, shining light in one eye results in constriction in the ipsilateral pupil (direct light reflex) and the contralateral pupil (consensual light reflex).

Because this reflex does not involve the visual cortex, a person who is cortically blind can still have this reflex.

▲ **Figure 20–3.0** Pupillary Light Reflex

3.1 Afferent Limb: Optic Nerve and Pretectal Region

- Light stimulates ganglionic axons of the optic nerve. A small percentage of the axons of the optic nerve projects to the pretectal nuclei on the dorsal midbrain.
- Pretectal nuclei project *bilaterally* to both *Edinger-Westphal nuclei* of the midbrain.

3.2 Efferent Limb: Edinger-Westphal Nucleus and Parasympathetic Fibers

- Each *Edinger-Westphal nucleus* contains preganglionic parasympathetic cell neurons of CN III that project to the ciliary ganglion.
- The *ciliary ganglion* contains postganglionic cell neurons that project to the sphincter pupillae muscle and constriction of both pupils via CN III.

Please visit us at www.Groupinsiders.com

© DeVry/Becker Educational Development Corp. All rights reserved.

4 Accommodation Reflex

The *accommodation reflex* is the process that occurs when an individual focuses on a near object after shifting gaze from a distant object. The three components of the accommodation reflex are all mediated by CN III: convergence, pupillary constriction, and thickening of the lens.

- *Convergence* is the contractions of both medial recti muscles that adduct both eyes medially toward the nose. Convergence allows the image to fall on the same point on each retina.
- *Thickening of the lens (accommodation)* results from contraction of the ciliary muscle, which relaxes the suspensory ligaments of the lens and allows its natural elasticity to thicken.
- *Pupillary constriction* results from contraction of the constrictor pupillae muscle, which narrows the opening of the iris, improves optical performance, and increases depth of focus.

Clinical Application

A summary of some of the major clinical applications is shown in Table 20–5.0.

▼Table 20–4.0 Vision Abnormalities

Syndrome	Clinical Characteristics
Horner syndrome	• It is caused by a lesion of the sympathetic pathways (CNS and PNS) to the head and neck. • Clinical features of the syndrome include ipsilateral ptosis, anhydrosis, flushing of skin, and miosis.
Argyll Robertson pupil	• A pupil that accommodates to near objects but does not react to light. • Seen in syphilis, systemic lupus erythematosus (SLE), and diabetes mellitus.
Marcus Gunn pupil (afferent defect)	• It is caused by a deficit in the afferent portion of the light reflex pathway. • Shining a light in the affected pupil causes paradoxical dilation of the pupils.
MLF syndrome	• Caused by a lesion of the MLF and can be unilateral or bilateral. • Clinical features: –The ipsilateral eye (the eye on the side of the MLF lesion) is unable to adduct, and the contralateral eye (the opposite eye) has nystagmus. For example, in the cases of right MLF lesions, the right eye is unable to adduct and the left eye has nystagmus when looking left. –Convergence is unaffected. • Often seen in multiple sclerosis (MS).

Please visit us at www.Groupinsiders.com

© DeVry/Becker Educational Development Corp. All rights reserved.

5 Histology of the Retina

The major cell types and neural circuitry of the retina are shown in Figure 20–5.0.

Important Concept

Cones:

- High visual acuity
- Color vision

Rods:

- Night vision
- Dim light vision

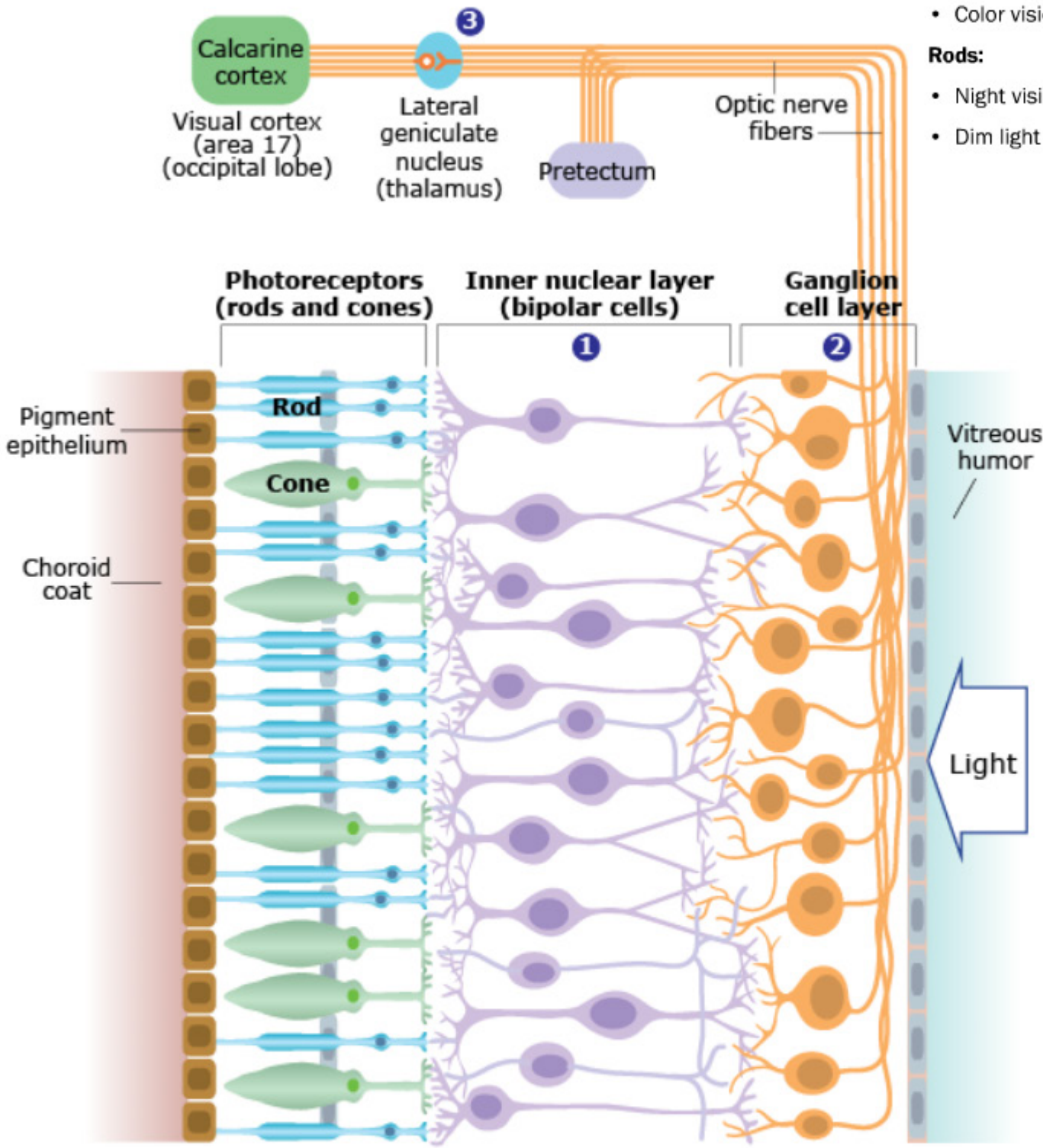

▲ **Figure 20–5.0** Histology of the Retina

Please visit us at www.Groupinsiders.com

© DeVry/Becker Educational Development Corp. All rights reserved.

6 Visual Pathway

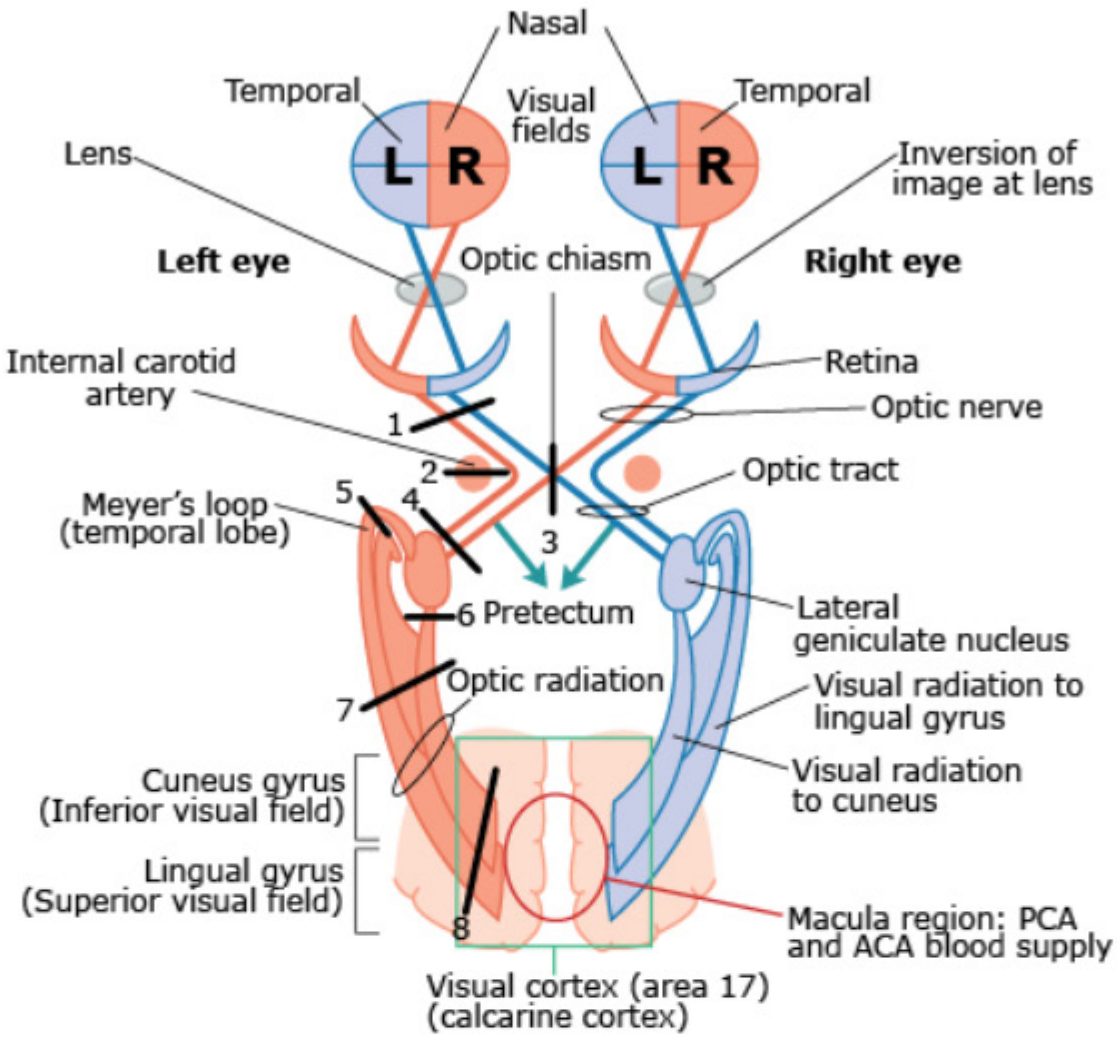

	Defects: Visual Fields	Lesions
Before chiasm: Ipsilateral, monocular	1. Anopia of left eye	M.S.; vascular
	2. Left nasal hemianopia	Internal carotid artery aneurysm
Midline chiasm: Bitemporal, binocular, heteronymous	3. Bitemporal heteronymous hemianopia	Tumor; vascular
(No. 4 will have abnormal pupillary testing)	4/7. Right homonymous hemianopia	Vascular
Past chiasm: Contralateral, binocular, homonymous	5. Right homonymous superior quadrantanopia	Vascular (MCA)
	6. Right homonymous inferior quadrantanopia	Vascular (PCA)
	8. Right homonymous hemianopia with macular sparing	Vascular (PCA)

Important Concept

1. The image is inverted at the lens.
2. **Partial decussation (60%) at the optic chiasm:**
   - Nasal fibers decussate.
   - Temporal fibers do not decussate.
3. **Rule of L—superior quadrant visual fields**

Superior quadrant projections course **laterally** through Meyer **loop** into the **lingual** gyrus of the cortex.

▲ **Figure 20–6.0** Visual Pathways

Please visit us at www.Groupinsiders.com

© DeVry/Becker Educational Development Corp. All rights reserved.

- Light images from the temporal and nasal visual fields pass through the lens, where the images are inverted to the contralateral side of the retina, as in a camera. Thus, nasal visual fields invert to the temporal side of the retina, and vice versa.
- The images pass through the layers of the retina to reach the pigmented epithelial layer of the retina, where the light rays bounce onto the rods and cones. Visual impulses are generated at the rods and cones, and course in an opposite direction from the light rays.
- The visual impulses from the rods and cones project to the bipolar cells (primary or first-order neurons of the visual pathway), which project to the ganglionic neurons (second-order neurons). The axons of the ganglionic cells in the retina collect at the optic disc, become myelinated by oligodendrocytes, and exit the eyeball as the *optic nerve*. The two optic nerves reach the *optic chiasm*.
- There is a *partial decussation* (60%) of visual field fibers at the *chiasm*. Temporal retinal fibers do not decussate, and pass through the chiasm to the ipsilateral optic tract and lateral geniculate body of the thalamus. The nasal retinal fibers decussate to the contralateral optic tract and thalamus. Because of the partial decussation, all visual field pathways that pass the chiasm are *contralateral*.
- A few fibers in the optic tract do not reach the thalamus, and project to the pretectal nuclei for the light reflex. Some fibers also project to the superior colliculi and hypothalamus.
- The *lateral geniculate body of the thalamus* contains the third-order neurons of the visual pathway. These axons leave the thalamus and form the *geniculocalcarine tract (optic or visual radiations)*, which projects initially through the internal capsule, then through the parietal lobe, and finally to the visual cortex (calcarine cortex, area 17) of the occipital lobe.
- Visual impulses representing superior and inferior quadrants of the visual fields are located in different parts of the optic radiations.
  - The more lateral fibers of the optic radiation carry images from the *contralateral superior quadrant visual fields* and route around the lateral ventricle in the temporal lobe (called *Meyer loop*) and terminate in the lower bank of the visual cortex, the *lingual gyrus*.
  - The more medial fibers of the optic radiation course medially in the parietal lobe, carrying images from the *contralateral inferior quadrant visual field* and terminate in the *cuneus*, on the upper bank of the visual cortex.
- Within the cortex, the macula of the retina is represented in the central, posterior area of the right and left striate cortex.

Please visit us at www.Groupinsiders.com

© DeVry/Becker Educational Development Corp. All rights reserved.

7 Visual Field Defects

7.1 Lesions Before the Optic Chiasm (Ipsilateral and Monocular)

- Optic Nerve (trauma, vascular occlusion, optic neuritis)
  - Causes *total blindness (anopsia)* in the ipsilateral eye.
  - Absence of the sensory limb of the pupillary light reflex.
- *Pressure on Lateral Side of the Chiasm* (internal carotid artery aneurysm)
  - Compresses the outer, non-decussating fibers of the chiasm and results in *ipsilateral nasal hemianopia*.

7.2 Lesions at the Midline of the Optic Chiasm (Binocular, Bitemporal, Heteronymous)

- Complete midline compression of the chiasm (pituitary tumors, craniopharyngiomas, aneurysms)
  - Compresses the decussating fibers from each nasal retina, resulting in *bitemporal heteronymous hemianopia*. *Heteronymous* indicates loss of different visual fields in each eye.

7.3 Lesions Past the Chiasm (Binocular, Contralateral, Homonymous)

- *Optic Tract and Optic Radiation* (vascular lesions)
  - Lesions at either of these two sites produce *contralateral homonymous hemianopia*.
  - Homonymous indicates loss of the same visual fields in each eye.
  - Can differentiate between these two lesions with the pupillary light test. With a tract lesion, the patient has abnormal pupillary testing, whereas with a lesion of the optic radiation, the patient has normal pupillary light testing.
- *Lateral Fibers (Meyer Loop) of Optic Radiation in Temporal Lobe (temporal lobe tumor and vascular lesion of middle cerebral artery)*
  - These fibers represent the contralateral superior quadrant visual fields.
  - Lesion produces a *contralateral homonymous superior quadrantanopia*.
- *Medial Fibers of Optic Radiation in Parietal Lobe (vascular)*
  - These fibers represent the contralateral lower visual quadrant visual fields.
  - Lesions produce a *contralateral homonymous inferior quadrantanopia.*

7.4 Lesions at the Visual Cortex (Binocular, Contralateral, Homonymous, With Macular Sparring)

Visual (calcarine) cortex lesions demonstrate macular sparring because the macular region of the cortex has dual blood supply: the posterior cerebral artery and collateral circulation from the middle cerebral artery.

Please visit us at www.Groupinsiders.com

© DeVry/Becker Educational Development Corp. All rights reserved.

Chapter 20 Review Questions

1. An ophthalmological exam and an MRI reveal that a patient has suffered a stroke in the artery that supplies the left optic tract. Which of the following visual symptoms would be expected in this patient?

A. Right superior quadrantanopia
B. Right homonymous hemianopia
C. Left superior quadrantanopia
D. Bitemporal hemianopia
E. Left nasal hemianopia

2. During a pupillary light reflex exam, the physician notes that when light is shown in the left eye there is constriction of the left pupil but not of the right eye. But when light is shown in the right eye, there is constriction of the left pupil but the right pupil does not constrict. The lesion is found in which of the following locations?

A. Right optic nerve
B. Left optic nerve
C. Left visual cortex
D. Right oculomotor nerve
E. Left lateral geniculate nucleus

3. A 68-year-old man is admitted to the hospital with some memory loss and visual problems. An MRI shows that he has a tumor compressing the right temporal lobe. Which of the following would best describe the visual deficits observed in the patient?

A. Right inferior quadrantanopsia
B. Left homonymous hemanopsia
C. Right inferior quadrantanopsia
D. Left superior quadrantanopsia
E. Right homonymous hemanopsia

4. An older man wakes up with a headache and cannot see anything to his left with either eye. A visual field test shows a hemianopia with no macular sparing. His light reflexes are normal in both eyes. The lesion most likely would be located at which of the following?

A. Optic radiations
B. Meyer loop
C. Cuneus gyrus
D. Optic tract
E. Lingual gyrus

5. An elderly man is diagnosed with blindness in the left eye caused by damage of the cell bodies that give rise to the fibers in the optic nerve. Which of the following are the damaged neurons?

A. Thalamic cells
B. Rod cells
C. Cone cells
D. Bipolar cells
E. Ganglionic cells

Please visit us at www.Groupinsiders.com

© DeVry/Becker Educational Development Corp. All rights reserved.

Review Answers Chapter 20

1. The correct answer is B. Visual field pathways past the chiasm are contralateral and homonymous. Thus, a left optic tract lesion results in a right homonymous hemianopia. Because this is a tract lesion, the patient would demonstrate abnormal pupillary light reflex testing.

2. The correct answer is D. Because there was a pupillary response after shining the light in both eyes, the optic nerve is intact on both sides. But because the right eye did not respond with testing in either eye, a motor lesion of the right oculomotor nerve is indicated.

3. The correct answer is D. The temporal lobe tumor will result in memory deficits (parts of the limbic system) and damage to the Meyer loop of the visual pathway. Meyer loop fibers leave the thalamus and take a lateral course through the temporal lobe. The fibers in the loop are contralateral superior quadrant visual fields and a lesion of these fibers in the right temporal lobe will produce left superior quadrantanopsia.

4. The correct answer is A. The patient demonstrates left homonoymous hemianopia. Because there was normal pupillary light testing in both eyes and there was no macular sparing, the lesion would be localized in the optic radiation.

5. The correct answer is E. The axons of the ganglionic cells of the inner layer of the retina leave the eyeball at the optic disc and project through the optic nerve, chiasm, and tract to reach the lateral geniculate nucleus of the thalamus.

Please visit us at www.Groupinsiders.com

© DeVry/Becker Educational Development Corp. All rights reserved.

1 Divisions of the Diencephalon

The *diencephalon* has many diverse functions involving connections with motor, sensory, and limbic pathways. The diencephalon is divided into four components, each including the term *thalamus* (Figure 21–1.0):

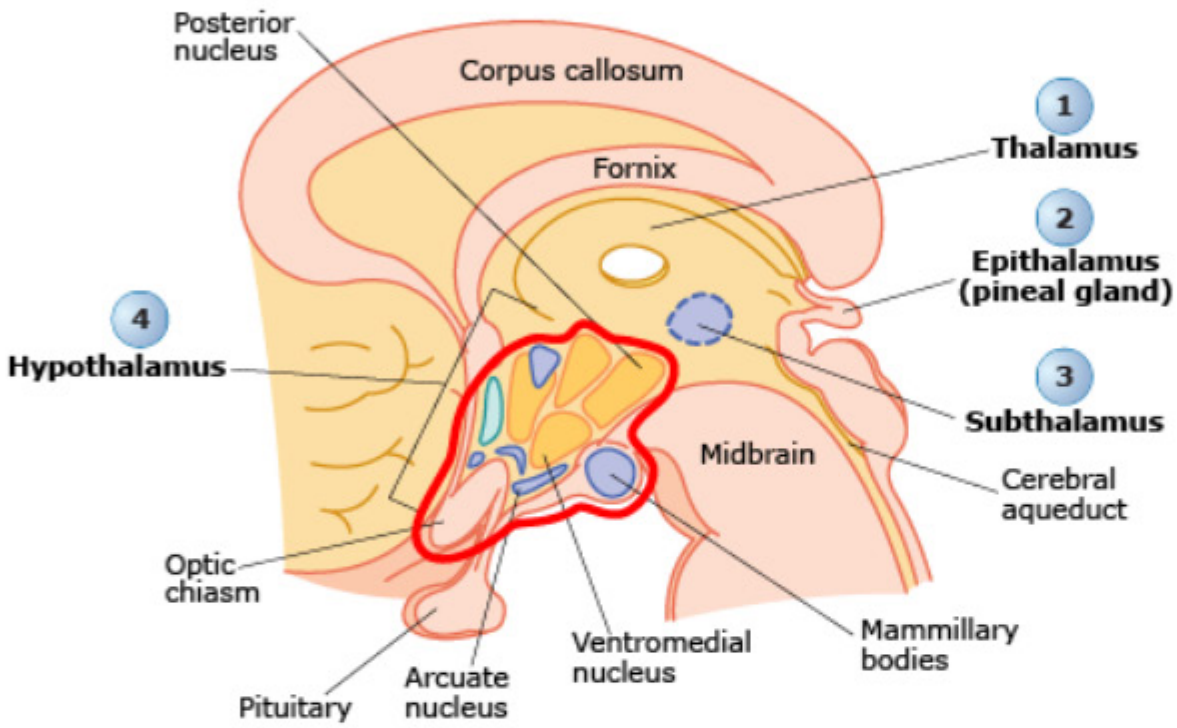

▲ **Figure 21–1.0** Diencephalon

USMLE® Key Concepts

For Step 1, you must be able to:

- Identify the four basic divisions of the diencephalon and their locations.
- List the names of the thalamic nuclei and their functions.
- Describe the basic organization and functions of the nuclei of the hypothalamus.
- Explain the clinical deficits seen in Parinaud syndrome.

1.1 Thalamus

The *thalamus* is an egg-shaped, oval nuclear mass that forms the largest component of the diencephalon (Figure 21–1.1). It is a major sensory relay nuclear system that receives input from most of the major sensory pathways except for the olfactory system, which does not relay through it. The thalamus contains a variety of sensory and motor nuclei that relay information from different areas of the CNS to the cerebral cortex. It projects primarily to the cerebral cortex, with some fibers projecting to the basal ganglia and the hypothalamus. There are two *motor relay nuclei* that process motor pathways from the cerebellum and basal ganglia.

The major nuclei of the thalamus, their functions, and connections are outlined in Table 21–1.1.

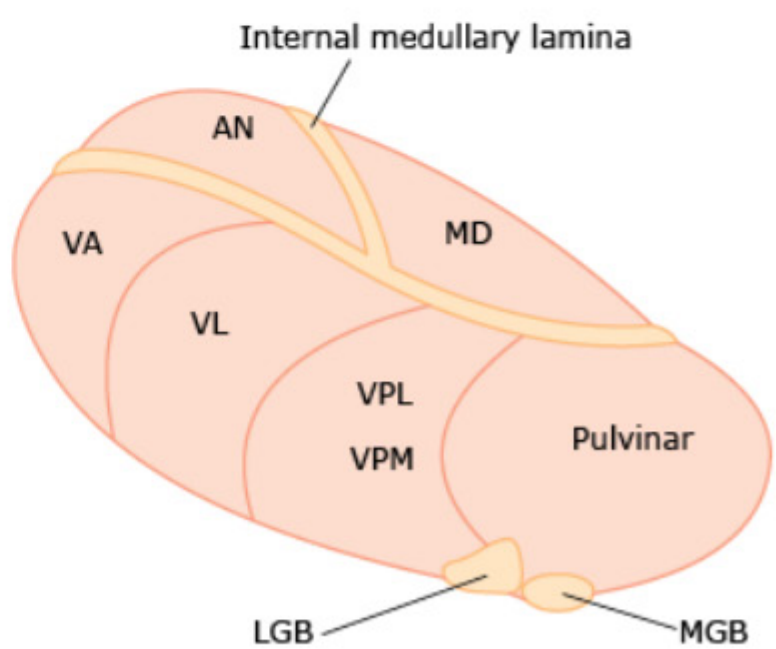

▲ **Figure 21–1.1** Thalamus

Please visit us at www.Groupinsiders.com

© DeVry/Becker Educational Development Corp. All rights reserved.

▼Table 21–1.1 The Various Thalamic Nuclei, Their Nervous Connections, and Their Functions

Thalamic Nucleus	Afferent Neuronal Loop	Efferent Neuronal Loop	Function
Ventral posterolateral (VPL)	Trunk and limbs	Somatosensory (areas 3, 1, and 2) cortex	Relays general sensations
Ventral posteromedial (VPM)	Trigeminal from face; gustatory fibers	Somatosensor (areas 3, 1, and 2) cortex	Relays general sensations
Ventral anterior Ventral lateral	Basal ganglia and cerebellum	Premotor cortex	Influences activity of motor cortex
Medial geniculate body	Auditory from inferior calliculus	Auditory radiation to superior temporal gyrus	Hearing
Lateral geniculate body	Visual from optic tract	Optic radiation to visual cortex of occipital lobe	Visual information from opposite field of vision
Dorsomedial	Prefrontal cortex	Prefrontal cortex	Integration of somatic, visceral, and olfactory information and memory
Anterior	Mammillothalamic tract	Cingulate gyrus	Emotional tone, mechanisms of recent memory
Intralaminar Midline	Reticular formation, spinothalamic and trigeminothalamic tracts	To cerebral cortex via other thalamic nuclei, corpus striatum	Influences levels of consciousness and alertness

1.2 Epithalamus (Pineal Gland)

The *epithalamus* is composed of the pineal gland and habenular nuclei. The *pineal gland* is an endocrine gland located on the dorsal midline of the diencephalon immediately superior to the superior colliculi. The gland plays a role in regulating circadian rhythms (dark-light cycles). Highly vascular, the pineal gland contains specialized secretory cells called *pinealocytes*, which produce melatonin, serotonin, and norepinephrine.

Clinical Application

Parinaud Syndrome

Parinaud syndrome is a dorsal lesion of the midbrain at the level of the superior colliculus, usually due to a pineal tumor. The tumor involves the pretectal area on either side of the pineal gland at the superior colliculus and the sylvian aqueduct in the midbrain.

The patient has a weakness of upward gaze (sunset eyes at rest), pupillary light reflex abnormalities, and noncommunicating hydrocephalus.

Please visit us at www.Groupinsiders.com

© DeVry/Becker Educational Development Corp. All rights reserved.

1.3 Hypothalamus

The *hypothalamus* is relatively small, but contains many important nuclei that provide many diverse functions (Figures 21–1.3A and 21–1.3B). These nuclei have extensive afferent and efferent connections with other areas of the nervous system.

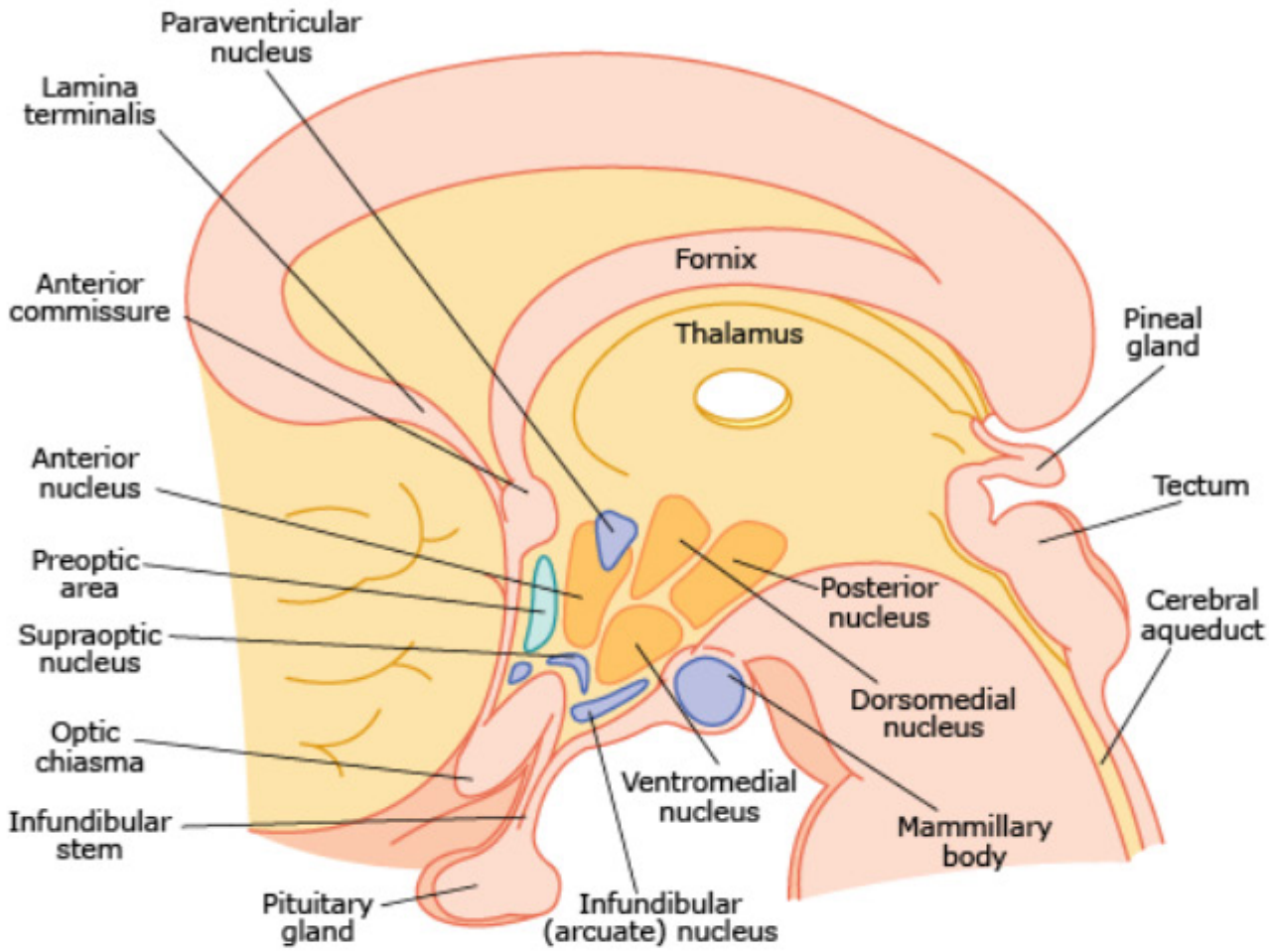

▲ **Figure 21–1.3A** Hypothalamus

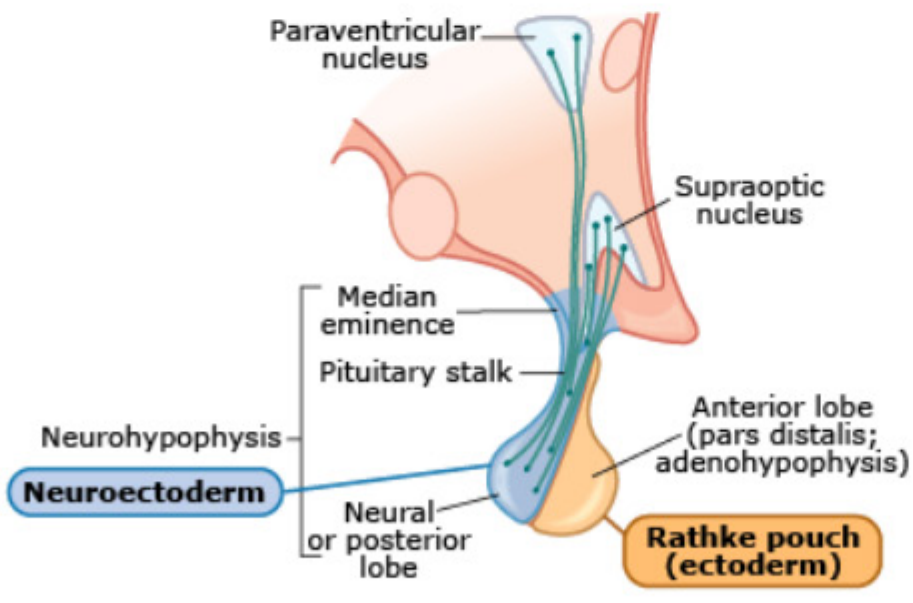

▲ **Figure 21–1.3B** Development of Pituitary Gland

Please visit us at www.Groupinsiders.com

© DeVry/Becker Educational Development Corp. All rights reserved.

- The hypothalamus promotes homeostasis and controls visceral activity of the *endocrine system, autonomic nervous system, and limbic system* (including endocrine functions of the pituitary gland, sympathetic and parasympathetic systems, temperature regulation, sexual functions, circadian rhythms, and feeding and drinking behavior).
- The major nuclei of the hypothalamus are the *preoptic, supraoptic, paraventricular, ventromedial, suprachiasmatic, dorsomedial, acruate, tuberal,* and *mammillary bodies.* The major nuclei and their functions are organized in Table 21–1.3.

▼Table 21–1.3 Functions of the Main Hypothalamic Nuclei

Hypothalamic Nucleus	Function
Supraoptic nucleus	Synthesizes vasopressin (antidiuretic hormone)
Paraventricular nucleus	Synthesizes oxytocin
Arcuate nucleus	Forms releasing and inhibitory factors that influence the anterior pituitary
Anterior nuclei	Control parasympathetic system Regulate temperature (response to heat)
Posterior nuclei	Control sympathetic system Regulate temperature (response to cold)
Lateral nuclei	Initiate eating and increase food intake (hunger center) Increase water intake (thirst center)
Medial nuclei	Inhibit eating and reduce food intake (satiety center)
Suprachiasmatic nucleus	Controls circadian rhythms

1.4 Subthalamus

The role of the *subthalamus* in the indirect pathway of the basal ganglia was discussed earlier. A subthalamic lesion produces contralateral hemiballismus.

Please visit us at www.Groupinsiders.com

© DeVry/Becker Educational Development Corp. All rights reserved.

1 Overview

The *cerebral cortex* is the most highly developed area of the CNS. The surface of the cortex has extensive foldings and convolutions into ridges called *gyri* with grooves between the gyri called *sulci*. The gyri increase the total cortical surface area. *Brodmann areas* give a numerical designation to various functional areas of the cortex. A few of the Brodmann areas are important and will be discussed further. Note that most of the motor and sensory functions of the cortex are projected to the contralateral side of the body.

2 Surface Features of the Cortex

2.1 Lateral Surface of the Cortex

On the lateral surface of the cortex, there are two prominent fissures that help demarcate the lobes of the brain (Figure 22–2.1).

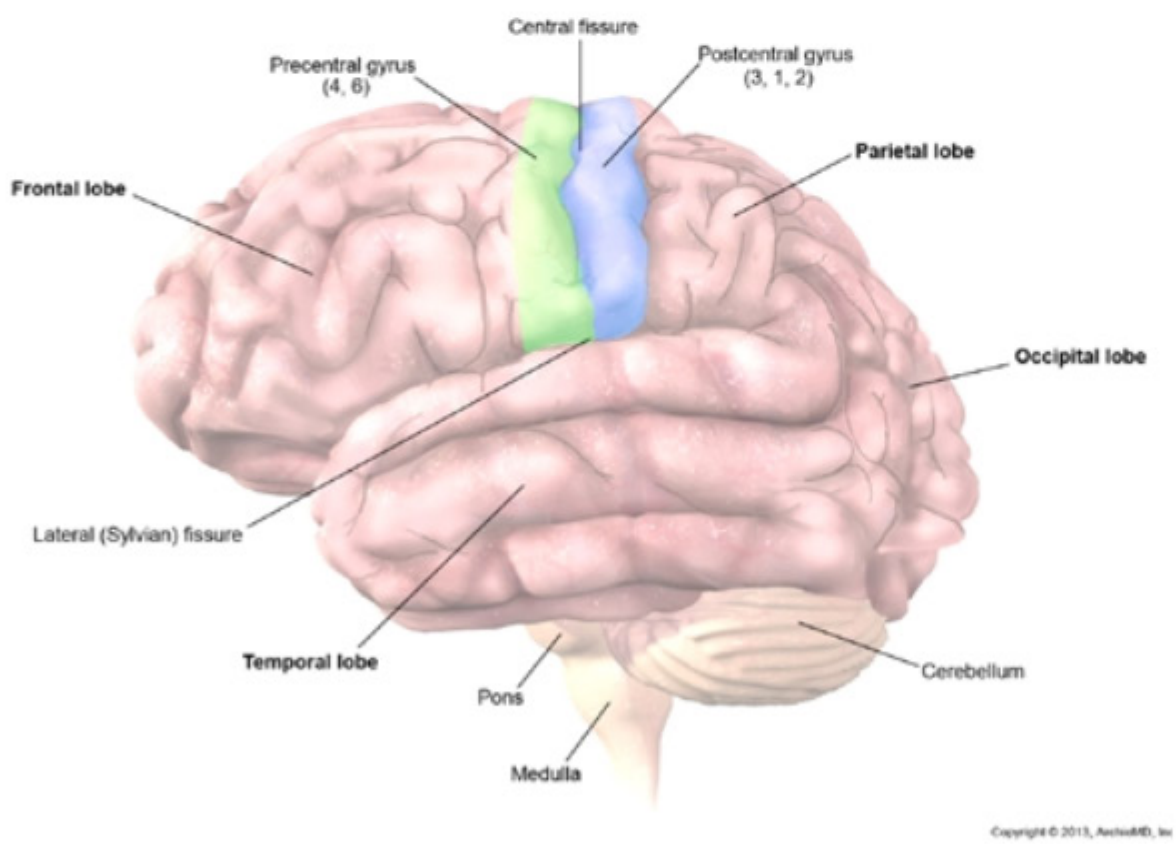

▲ **Figure 22–2.1** Lateral View of Cortex

USMLE® Key Concepts

For Step 1, you must be able to:

- Identify the major surface features and the four major divisions on the lateral and medial surfaces of the cortex.
- Describe the relationship of the cortical surface to the homunculus.
- List the vascular distributions of the anterior, middle, and posterior cerebral arteries supplying the brain and their contributions to the formation of the circle of Willis.
- Explain the distribution of the internal carotid artery on an angiogram.
- Identify the major functional strips on the surface of the cortex and relate them to normal function and lesions.
- Distinguish the characteristics of the primary language disorders and note the location of their associated lesions.
- Describe the structure and location of the internal capsule and what neural pathways course through the genu and posterior limb of the capsule.

Please visit us at www.Groupinsiders.com

© DeVry/Becker Educational Development Corp. All rights reserved.

1. The *central fissure (of Rolando)* is a major landmark that extends almost vertically from the upper margin of the cortex to the lateral sulcus. The central sulcus separates the primary motor cortex of the *frontal lobe* anterior to the sulcus from the somatosensory cortex of the *parietal lobe* posterior to the sulcus.
2. The *lateral fissure (of Sylvius)* extends almost horizontally, separating the frontal and parietal lobes above the sulcus from the *temporal lobe* below the sulcus. The *occipital lobe* forms the posterior pole of the brain and borders the parietal and temporal lobes.

2.2 Medial Surface of the Cortex

On the medial surface of the cortex (Figure 22–2.2), the central sulcus is visible, separating the frontal and parietal lobes. The premotor strip of frontal lobe and the somatosensory strip of parietal lobe are located immediately anterior and posterior to the central sulcus, respectively, and are known as the *paracentral lobule*. The paracentral lobule provides the motor and sensory innervations for the *contralateral lower limbs and pelvis*.

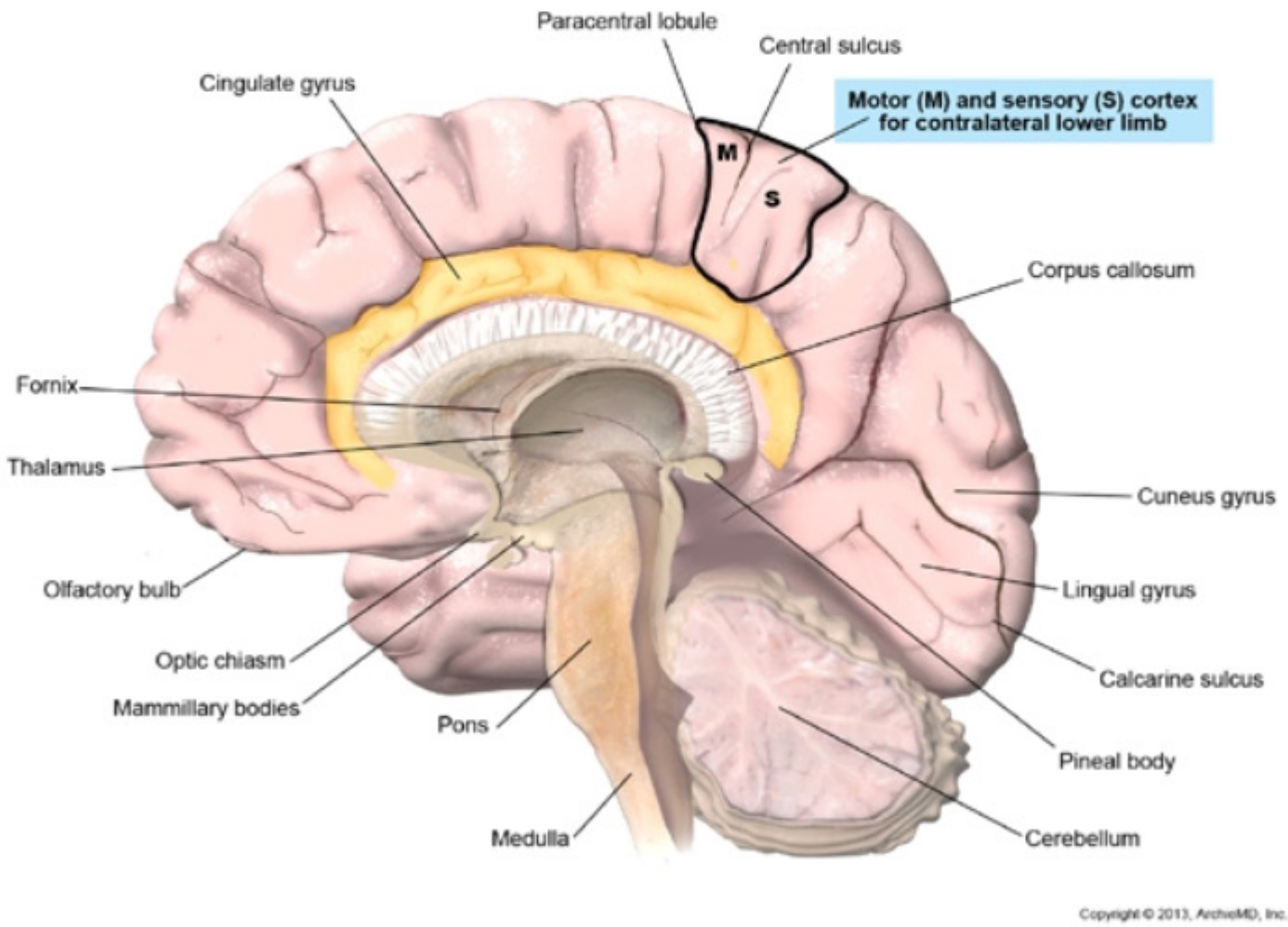

▲ **Figure 22–2.2** Medial View of Cortex

The occipital lobe is more clearly seen on the medial surface. The *calcarine sulcus* is a prominent fissure that divides the occipital lobe into a dorsal cuneus gyrus and a ventral lingual gyrus.

The *corpus callosum* forms a large, C-shaped fiber bundle that connects the two hemispheres. It is subdivided into a rostral head, body, and a caudal splenium. Dorsal to the corpus callosum is the cingulate gyrus, a part of the limbic system.

Please visit us at www.Groupinsiders.com

© DeVry/Becker Educational Development Corp. All rights reserved.

3 Somatotopic Regions of the Cortex: Homunculus

Different parts of the cortex are associated functionally and anatomically with specific parts of the body. This somatotopic relationship is indicated by the homunculus (Figure 22–3.0). The *homunculus* is a map of the contralateral half of the body lying over the lateral and medial surfaces of the cortex. On the lateral surface, the head and neck region is represented closest to the lateral sulcus. Farther up lies the area for the upper limb, with the trunk represented most dorsally. On the medial surface of the cortex, the lower limb and pelvis are represented. These relationships are shown in Figures 22–3.0 and 22–4.0.

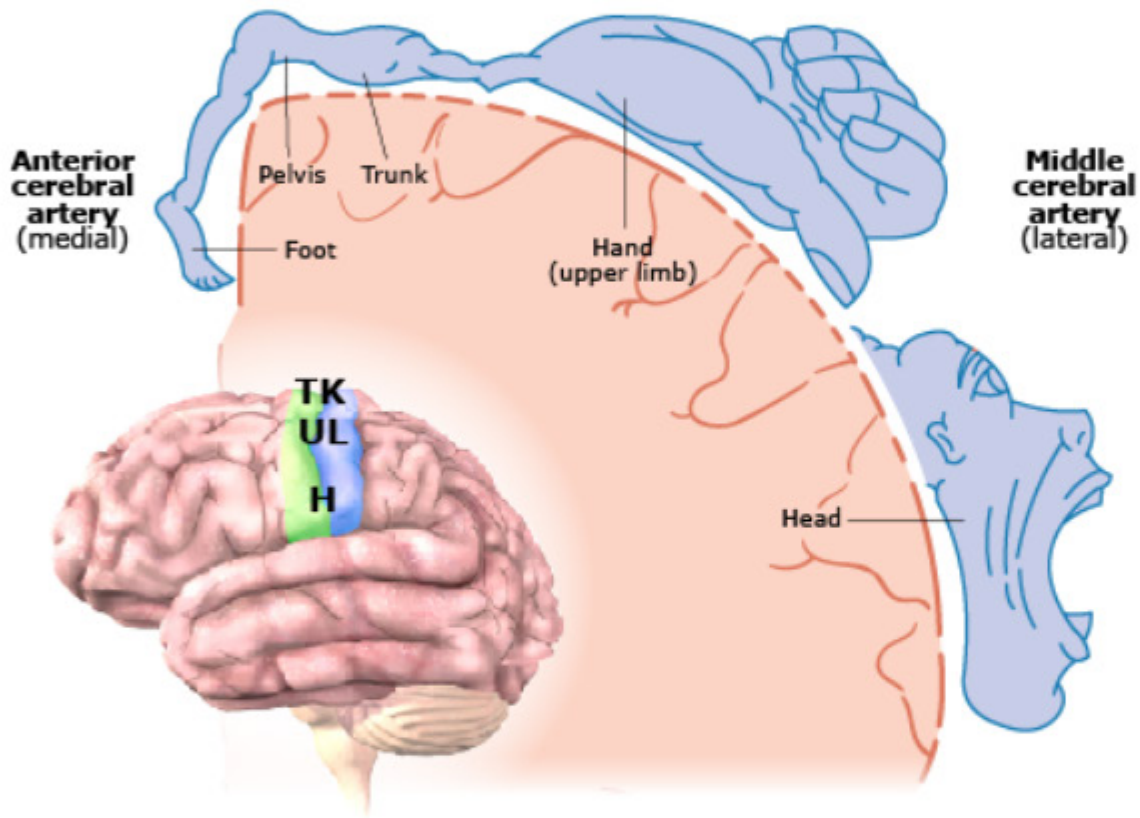

▲ **Figure 22–3.0** Motor Homunculus

Please visit us at www.Groupinsiders.com

© DeVry/Becker Educational Development Corp. All rights reserved.

4 Cell Layers of the Cortex

The cellular organization of the cortex is arranged in six layers (Figure 22–4.0), named according to the cell types that are most prominent in that layer. Layers IV and V are particularly significant. Layer IV is the internal granule layer and receives most of the sensory inputs from the thalamus to the cortex. Layer V is the internal pyramidal layer and contains the large pyramidal cells (of Betz) whose axons form the corticospinal and corticobulbar tracts.

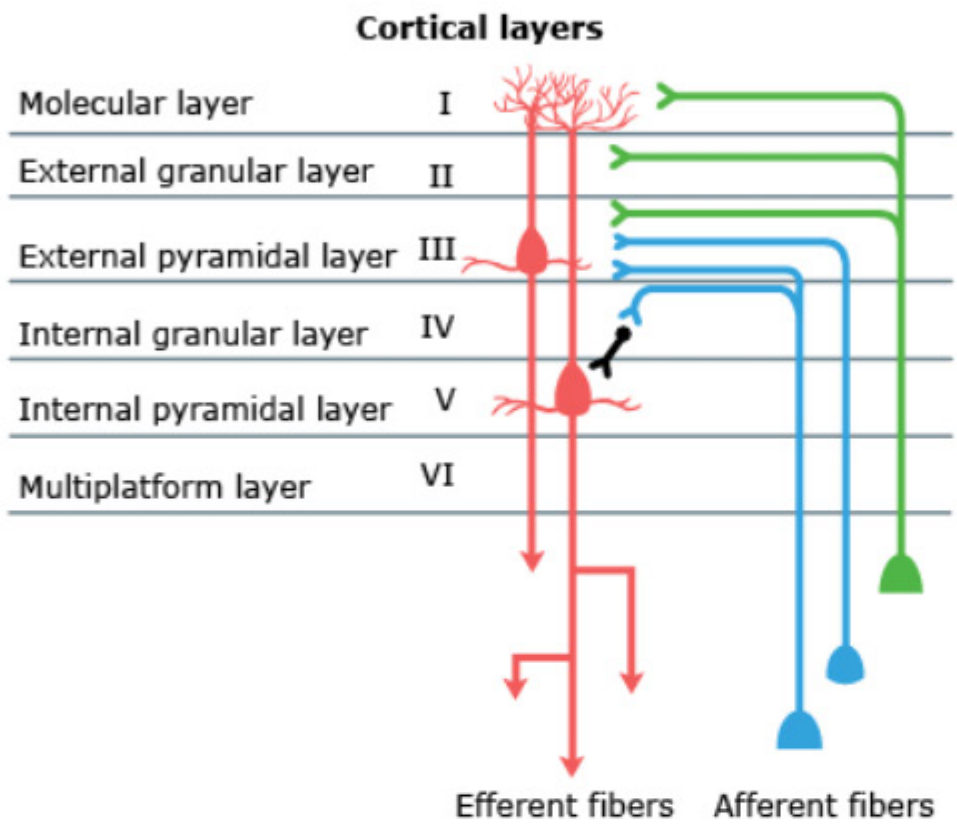

▲ **Figure 22–4.0** Cortical Axons

Clinical Application

Thalamic sensory projections terminate in the internal granular layer (IV).

Upper motor neurons of CST and CBT originate in the internal pyramidal layer (V).

Please visit us at www.Groupinsiders.com

© DeVry/Becker Educational Development Corp. All rights reserved.

5 Blood Supply of the Cortex

The blood supply of the cortex is provided by two sources: (1) the paired internal carotid arteries and (2) the paired posterior cerebral artery, a branch of the basilar artery (Figures 22–5.0A, 22–5.0B, 22–5.0C, 22–5.0D, and 22–5.0E).

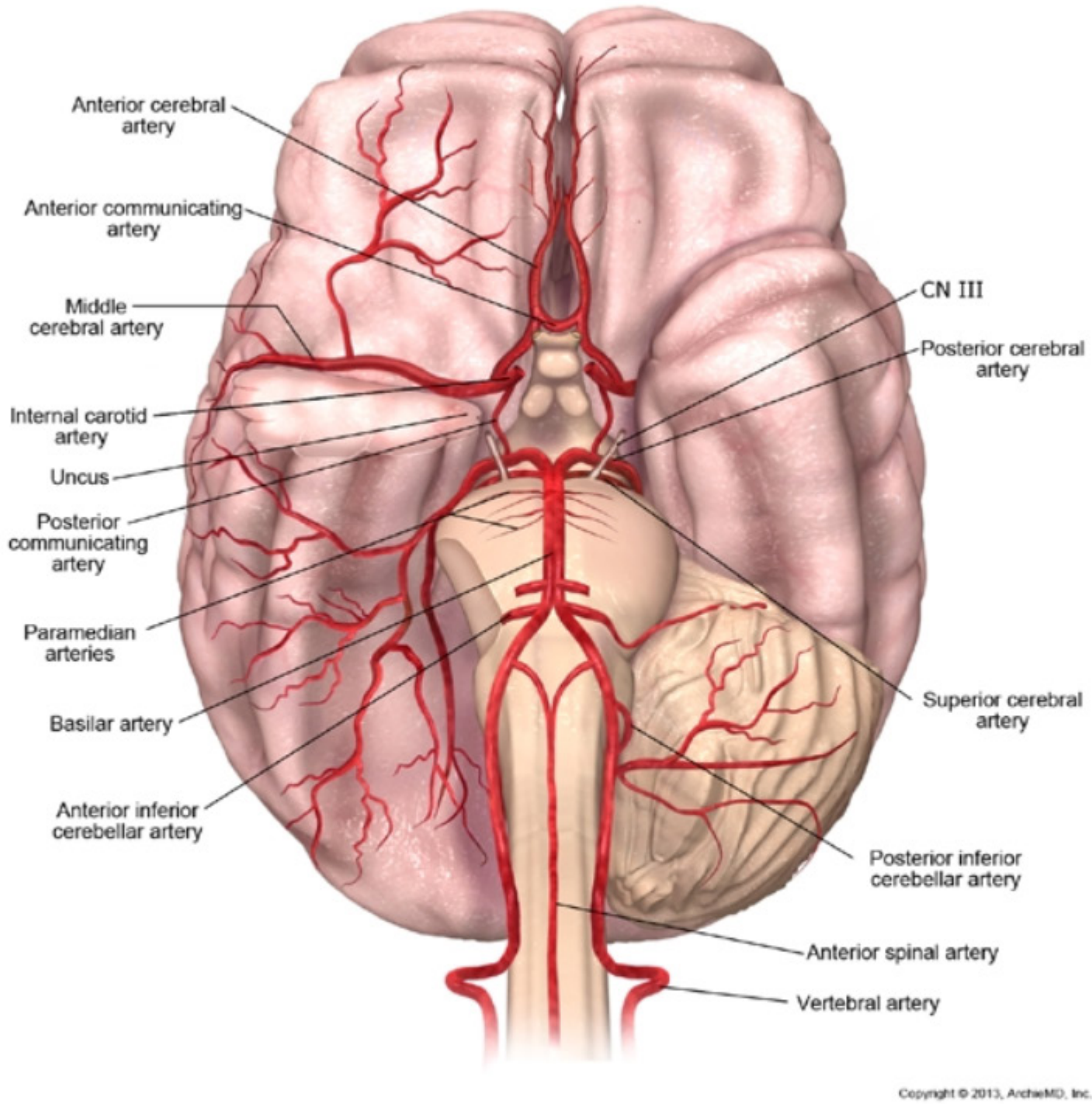

▲ **Figure 22–5.0A** Blood Supply to Brain

Please visit us at www.Groupinsiders.com

© DeVry/Becker Educational Development Corp. All rights reserved.

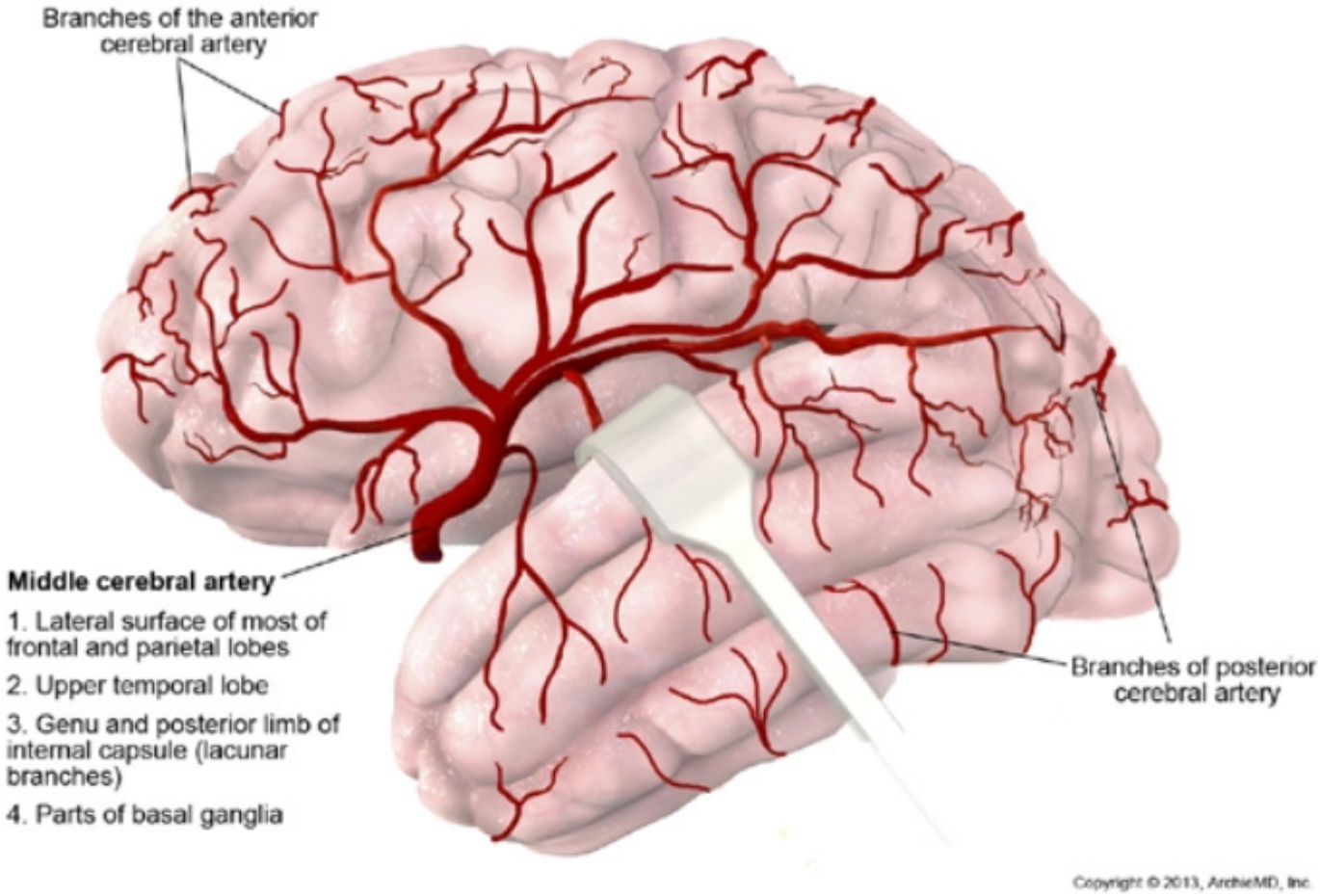

▲ **Figure 22–5.0B** Distribution of MCA

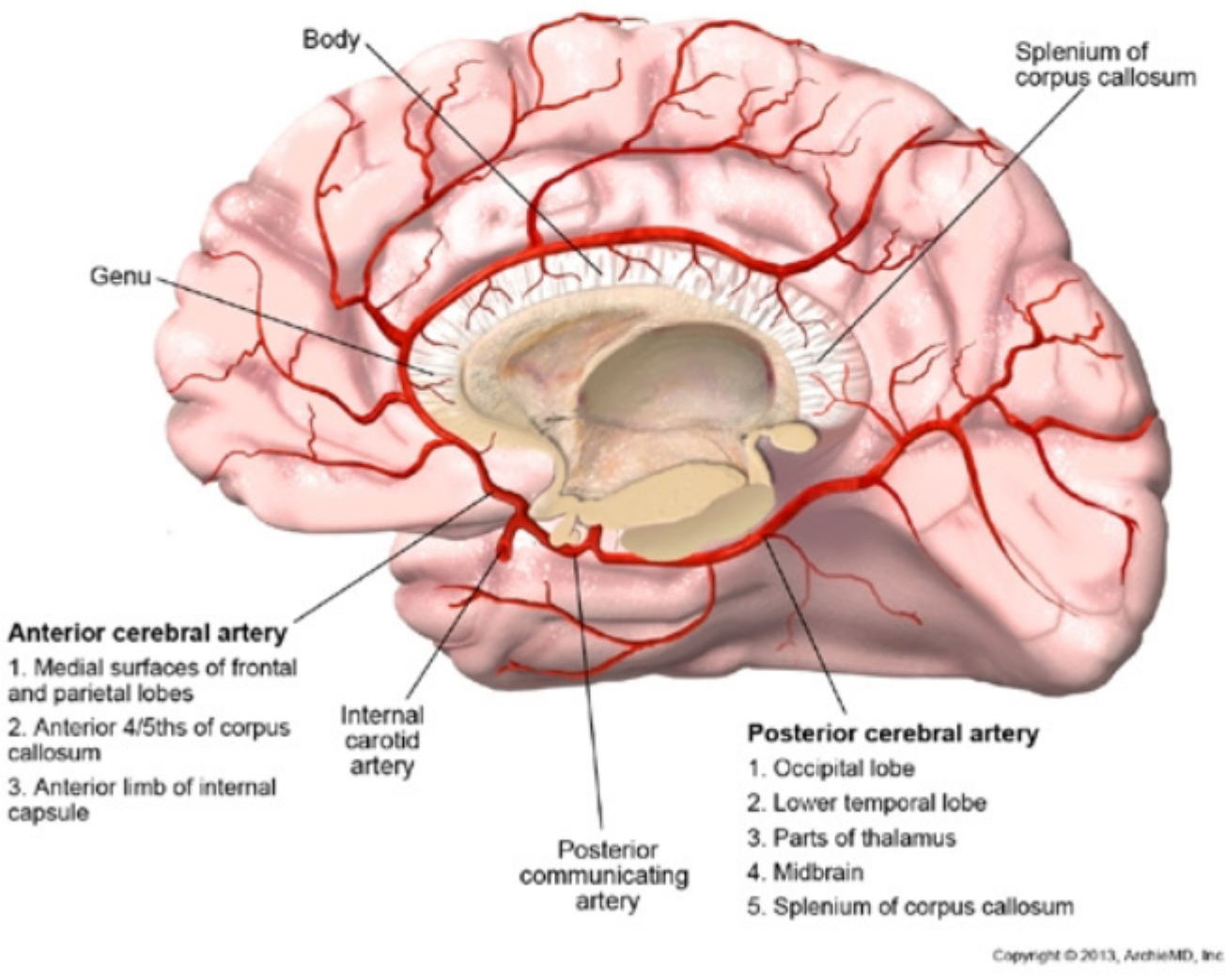

▲ **Figure 22–5.0C** Distribution of ACA and PCA

Please visit us at www.Groupinsiders.com

© DeVry/Becker Educational Development Corp. All rights reserved.

1. The two *internal carotid arteries* enter the skull through the carotid canal and course through the cavernous sinus to reach the inferior surface of the brain, where they divide into the anterior and middle cerebral arteries.
   - The *middle cerebral artery* is the largest branch and the continuation of the internal carotid artery after the anterior cerebral artery has branched from it. The middle cerebral artery courses through the lateral sulcus to supply:
     - **a.** most of the lateral surface of the frontal and parietal lobes (dedicated to the contralateral upper limb and the head and trunk);
     - **b.** the upper temporal lobe;
     - **c.** lacunar branches to the genu and posterior limb of the internal capsule;
     - **d.** parts of the basal ganglia.
   - The *anterior cerebral artery* is the smaller branch of the internal carotid artery and branches at a 90-degree angle. The two anterior cerebral arteries are connected by the anterior communicating artery. The artery travels between the two hemispheres and supplies:
     - **a.** most of the medial surfaces of the frontal and parietal lobes that represent the motor and sensory cortical areas for the contralateral lower limb and pelvis;
     - **b.** the anterior four fifths of the corpus callosum;
     - **c.** lacunar branches to the anterior limb of the internal capsule.
2. The two vertebral arteries join to form the single, midline *basilar artery* on the ventral surface of the pons. The basilar artery terminates at the rostral pons by dividing into the *two posterior cerebral arteries*. Each posterior cerebral artery is joined to the terminal ends of the internal carotid arteries by the posterior communicating artery to complete the posterior part of the *circle of Willis*. The posterior cerebral artery supplies the:
   - **a.** occipital lobe;
   - **b.** most of the lower part of the temporal lobe;
   - **c.** thalamus;
   - **d.** splenium of the corpus callosum.

Parts of the two posterior cerebral arteries, the two middle cerebral arteries, and the anterior cerebral arteries connect with the anterior and posterior communicating arteries to form the circle of Willis at the optic chiasm on the base of the brain.

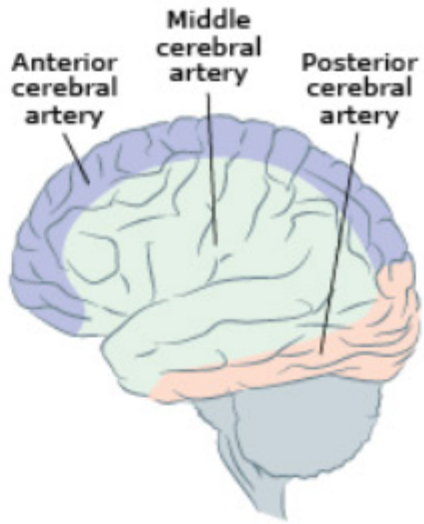

Lateral

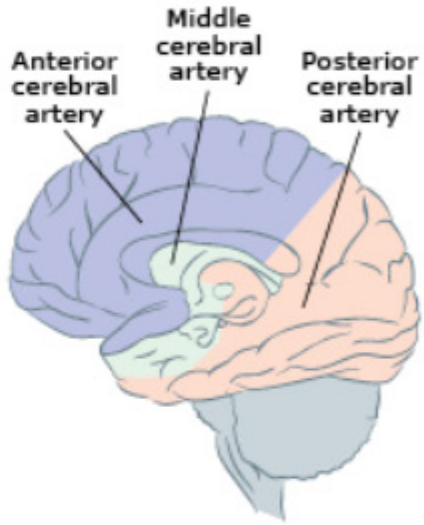

Medial

▲ **Figure 22–5.0D** Distribution of Cerebral Vessels

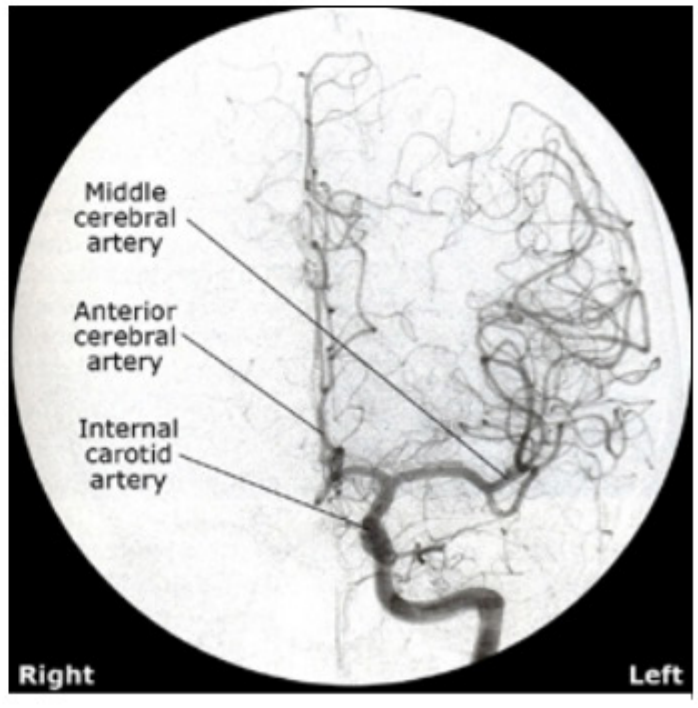

▲ **Figure 22–5.0E** Arteriogram of Internal Carotid Artery

Please visit us at www.Groupinsiders.com

© DeVry/Becker Educational Development Corp. All rights reserved.

6 Functional Areas of the Cortex

The major functional areas on the lateral surface of the cortex are shown in Figure 22–6.0.

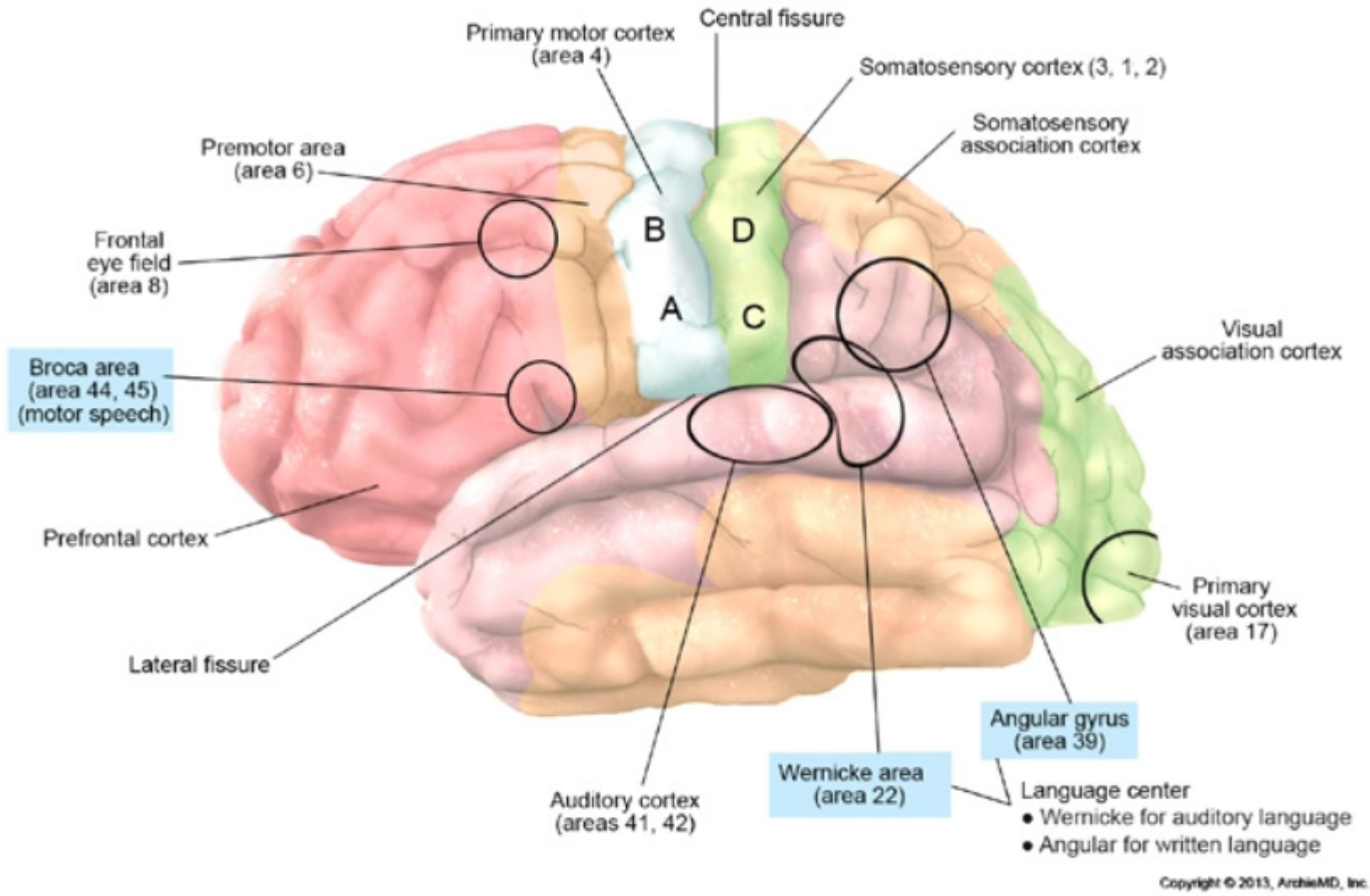

▲ **Figure 22–6.0** Functional Areas of the Cortex

6.1 Frontal Lobe

- The *primary motor cortex* (Brodmann area 4) occupies the precentral gyrus that borders the central sulcus on the lateral surface of the cortex and the motor strip of the paracentral lobule on the medial surface of the cortex. The precentral gyrus contains a high density of pyramidal cells that give rise to the corticospinal and corticobulbar upper motor neurons (UMN). Lesions produce contralateral muscle spasticity and weakness.
- The *premotor cortex* (area 6) also gives rise to upper motor neurons. It is thought to be associated with some degree of programming and planning of motor movements. Lesions result in difficulty in performing the correct sequence of a muscle activity. They can result in motor apraxia, in which the person will not perform a task when requested, but will spontaneously do so a few minutes later.
- The *frontal eye fields* (area 8) are rostral to area 6 and produce contralateral conjugate horizontal movements of the eyes.

Please visit us at www.Groupinsiders.com

© DeVry/Becker Educational Development Corp. All rights reserved.

- The *prefrontal cortex* is a large area of the frontal lobe referred to as the frontal association cortex. Parts of the prefrontal cortex have limbic connections and are associated with social behavior, and other parts are concerned with concentration, problem solving, judgment, and planning. With lesions of the prefrontal area, the individual has trouble with concentration and loss of ambition and judgment. The person is careless in appearance, with decreased social behavior, impairment in making decisions, planning, and social behavior.
- The *Broca area* (areas 44 and 45) is in the inferior frontal gyrus adjacent to the motor cortex for the head region. The Broca area is the motor programming cortex for motor speech and the production of words. It is adjacent to the motor cortex containing corticobulbar fibers that control muscles used in mechanical speech: vocal folds, tongue, lips, etc. Lesions of the Broca area will be discussed further.

6.2 Parietal Lobe

- The *somatosensory cortex* (areas 3, 1, and 2) occupies the postcentral gyrus on the lateral parietal lobe and the sensory strip of the paracentral lobule on the medial cortex. The sensory cortex consists of three areas, with area 3 being the area immediately posterior to the central sulcus. Lesion of the area produces contralateral anesthesia of areas represented by the homunculus.
- The *parietal association cortex* (areas 5 and 7) is located posterior and ventral to the somatosensory cortex and is involved in orderly and sequential performance of motor tasks. Lesions on the hemisphere of areas 5 and 7 are associated with (1) astereognosis, the inability to identify objects by touch; and (2) apraxia, the inability to perform a voluntary movement when there is no paralysis or sensory loss.
- On the inferior, lateral aspect of the parietal lobe is the *angular gyrus* (area 39), associated with language processing on the dominant hemisphere where written language is interpreted. This will be discussed further.

6.3 Temporal Lobe

The temporal lobe is located inferior to the lateral sulcus and contains the primary auditory area and areas associated with speech, emotions, and memory (limbic system).

- The *primary auditory cortex (*areas 41 and 42) on each hemisphere receives bilateral auditory input from both ears. Thus, a unilateral lesion in the primary auditory area results in no significant hearing loss, but does cause difficulty with sound direction.
- Posterior to the auditory cortex and extending into the lateral parietal lobe is the *Wernicke area* (area 22), which is involved in language processing for comprehension of the spoken language. Lesions of this area will be discussed later.

Please visit us at www.Groupinsiders.com

© DeVry/Becker Educational Development Corp. All rights reserved.

6.4 Occipital Lobe

The occipital lobe forms the posterior pole of the brain and contains the primary visual cortex and the visual association areas.

- The *primary visual (calcarine) cortex* (area 17) receives inputs from the lateral geniculate body of the thalamus via the optic radiations. The visual cortex is located at the posterior pole of the occipital lobe and is divided by the calcarine fissure into an upper gyrus called the *cuneus* and a lower lingual gyrus. The cuneus represents the contralateral lower quadrant visual field, and the lingual gyrus represents the contralateral upper quadrant visual fields. Because there is a point-to-point projection of visual fields from the retina to the cortex, the *macula region of the retina* is represented by the macula region of the cortex, which is at the most posterior surface of the visual cortex and incorporates a piece of the cuneus and lingual gyri.

  The entire occipital lobe and visual cortex are supplied by the posterior cerebral artery, but the macula region has a dual blood supply from the posterior cerebral artery and a collateral branch from the middle cerebral artery. A lesion of area 17 resulting from an occlusion of the posterior cerebral artery produces a contralateral homonymous hemianopsia with macular sparring because of the collateral blood supply provided by the middle cerebral artery.
- The *visual association area* is anterior to the primary cortex and forms most of the lateral aspect of the occipital lobe. This area receives visual inputs from primary visual cortical areas and is important in complex visual functions of color vision and perception of movement. Lesions result in the loss of contralateral color vision and the loss of perception of movement.

Please visit us at www.Groupinsiders.com

© DeVry/Becker Educational Development Corp. All rights reserved.

7 Language Disorders (Aphasias)

Language functions tend to be lateralized to one hemisphere. The hemisphere that is more important for the comprehension and production of language is called the *dominant hemisphere*. By far, the majority of the population is *left-dominant* for language. Dominance for language is usually established in the first decade of life. The main language areas in the dominant hemisphere are *Broca*, *Wernicke*, and the *angular gyrus*. Aphasic patients generally have difficulty writing (agraphia) and repeating words or phrases.

7.1 Expressive or Motor Aphasia

The *Broca area* for fluent speech is located in the inferior gyrus of the frontal lobe of the dominant hemisphere and is responsible for the motor programming of the muscles used in the production of words. A lesion of the Broca area of the frontal lobe results in *expressive* or *motor aphasia* characterized by:

- **Nonfluent Speech:** Patients have trouble putting words together to produce fluent speech. They often omit most of the unnecessary words and speak in very short sentences in a telegraphic, broken speech pattern.
- **Normal Language Comprehension:** Because the Wernicke and the angular gyrus are intact, the patients understand all that they hear and read.
- **Extreme Frustration:** Patients can interpret all incoming language, but lack the ability to verbalize their thoughts.
- **Agraphia (the inability to write):** This is often part of a Broca lesion.
- If the Broca lesion grows into the motor cortex, there may be damage to the upper motor neurons, which produces contralateral spasticity.

7.2 Receptive or Sensory Aphasia

The *Wernicke* (22) and *angular* (39) regions of the cortex are involved in language comprehension. The *Wernicke area* is involved in interpreting spoken language, and the *angular gyrus* is associated with interpreting written language. Damage to these two areas results in *receptive,* or *sensory aphasia*, which is characterized by:

- **Fluent Speech:** Production of words is fluent (the Broca area is intact), but the individual substitutes words and uses meaningless words; the lengthy speech has no meaning, often referred to as *word salad*.
- **Lack of Language Comprehension:** Patients do not comprehend what they read or hear.
- **Agraphia:** Patients cannot write.
- **Not Frustrated:** Patients are not aware of their language disorder.

Please visit us at www.Groupinsiders.com

© DeVry/Becker Educational Development Corp. All rights reserved.

7.3 Conduction Aphasia

The Wernicke area of the temporal lobe and the Broca area of the frontal lobe are connected by association fibers called the *arcuate fasciculus*, which courses through the parietal lobe. A deeper lesion in the parietal lobe of this bundle of fibers produces *conduction aphasia* (Figure 22–7.3):

- **Fluent Speech:** Verbal output is fluent, but individuals make repeated attempts for the correct words.
- **Intact Language Comprehension:** Auditory and visual comprehensions are not impaired.
- **Difficulty Naming Objects:** Individuals have trouble naming everyday common objects and pictures.
- **Difficulty Repeating Words:** Individuals cannot repeat words or a phrase upon request.

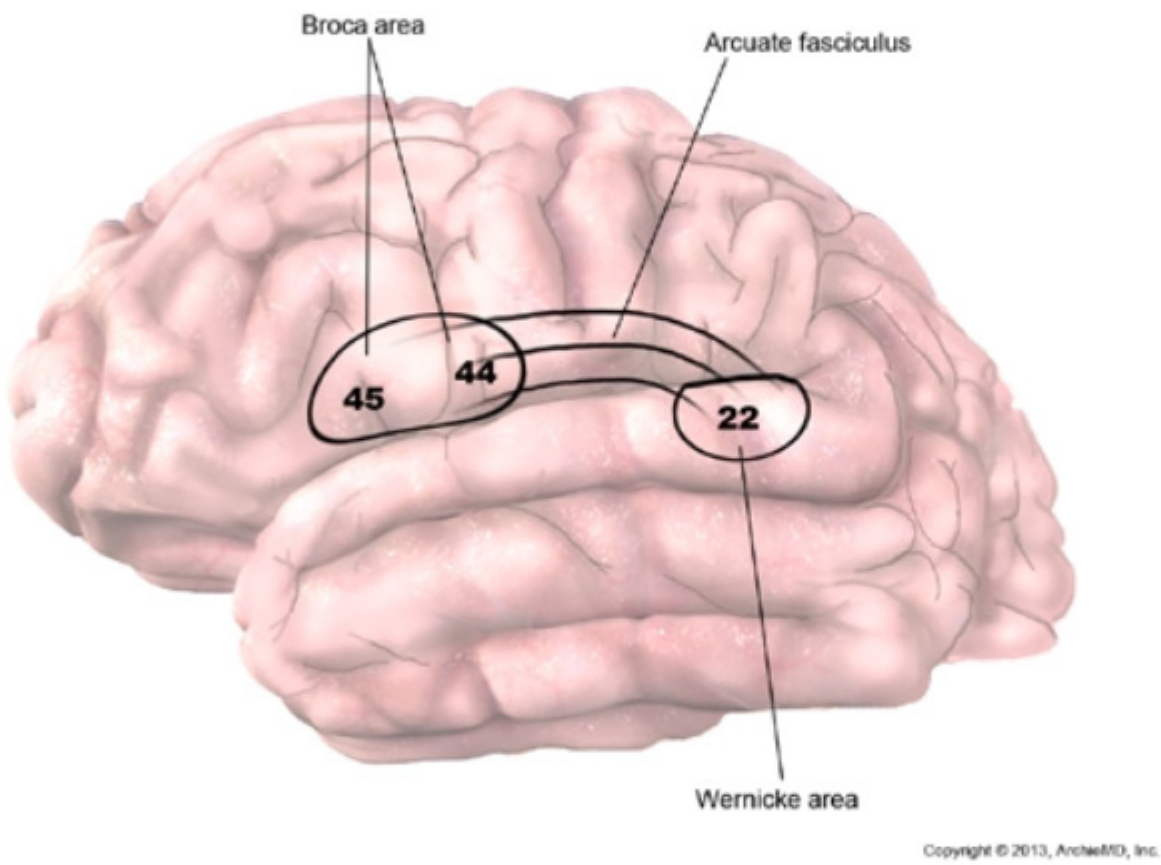

▲ **Figure 22–7.3** Conduction Aphasia

Please visit us at www.Groupinsiders.com

© DeVry/Becker Educational Development Corp. All rights reserved.

8 Additional Cortical Disorders

8.1 Gerstmann Syndrome

A lesion limited to the angular gyrus (area 39) of the inferior parietal lobe, usually on the *dominant hemisphere (left),* produces an interesting constellation of deficits called *Gerstmann syndrome*:

- Cannot read (alexia) due to loss of written comprehension.
- Cannot write (agraphia).
- Inability to do simple arithmetic (acalculia).
- Finger agnosia: The inability to distinguish one's own fingers.
- Right-to-left confusion.

8.2 Neglect Syndrome

A lesion of the angular gyrus in a similar area (areas 39 and 40) but on the *nondominant hemisphere (right)* results in the *neglect syndrome (asomatognosia)*, in which individuals do not recognize or perceive the *contralateral (left)* side of their body or their world (Figure 22–8.3).

8.3 Disconnect Syndromes

The following are two types of *disconnect syndromes,* in which the language centers (Wernicke and angular) of the left dominant hemisphere are disconnected from other cortical functional areas in the opposite hemisphere. The lesions are caused by vascular infarcts to different parts of the corpus callosum that connect the hemispheres.

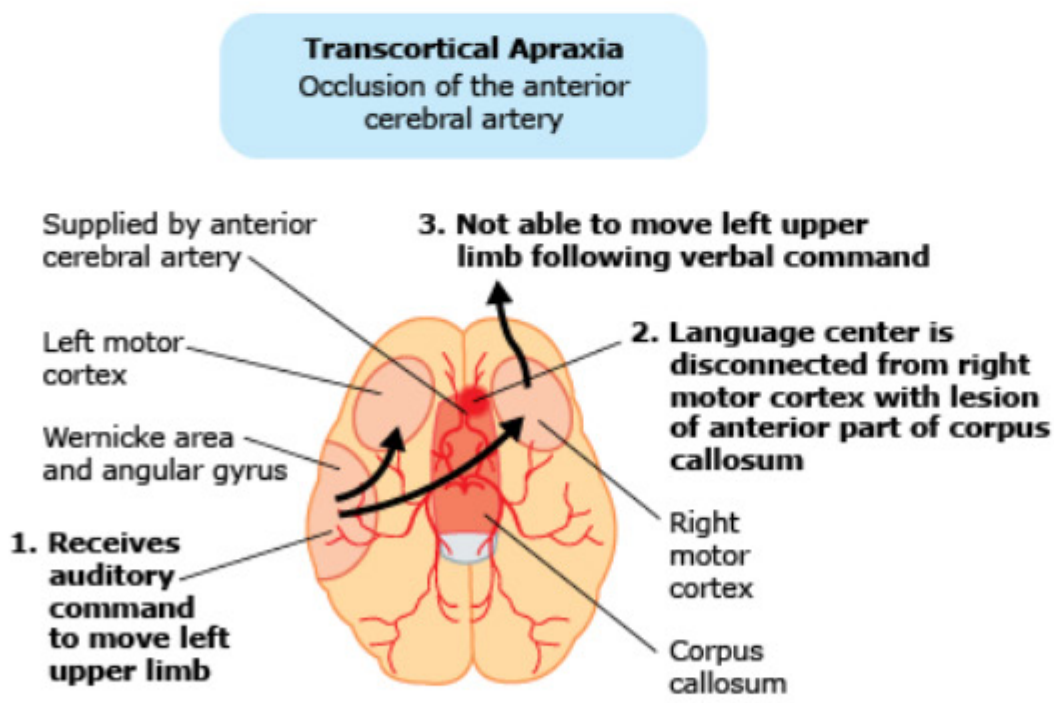

▲ **Figure 22–8.3A** Disconnect Syndromes

Please visit us at www.Groupinsiders.com

© DeVry/Becker Educational Development Corp. All rights reserved.

8.3.1 Transcortical Apraxia

Transcortical apraxia is a disconnection between the left language center in the dominant hemisphere from the right hemisphere motor cortex due to an occlusion of the *anterior cerebral artery*. The infarct damages the *anterior four fifths of the corpus callosum* that connects these two areas of the left and right hemispheres. In cases of apraxia, there is no muscle weakness or paralysis.

- A verbal command to *move a left limb* is heard and comprehended in the language centers of the dominant hemisphere.
- Lesions of the anterior corpus callosum prevent the verbal command from reaching the right motor cortex to execute the movement of the left limb. But the individual can move the left limb under his own control.
- Upon verbal command, the individual can move the right limb because there is no disconnect to the left motor cortex.

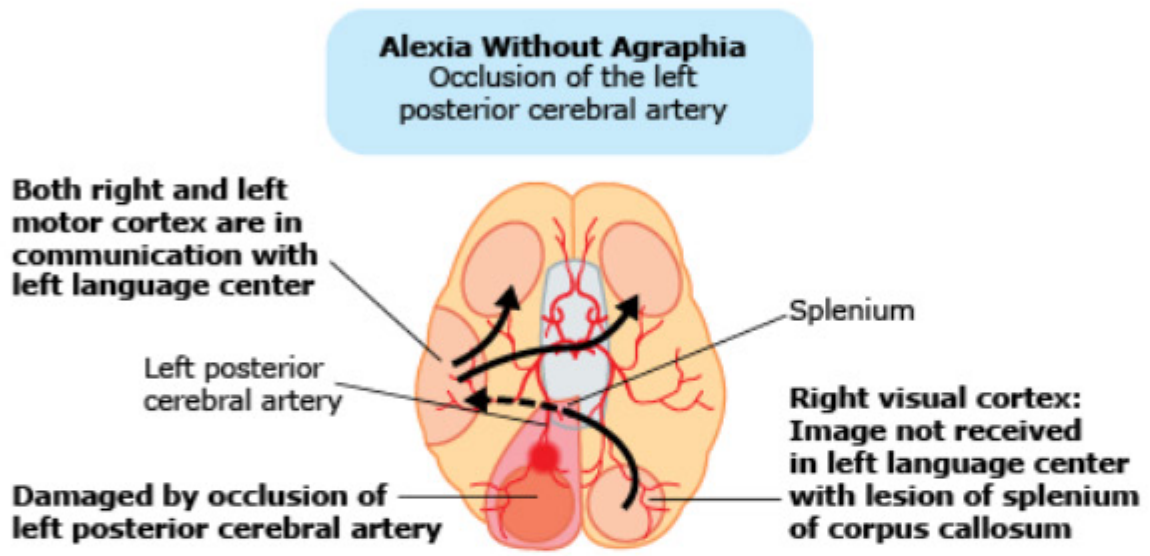

▲ **Figure 22–8.3B** Disconnect Syndromes

8.3.2 Alexia Without Agraphia

Alexia without agraphia is a disconnection between the left language center in the dominant hemisphere from the right visual cortex in the right hemisphere due to an occlusion of the *left posterior cerebral artery* that damages the *splenium* of the corpus callosum. The splenium connects the fibers of the right visual cortex to the left language center for comprehension.

- The left visual cortex is lesioned without any visual processing.
- The right visual cortex is intact, but is disconnected from the left language area (usually via the splenium), which prevents the visual images from the right intact visual cortex from reaching the left language centers. Thus, the individual cannot read *(alexia)*, and cannot interpret the words that he sees.
- The left motor cortex is not disconnected from the left language area, so the individual can write.
- Exhibits a right homonymous hemianopia (due to left visual cortex lesion).

Please visit us at www.Groupinsiders.com

© DeVry/Becker Educational Development Corp. All rights reserved.

▼ Table 22–8.3 Cortical Functions and Lesion Abnormalities

Lobe	Structure	Function	Destructive Lesion
Frontal	Precentral gyrus (in ant. wall of central sulcus) and paracentral lobule (ant. part)	Commands movements—head and upper limb and lower limb	Contralateral paralysis or paresis: lower face and upper limb and lower limb
	Frontal eye fields	Voluntary eye movements	Babinski response, paralysis of conjugate gaze to opposite side
	Broca speech	Word production	Nonfluent aphasia
	Prefrontal cortex	Problem solving, judgment, planning, etc.	Bilateral lesions: impaired ability to concentrate, easily distracted, loss of initiative, apathy, cannot make decisions
Parietal	Postcentral gyrus and paracentral lobule (post. part)	General sensory head and upper limb and lower limb	Contralateral anesthesia: head and upper limb and lower limb
	Angular gyrus (nondominant) Inferior parietal lobule (supra-marginal and angular gyrus)	Processing of somatic and visual information	Neglect of contralateral self and surroundings
	Angular gyrus (dominant hemisphere)	Recognition of body and surrounding objects	Gertsmann syndrome
Temporal	Transverse temporal gyrus (of Heschl)	Hearing (bilateral)	Subtle decrease in hearing and ability to localize sounds
	Superior temporal gyrus—(post. part in dominant hemisphere)	Wernicke speech: language understanding and formulation	Fluent aphasia
	Middle and inferior temporal gyrus	Long-term memory	Bilateral lesions: memory impairment of past events
	Uncal region	Olfaction	Bilateral lesions: anosmia
Occipital	Cuneus and lingual gyrus (walls of calcarine fissure)	Vision	Contralateral homonymous hemianopsia with macular sparring

Please visit us at www.Groupinsiders.com

© DeVry/Becker Educational Development Corp. All rights reserved.

9 Internal Capsule

The *internal capsule* is a narrow strip of white matter buried deep in the cortex (Figure 22–9.0). This serves as the gateway for the cortex, with most motor and sensory systems that are leaving or entering the cortex coursing through the internal capsule. It has important relationships with the basal ganglia that have been reviewed previously.

The internal capsule is divided into three basic sections, as reviewed in Table 22–9.0.

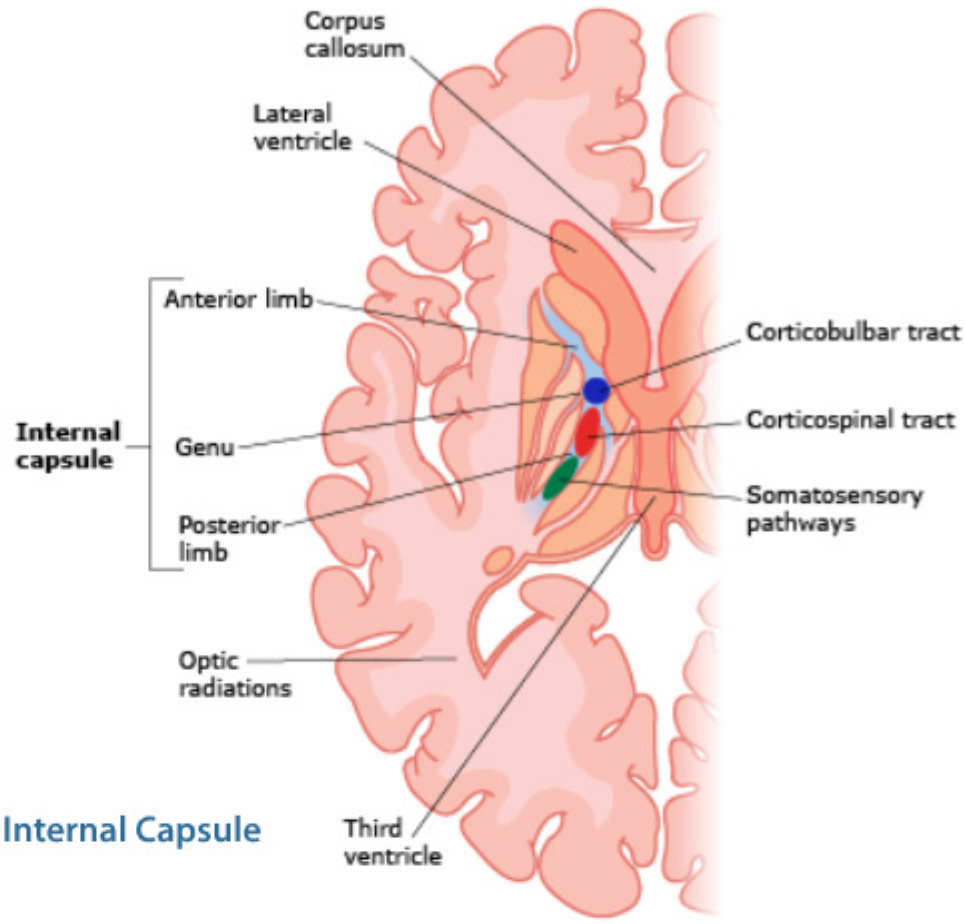

▶ **Figure 22–9.0** Internal Capsule

▼ **Table 22–9.0** Internal Capsule: Arterial Supply

Internal Capsule	Arterial Supply	Tracts
Anterior Limb	Medial striate branches of ACA	Prefrontal
Genu	Lenticulostriate branches of MCA	Corticobulbar
Posterior Limb	Lenticulostriate branches of MCA	Corticospinal, all somatosensory thalamocortical radiations; optic and auditory radiations

Note: The posterior cerebral artery also supplies the optic radiations. Abbreviations: ACA, anterior cerebral artery; MCA, middle cerebral artery

Clinical Application

A vascular stroke resulting from occlusion of the lenticulostriate branches of the middle cerebral artery results in (Figures 22–5.0A and 22–5.0B):

- Contralateral lower-face weakness.
- Contralateral upper- and lower-limb spasticity.
- Contralateral anesthesia of trunk, limbs, and face.
- Contralateral homonymous hemianopia.

Please visit us at www.Groupinsiders.com

© DeVry/Becker Educational Development Corp. All rights reserved.

1 Overview of the Limbic System

The *limbic system* is located on the medial aspect of the hemisphere, bordering the corpus callosum and rostral brainstem. The limbic nuclei connect structures between the cerebral cortex and the diencephalon. The limbic system concerns:

- Memory and learning.
- Visceral functions such as olfaction and feeding.
- Sex drive.
- Behavior, emotions, and feelings.

The major components of the limbic system are the *hippocampus*, *mammillary body*, *anterior and dorsomedial nuclei of the thalamus*, and the *cingulate gyrus*. In addition, the *amygdala plays an important role in behavior and sex drive*. The hippocampus and amygdala are located on the medial surface of the temporal lobe.

USMLE® Key Concepts

For Step 1, you must be able to:

- Describe the major components of the limbic system and the pathway of the limbic structures in the Papez circuit.
- Explain the major functions of the limbic system.
- Identify the major lesions of the limbic system.

Please visit us at www.Groupinsiders.com

© DeVry/Becker Educational Development Corp. All rights reserved.

2 Papez Circuit

The *Papez circuit* describes a series of connections that begin and end in the *hippocampus*. They are associated with processing memory and learning (Figure 23–2.0). The hippocampus is located on the medial surface of the temporal lobe and is important in the consolidation of memory and learning and converting short-term memory to long-term memory. The hippocampus projects efferents via the fornix to the mammillary bodies of the hypothalamus. The mammillary bodies project to the anterior nucleus of the thalamus, which then projects to the cingulate gyrus, and the cingulate gyrus projects back to the hippocampus.

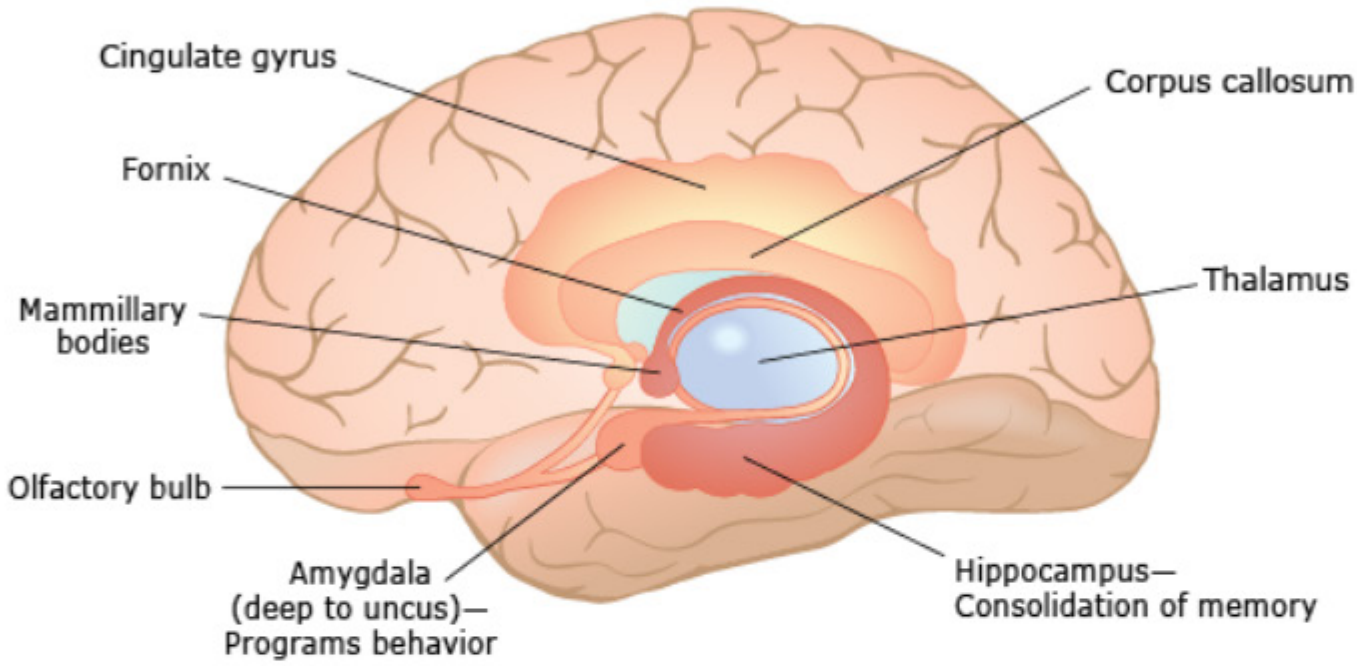

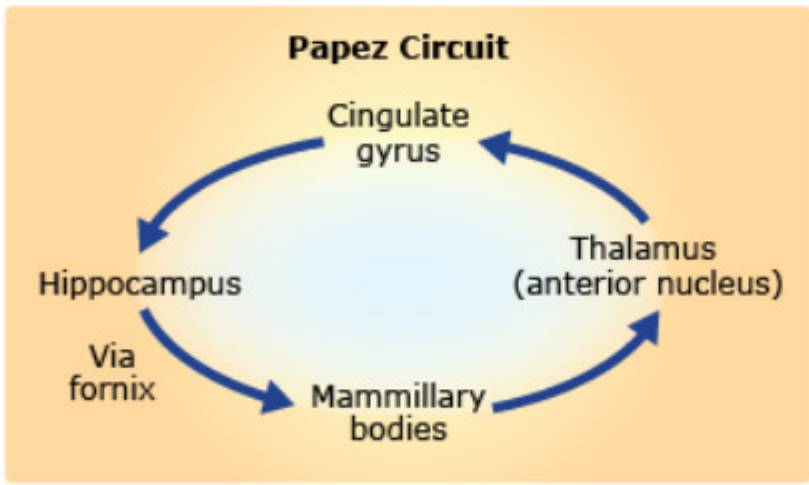

▲ **Figure 23–2.0** Limbic System

Please visit us at www.Groupinsiders.com

© DeVry/Becker Educational Development Corp. All rights reserved.

3 Amygdala

The *amygdala* plays a significant role in behavior and emotions and feeding. It is located inferior to the uncus at the medial tip of the temporal lobe. The amygdala connects experiences with consequences and then programs the appropriate behavior to an event. It is also the organ that programs fear, rage, and sex drive.

Clinical Application

Anterograde Amnesia

Bilateral degeneration of the hippocampus results in the inability to form long-term memories (anterograde amnesia), although past memories and intelligence are intact.

Korsakoff Syndrome

Chronic alcoholism and thiamine (vitamin B1) deficiency result in bilateral damage to the *mammillary bodies* and the *dorsomedial nucleus* of the thalamus, producing *Korsakoff syndrome*. Patients present with anterograde amnesia (cannot form new memories) and retrograde amnesia (lose past memories). They confabulate and make up stories to compensate for their loss of memory.

Klüver–Bucy Syndrome

Klüver-Bucy syndrome results from bilateral temporal lobe lesions involving the amygdala and hippocampus.

- Individuals are placid and passive, with decreased emotional excitability.
- Individuals place most objects in their mouths.
- Hypersexuality.
- Anterograde amnesia.
- Visual agnosia (psychic blindness), in which individuals or objects are not recognized visually.

Please visit us at www.Groupinsiders.com

© DeVry/Becker Educational Development Corp. All rights reserved.

4 Cortex Review

An overview of the major CNS structures of the cortex and head is shown in Figure 23–4.0.

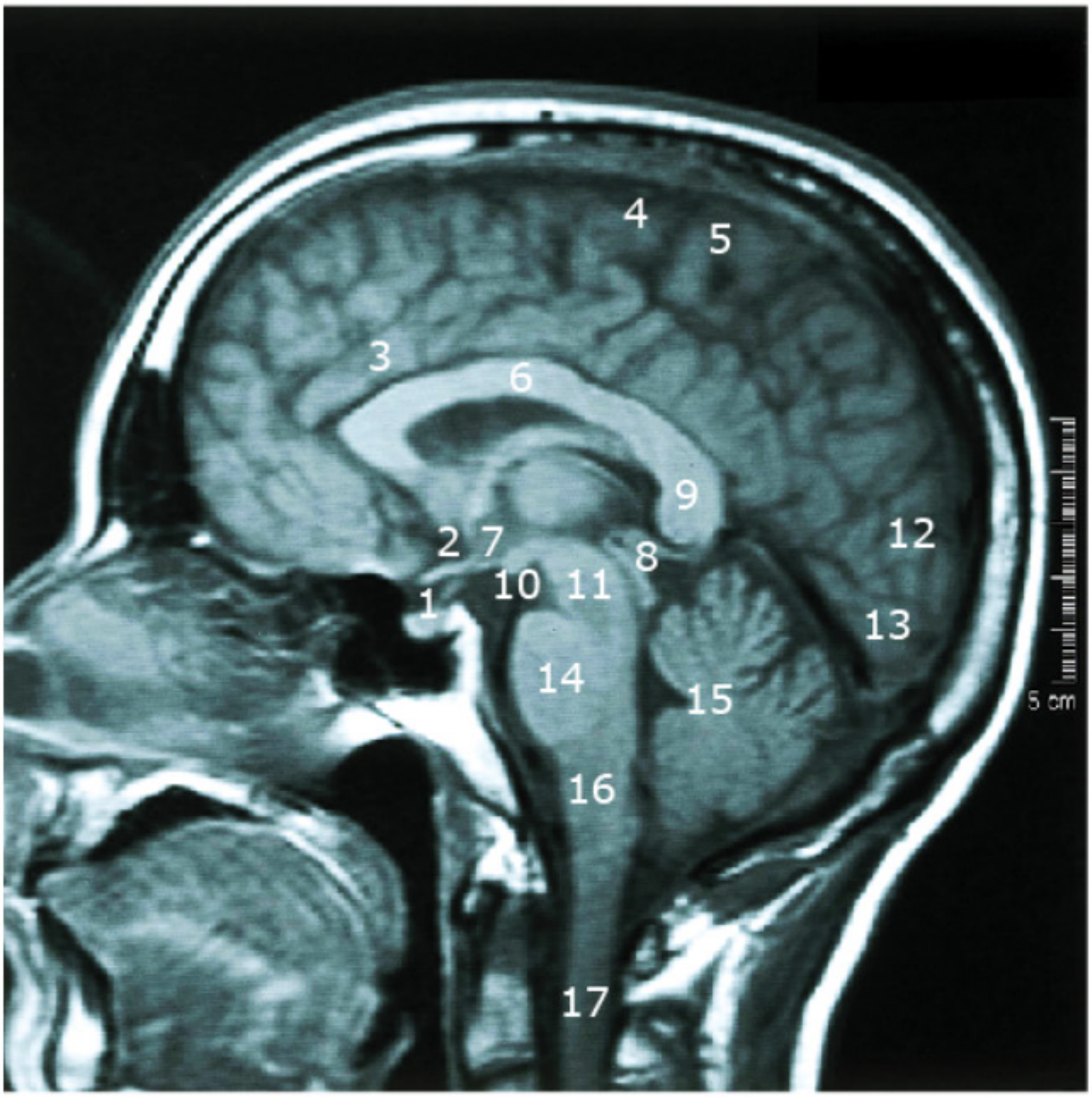

1. Pituitary
2. Optic chiasm
3. Cingulate gyrus
4. Primary motor cortex
5. Primary somato-sensory cortex
6. Corpus callosum (body)
7. Hypothalamus
8. Pineal body
9. Splenum
10. Mammillary body
11. Midbrain
12. Cuneus gyrus
13. Lingual gyrus
14. Pons
15. Cerebellar vermis
16. Medulla
17. Spinal cord

Wellcome Images

▲ **Figure 23–4.0** CNS Structures of the Cortex

Please visit us at www.Groupinsiders.com

© DeVry/Becker Educational Development Corp. All rights reserved.

Chapters 21–23 Review Questions

1. A male patient collapses at his home and is admitted to the hospital. An MRI indicates a large vascular stroke. Over the next several days the patient develops spastic weakness of his right upper limb and weakness on the lower part of his right face. There also is sensory loss on the right upper limb and right face. In addition, his speech patterns are significantly altered. The stroke most likely occurred in which of the following arteries?

A. Right anterior cerebral
B. Left posterior cerebral
C. Left vertebral
D. Left middle cerebral
E. Lacunar branches of right middle cerebral

2. A patient presents with a weakness in elevation of both eyes and an increase in CSF pressure. Which of the following most likely would be the site of the lesion?

A. Precentral gyrus
B. Frontal eye fields
C. Pineal gland
D. Arachnoid granulations
E. Hypothalamus

3. A 60-year-old woman develops severe weakness of her right lower limb. The neurological exam shows that sensory functions for the same limb are normal and her cranial nerve functions are normal. An MRI indicates a small, isolated lesion in her cortex. Which of the following areas most likely would be the location of the lesion?

A. Left premotor cortex
B. Left anterior paracentral gyrus
C. Right posterior paracentral gyrus
D. Right primary motor cortex
E. Left posterior limb of the internal capsule

4. A neurological exam reveals that an elderly patient shows spasticity and weakness of the muscles on the left lower face and the left upper and lower limbs. An MRI indicates a hemorrhagic stroke. These deficits would indicate a lesion in which of the following areas?

A. Right primary and premotor cortex and genu of the internal capsule
B. Left primary and premotor cortex
C. Right genu and the adjacent segment of the posterior limb of the internal capsule
D. Right posterior limb of the internal capsule
E. Left posterior limb and genu of the internal capsule

5. A 55-year-old-man goes to his physician complaining of language problems, which have become progressively worse for the last month. His speech is fluent but he often uses the wrong words and is having trouble understanding both what he reads and what he hears. Where would the lesion most likely be located in a patient with these symptoms?

A. Lower frontal lobe adjacent to the lateral sulcus
B. Somatosensory association cortex
C. Frontal lobe immediately anterior to the central sulcus
D. Arcuate fasciculus
E. Upper temporal and lower parietal gyri

Please visit us at www.Groupinsiders.com

© DeVry/Becker Educational Development Corp. All rights reserved.

Review Answers Chapters 21–23

1. The correct answer is D. The stroke involved the lateral aspect of the left cortex due to occlusion of the left middle cerebral artery. The left primary and premotor cortex of the frontal lobe and the left somatosensory cortex of the parietal lobe were damaged, resulting in the contralateral (right) motor weakness and spasticity and the contralateral sensory losses on the upper limb and face, respectively. The language areas on the left cortex also were involved.

2. The correct answer is C. The bilateral weakness in elevation of the eyes (sunset eyes at rest) with increased CSF pressures due to blockage of CSF circulation (cerebral aqueduct) occurs following a pineal gland tumor. These symptoms are called Parinaud syndrome.

3. The correct answer is B. The right lower limb weakness with normal sensory functions would result from a small lesion affecting the anterior gyrus of the left paracentral lobule. The left anterior paracentral gyrus provides the UMN of the corticospinal tract dedicated to the contralateral lower limb (right lower limb in the case).

4. The correct answer is C. The muscle weakness and spasticity seen on the left lower face and left upper and lower limbs suggest a stroke involving the right internal capsule. The corticobulbar UMN fibers to the contralateral left lower face occupy the genu of the internal capsule, and the corticospinal UMN fibers for the contralateral left upper and lower limbs occupy an adjacent segment of the internal capsule's posterior limb.

5. The correct answer is E. The patient is showing signs of receptive or Wernicke aphasia, which includes fluent but meaningless speech and a lack of understanding of incoming auditory or visual language. This type of language disorder results from damage to the Wernicke (22) and angular (39) gyri located in the upper part of the temporal lobe and the lower part of the parietal lobe, respectively.

Please visit us at www.Groupinsiders.com

© DeVry/Becker Educational Development Corp. All rights reserved.

Please visit us at www.Groupinsiders.com

Please visit us at www.Groupinsiders.com

USMLE STEP 1 REVIEW

BECKER
PROFESSIONAL EDUCATION®

becker.com
ACCOUNTING | PROJECT MANAGEMENT | HEALTHCARE

USMLE® is a joint program of the Federation of State Medical Boards and the National Board of Medical Examiners®.

© 2013 DeVry/Becker Educational Development Corp. All rights reserved.